A TREATISE

ON

ORTHOPEDIC SURGERY

BY

ROYAL WHITMAN, M.D.

INSTRUCTOR IN ORTHOPEDIC SURGERY IN THE COLLEGE OF PHYSICIANS AND SURGEONS OF COLUMBIA UNIVERSITY, NEW YORK; ASSOCIATE SURGEON TO THE HOSPITAL FOR RUPTURED AND CRIPPLED; ORTHOPEDIC SURGEON TO THE HOSPITAL OF ST. JOHN'S GUILD; CHIEF OF THE ORTHOPEDIC DEPARTMENT OF THE VANDERBILT CLINIC.
MEMBER OF THE ROYAL COLLEGE OF SURGEONS OF ENGLAND; MEMBER AND SOMETIME PRESIDENT OF THE AMERICAN ORTHOPEDIC ASSOCIATION; CORRESPONDING MEMBER OF THE BRITISH ORTHOPÆDIC SOCIETY; MEMBER OF THE NEW YORK SURGICAL SOCIETY, ETC.

SECOND EDITION, REVISED AND ENLARGED

ILLUSTRATED WITH FIVE HUNDRED AND SEVEN ENGRAVINGS

THE LIBRARY OF CONGRESS

LEA BROTHERS & CO.
PHILADELPHIA AND NEW YORK
1903

THE LIBRARY OF CONGRESS,
TWO COPIES RECEIVED
NOV 2 1903
COPYRIGHT ENTRY
Nov. 2-1903
CLASS a XXc. No.
71769
COPY B.

1 d
4271

Entered according to the Act of Congress, in the year 1903, by
LEA BROTHERS & CO.,
in the Office of the Librarian of Congress. All rights reserved.

DORNAN, PRINTER.

TO

VIRGIL P. GIBNEY, M.D., LL.D.

THIS VOLUME IS INSCRIBED

AS A TOKEN OF FRIENDSHIP ASSURED BY LONG ASSOCIATION

AND OF APPRECIATION OF HIS EFFORTS

FOR THE ADVANCEMENT OF

ORTHOPEDIC SURGERY

PREFACE TO THE SECOND EDITION.

THE author has utilized the opportunity offered by the early exhaustion of the first edition to thoroughly revise the book; and he trusts that in its present form it fairly represents this department of medicine at the date of issue. The consideration of new subjects, the more extended description of others, and the addition of illustrative figures have resulted in a material enlargement of the book, but the general characteristics of the first edition have been retained.

283 LEXINGTON AVENUE, NEW YORK, October, 1903.

FROM THE PREFACE TO THE FIRST EDITION.

In the preparation of this volume it has been the purpose of the author to present as adequately as might be the practice of Orthopedic Surgery of the present day. The student of this subject is especially concerned with the mechanics of the human machine, with its development, with its capacity at different periods of life and under varying conditions, and with those affections that lead to deformity or that otherwise impair its usefulness. He is concerned, moreover, not only with the local and immediate effects of disease or disability, but with its general influence upon the entire mechanism, and with its ultimate consequences as well.

Orthopedic Surgery occupies a broad field and one of very great and general interest. Its most distinctive advance in recent years has been toward the prevention of deformity, an advance

that has been made possible by the better understanding of its predisposing and exciting causes. As a natural consequence, treatment has become more direct, more simple, and more effective. It has been the purpose of the author to emphasize this aspect of the subject, which is of the greatest importance to the general practitioner, who so often has the opportunity to recognize disease or disability in its incipiency, when its progress may be checked by timely treatment.

He has endeavored to present Orthopedic Surgery as far as possible objectively, and in a manner that has proved acceptable to students and practitioners in clinical teaching. Thus the selection of each subject and the space that has been allotted to it has been determined primarily by its relative importance in the actual work of orthopedic clinics. He has been at some pains, also, to outline methods of examination, to explain the phenomena of the symptoms and so to describe and to illustrate the causes and effects of disease and disability as to indicate, in natural sequence, the principles of treatment; but the particular methods of the application of these principles, which have been described in detail, are always those that have been tested by personal experience.

Although this book is designed particularly for students and practitioners of medicine, the author has included statistical and other data which he hopes may prove of interest to his fellow-workers in this special field.

The author desires to express his obligation to the gentlemen who have assisted him in the collection of statistics, and otherwise, whose names are mentioned in the text; to Dr. L. W. Ely and to Mr. W. P. Agnew for timely photographs, and especially to the Trustees of the Hospital for Ruptured and Crippled, for the facilities that have been afforded him in the preparation of this work.

CONTENTS.

CHAPTER I.

TUBERCULOUS DISEASE OF THE SPINE.

PAGE

Description —Pathology —Etiology —Statistics —General prognosis — Symptoms—Physical examination—Contour and flexibility of the spine—Divisions of the spine—Landmarks—The differential diagnosis of disease in the lower, middle, and upper regions of the spine—Treatment by horizontal fixation and overextension—by braces—by plaster jackets—by other means. The selection and adaptation of treatment for disease of the different regions of the spine. The complications of tuberculous disease of the spine—Abscess—course —symptoms—treatment. Paralysis—course—symptoms—treatment. Forcible correction of deformity—(Calot's operation)—Gradual correction of deformity—Recurrence of Disease—Secondary deformities—Recapitulation. 17

CHAPTER II.

NON-TUBERCULOUS AFFECTIONS OF THE SPINE.

Syphilis—Malignant disease—Osteomyelitis, acute and chronic—Actinomycosis —Injury —Traumatic spondylitis —Rhachitic spine—Typhoid spine—Gonorrhœal arthritis of the spine—Arthritis—Spondylitis deformans, varieties—Osteitis deformans—Neurotic spine—Hysterical spine —Pain in the back —Spondylolisthesis—Sciatic scoliosis—Disease and injury at the sacroiliac articulation . . 129

CHAPTER III.

LATERAL CURVATURE OF THE SPINE.

Description—habitual and fixed deformity, rotation and lateral deviation. Pathology—Etiology —Statistics —Varieties —Distribution and effects of deformity—Symptoms—Diagnosis—Prognosis—Prevention of deformity—Desks, chairs—Principles of treatment—Treatment —by exercises — general exercises — heavy exercises — special exercises—Supports. Forcible correction of deformity — Adjuncts in treatment—Duration of treatment 149

CHAPTER IV.

DEFORMITIES OF THE SPINE (CONTINUED). DEFORMITIES OF THE CHEST FUNCTIONAL PATHOGENESIS OF DEFORMITY.

Varieties in contour of the spine —The round and the flat back—Kyphosis —Lordosis —Treatment —Congenital elevation of the scapula —

PAGE

Absence of vertebræ—Flat chest—Pigeon chest—Funnel chest—Minor deformities—Absence of ribs—Defective formation of the pectoral muscles—Absence or defect of the clavicle—Acquired luxation or subluxation of the clavicle—Asymmetrical development—Tables of height, weight, and circumference of the chest—Functional pathogenesis of deformity—(Wolff's law)—Atrophy of bone . 223

CHAPTER V.

TUBERCULOUS DISEASE OF THE BONES AND JOINTS.

Predisposition—Mode of infection—Latent tuberculosis—Local predisposition—Statistics—distribution of disease—location—side affected—sex—age. Pathology—Varieties of disease—synovial—arborescent synovial form—lipoma arborescens—rice bodies—caries sicca—Progress and method of repair—Prognosis—Treatment—operative and mechanical—by drugs—local applications—X-ray—Active and passive congestion—venous stasis (Bier's treatment) 243

CHAPTER VI.

NON-TUBERCULOUS DISEASES OF THE JOINTS.

Syphilitic disease of joints—Gonorrhœal arthritis—Other forms of infectious arthritis—Acute epiphysitis—acute osteomyelitis—Subacute osteomyelitis—Osteoarthritis and rheumatoid arthritis—Varieties—Treatment—Still's disease—Hæmophilia—Hæmarthrosis—Scorbutus—Charcot's disease—Other forms of arthropathy—Anchylosis 263

CHAPTER VII.

TUBERCULOUS DISEASE OF THE HIP-JOINT.

Pathology—Statistics—Symptoms—Physical signs, distortion, apparent lengthening, apparent shortening. Causes of distortion—Atrophy—Causes of actual shortening—Measurements—Lovett's table—Kingsley's table—Explanation of physical signs—Differential diagnosis—Principles of treatment—The traction hip brace—The Thomas brace—The plaster bandage—Various methods of reducing deformity—Comparison of methods of treatment—The long hip splint—Other forms of apparatus—Bilateral hip disease—Hip disease in infancy—Hip disease in adult life—Abscess—statistics—treatment—Operative treatment—exploration—excision—reduction of resistant deformity—Prognosis, mortality, functional results—Secondary deformities of hip disease—Treatment—Final results . 291

CHAPTER VIII.

NON-TUBERCULOUS AFFECTIONS OF THE HIP-JOINT.

Statistics—Traumatisms at the hip—Acute infectious arthritis—Subacute arthritis—Spontaneous dislocation—Gonorrhœal arthritis—Extra-articular disease—Malignant disease at the hip-joint—Cysts of the femur—Arthritis deformans 391

CHAPTER IX.

TUBERCULOUS DISEASE OF THE KNEE-JOINT.

PAGE

Pathology—Etiology—Statistics—Symptoms, primary and secondary distortions—Shortening and lengthening—Diagnosis—Differential diagnosis—Treatment—Reduction of deformity—Forms of braces—Accessories in treatment—Extra-articular disease—Abscess—Operative treatment—arthrectomy—excision, amputation—Prognosis—mortality—functional results—General conclusions . . 399

CHAPTER X.

NON-TUBERCULOUS AFFECTIONS OF THE KNEE-JOINT.

Injury in childhood—Synovitis—Infectious arthritis—Osteoarthritis—Prepatellar bursitis—Pretibial bursitis—Injury of tibial tubercle—Bursæ and cysts in the popliteal region—Internal derangement of the knee-joint—Acquired genu recurvatum—Congenital genu recurvatum—rudimentary or absent patella—Congenital displacement of patella—Slipping patella—Elongation of the ligamentum patellæ—Snapping knee—Congenital contraction at the knee—General contractions 427

CHAPTER XI.

DISEASES AND INJURIES OF THE ANKLE-JOINT.

Tuberculous disease—Pathology—Etiology—Statistics—Symptoms—Diagnosis—Treatment—Prognosis—Tuberculous disease of the tarsus—Statistics—Treatment—Sprain of the ankle—Chronic sprain—Tenosynovitis—Other affections of the ankle-joint . . . 440

CHAPTER XII.

DISEASES AND INJURIES OF THE ARTICULATIONS OF THE UPPER EXTREMITY.

Tuberculous disease of the shoulder-joint—Pathology—Statistics—Symptoms—Treatment—Prognosis—Tuberculous disease of the elbow-joint—Pathology—Statistics—Symptoms—Treatment—Prognosis—Tuberculous disease of the wrist-joint—Symptoms—Treatment—Prognosis—Spina ventosa—Periarthritis at the shoulder-joint—Chronic bursitis at the shoulder—Sprain of the wrist—Acute and chronic tenosynovitis at the wrist 457

CHAPTER XIII.

DEFORMITIES OF THE UPPER EXTREMITY.

Congenital dislocation of the shoulder—Treatment—Obstetrical paralysis—Recurrent dislocation of the shoulder—Congenital deformities of the elbow—Cubitus valgus—Cubitus varus—Subluxation of the wrist—Congenital deformities at the wrist—Club-hand—Varieties

PAGE

Treatment—Club-hand associated with defective development—Congenital contraction of the fingers—Webbed fingers—Congenital displacement of phalanges—Trigger finger—Mallet finger—Base-ball finger—Dupuytren's contraction 472

CHAPTER XIV.

CONGENITAL AND ACQUIRED AFFECTIONS LEADING TO GENERAL DISTORTIONS.

Rhachitis—Etiology—Pathology—Symptoms, deformities—Prognosis—Treatment—"Late rickets"—Chondrodystrophia—Infantile scorbutus—Fragilitas ossium—Osteomalacia—Osteitis deformans—Secondary hypertrophic osteo-arthropathy—Acromegalia . . . 486

CHAPTER XV.

CONGENITAL DISLOCATION OF THE HIP AND COXA VARA.

Congenital dislocation of the hip-joint—Statistics—Pathology—Etiology—Symptoms, unilateral, bilateral—Anterior—Supracotyloid—Diagnosis—Differential diagnosis—Treatment—the Lorenz operation—Details and modifications—Prognosis—Treatment of older subjects—Treatment in infancy—The open operation—Arthrotomy—the intermediate operation—secondary osteotomy—Review of treatment—Congenital subluxation of the hip—Snapping hip—Palliative treatment—Coxa vara—Pathology—Etiology—Statistics—Symptoms, unilateral, bilateral—Diagnosis—Treatment—mechanical—operative—Forcible abduction—Osteotomy—Cuneiform—Linear—Fracture of the neck of the femur—Traumatic separation of the epiphysis of the head of the femur—Fracture in adult life—Coxa valga 502

CHAPTER XVI.

DEFORMITIES OF THE BONES OF THE LOWER EXTREMITY.

Bow-leg—Knock-knee—Statistics—Etiology—The outgrowth of deformity—Genu valgum—Description—Attitudes—Secondary deformities—Gait—Unilateral deformity—Pathology—Treatment—expectant—mechanical—operative—Genu varum, varieties—Symptoms—Treatment—Expectant—mechanical—operative—Anterior bow-leg—General rhachitic distortions 553

CHAPTER XVII.

DISEASES OF THE NERVOUS SYSTEM.

Acute anterior poliomyelitis—Pathology—Etiology—Statistics—Symptoms—Diagnosis—Prognosis—Causes of Deformity—Deformity in various regions—Subluxation—Retardation of growth—Principles of Treatment—Treatment, mechanical, operative 583

CHAPTER XVIII.

DISEASES OF THE NERVOUS SYSTEM (CONTINUED).

PAGE

Cerebral paralysis of childhood—Description—Distribution—Etiology—Pathology—Symptoms—Congenital paralysis—Acquired paralysis—Hemiplegia—Paraplegia—Treatment—Prognosis—Spastic spinal paraplegia—Progressive muscular atrophy—Varieties—Symptoms—Hereditary ataxia—Neuritis—Hysterical and functional affections of the joints—"Hysterical" hip—Differential diagnosis—"Hysterical" deformities—"Hysterical" club-foot—"Hysterical" scoliosis—Neurotic joints 606

CHAPTER XIX.

CONGENITAL AND ACQUIRED TORTICOLLIS.

Description—Statistics—Congenital torticollis—Etiology—Hæmatoma of the sternomastoid muscle—Acquired torticollis—Varieties—Acute torticollis—Etiology—Symptoms—Diagnosis—Treatment of chronic torticollis—mechanical, operative—Treatment of acute torticollis—Spasmodic torticollis—Etiology—Pathology—Treatment—Exceptional forms of torticollis—paralytic—diphtheritic—cervical opisthotonos, rhachitic—ocular—psychical 625

CHAPTER XX.

DISABILITIES AND DEFORMITIES OF THE FOOT.

General description of the foot and of its functions, the arches, the foot as a passive support, in activity—Improper postures—Movements—Function of the muscles—Strength of the muscles—The foot as a mechanism—The weak foot or so-called flat-foot—Description—Anatomy—Pathology—Etiology—Statistics—Symptoms—Diagnosis—Varieties—Weak foot in childhood—Treatment, preventive—Exercises—Support—Construction of brace—The rigid weak foot—Forcible correction of deformity—Subsequent treatment—Adjuncts in treatment—Operative treatment 647

CHAPTER XXI.

DISABILITIES AND DEFORMITIES OF THE FOOT (CONTINUED).

The hollow foot—Varieties and treatment—Anterior metatarsalgia—Morton's neuralgia—Etiology—Treatment—Achillobursitis—Strain of the tendo Achillis—Calcaneobursitis—Plantar neuralgia—Erythromelalgia—Hallux rigidus—Painful great toe—Hallux varus—Pigeon toe—Hallux valgus—Hammer toe—Overlapping toes—Fracture of metatarsus—Exostoses—Displacement of the peronei tendons—Shoes, effects of improper shoes—Demonstration of the proper shoe—Socks 699

CHAPTER XXII.

DEFORMITIES OF THE FOOT.

PAGE

Talipes—Description—Varieties—Statistics of talipes, congenital and acquired—Relative frequency of the different varieties—Congenital talipes—Etiology—Anatomy—Symptoms—Principles of treatment of infantile club-foot—Treatment—mechanical—by plaster bandage—by braces—restoration of function—supervision—Treatment in older subjects—forcible manual correction—tenotomy—Wolff's treatment, reduction of deformity by wrenches—Phelps' operation—Operations on the bones—Astragalectomy—Osteotomy—Mechanical treatment—Other varieties of congenital talipes—varus—equinus—calcaneus—valgus—equinovalgus—calcaneovalgus—calcaneovarus—equinocavus—valgocavus—Congenital talipes associated with defective development—with absence of fibula—with absence of tibia—with defective formation of the foot—Constricting bands—Congenital amputation—Congenital œdema—Spina bifida and talipes 733

CHAPTER XXIII.

DEFORMITIES OF THE FOOT (CONTINUED).

Acquired talipes—Etiology—Diagnosis—Talipes equinus—Description—Etiology—Symptoms—Treatment—mechanical—operative Talipes calcaneus—Description, development of deformity—Symptoms—Treatment—mechanical, operative—Talipes calcaneo varus and calcaneovalgus—Talipes equinovarus and talipes equinovalgus—Talipes valgus—Traumatic valgus—Other varieties of acquired talipes—Tendon transplantation in the treatment of paralytic talipes—Tendon transplantation and arthrodesis—Tendon splicing—Arthrodesis and other procedures 794

ORTHOPEDIC SURGERY.

CHAPTER I.

TUBERCULOUS DISEASE OF THE SPINE.

Synonym. Pott's disease.

Pott's disease is a chronic destructive ostitis of the bodies of the vertebræ, the anterior or weight-supporting portion of the spinal column. As the disease progresses the spine bends at the weakened point, and the upper part, sinking downward and forward, throws into relief the spinous processes at the seat of the disease; thus an angular posterior projection is formed. It is called Pott's disease because such deformity, slow in formation, accompanied by pain and sometimes by paralysis, was first described accurately by Percival Pott, in 1779. Angular deformity is, however, simply the evidence of destruction of a portion of the anterior part of the vertebral column. Thus it might be the result of fracture, or of the erosion of an aneurism, or of malignant disease, or syphilis, or other pathological process; but deformity from such causes is not now included under Pott's disease, nor is the term now synonymous with deformity. In the modern sense it signifies tuberculous disease of the bodies of the vertebræ, of which the early symptoms may be detected and of which the deforming effects may be checked and even prevented by proper treatment.

The compression and collapse of the affected parts cause the characteristic angular projection at the seat of the disease (Fig. 2). If one vertebral body is destroyed the projection will be sharp; if several are implicated it will be less angular, and if one side of a body breaks down before the other there may be a lateral as well as a posterior distortion.

The size of the deformity and its effect upon the individual depend in great degree upon its situation. If the disease is at either extremity of the spine the angular projection must be small, because so little of the column remains beyond the destructive

process; in other words, the area of the spine directly involved in the deformity is small compared to that which is free from disease (Fig. 5). But if the middle of the spine is affected, the opportunity for deformity is great, because the entire column may enter into the formation of the angular kyphosis. In such cases the internal organs are compressed and the effect upon the vital mechanism is disastrous (Fig. 23).

Pott's disease, as contrasted with tuberculosis of other bones and joints, is peculiar in that it is concealed from view, in that direct surgical intervention is of comparatively little avail, in that it lies in close proximity to important parts, the spinal cord behind and the vital organs in front, and, finally, in that the effects of the disease and deformity are not limited to the parts directly involved, but influence, to a greater or less degree, the entire mechanism of the body.

FIG. 1.

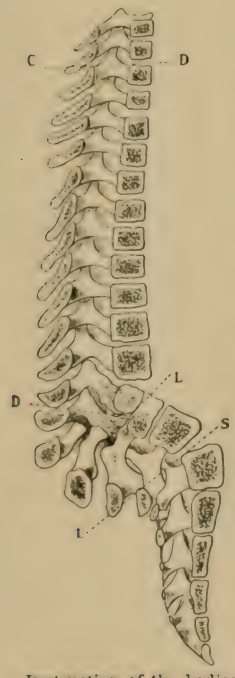

Destruction of the bodies of the first, second and third lumbar vertebræ—with the resulting deformity. (Ménard.)

Pathology. The minute changes that characterize tuberculosis of bone in general are described in Chapter V.

The first indication of the disease is usually found in the anterior part of a vertebral body just beneath the fibroperiosteal layer of the anterior longitudinal ligament. From this point the granulation tissue advances along the front of the spine and, following the course of the bloodvessels, it invades and destroys the adjacent vertebral bodies. In other instances the disease may begin in the interior of a vertebral body, most often in several minute foci near the upper or lower epiphysis. These coalescing, gradually enlarge, forming a cavity, surrounded for a time by unbroken cortical substance, which, becoming weaker, collapses under the pressure of the superincumbent weight. Occasionally the disease advances beneath the anterior ligament without implicating deeply the substance of the bone—a form of tuberculous periostitis, "spondylitis superficialis."

The intervertebral disks appear to offer some resistance to the extension of the disease from one vertebra to another, but when the bone is destroyed on either side they quickly disintegrate and

disappear. The posterior part of the spinal column usually remains free from disease, with the exception of the pedicles and articulations that may be in direct contact with the tuberculous process. In rare instances the disease may begin in a lamina or spinous process, or one of the small joints may be primarily

FIG. 2.

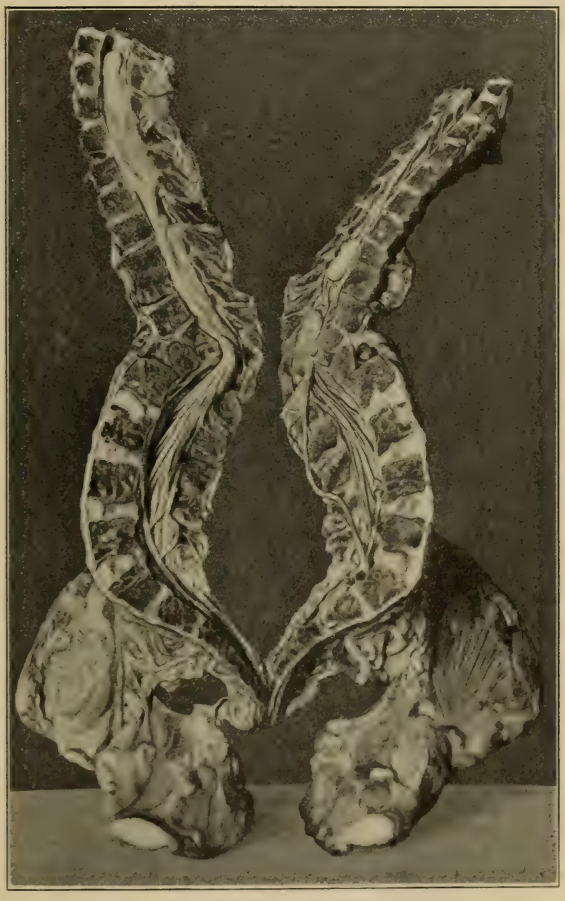

Pott's disease.

involved; but such forms of local tuberculosis would hardly be classed as Pott's disease unless the anterior part of the spine were implicated also.

The course and outcome of the disease depends upon its type. In one instance the area of primary infection is small and the local resistance is sufficient to check its further progress, so that cure

without deformity may follow. In another the disease is inactive and the granulation tissue undergoes a fibroid transformation or becomes ossified. In such cases deformity may appear and slowly increase, practically without symptoms. In most instances, however, the tuberculous granulations advance more rapidly, destroying the bone or other tissue with which they come in contact; the usual retrograde metamorphosis to cheesy degeneration follows, and very frequently liquefaction or abscess formation. This latter complication may be dependent upon secondary infection, but the liability to abscess is very much increased by irritation or injury, and it is decreased by absolute rest of the diseased part.

As a rule, in those cases of moderate severity that come to autopsy during the progressive stage of the disease, one finds, on dividing the thickened tissues in front of the spine, a cavity, the walls of which are lined with tuberculous granulations in various stages of degeneration, and containing puriform fluid. The adjoining vertebral bodies present a worm-eaten appearance, and one or more of them is partially destroyed. Small fragments of necrosed bone and "bone sand" may be present, together with larger masses of degenerated tissue, and occasionally sequestra of considerable size may be found.

In other instances the disease may begin in the posterior part of a vertebral body, or it may extend backward as well as forward, and, forcing its way into the vertebral canal, it may press upon the spinal cord and involve its coverings, and thus cause paralysis of the parts below. Less often pressure on the cord may be due to the presence of an abscess or to a projecting fragment of bone. The calibre of the spinal canal may be constricted somewhat by the pressure of the superincumbent weight upon the softened and thickened tissues at the seat of disease; but, as a rule, its capacity is not directly lessened by the angular distortion, nor does the degree of deformity directly influence the frequency of paralysis.

Although the disease may begin in multiple primary foci of infection over an extended area, or in two or more distinct regions of the spine simultaneously, yet clinical observation seems to show that it is, in most instances, originally confined to one or two adjacent bodies. From this central point the disease may extend in either direction until half the spine may be implicated; but in ordinary cases the final area of deformity and rigidity shows that from three to six bodies are more or less involved before cure is established.

If the disease is limited in extent, the eroded surfaces of the adjoining vertebræ may come into direct contact, but if several vertebral bodies have been destroyed the upper portion of the spine as it sinks downward is often displaced backward so that the anterior aspect of one or more of the upper segments may be

Fig. 3.

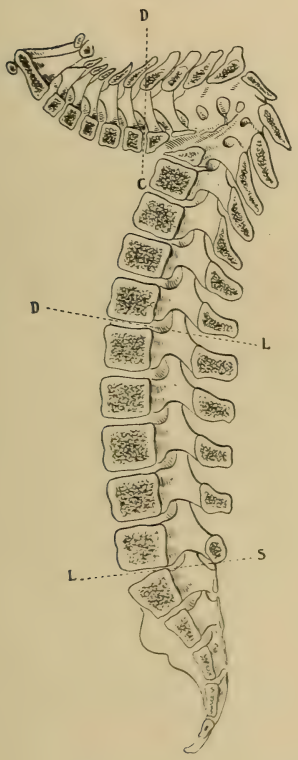

Destruction of the bodies of the third, fourth, fifth, sixth, and seventh dorsal vertebræ; partial destruction of three others. (Ménard.)

Fig. 4.

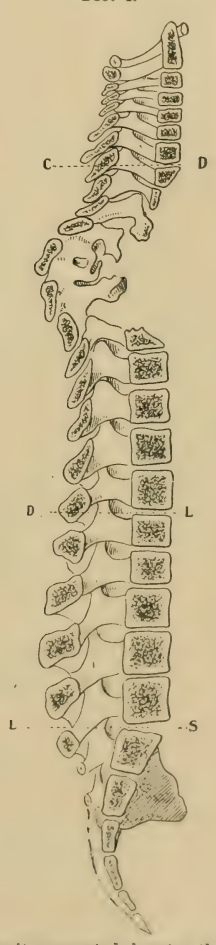

The deformity corrected showing the area of the destructive process (Ménard.)

apposed to the superior surface of the first body of the lower section (Fig. 3). Less often there may be forward displacement of the upper part upon the lower (Fig. 1).

At all stages of the disease resistance to its progress and efforts

at repair are evident in the affected parts. When this resistance overbalances the tendency to degeneration, cure follows.

Repair is accomplished occasionally by contact and solid union of the adjoining surfaces of softened bone; but usually the anchylosis is in part fibrous, in part cartilaginous, and in part bony, and this union may be further strengthened by a callous formation from the thickened tissues about the seat of the disease. In many instances the articular processes, the pedicles and laminæ, become anchylosed before repair has advanced appreciably in the anterior portion of the column.

Cure may be absolute, as when no vestige of the disease remains; it may be practically assured, as when the diseased products undergo calcareous degeneration and are shut in by a layer of solid bone. In other instances the disease becomes quiescent or but slowly advances, showing its presence by exacerbations of pain or by the formation of an abscess, long after active symptoms have ceased.

Etiology. The etiology of tuberculosis of the spine does not differ from that of tuberculosis of other bones; the subject is considered in Chapter V.

Relative Frequency. Tuberculosis of the spinal column is more common than of any other single bone or joint, as might be expected from its greater area. This is illustrated by the statistics of tuberculous disease treated in the out-patient department of the Hospital for Ruptured and Crippled, New York, during a period of fifteen years, 1885–1899:

Tuberculosis of the spine	3207 cases.
" " the hip	2230 "
" " other joints inclusive	2408 "

Also by similar statistics of the Boston Children's Hospital, for a longer period, 1869–1893:

Tuberculosis of the spine	1864 cases.
" " " hip, knee, ankle, shoulder, elbow, and wrist combined	1856 "

Age. Pott's disease, although far more frequent in the middle period of childhood, from the third to the tenth year, may occur at any time from earliest infancy to extreme old age.

In a series of 1259 consecutive cases of tuberculosis of the spine collected from the records of the out-door department of the Hospital for Ruptured and Crippled, New York, analyzed by Drs. R. T. Frank and C. Gunter, the ages of the patients

at the supposed time of onset of the disease appeared to be as follows:

Less than 1 year	38	=	3.1 per cent.
Between 1 and 2 years	176	=	14.2 "
" 3 " 5 "	627	=	50.2 "
" 6 " 10 "	234	=	18.3 "
" 11 " 20 "	89	=	7.2 "
" 21 " 30 "	43	=	3.5 "
" 31 " 50 "	31	=	2.6 "
Over 50 "	11	=	0.8 "

The youngest patient was two months old, the oldest seventy-one years.

Thorndike,[1] of Boston, from the records of the Boston Children's Hospital for thirteen years, 1883 to 1896, collected 115 cases of tuberculosis of the spine in children of two years or less. Seven of these were less than six months, and twenty were under one year in age.

Howard Marsh[2] has called attention to Pott's disease of the aged, and cites three cases in subjects of sixty or more years of age.

Sex. Sex exercises comparatively little influence on the liability to disease of this region. Of 3797 cases collected by Mohr, Gibney, Fischer, Taylor, and Bradford and Lovett, quoted by Hoffa, 2045 were in males and 1752 were in females. Of 1367 cases collected by Frank and Gunter, 708 (52 per cent.) were in males and 659 (48 per cent.) were in females; and in 2455 cases tabulated by Knight, 1329 were in males and 1126 in females. Of these combined cases from the Hospital for Ruptured and Crippled, 3822 in number, 53.2 per cent. were in males and 46.8 per cent. in females.

The Situation of the Disease. The dorsolumbar section of the spine is most often affected. Cervical disease is comparatively infrequent.

In the series of 1355 cases from the records of the Hospital for Ruptured and Crippled, the attempt was made to locate the origin of the disease by the most prominent spinous process in the tracing. The following are the conclusions:

[1] Transactions American Orthopedic Association, 1896, vol. ix.
[2] Ibid., 1891, vol. iv.

	Cervical.	*Dorsal.*	*Lumbar.*	*Lumbosacral.*
First	3	26	94	13
Second	3	43	96	...
Third	15	42	64	...
Fourth	20	46	57	...
Fifth	13	49	6	...
Sixth	22	76	...	...
Seventh	24	82	...	...
Eighth	...	97	...	...
Ninth	...	92	...	...
Tenth	...	110	...	...
Eleventh	...	71	...	...
Twelfth	...	120	...	...
	100	854	317	13

No deformity, cervical	2
" dorsal	31
" lumbar	22
	55
Disease in two regions of the spine	16

Similar statistics are recorded by Julius Dollinger,[1] of Budapest, of 700 cases of Pott's disease. Of these the situation of the primary disease could be ascertained in 538. Of this number, in 63 the disease was of the cervical, in 321 of the dorsal, and in 154 of the lumbar region.

The relative frequency of disease of the different dorsal and lumbar vertebræ was as follows:

	Dorsal.	*Lumbar.*
First	6	59
Second	7	37
Third	12	31
Fourth	10	17
Fifth	19	10
Sixth	17	...
Seventh	33	...
Eighth	36	...
Ninth	36	...
Tenth	43	...
Eleventh	38	...
Twelfth	64	...
	321	154

The proportionate length of the different sections of the spine at the age of five years is, according to Professor Disse (Skeletlehre, 1896):

Cervical	20.2
Dorsal	45.6
Lumbar	34.2
	100.0

If this be contrasted with the percentage of the cases of disease of each section, it will show that the frequency of the disease in

[1] Die Behandlung der Tuberculosen Wirbelentzündung. Stuttgart, 1898.

the different regions of the spine does not correspond to the area, as has been suggested, but that it is proportionately much less frequent in the cervical and much more frequent in the dorsal region.

Dollinger.		*Frank and Gunier.*	
Cervical . . .	11.7 per cent.	Cervical . . .	7.6 per cent.
Dorsal . . .	59.6 "	Dorsal . . .	61.1 "
Lumbar . . .	28.6 "	Lumbar . . .	26.2 "

This may be explained apparently by the greater strain to which the middle and lower part of the spine is subjected, as well as by the relative proportion of cancellous tissue which offers the opportunity for infection.

Prognosis. The prognosis in tuberculous disease is discussed in Chapter V. Pott's disease is the most dangerous of all the tuberculous affections of the bones or joints, as would be expected from the relative importance of the structure affected and of the parts lying in contact with it.

It is evident also that the amount of deformity and its situation have a direct influence on the prognosis. In disease of either extremity of the spine the direct deformity is insignificant and the secondary effect upon the trunk is slight.

In the typical "hump-back" deformity, however, the contents of the thorax and abdomen are necessarily compressed; the blood-vessels are distorted, and the calibre of the aorta, which is more directly affected, is often much diminished; respiration is made difficult, and the circulation is impeded; as a consequence, the heart is usually hypertrophied and valvular insufficiency is not infrequent. Thus the vital functions, which are carried on at a disadvantage even under favorable conditions, become impossible under the added strain of unfavorable surroundings, overwork, or disease. It is a matter of common observation that few of those who are markedly deformed reach old age. On the other hand, it may be assumed that slight deformities, or those which do not as directly interfere with the vital functions, exercise but little influence upon the future well-being of the patient.

Although the absolute mortality of Pott's disease cannot be accurately estimated, it may be stated that at least 20 per cent. of all patients die during the progress of the disease and within a few years after its onset, from causes directly or indirectly dependent upon the local lesion. Some of these die from general dissemination of the tuberculous infection and tuberculous meningitis; some from exhaustion following septic infection and long-continued suppuration, or from amyloid degeneration of the

internal organs; some from tuberculosis of the lungs, and many from intercurrent affections that are fatal because of the devitalizing influence of the disease and its complications.

The prognosis of Pott's disease in the individual case is influenced by many considerations. In one instance the family history is good, the surroundings are favorable, the patient is in good condition, and the disease is in the early stage; one is then inclined to look upon it as an accident, and hardly considers the possibility of a fatal termination; while in another case the weakness and undervitalization of the body are so evident that the affection of the spine seems but an incident of a general degeneration.

Symptoms. The most distinctive sign of Pott's disease is deformity. At an early stage of the process there may be but a slight irregularity in the contour of the spine, and if several adjacent vertebral bodies are affected the projection may be somewhat rounded in outline; but as compared with other deformities of the spine, that of Pott's disease is characteristically angular, and as its cause is loss of substance, its formation is accompanied by and must have been preceded by the symptoms of bone disease.

Deformity is thus the evidence of a destructive process that may have existed for weeks or months even, and only by its early recognition can the ideal result—the prevention of deformity—be attained. The spine which, although weak, is still straight may be held straight; but when the deformity is present, it can be remedied only in part, and it may be difficult even to check its further progress. For as the upper segment of the spine sinks forward and downward, the influences of compression and attrition increase the activity of the local process and aggravate its effects.

For many years angular deformity was thought to be the essential sign of Pott's disease, and even now the fact is not generally recognized that the detection of tuberculous ostitis of the spine in the early stage is both possible and easy, if one will apply the same methods that serve for the diagnosis of other affections not attended by such obvious symptoms as external deformity. It is to such application of the principles of differential diagnosis that attention is especially called.

The spine is the chief support of the body, possessing a free mobility that accommodates it to every movement of the trunk and to every motion of the limbs even. It is evident, therefore, that the symptoms of a destructive disease must be pain, weakness, and impairment of normal motion. Motion and support are not, however, the only functions of the spine; it contains the spinal

cord, from which branch the nerves that supply the organs and members of the body. This may be implicated at an early stage of the affection and the sudden onset of paralysis may overshadow the symptoms of the original disease. In other instances the tumor of an abscess—one of the common accompaniments of tuberculous disease of bone—may interfere with the functions of important parts lying in the neighborhood of the spine, and peculiar symptoms, due to this cause, may attract attention before the primary disease is suspected. Such symptoms may be misleading and it is well, therefore, to consider them apart from those that indicate the primary effect of the disease upon the spine, considered as an elastic support. These direct symptoms usually precede and always accompany the secondary or complicating symptoms, and upon them the diagnosis depends.

The primary and diagnostic symptoms of Pott's disease may be classified as follows:

(*a*) Pain.
(*b*) Stiffness.
(*c*) Weakness.
(*d*) Awkwardness.
(*e*) Deformity.

(*a*) **Pain.** At first thought, one might expect the pain of Pott's disease to be localized at the affected vertebræ, and to be accompanied by sensitiveness to pressure or even by infiltration and swelling of the tissues; but it will be remembered that the bodies of the vertebræ are in the interior of the trunk, practically speaking, as near to its anterior as to its posterior surface (Fig. 9), and that the products of the disease pass downward and forward, rarely backward. Thus sensitiveness to pressure on the projecting spinous processes is unusual, and palpation, except in the cervical region, is of comparatively little diagnostic value.

The pain of Pott's disease is not localized in the back, in the neighborhood of the disease, because the filaments that supply the bodies of the vertebræ are insignificant parts of nerves that are distributed to distant points—to the head, to the limbs, to the front and sides of the trunk—and to these parts the pain is referred; thus "earache" or "stomach-ache" or "sciatica" may be symptomatic of Pott's disease. The pain of Pott's disease is by no means constant; it is induced by jars or by sudden or unguarded movements. It is often worse at night, when, after the relaxation of the muscular spasm that has protected the part, the unconscious movements during sleep cause discomfort or pain,

and the child moans in its sleep, or is restless, and sometimes it wakes with a cry—"night cry."

(*b*) **Impairment of Function or Loss of Normal Mobility: Stiffness.** Stiffness of the spine is in part voluntary, in the sense that the patient adapts his movements and attitudes to the disease and pain—in order to avoid as far as possible strain and jar—but the essential and characteristic stiffness of Pott's disease is caused by the involuntary muscular tension and contraction of the muscles about the seat of disease. This reflex muscular spasm varies in degree, according to the state of the underlying disease. It may fix the spine or it may be evident only at the extremes of motion, but it is always present, preceding deformity and accompanying it until cure is established; thus it is the most important of the diagnostic symptoms of Pott's disease.

FIG. 5.

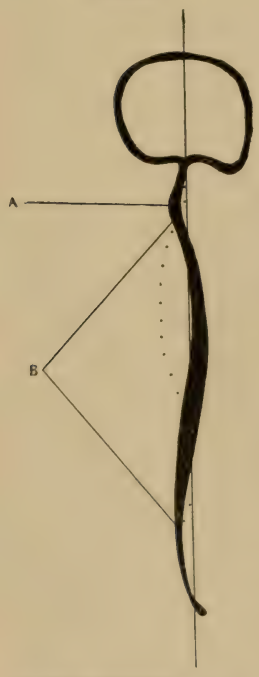

A, direct deformity; *B*, compensatory deformity. The dotted line indicates the normal contour of the spine.

(*c*) **Weakness.** As the disease affects the most important support of the body, it is a direct as well as an indirect cause of weakness, and the more vulnerable the spine, the more pronounced is this symptom; thus in a young child, whose spine is in great part cartilaginous, evidence of weakness is shown by the "loss of walk," the refusal to stand, and by the instinctive desire for support, at an early stage of the disease.

(*d*) **Change in Attitude: "Awkwardness."** This really sums up the effects of the preceding symptoms, since it is evident that pain, weakness, and rigidity must cause a change in the appearance and in the habitual attitudes of the patient. Such symptomatic attitudes may be almost diagnostic of the disease and of the part of the spine involved.

(*e*) **Change in the Contour of the Spine: Deformity.** The deformities of Pott's disease may be classified as follows:

1. Bone deformity.
2. Muscular deformity.
3. Compensatory deformity.

The characteristic angular projection due to destruction of bone has been described already.

Muscular deformity is the distortion due to muscular spasm or contraction. Of this, the wry neck, symptomatic of cervical disease, and psoas contraction in the lower region of the spine, are the most familiar examples.

Compensatory deformity signifies the more general effect of the local disease and local distortion upon the spine as a whole (Fig. 5). Thus an angular projection must be balanced by a compensatory incurvation, and lateral distortion in one direction by lateral distortion in another.

These three deformities are, of course, nearly related, and they are usually combined, although muscular distortion may precede

FIG. 6.

Normal contour and flexibility of the spine.

the stage of bone destruction, while the compensatory changes are not immediately apparent. On the other hand, the secondary changes in the contour of the spine may catch the eye before the primary local deformity is detected.

Lateral deviation of the spine is not infrequent; it may be a direct distortion at the seat of the disease, caused by the destruction of the side of a vertebral body (Fig. 22), but more often it is a secondary effect of such irregular erosion at one or the other extremity of the spine, or the effect of muscular contraction, or it may be due to simple weakness, in which case it is a transient symptom.

Finally, even at the earliest stage of the disease, there is almost always a slight change in the outline of the spine due to local

rigidity; the spine no longer forms a long, regular curve when the body is bent forward, but as one section remains more or less rigid while the other bends, the outline is broken at or near the seat of the disease (Fig. 7).

Secondary or Complicating Symptoms. (*a*) **Abscess.** This may, by its size or situation, cause peculiar symptoms. In the retropharyngeal space it may interfere with respiration and deglutition. In the thoracic region it might be mistaken for

FIG. 7.

Incipient Pott's disease. Showing the break in the contour of the spine, of which the normal flexibility is but slightly impaired.

pleurisy or empyema, and when it forms a tumor in the iliac fossa it may interfere with locomotion.

(*b*) **Paralysis.** This is usually a late symptom, but if the disease begins in the centre or posterior part of a vertebral body it may implicate the spinal cord before deformity is apparent.

Abscess and paralysis are symptoms that may be explained by Pott's disease, but other than by calling attention to disease of the spine as a possible cause of the complication, they do not aid one

in determining the diagnosis; for this reason they are classed as secondary symptoms.

General Symptoms. Especial stress is laid by certain writers upon the diagnostic value of a slight but constant elevation of the temperature. This is usually present if the disease is active or when an abscess is approaching the surface, but the positive value of the symptom in early or quiescent cases is doubtful. One may expect also that a patient suffering from tuberculous disease of the spine will present some evidence of a painful and depressing affection, or some evidence of inherited or acquired weakness; yet it must be remembered that the absence of such general symptoms would not exclude Pott's disease.

The Contour and Flexibility of the Normal Spine. In the enumeration of the early symptoms of Pott's disease, two have been noted as of especial importance—the impairment of normal mobility and the effect of the disease upon the contour of the spine and upon the attitudes of the patient. Therefore, in the study of the normal spine the standard with which that suspected of disease must be compared—mobility and contour—at different ages and under different conditions should receive especial consideration.

The spine as a whole is a flexible column, yet it has a fixed contour; it curves forward in the upper, backward in the middle, and forward again in the lower region. These curves are essentially the effect of the force of gravity and of the action of the muscles in balancing the weight of the body in the upright attitude. In the adult they are practically constant; in early childhood they can be nearly obliterated by traction in the horizontal position; and in infancy they do not exist. If the newborn infant be placed in the sitting posture, the head falls forward and the spine bends in one long, backward curve, characteristic of weakness. If it be placed on the back and the legs be drawn down from their habitual attitude of semiflexion, it will be noticed that the range of extension is somewhat limited because of the absence of the lumbar curve and the inclination of the pelvis. When the gain in muscular power is sufficient to enable the infant to raise and control the head, the curve of the neck appears. Later when the child stands, the erector spinæ muscles hold the body upright against the resistance of the iliopsoas group and of the ligaments of the hip-joint; thus the lumbar curve and the inclination of the pelvis result and the normal contour of the spine is established.

If from the odontoid process of the axis of a normal individual

in the erect posture a line be dropped to the ground, this perpendicular or weight line, about which the weight of the body is balanced, will indicate the curve of the spine, and divide it into sections that correspond sufficiently well to function. The cervical curve ends at the second dorsal, the thoracic curve at the twelfth dorsal, and the lumbar curve at the sacrovertebral angle (Fig. 8).

Fig. 8.

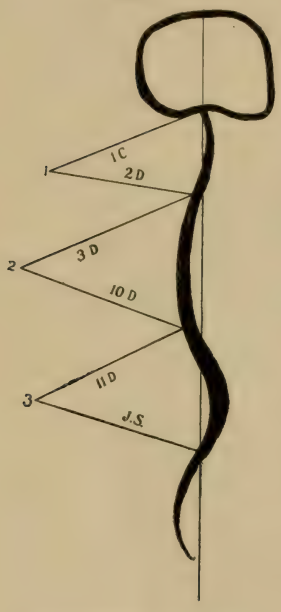

The divisions of the spine.

What has been spoken of as the normal contour of the spine varies considerably in the adult. It is affected by the occupation and many other circumstances; of this, the round shoulders of the cobbler or the weaver, the stoop of weakness, of old age and the like, are familiar examples; but in childhood distinct variations from the normal contour almost always have a clearly defined pathological cause. As the normal contour is the effect of the balancing of the body in the upright posture, it is evident that if the outline of one part is permanently changed, compensation for this change must be made in another part. Thus when deformity is well marked, the normal curves of the spine are often completely reversed (Fig. 5), and even at an early stage of the disease the abnormal contour will often attract attention, long before the characteristic angular projection has become apparent.

Divisions of the Spine.

Although the spine is a flexible column whose outline changes with every movement and posture, yet the range and character of this motion vary greatly in different parts. In the cervical and lumbar regions motion is extensive, because of the relatively large proportion of elastic intervertebral substance, because of the direction of the articular surfaces, and because the centre of motion is near the middle of the body. Motion is very limited in the thoracic region, because the intervertebral disks are thin, because of the overlapping spinous processes, and because it forms a part of the rigid thorax. Where free motion is essential to the habitual attitudes, interference with normal

motion and the other attendant symptoms of disease will be apparent earliest. Thus one more often has the opportunity for

FIG. 9.

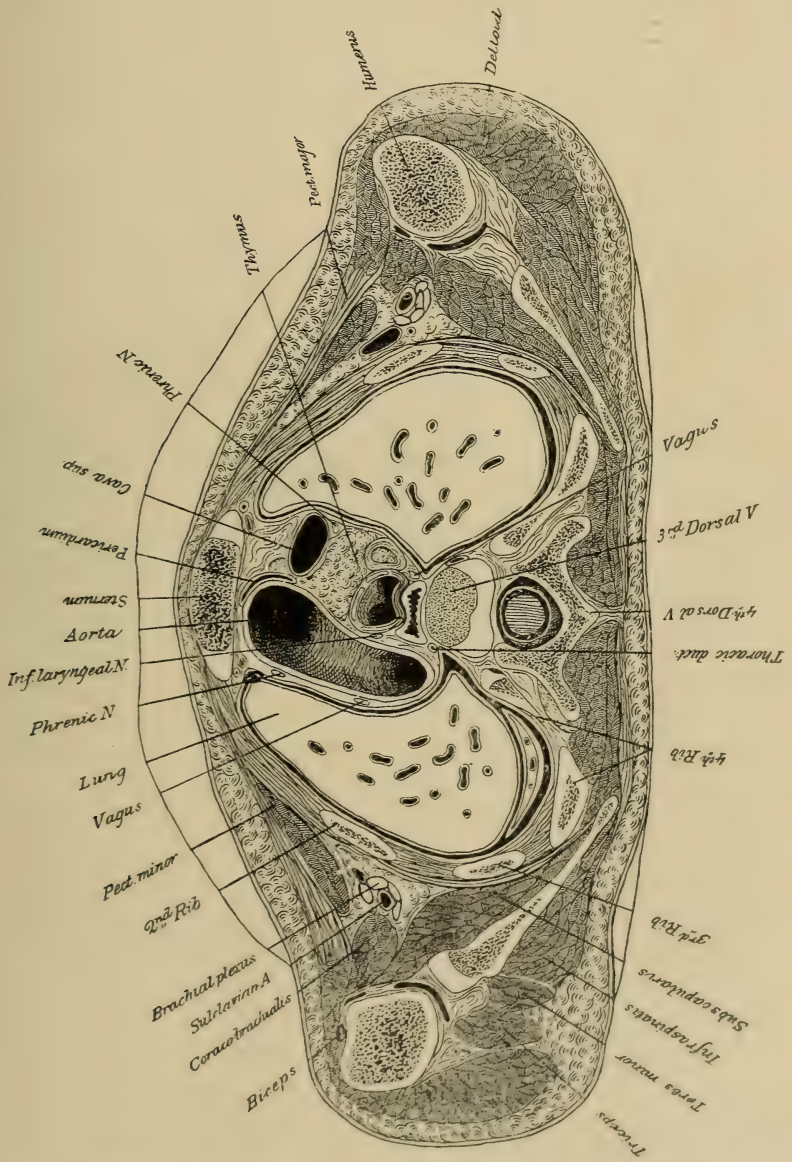

Cross-section of the body of a child at the third dorsal vertebra. (Dwight.)

early diagnosis in disease of the lumbar and cervical regions, because in the one the motions necessary in stooping, sitting, and

standing are constrained, and in the other the neck is stiff, or the head is turned, or drawn from the normal line. In the thoracic region early diagnosis is less often made, because in this section motion is so unimportant that its restraint may escape the attention of the patient or parent. In considering diagnosis, therefore, and, in fact, treatment and prognosis, one should divide the spine into three sections to correspond with function :

1. The neck part, that allows free motion of the head, ending at the third dorsal vertebra.

2. The rigid thoracic part, which includes the third and the tenth dorsal vertebræ.

3. The lower part, made up of the two lower dorsal and the lumbar vertebræ, in which the principal movements of the trunk are carried out (Fig. 8).

One must bear in mind the distribution of the nerves, because the characteristic pain is referred to their terminations, also the parts in relation to the spine at different levels that may be implicated in the disease. Thus, remembering that the symptoms of Pott's disease are in general, stiffness, weakness, pain and deformity, one will always apply these symptoms to a particular region of the spine, and will picture to himself the effect of such stiffness, weakness, and deformity at this or that vertebra; the effect of an abscess in this or that situation, and the area of paralysis that might be caused by pressure on the cord at one or another level.

Landmarks. The atlas is on a line with the hard palate.

The axis is on a line with the free edge of the upper teeth.

The transverse process of the atlas is just below and in front of the tip of the mastoid process.

The hyoid bone is opposite the fourth cervical vertebra.

The cricoid cartilage is on a line with the sixth cervical vertebra.

The upper margin of the sternum is opposite the disk between the second and third dorsal vertebræ.

The junction of the first and second sections of the sternum is opposite the fourth dorsal vertebra.

The tip of the ensiform cartilage is opposite the lower part of the body of the tenth dorsal vertebra.

The anterior extremity of the first rib is on a line with the fourth rib at the spine, the second with the sixth, the fifth with the ninth, the seventh with the eleventh.

The scapula overlaps the second and the seventh ribs, its lower angle being opposite the centre of the eighth dorsal vertebra.

The root of the spine of the scapula, the glenoid cavity, and the interval between the second and third dorsal spines are in the same plane.

The most constant landmark from which to count is the spinous process of the fourth lumbar vertebra, which is on a line with the highest point of the crest of the ilium. The umbilicus is near the same plane.

The Inclination of the Pelvis. In the erect attitude the plane of the brim forms an angle of 60° to 65° with the horizon.

The tip of the coccyx is opposite the lower border of the symphysis pubis.

Length of the Spinal Cord. In the adult the spinal cord terminates at the lower margin of the first lumbar vertebra. At birth it extends to the third lumbar vertebra and its membranes to the second division of the sacrum.

The Intervertebral Disks. In the adult the intervertebral disks form 41.9 per cent. of the cervical, 26.4 per cent. of the dorsal, and 44.6 per cent. of the lumbar regions of the spine (Dwight).

The character of the disease, its manifestations, and its effects upon the spine having been outlined, the student is now brought, as it were, into actual contact with the patient and his friends. And as Pott's disease is the most important of the chronic affections of childhood, it will serve as a type to illustrate methods of examination and of treatment as applied in orthopedic practice.

The Rational Signs. The symptoms of Pott's disease vary decidedly, not only with the region of the spine involved, but also with the age and surroundings of the patient. Like other forms of tuberculous disease it is an insidious chronic affection, and its early symptoms may fail to attract attention, because they are irregular or intermittent. The child may cry after overexertion or injury, but otherwise it may appear to be perfectly well for weeks or months even. When the diagnosis is evident, however, the mother almost always recalls the fact that something was "wrong," that it was fretful and disinclined to play, that it liked to lie on the floor, that it was awkward in its movements, that it was troubled by a cough or indigestion, or by oppression of breathing. One, or many, of such symptoms may have existed for months; but, as a rule, it is not until deformity appears that the child is brought for treatment. It is often after a fall or violent play that the evidence of pain or weakness can no longer be overlooked, so that injury is likely to occupy a prominent place in the history.

History. The history of the disease as obtained from the parent is usually indefinite and misleading. Certain points, however, of relative importance may be ascertained by an examination somewhat as follows:

One asks if the immediate relatives of the child have suffered from phthisis or other form of tuberculosis, as this might indicate a predisposition to disease, and thus affect the prognosis.

One asks if the child has been robust or the reverse, and if recovery from the ordinary ailments of childhood was prompt or tedious, in order that one may judge of the quality of the patient.

One next asks, not "how long has the child been ill?" for this is usually understood to refer to the duration of the more decided symptoms; but "when was the child last perfectly well?" One asks particularly as to the onset of the first symptoms, whether it was sharp and decided, or gradual and ill-defined; if the symptoms were preceded by contagious disease. This latter is an important question, because measles, for example, predisposes to tuberculous infection, or at least to its local outbreak, and diphtheria is often followed by paralysis or by weakness that may simulate certain symptoms of Pott's disease. The character of the injury that almost every patient is supposed to have received is then investigated. It should be made clear whether the injury was the direct cause of the symptoms, or if it may have simply aggravated or brought to light the dormant disease, or if, as is often the case, there is simply an indefinite remembrance of an injury which has no connection with the symptoms.

To establish injury as the sole and direct cause of symptoms, the patient must have been well at the time of the accident, the symptoms must have followed immediately and must have persisted since; and, finally, the symptoms must be of a nature to be explained by a definite injury.

By careful questioning one may usually determine whether the symptoms of which the patient complains are acute or chronic. This is of importance, because tuberculosis is a chronic disease—one of the few chronic diseases of childhood—although its exacerbations may resemble the symptoms of acute disease or even injury.

However important a correct history may be, it is upon the physical examination that the diagnosis practically depends.

Physical Signs. The physical examination begins on the first sight of the patient, for one may note then the general condition and the actions and postures; but the ultimate purpose of the

examiner is to compare the appearance and the mobility of the spine suspected of disease with the normal standard.

Voluntary actions and attitudes are important, because they show the adaptation of the body to the disease, the conscious and unconscious efforts of the patient to guard the weak part from strain and from motions that cause discomfort and pain. Inspection, palpation, and the tests of voluntary and passive motion are of still greater importance, because by such means one may demonstrate the presence of disease and localize it with accuracy.

The examination must be purposeful. When one asks the patient to pick up a coin from the floor, it is to test the lower region of the spine for the symptoms of weakness and stiffness. The ability to perform the act with ease by no means excludes disease of the spine in the regions not especially involved in the movements of stooping or turning the body, although this would appear to be the general belief.

Such tests must not only be purposeful, but they must be adapted to the age and intelligence of the patient. The child that refuses to pick up a coin will often gather up its clothing, because it wishes to be dressed again. If it will not stoop, it will rise usually if placed in the recumbent or sitting posture—an equally useful test. A child will walk toward its mother if placed at a distance from her. It will always turn its head toward her; thus voluntary motion of the cervical region may be tested by changing the mother's position, while the child is held by the examiner. Young children that struggle and resist passive motion if placed on the table, submit quietly when held in the mother's arms.

Various simple and effective tests will suggest themselves to the examiner who has a definite purpose in view, but much patience may be required in early cases, and several examinations may be necessary before the presence or absence of disease can be definitely determined. It is important to remember that, in childhood at least, abnormal symptoms always have a cause; therefore, a patient should be kept under observation until the cause is discovered.

Of all the early signs of Pott's disease muscular rigidity or reflex muscular spasm is the most important, since it precedes deformity and accompanies it until cure is finally established. It is a spasm that resists motion in all directions; thus it may be distinguished from the spasm or contraction of certain groups of muscles caused by irritation or inflammation not connected with the spine. For in such instances motion is limited only in the directions directly opposed by the muscular contraction. True reflex muscular spasm

is quite independent of the will, and thus it may be distinguished from simple voluntary resistance on the part of the patient.

The muscular rigidity is most marked in the neighborhood of the disease, but it extends to a greater or less distance according to the acuteness of the local process and the susceptibility of the patient.

Even at an early stage the situation of the disease is usually shown by a slight irregularity of the spine in the centre of the area made rigid by muscular spasm, as well as by the change of contour. This change in outline and in flexibility may be demonstrated by bending the patient forward. If the spine forms a long, even, regular curve, and if there is no evidence of pain or rigidity when such an attitude is assumed, Pott's disease is extremely improbable. If, on the other hand, the outline of the curve is broken; if the motion of one section of the spine is restrained by muscular rigidity, disease may be suspected; and if other evidence of tuberculous ostitis is present, the diagnosis may be made with certainty (Figs. 6 and 7).

By a careful physical examination one may expect to detect Pott's disease at its inception and to fix upon its location, or at least upon the point suspected of disease. One will then ask one's self if tuberculous disease of the bodies of the vertebræ of this particular region will satisfactorily explain all the symptoms of which the patient complains; if, for example, the pain corresponds to the distribution of the nerves; if restraint of function will explain the attitudes of the patient, and if the change in contour is significant of a destructive process.

As has been stated, the symptoms and the effects of the disease differ according to the function of the part of the spine involved; the further examination should be conducted, therefore, from this standpoint.

The Regional Examination.

1. **The Lower Region.** Considering the regions of the spine in the order of liability to disease, one begins with the lower section, comprising the lumbar and the two lower dorsal vertebræ, that more nearly correspond in shape and function to the lumbar than to the thoracic division.

This is the region of constant and extensive motion; thus the painful rigidity, characteristic of the disease, is often marked long before the stage of bone destruction.

The characteristic attitude of the patient is one of what might be called overerectness, and in many instances there is an in-

creased *hollowness* (lordosis) of the back (Figs. 10 and 12); thus the prominent abdomen may first attract attention. The *walk* is careful, and a peculiar tip-toeing step, the feet being slightly inverted to avoid the jar of striking the heels, is often observed; this is, however, not a peculiarity of disease of this region alone, but is rather an evidence that the spine is sensitive to slight jars. More characteristic of lumbar disease is a peculiar swagger or

FIG. 10.

Disease of the upper lumbar region before the stage of deformity, showing abnormal lordosis.

FIG. 11.

The same patient (Fig. 10) five years later, showing deformity.

waddle, explained in part by the exaggerated lordosis, and in part by the loss of the accommodative, balancing motion of the lumbar spine, as the weight falls alternately on each limb in walking.

The increased lumbar lordosis, so characteristic of the early stage of the disease, is capable of several explanations. It is partly voluntary; as bending the body forward brings pressure

upon the diseased vertebral body, so bending it backward relieves this pressure. It is partly involuntary, caused by the contraction of the large muscular masses on the posterior aspect of the spine; and it is in part compensatory, as the slight psoas contraction which is often present has a tendency to tilt the pelvis forward, necessitating a greater compensatory backward inclination of the body.

As the disease progresses the lumbar section becomes straighter, and finally it may project backward in the characteristic angular deformity. Yet even after the lordosis has been obliterated the backward inclination of the body still continues as a compensation for the change in balance, which the transformation of the forward curve to a posterior deformity has necessitated (Fig. 11). Thus overerectness or backward inclination of the body characterizes the disease of this region from its beginning to its end in uncomplicated cases.

Slight psoas contraction as a part of the general muscular spasm about the diseased area simply increases the lordosis; but if the contraction is greater, when for example an abscess is present which involves the substance of the psoas muscles or forms a painful tumor in the pelvis, the erect attitude is no longer possible. The thighs are drawn toward the body, and the body is inclined forward to relax the tension. As this greater contraction, with the abscess that is usually its cause, is commonly unilateral the patient "favors" the flexed limb, and the resulting limp is often mistaken for a sign of hip disease. Unilateral psoas contraction is, in fact, so often present when the patient is first brought for treatment, that a limp and the accompanying inclination of the body may be considered as characteristic of disease of the lumbar region at a somewhat advanced stage (Fig. 13).

The *location of the pain* depends upon the distribution of the nerves that supply the diseased vertebræ or that pass in their vicinity; it may radiate over the inguinal region or backward to the loins or buttocks or down the front or back of the thighs to the knees. *Painful "cramp"* is sometimes a prominent symptom; the limb is spasmodically drawn toward the body and the patient, seizing it with both hands, shrieks with pain.

Lateral inclination of the body is often present. It is usually a symptom of unilateral psoas contraction and abscess; it may be due also to unilateral contraction of the muscles of the back, or at a later stage it may indicate collapse or destruction of one side of a vertebral body. In other instances it is not a fixed attitude,

but is simply a voluntary adaptation to weakness or pain; thus one may find a large abscess in one pelvic fossa unaccompanied by psoas contraction, while the body is inclined toward the opposite side, apparently because the weight is supported habitually on this limb.

FIG. 12.

Disease of the lumbar region. First symptom, pain in the knees.

FIG. 13.

Disease of lumbar region with right iliopsoas abscess and psoas contraction.

The stiffness, weakness, and pain, characteristic of disease in this region are exemplified in many ways; for example, the child may be unable to turn in bed; it is slow and awkward in rising in the morning or in changing from an attitude of rest to one of activity. It often prefers to stand rather than to sit, because in the latter position more weight is thrown upon the sensitive

vertebral bodies. When seated, particularly when riding in a carriage or street car, the patient often sits upon the edge of the seat, the shoulders only touching the back, while the hands rest instinctively on the seat, partially supporting the weight and steadying the spine.

Stooping, a posture that increases the pressure on the diseased vertebral bodies and which necessitates muscular tension and strain in regaining the erect position, is particularly difficult and it is always avoided by the patient if the disease is at all acute. For example, when the child is asked to pick up an object from the floor, it either refuses or it squats on the heels or drops upon the knees (Fig. 14) instead of flexing the spine as in health. Young children, having seized the object on the floor, regain the erect attitude by pushing the body up by the pressure of the hands on the thighs. If the child is placed upon the floor it will, if possible, seize the mother's dress or will crawl to a chair or other object upon which the body may be drawn up by the arms, so that the discomfort caused by muscular contraction of the back muscles may be avoided.

FIG. 14.

Lumbar disease. The manner of picking up an object.

After the inspection and the observation of the motions and attitudes of the patient, the examination of the range of passive motion is made. The patient is placed at full length face downward on a table, and the range of extension and of lateral motion is tested by lifting the legs and swaying the body gently from side to side (Fig. 15). The spine is so flexible in childhood that rigidity even in the upper dorsal region may be demonstrated by this method, and in testing the lumbar region the thorax should be fixed by the hand of the examiner. While the patient remains in this attitude, one should test for psoas contraction. The pelvis is pressed firmly against the table with one hand, while the leg, held in the line of the body, is gently lifted by the other

(Fig. 16). As tested in this manner, the normal range of hyper-extension at the hip-joint should allow the knee to be lifted two or three inches from the table. Slight restriction of extension

FIG. 15.



Showing the rigidity of the spine before appearance of deformity.

FIG. 16.

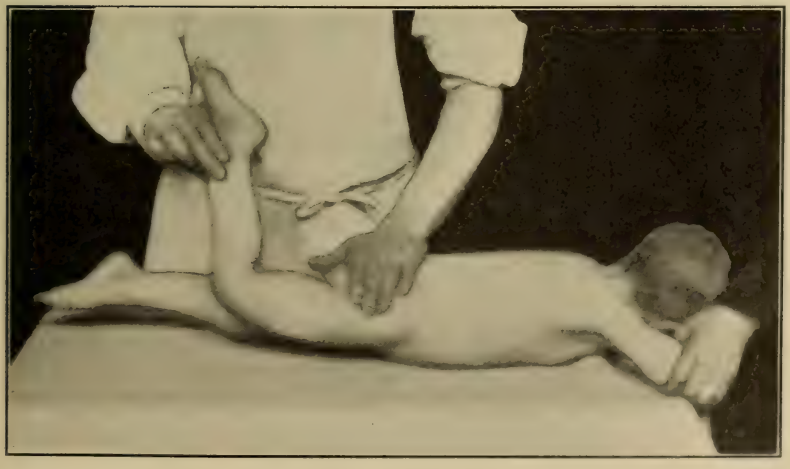

Test for psoas contraction.

of both thighs, indicating a slight degree of psoas contraction, is very common in lumbar Pott's disease; but when the restriction is marked, and especially if it be unilateral, a deep abscess

may be suspected. Such unilateral psoas contraction may be demonstrated by placing the child on the back, allowing the limbs to hang over the edge of the table, when the unaffected thigh will drop below its fellow (Fig. 17).

As a rule, flexion of the lumbar spine is much more restricted in the early stage of the disease than is extension; this rigidity may be demonstrated by placing the child on its hands and knees, and lifting it from the floor, when the body, instead of bending over the supporting hands, retains almost its original contour (Fig. 18).

As has been stated, even at an early stage of the disease one may detect often a slight fulness about the spinous processes or

FIG. 17.

A method of demonstrating psoas contraction.

a slight irregularity in their line, about which the muscular spasm is most marked; this indicates the exact seat of the disease. Deep pressure on the spinous processes at this point will often cause pain, and sometimes greater elasticity at the diseased area may be demonstrated. Except in the hands of an expert, it is, however, a test of comparatively little value; and again it may be mentioned that local pain and local sensitiveness to pressure on the spinous processes are not characteristic signs of Pott's disease.

Finally, one should examine for *pelvic abscess*. This may be suspected when unilateral psoas contraction is present in marked degree, although psoas contraction may be present without abscess

and abscess may be unaccompanied by psoas contraction when the substance of the muscle is not involved.

The typical psoas abscess, as pictured and described, is the fluctuating tumor that suddenly appears on the inner side of the thigh, although it may have been many months in descending to this position from its original site. Demonstrable abscess is present at some time in at least 50 per cent. of the cases of lumbar disease, and its detection is a matter of importance, since its sub-

FIG. 18.

Disease of the lumbar region before the stage of deformity. A test for rigidity

sequent behavior will often materially influence the treatment. The child is placed on the side, the thigh is flexed, and the hand is pressed gently down into the loin and iliac fossa. Sometimes the examination will be made easier by extending the limb and thus bending the spine forward toward the hand. Often in this manner one can make out the peculiar, sausage-like thickening on one or the other side of the spine, or a larger, rounded tumor in the iliac fossa, the presence of which would not otherwise have been suspected.

Diagnosis. If a careful physical examination were made in all suspicious cases, by one at all familiar with the ordinary symptoms of Pott's disease, the field for differential diagnosis would be small indeed; but it would appear that such examinations are not made usually by the physician who is first consulted. One may learn, for example, that the child has been circumcised because of pain about the genitals, or because of weakness of the limbs, supposed to be due to "reflex irritation;" or if the patient is an adult, that he has been treated for sciatica, rheumatism, or strain, long after the evidence of Pott's disease, even in the angular kyphosis, would have been apparent had the back been inspected.

Pott's disease is most often mistaken for some one of the following affections:

Lumbago. This may simulate some of the symptoms of Pott's disease of this region, but it is an acute affection, of sudden onset, usually accompanied by local pain and sensitiveness of the muscles themselves.

Strain of the Back. This is often accompanied by stiffness and pain on motion, but, like lumbago, its onset is sudden and its cause is known. The pain is usually localized at the point of injury; it is relieved by rest, and the restriction of motion is, in great degree, voluntary. In Pott's disease the pain is neuralgic; it is often worse at night and the rigidity is due to reflex spasm.

Sciatica. The pain of sciatica is most often unilateral; it is usually confined to the distribution of this nerve, which is often sensitive to pressure throughout its course. The pain of Pott's disease, if it is referred to the limbs, is usually bilateral and the nerve trunks are not often sensitive to pressure. In sciatica, movements of the leg that cause tension on the nerve are often painful, while motion of the spine is free, or but slightly restricted, the reverse of the symptoms of Pott's disease. It is true that lateral deviation and even rigidity of the lumbar spine are sometimes observed in cases of lumbosciatic neuralgia of long standing, but if the latter symptom is marked the diagnosis may be regarded as open to question.

Sacro-iliac disease is far more likely to be mistaken for disease of the hip-joint than of the spine; the pain and sensitiveness are usually localized about the seat of disease and the movements of the spine are not restricted.

Lumbago and sciatica and sacro-iliac disease are extremely uncommon in childhood, and if supposed strains or injuries of the

back cause persistent symptoms, the appropriate treatment would be similar to that of Pott's disease; that is to say, fixation and rest of the suspected part, until the cause of the symptoms is made clear.

The attitude, characteristic of Pott's disease of this region, the hollow back and prominent abdomen, combined with the waddling

FIG. 19.



Disease of the lower dorsal region. The earliest indication of deformity.

gait, may be simulated by *bilateral congenital dislocation of the hip*, in which the pelvis is suspended at a point behind its normal position; but in this instance the gait and attitude have existed since the child began to walk, and the symptoms of bone disease are absent. A similar attitude is sometimes the result of weakness or paralysis of the muscles of the back, as, for example, in *progressive*

muscular atrophy or *pseudohypertrophic muscular paralysis.* In this latter affection there is also a disinclination to stoop, and there may be rigidity of the back, symptoms that bear a superficial resemblance to Pott's disease; but as there are no other signs of disease of the spine, it may be readily excluded.

When psoas contraction is present in lumbar Pott's disease, the resulting limp, that is often accompanied by pain in the limb, is almost invariably mistaken for a symptom of *hip disease.*

Although flexion of the leg caused by psoas contraction is a common accompaniment of Pott's disease, it is not usually an early symptom; thus the history will probably call attention to symptoms referable to the spine, that have preceded it. Again, the limp of Pott's disease is caused simply by flexion of the limb, a limp that is not, as in joint disease, accompanied by pain on functional use. When, therefore, in the physical examination the tension of the contracted iliopsoas muscle is relieved by flexing the thigh still further, the other movements of the hip, abduction, adduction, rotation, and flexion, are free and painless. Thus, hip disease, in which all motions are restrained in equal degree by muscular spasm, may be excluded readily, except, perhaps, in infancy.

Hip Disease in Infancy. At this susceptible age there is almost always sympathetic spasm of the lumbar muscles in acute affections of the hip, and similar spasm of the hip muscles may be present in Pott's disease of the lower part of the spine. Several examinations may be necessary before the exact location of the disease can be determined, and in doubtful cases the application of a temporary support to the back and thigh, such as a spica-plaster bandage to relieve the sympathetic spasm, is a useful aid in diagnosis.

It has been stated that extension of the thigh only is restrained by psoas contraction. It will be evident, however, that the presence of a large and painful abscess in the pelvis or thigh would limit motion in other directions as well; but even in such cases at least one movement is unrestrained; thus disease within the joint may be excluded.

Secondary Hip Disease. In Pott's disease of long standing, complicated by abscess, in which the tissues about the joint are infiltrated or traversed by discharging sinuses, secondary infection of the hip-joint is not an unusual complication. In such cases, when the limb is distorted and when motion at the hip is limited by the infiltrated and contracted tissues, it is not easy to determine the presence or absence of joint disease. Doubtful cases of this class should be treated symptomatically.

Pelvic Abscess. As abscess is such a common complication of Pott's disease, it will be necessary to consider abscesses of other origin, that may cause occasionally symptoms resembling somewhat those of disease of the spine. Such are the *perinephritic abscess*, and, more rarely, that of *appendicitis*. They differ from the abscesses of Pott's disease in that they are, as a rule, acute in their onset and are accompanied by constitutional symptoms and by local pain and tenderness. In such cases the motions of the spine may be restrained, but the restraint is in great degree voluntary, quite different from the rigidity due to disease of its substance. It is true that the pelvic abscess of Pott's disease which has become infected may cause constitutional symptoms, but the history of the disability and discomfort that must have preceded the abscess, together with the probable presence of deformity, will make the diagnosis clear. Chronic abscess in the pelvis of other than spinal origin may be the result of disease of the pelvic bones, or of the sacro-iliac articulations, or of the hip-joint. It may be caused by the breaking down of lymphatic glands, or it may have its origin in inflammation about the uterine appendages, and cases of so-called idiopathic inflammation and suppuration of the iliopsoas muscle have been described. In childhood, chronic abscesses in this locality are almost always tuberculous in character, and are caused by disease of bone, either of the spine or of the pelvis. Disease of the spine can be determined usually by the methods already indicated, but if the abscess is of other origin its exact cause can be decided in many instances only by an operative exploration. Abscesses of this character, of slow and apparently painless formation, may finally cause a swelling in the inguinal region or about the saphenous opening, that in the adult is not infrequently mistaken for *hernia*. In practically all cases, however, the tumor of the abscess may be made out on palpation within the pelvis, and, although the contents of the external sac may be in part forced back into the larger reservoir, its reduction is very different in feeling from that of a true hernia.

Peculiarities of Lumbar Pott's Disease in Infancy.

Attention has been called repeatedly to the great importance of careful observation of the postures and movements of the patient, to the change in the contour of the spine, and particularly to the abnormal lordosis and peculiar attitude of overerectness in the early stage of lumbar disease. But the description of attitudes of

standing and walking, and of the contour of the spine, which is the result of the erect posture, does not apply to the infant in arms, nor need the spine be divided into contrasting sections for the purpose of differential diagnosis. In Pott's disease of infancy the muscular spasm is usually more intense and its extent is greater; the child screams when it is moved or when the diapers are changed. Slight irregularity of the spinous processes indicating the position of the destructive process is often evident and abscess is not unusual. There is usually no difficulty in determining the presence of disease even in very early cases, but, as has been mentioned, it is sometimes difficult to decide whether the lumbar spine or one of the hip-joints is involved.

Pott's disease of infancy may be mistaken for *acute rhachitis*, or *scurvy*. The symptoms of such affections are, however, not limited to the spine, but involve to a greater or less degree the limbs and joints, indicating that the discomfort and pain are due to a general, not to a local disease.

The Rhachitic Spine. The deformity of the spine, caused by rhachitis, is not infrequently mistaken for the kyphosis of Pott's disease.

It has been stated that when in early infancy the child is placed in the sitting posture the spine bends in a long, posterior curve, indicative of the weakness normal at this age. Such a curvature is characteristic also of acquired weakness and particularly that caused by rhachitis in early childhood. During the subacute stage of general rhachitis the child that has never walked or that has "lost its walk" sits much of the time in its chair, or is carried about on the mother's arm. In this posture the spine is bent backward and a curvature of the lower thoracic and lumbar region is habitual. Soon a slight projection persists, even when the child is lying down; it usually increases in size and becomes more resistant if its exciting cause remains; thus, a somewhat rounded and rigid posterior curvature of the dorsolumbar portion of the spine is formed.

The diagnosis from Pott's disease should be made without difficulty, because the evidences of general rhachitis are always present, and because the deformity is almost as much to be expected as would be distortions of the legs were the child walking. If the patient is placed in its habitual sitting posture it will be seen that the deformity is simply an exaggeration of a normal attitude. In this attitude the patient remains contentedly for an indefinite time, whereas if Pott's disease were present the child would lie on its

back or abdomen. The projection is rounded, not angular, and if the patient be placed in the prone posture the projection may be reduced, in great part, by raising the thighs while gentle pressure is exerted upon the kyphosis. Finally, although such extension and pressure may cause discomfort, there is complete absence of the muscular spasm characteristic of Pott's disease.

It may be stated, then, that the rhachitic deformity is a rounded curvature of the lower part of the spine. Its cause is weakness and habitual posture. The rigidity depends upon the duration of the deformity. The pain, if the rhachitis be acute, is general and it is easily explained by the sensitive condition of the bones and joints. It is true that rhachitis and tuberculous disease of the spine may be combined, but in such rare instances the symptoms of the more serious local disease will make themselves evident as distinct from those of the general weakness.

Recapitulation. The more characteristic symptoms of disease of the dorsolumbar region may be summed up as follows:

Increased lordosis or overerectness and a prominent abdomen; a cautious, constrained, or waddling gait; less often a lateral inclination of the body or a limp caused by psoas contraction.

Stiffness of the spine, which makes bending or turning the body difficult.

Pain, referred to the back, to the inguinal region, or to the thighs, and in more advanced cases the characteristic deformity.

Diagnosis. The attitude may be simulated by congenital dislocation of the hips and by pseudohypertrophic muscular paralysis.

The limp may be mistaken for that of hip disease.

The pain and stiffness for sciatica, rheumatism, lumbago, or injury.

The abscess is to be distinguished from those from other sources.

In young infants the symptoms may be simulated by hip disease and by acute rhachitis or scurvy.

Finally, the deformity of the subacute form of rhachitis is to be distinguished from that symptomatic of bone destruction.

Disease of Thoracic Region of the Spine.

The normal motion of this section of the spine, which includes the third and tenth vertebræ, is, as compared with those above and below it, slight; thus, disease of this region may not interfere to a noticeable degree with the general function of the spine.

As this part of the column curves backward, the deformity, often

unattended by severe symptoms, is not infrequently mistaken for round shoulders (Fig. 20). It seems probable, also, because of the normal backward curve, and because of the leverage exerted by the weight of the head and arms, that deformity quickly follows disease. At all events, patients are not often seen before it is present, so that diagnosis is usually evident on inspection of the patient.

The *attitudes* are not especially significant. If the lower part of the region is involved, and if the disease be at all acute, they are similar to those of disease of the lower region, viz., erectness, the peculiar, cautious, in-toeing step, and the disinclination to bend the body forward (Fig. 19).

If, on the other hand, the upper part is affected, the attitude is often, particularly in young children, one of weakness; there is a slight forward inclination of the body, the head being tilted backward or inclined toward one side, and a peculiar shrugging, squareness, and elevation of the shoulders is often noticeable (Fig. 21). In many instances the apparent elevation of the shoulders is in reality caused by the deformity, which shortens the neck and lowers the head (Fig. 23).

In this connection it should be mentioned that one of the secondary effects of the disease, the so-called *pigeon breast*, is, not infrequently, noticed by the parent before the angular deformity of the spine. In the pigeon breast of Pott's disease the forward inclination of the spine causes a flattening of the upper part of the chest, while the sternum sinks downward and becomes prominent; thus, the anteroposterior diameter of the thorax is increased, and it is compressed from side to side, resembling very closely the deformity of rhachitis. As the pigeon breast of Pott's disease is always secondary to the spinal deformity, its cause, of course, becomes apparent on examining the back.

Of the early symptoms of disease of the thoracic region, pain and labored or "grunting" respiration are the most characteristic. *Pain* referred to the abdomen and to the front and sides of the chest is usually an early and often a constant symptom; thus, persistent "stomach-ache" in a child should always lead to an examination of the spine. A "spasm of pain" is sometimes excited by lateral compression of the chest, as when the child is lifted suddenly by the parent.

Of much greater importance, however, is the *labored or grunting respiration*, which, indeed, is almost pathognomonic of Pott's disease. This "grunting" is caused by the interference with

respiration, more particularly with the normal rhythmical movements of the ribs. The restraint is, in part, due to muscular spasm and deformity and in part to the voluntary effort of the patient. The inspiration is quick and shallow, in great degree diaphragmatic, and expiration is accompanied by a sigh or grunt. This is caused apparently by a momentary closure of the larynx to resist

FIG. 20.

Pott's disease of the middle dorsal region at an early stage, showing slight increase of the dorsal kyphosis, without noticeable change in the attitude. Contrast with Fig. 21.

FIG. 21.

Disease of the upper dorsal region. Characteristic attitude.

the escape of air and thus sudden motion of the chest walls. Grunting respiration is, of course, an evidence of the more acute type of disease, but even in mild cases in children it will be noticed when the patient is fatigued or during play.

An *irritating, aimless cough* is often a symptom of disease of the

upper dorsal region, and spasmodic attacks resembling asthma are not uncommon.

In most instances the characteristic angular kyphosis will appear on examination, and in the exceptional cases in which deformity is absent, a slight change in contour will be apparent when the patient is bent forward. In place of the long, regular curve of the normal spine a point where two distinct outlines unite will be observed — one of which may be curved, while the other is practically straight (Fig. 7).

FIG. 22.

Marked lateral deviation of the spine with rotation. Deformity at the eighth dorsal vertebra.

The presence of muscular spasm may be shown by sudden movement of the spine, and it may also be demonstrated in children by raising the legs and swaying the body from side to side, as illustrated in the preceding section (Fig. 15). The change in the rhythm of respiration has been mentioned already. Although the respiratory movement of the entire thorax is lessened in range, the restraint does not affect all the ribs equally; those that articulate with the diseased vertebræ are often nearly motionless, while the movement of those at a distance from the disease may approach the normal.

In tracing the neuralgic pain to its origin the sharp, downward inclination of the ribs must be borne in mind; thus, the cause of pain in the "stomach" must be looked for between the shoulder blades.

As in the lumbar region, slight *lateral deviation* of the spine is not uncommon, and it may be accompanied by a noticeable twist or rotation so that the ribs on one side project slightly backward (Fig. 22).

In this region of the spine the *spinal cord* is more often involved than in disease of other sections; thus, an awkward, stumbling gait

and finally a "loss of walk" may be the symptoms that first attract attention. The paralysis of Pott's disease and its differential diagnosis are considered in more detail elsewhere.

Abscess as a complication of disease of the thoracic region cannot be demonstrated by palpation unless it has found an outlet between the ribs, but percussion will often show an area of dulness or flatness, extending from the diseased vertebræ toward the lateral aspect of the chest. This is due in part, however, to the inflam-

FIG. 23.

Double psoas contraction of an extreme degree and paralysis. The arms used as supports.

matory thickening of the tissues in the neighborhood. In rare instances the abscess may press directly upon the trachea or bronchi and cause spasmodic attacks of dyspnœa resembling asthma.

Diagnosis. It is hardly necessary to mention the list of affections that may cause pain in the chest or abdomen; it is sufficient to state that such symptoms always require a physical examination. The same statement applies to irregular respiration, to cough, and to so-called asthma.

Occasionally tuberculous disease of the dorsal spine in adolescence is practically painless, and the resulting deformity is rather rounded than angular, so that it may be mistaken for round shoulders. "*Round shoulders*" is, however, as a rule, of long duration. The exciting cause or causes of postural deformity, in occupation or otherwise, are indicated often by the history. The rigidity is less marked than in Pott's disease, and neuralgic pain is absent.

The situation and shape of the rhachitic kyphosis has been described. It should be evident that a more or less angular projection in the upper part of the spine could not be rhachitic; and yet because of the absence of pain this diagnosis is made not infrequently, and as a consequence the activity of the tuberculous disease may be increased by massage and exercises.

Lateral deviation of the spine as a symptom of disease hardly could be mistaken for the ordinary *rotary-lateral curvature*, in which pain and muscular rigidity are absent.

Acute affections within the chest, *pleurisy*, *pneumonia*, and *empyema*, are sometimes accompanied by lateral deviation of the spine, but the sudden onset and the constitutional and local symptoms that accompany such affections should make the cause of the deformity and pain evident. It is because these cases are sometimes sent to orthopedic clinics for braces that they seem worthy of mention.

The abscesses in this region, as has been mentioned, cause usually dulness or flatness on percussion of the chest, and within this area friction sounds and râles may be heard. The tuberculous fluid may remain indefinitely in the posterior mediastinum and the area of flatness may extend beyond the axillary line, yet it may give rise to no symptoms. If the diagnosis of Pott's disease had not been made or if the presence of the abscess had not been determined by the previous physical examination, it might be mistaken, during an acute exacerbation of the disease or constitutional disturbance from other cause, for pleurisy or empyema or even for phthisis. In all cases, therefore, a careful examination of the chest should be made from time to time in order that the presence or absence of abscess may be recorded.

Recapitulation. Pott's disease of this region is often insidious in its onset, causing no positive symptoms before the stage of deformity.

Its most characteristic symptoms are pain referred to the front and sides of the body and the grunting respiration.

If the disease is progressive, the characteristic symptoms of Pott's disease—weakness and rigidity—are present. The attitude, when the disease is in the lower thoracic region, resembles that of lumbar disease; if the upper part is affected the head is tilted somewhat backward and the shoulders appear to be elevated.

In differential diagnosis one will consider the significance of pain, cough, or embarrassed respiration, and the affections for which abscess or paralysis might be mistaken. Also, round shoulders, rhachitic deformity, and lateral deviation of the spine as distinguished from the kyphosis of Pott's disease.

2. **The Upper Region.** The upper region of the spine, which includes the cervical and two of the dorsal vertebræ, corresponds

FIG. 24.

Cervical disease with abscess. Characteristic attitude.

in freedom of movements and in its contour to the lumbar region. For the purpose of study it must be divided into two parts. Of these, the superior or occipito-axoid section is peculiar, in that it contains no vertebral body or intervertebral cartilage, and in that

the movements of the head are carried out in special joints and are controlled by special muscles.

Disease at this point is especially dangerous, because displacement or fracture of the weakened vertebræ may cause sudden death by pressure on the vital centres.

Occipito-axoid disease is uncommon, and it is relatively more frequent in adult life than in childhood.

Symptoms. In a typical case the symptoms are *neuralgic pain* radiating over the back and sides of the head, following the distribution of the auricular and occipital nerves. *The neck is stiff* and the head may be fixed in the median line, the chin being somewhat depressed, but it is more often tilted to one side, simulating the attitude of torticollis (Fig. 24).

The attitude and appearance of the patient, when normal movement of the neck is restrained by a painful disease, is characteristic; the eyes follow one, or the body is turned, when the attention of the patient is attracted. The patient moves carefully, in order to avoid jar; often the chin is instinctively supported by the hand, and a favorite attitude is one in which the patient sits with the elbows on a table, the hands supporting the head (Fig. 25). If the attempt is made to raise the chin, or to rotate the head, the patient seizes the hands of the examiner, and, it may be, screams in apprehension. There may be slight *bulging and thickening* of the tissues at the seat of disease. The affected vertebræ are usually sensitive to direct pressure, and not infrequently deep fluctuation in the suboccipital triangle can be made out.

The atlo-axoid junction lies just behind the posterior wall of the pharynx, on a line with the upper teeth. Here *abscess* often presents itself, occasionally early in the course of the disease, causing symptoms characteristic of obstruction, such as snoring, change in the quality of the voice, difficulty in swallowing, or spasmodic attacks of so-called croup. When abscess is present and when the disease is at all acute, the reclining posture sometimes aggravates the symptoms, so that "getting the child to bed" is often a tedious and difficult task.

In certain cases one can determine whether the disease is of the occipito-atloid or of the atlo-axoid articulation, but, as both joints are to a great extent controlled by the same muscles, this is often impossible.

The uppermost joint, that between the atlas and occiput, permits the nodding movement of the head, or flexion and extension

on the spine; while the atlo-axoid joint permits rotation of the atlas about the axis to the extent of about 30° in either direction. If the disease be in the upper joint the nodding movements will be more restricted than those of rotation, and *vice versa*. The motion of the cervical region is very free; so that to make the test one must grasp the neck firmly in order to restrain motion except in the joint under examination. Because of this freedom of movement, restriction of motion of the upper articulations is often overlooked when the disease is of the subacute variety.

FIG. 25.

Cervical disease. A characteristic attitude.

The Lower Cervical Region. The symptoms of disease of the lower cervical section, although similar in character, are often less marked than those of the upper region. The cervical spine becomes straighter, and often a slight backward projection or thickening indicates the position of the disease. The head is usually turned to one side by spasm of the lateral muscles in an attitude of wryneck (Fig. 26). The pain is referred to the neck,

to the sternal region, or down the arms, following the distribution of the brachial plexus.

In the more advanced cases one's attention may be attracted to the cervical region, because the neck seems short and because the head is tilted backward. The entire back shows a compensatory flattening, yet no deformity is apparent until the occiput is raised and drawn forward, when a shelf-like projection may be felt, at what appears to be the top of the spine, but which is really an angular deformity at the third or fourth vertebra.

This emphasizes the importance of a careful observation of the contour of the spine, and the necessity of explaining to one's self every change from the normal that may be noticed.

FIG. 26.

Disease of the middle cervical region at an early stage.

Disease at the cervicodorsal junction resembles in its symptoms that of the upper dorsal region. The head is usually tilted backward (Fig. 21) or it may be turned to one side. Disease at this point is often subacute in character, and paralysis from implication of the spinal cord sometimes appears before deformity is apparent. Occasionally irregularity of the pupils is present.

The spinous process of the seventh cervical or first dorsal vertebra is often prominent (vertebra prominens) in normal individuals, and it may be mistaken for the deformity of disease, especially when pain about this point is a symptom, as in hysterical or hyperæsthetic persons. If such projection is symptomatic of disease there is almost always a slight compensatory

flattening of the spine below the point and a certain degree of rigidity of the surrounding muscles.

Diagnosis. As stiffness and distortion of the neck are the most prominent symptoms of disease of this region, one must consider first the forms of *torticollis* for which it might be mistaken. In typical torticollis, the distortion of the head is caused almost invariably by contraction of the muscles supplied by the spinal accessory nerve, the sternomastoid, and trapezius; thus, the chin is slightly elevated and turned away from the contracted muscle.

Congenital torticollis, which has existed from birth, is not accompanied by pain, and it could hardly be mistaken for a symptom of disease.

Acute rheumatic torticollis, "stiff neck," is sufficiently common to be familiar in its characteristics. It is of sudden onset, "in a single night;" the affected muscles are sensitive to pressure; the course of the affection is short, and it is of comparative insignificance.

A more persistent form of acute *torticollis*, accompanied by muscular spasm and by local tenderness, sometimes accompanies enlarged or suppurating cervical glands; it may follow "earache," "tonsillitis," "sore-throat," or any form of irritation about the pharynx. This form of wryneck is not only very painful, but it may persist indefinitely, and permanent deformity may result. The onset is usually sudden; the pain and tenderness are local, and are confined, as a rule, to the contracted part. The sternomastoid and trapezius muscles are most often involved; thus, the wryneck is typical. If the tension be relaxed by inclining the head toward the contracted muscles, motion of the spine itself will be found to be free and painless; but if traction be made on the contracted muscles it causes discomfort, and it is usually resisted by the patient.

In disease of the occipito-axoid region the distortion of the head is, by no means, typical of sternomastoid contraction; it may be tilted up or down or laterally to an exaggerated degree. In other words, the wryneck of Pott's disease is an irregular distortion, because it is not dependent on the contraction of a particular muscle or muscular group. "In torticollis the chin is turned away from the contracted muscle, while in Pott's disease it is turned toward the contracted muscle." This is an axiomatic expression of the fact that the distortion of the head symptomatic of atlo-axoid disease depends, in great degree, upon the spasm of the small muscles that directly control these joints, the recti

and obliqui, and not directly upon the contraction of the sternomastoid muscle, as in the ordinary form of wryneck. Again, the contraction, symptomatic of Pott's disease, of this or other regions, is the result of muscular spasm, a muscular spasm that prevents painful motion. If the head be grasped firmly by the hands and if gentle traction is made, the muscular spasm relaxes and the patient experiences a sensation of comfort. If similar traction is made upon the contracted muscles of acute wryneck, the pain is increased and the patient protests.

In disease of the middle cervical region, however, the distortion due to the reflex muscular spasm may resemble closely that of simple torticollis, particularly if the latter is caused by the irritation of inflamed or suppurating glands. For, in such cases, there is usually much sensitiveness to manipulation, with more or less general muscular spasm, and diagnosis may be impossible until apparatus has been applied to rest the part and to correct the deformity.

As has been stated, the head may be tilted backward to compensate for deformity in the middle cervical region, and in some instances it may be drawn backward by spasm of the posterior muscles. Such a case might be mistaken for *cervical opisthotonos*, or posterior torticollis, which is sometimes seen in young infants suffering from exhausting diseases, basilar meningitis, and the like. In such conditions, however, the characteristic symptoms of Pott's disease are, of course, absent.

The opposite attitude, viz., a forward droop of the head due to weakness of the trapezii muscles, is not uncommon as a sequence of *diphtheria* or other forms of contagious disease. This droop may be accompanied, also, by spasm of one of the sternomastoid muscles and by pain. In such cases the history of the preceding affection, the weakness or paralysis of other parts, as of the soft palate, the muscles of accommodation of the eyes and the like, together with the general bodily weakness that the patients often present, should make the diagnosis clear.

Injury to the upper segment of the spine, a sprain, contusion, or fracture, unless efficiently treated, may cause symptoms resembling very closely those of tuberculous disease; for example, pain, radiating over the back of the head, rigidity and deformity of the neck, and even infiltration and local tenderness about the injured part. Such cases, when seen several weeks or months after the accident, are puzzling, because one may be in doubt whether the symptoms were caused by a simple injury or whether

tuberculous infection may have followed or preceded it. In such cases a positive diagnosis cannot be made until the effect of rest and protection has been observed—that is to say, suspicious cases should be treated as one would treat actual disease. If the case is simply one of injury recovery will be rapid and complete, while if disease be present the symptoms only will be relieved.

The occipito-axoid articulation may be involved in *acute articular rheumatism* or in *chronic rheumatoid arthritis.* If the manifestations are general in character the diagnosis is, of course, easily made; but occasionally the joints at the upper extremity of the spine may be the seat of what appears to be an infectious arthritis, in which the symptoms are of sudden onset and are sometimes combined with fever and constitutional disturbance, and in which no other joint is involved. The sudden onset and rapid recovery are the diagnostic points.

Abscess in the cervical region is a secondary symptom, and although the change in the voice or the difficulty in breathing or swallowing may be the most noticeable symptoms, yet they are always accompanied by some of the characteristic signs of Pott's disease.

Whenever the diagnosis of cervical disease is made one should examine the throat, and whenever a chronic retropharyngeal abscess is present one should look for the symptoms of Pott's disease.

The diagnosis of the retropharyngeal abscess can be made only by inspection and palpation; therefore, one need only mention the fact that symptoms of obstruction in the throat, similar to those of abscess, may be caused by adenoid growths and by enlarged tonsils.

Retropharyngeal abscess is by no means always symptomatic of Pott's disease. It may be one of the sequelæ of contagious disease or a complication of pharyngitis. It is then rapid in its onset and is not accompanied by the symptoms of Pott's disease.

Recapitulation. If the disease is of the upper or occipito-axoid region the head is usually fixed in an attitude of deformity, which is sometimes slight and sometimes extreme.

If the disease is of the middle region, the attitude more often resembles that of ordinary torticollis. In the lower region there is often no marked spasm of muscles, but the head inclines backward or toward one shoulder.

The contour of the cervical spine changes as the disease progresses; the normal anterior curvature is obliterated; thus,

the head is pushed forward, while the dorsal section of the spine becomes flat or even incurvated in compensation. The seat of the disease is often shown by an area of thickening or local tenderness to deep pressure.

Disease of the joints of the upper or occipito-axoid section is often acute in onset, in some instances apparently a form of synovial tuberculosis, and abscess is a very frequent complication.

Differential diagnosis of disease in this region will include the consideration of the various forms of wryneck, cervical opisthotonos, diphtheritic paralysis, and injury. Secondary abscess must be distinguished from simple retropharyngeal abscess and from other forms of obstruction in the throat.

Diagnosis in General. Weakness and the so-called "loss of walk" are well-known symptoms of Pott's disease, and on this account children suffering from different forms of weakness or paralysis are often sent to orthopedic clinics for the treatment of "spine disease."

Certain forms of paralysis bear a superficial resemblance to some of the symptoms of Pott's disease; for example, *pseudo-hypertrophic muscular paralysis* to the attitude caused by disease of the lumbar region, and *diphtheritic paralysis* to that of the dorsal region. *Spastic paralysis*, of cerebral origin, resembles somewhat the paralysis of Pott's disease, but it may be differentiated by the absence of pain, by the history, and by what is apparent in most cases, the mental impairment.

Primary spastic spinal paraplegia resembles the paralysis of Pott's disease more closely, but here, again, the essential symptoms of a destructive disease of the spine are absent.

The contractions combined with the weakness and pain that sometimes follow *cerebrospinal meningitis* may be mistaken for the symptoms of bone disease, but are, as a rule, readily explained by the history of the case.

Forms of organic disease of the spine other than tuberculosis, as, for example, malignant disease, syphilis, spondylitis deformans and the like, are described in Chapter II.

The list of affections that has been considered in the differential diagnosis is a long one, but it has been made up from actual experience. Most of the mistakes in diagnosis may be explained by carelessness or ignorance, or because of insufficient opportunity for examination; but in the earliest stages of the disease repeated examinations and even tentative treatment may be necessary before the diagnosis is confirmed.

The Roentgen Ray Photography as a Means of Diagnosis. The Roentgen ray is of comparatively little importance from the diagnostic standpoint, but it may be of value as a means of determining the exact extent of the disease. If the negative is well defined, the diseased vertebræ are seen to be irregular in outline, or they may be lost in a peculiar blur. By counting from above and below the exact extent of the disease may be made out, but inferences as to its character and quality must be made from the rational and physical signs (Fig. 34).

The Record of the Case. The history and the results of the examination of the patient should be recorded somewhat in the following order:

1. The family and the personal history.

2. The history of the disease, with especial reference to its mode of onset, its probable duration, to the noticeable symptoms, and to previous treatment.

FIG. 27.



Tracings of the spine illustrating the recession of deformity.

3. The physical examination. This should include the general condition of the patient, the height and weight, the attitude, the character of the disease, whether progressive, as indicated by muscular spasm and pain on motion, or quiescent, the presence of abscess or paralysis as a complication, and, finally, the position and extent of the disease. This is best shown by a tracing, made by means of a strip of lead or pure tin, of such thickness that it may be readily moulded on the spine and yet hold its shape when removed (Fig. 27).

The tracing should be of the entire spine, made while the patient lies extended in the prone position, and the exact location of the most prominent spinous processes should be marked upon it. In determining the position of the disease it is well to count the spinous processes from below upward, beginning with that of the fourth lumbar vertebra, which lies on a line drawn between the highest points of the iliac crests. There are other landmarks

that are approximately correct. Sometimes the last rib may be traced to its origin; the scapula covers the second and seventh ribs, the root of the spine of the scapula and the middle point of the glenoid cavity being on a line with the third, and its inferior angle opposite the tip of the seventh dorsal spinous process. The upper margin of the sternum is opposite the interval between the second and third dorsal vertebræ. In many instances the vertebra prominens and the spinous process of the axis can be identified. Such landmarks are, of course, somewhat displaced if the deformity is extreme, but they are always sufficiently correct to check errors in counting the spinous processes.

The history furnishes a foundation on which treatment is conducted and from which its results may be determined. The study of final results has become of great importance in orthopedic surgery, and on this account the record should present the condition of the patient when treatment is begun, in a form that may be readily understood, not only by its writer when details have been forgotten, but by anyone who may in after years consult it. In this history the complications and incidents and the changes in the treatment should be noted at regular intervals until the patient is cured.

Treatment. The general treatment of tuberculous disease is considered in Chapter V. Pott's disease is the most important of the tuberculous affections of the bones, and the importance of proper surroundings, proper food, sunlight, and above all open air both day and night, if possible, can hardly be exaggerated.

The General Principles of Mechanical Treatment. Under normal conditions the weight of the head and of the thoracic and abdominal organs tends to bend the spine forward and downward—a tendency that is resisted by the action of the muscles of the back. If the resistance is weakened, as in Pott's disease by the direct destruction of the weight-bearing portion of the spine, this tendency toward deformity is, of course, greatly increased. Thus, the pressure of the superincumbent weight upon the weakened part and the strain of motion are, from the mechanical standpoint, the most important factors in the production of deformity.

When the body is bent forward, as in the stooping posture, the intervertebral discs are compressed and the pressure upon the vertebral bodies is increased. When the body is held erect or is bent backward this pressure is lessened, and a part of the weight is transferred to the articular processes and to the posterior parts of the column. The object of a brace or other support is to hold

the spine in this extended position, so that pressure on the diseased vertebræ may be removed. One aims to splint the diseased spine as effectively as if it were broken, in order to relieve the discomfort and pain, so depressing to the patient, and to secure the rest that is essential to repair.

The effectiveness of a particular splint or support, whether applied to a broken bone or to a diseased spine, depends upon the area that it covers on either side of the part to be supported, and upon the accuracy of its adjustment, as well as upon the damage that the part has already sustained, and the strain to which it still may be subjected.

From this standpoint it is evident that it is difficult to apply effective support to the trunk because of its size, shape, and contents, and it is apparent also that the mechanical conditions are more favorable in some parts than in others. For example, the splint is likely to be effective when the disease is of the lower dorsal region, because its two extremities, attached to the pelvis and to the shoulders, are equidistant from the point to be supported. These conditions are reversed in disease of the upper thoracic region, because the weight of the head and of the arms tends to increase the deformity, and because of the insufficient leverage that can be secured for the supporting appliance. The pelvis is the base of support for all forms of splints, and if it be smaller than the abdomen, as in infancy, the adjustment of efficient support is more difficult than in older subjects.

In actual practice the treatment of Pott's disease is influenced by the age of the patient, the situation of the disease, the duration of the deformity, and by many other circumstances, but the relative efficiency of braces or other appliances may be decided on purely mechanical grounds. Thus, as the ultimate deformity of Pott's disease is, in great degree, caused by the *force of gravity acting on a weakened spine*, the most effective treatment must be fixation in the horizontal position, for in this position the strain of use and the pressure of superincumbent weight can be removed completely; and relief from jars and strains that favor the extension of the disease can be assured.

Horizontal Fixation. Apparatus for this treatment must be quite independent of the bed on which it may be placed, and of such appliances several forms may be employed.

The reclinationgypsbettes of Lorenz[1] is simply a posterior case of plaster-of-Paris enclosing the head and body.

[1] Hoffa. Lehrbuch der Orthopädischen Chir., 3d ed., p. 324.

The Phelps bed is somewhat similar. A thin board is cut in the outline of the child's body and extended legs. It is padded with wadding and covered with cotton cloth; the patient is then placed upon it, and plaster bandages are applied to enclose the body and the legs. The front is then cut away, so that the patient may be removed from the bed for an occasional bath and change of clothing.[1]

FIG. 28.

Bradford's bed-frame. (Bradford and Lovett.)

The wire cuirasse has been popularized by Sayre;[2] it is an effective appliance, although somewhat cumbersome and expensive.

An effective and convenient form of support is the Bradford frame or stretcher. This is a rectangular frame a few inches longer and slightly wider than the patient's body. Over the frame covers of strong canvas are drawn tightly by means of

FIG. 29.



The modified frame with the bandage.

corset lacings or straps on its under surface, leaving an interval beneath the buttocks for the use of the bed pan (Fig. 28).

The efficiency of this appliance may be increased by changing it in several particulars, and the following description applies to the apparatus used by the writer:

The stretcher frame is made of ordinary galvanized gas-pipe or of steel tubing of a smaller diameter. It should be about four

[1] The Phelps Plaster-of-Paris Bed. Trans. Amer. Ortho. Assoc., 1891, vol. iv. p. 83.
[2] La gouttière de Bonnet. Rédard, Chir. Orthopédique, p. 243.

inches longer than the child and about four-fifths as wide, the lateral bars corresponding to the articulating surfaces of the four extremities with the trunk. The ordinary dimensions are seven and one-half by thirty-eight inches, or the width to length about as one to five.

At first thought it would seem that the side bars might cause uncomfortable pressure on the overhanging shoulders, but as the

FIG. 30.

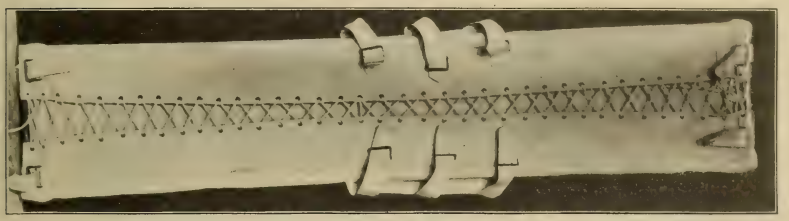

The stretcher frame, showing the canvas cover and apron.

arms are set upon the middle of the lateral aspect of the trunk and thus on a considerably higher plane than the dorsum, there is but bare contact when the cover is fairly rigid. Before applying the cover one may with advantage wind bandages tightly about the frame at the point which is to support the trunk in order to make the support as unyielding as possible (Fig. 29). The

FIG. 31.

The frame bent to assure overextension of the spine. The recession of deformity obtained in this case is shown by the tracings, Fig. 27.

cover should be of strong canvas suitably protected in the centre by rubber cloth. This is applied and is drawn tight by means of corset lacings and straps. Upon this two thick pads of felt are sewed; these should be about seven inches in length and about three-quarters of an inch in thickness, so placed as to pass on either side of the spinous processes at the seat of the disease, thus protecting them from pressure, fixing the part more firmly,

and increasing the leverage of the apparatus. The child, wearing only an undershirt, stockings, and diaper, is placed upon the frame and is fixed there usually by a front piece or apron similar to that used with the spinal brace. As soon as the patient has become accustomed to the restraint, one begins to overextend the spine by bending the bars from time to time upward beneath the kyphosis with the aim, as has been stated, of actually separating the diseased vertebral bodies and obliterating all the physiological curves of the spine, so that the body shall be finally bent backward to form the segment of a circle. The greatest convexity is at the seat of the disease, and as the head and lower extremities are on a much lower level, an element of gravity traction is present in some instances, while the support of the spine, as a whole, is much more comprehensive than when the body

FIG. 32.

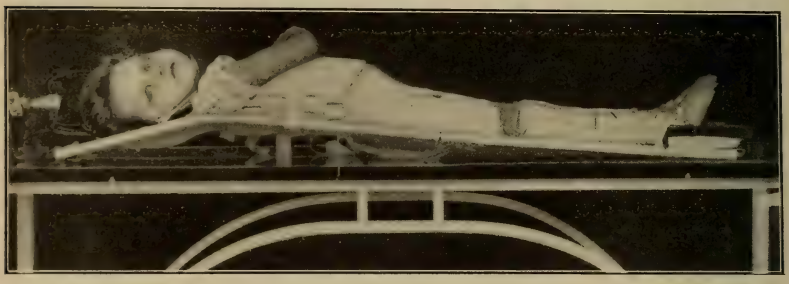

The modified stretcher frame, showing overextension of the spine, with traction for the head and limbs as applied for Pott's paraplegia. Caused by disease in the upper dorsal region. (See Fig. 53.)

lies upon a plane surface (Fig. 31). The gradual overextension of the spine by bending the frame in this manner is so definite and simple that it may be easily carried out by the physician, and it may be exaggerated slightly to compensate for the sagging of the cover. Thus, it is far more effective than any form of padding or other form of support with which I am familiar. Upon this frame the child lies constantly, its clothing being made sufficiently large to include the apparatus, thus assuring additional fixation. Once a day in most instances the child is removed from the frame and is carefully turned face downward upon a large pillow ; the back is then inspected, bathed with alcohol and powdered, and the apparatus is then reapplied. It is, of course, desirable to have two equipped frames, but this is by no means essential.

The effect of the continued fixation upon the back is not merely to change the contour of the spine, but of the entire trunk as well; to flatten and broaden the body. This increase of the lateral at the expense of the anteroposterior diameter is quite the reverse of the natural tendency of the deformity, and it is, therefore, a favorable rather than an unfavorable effect of the treatment. The same tendency in the lower region may be checked by the use of a flannel binder, such as is ordinarily worn by infants.

FIG. 33.

A perfect cure obtained by the stretcher treatment. The situation of the disease is shown in the X-ray picture, Fig. 34.

The method of attaching the patient to the frame varies somewhat according to the situation and character of the disease. In ordinary cases, as has been stated, a canvas apron, similar to that used with the back brace (Fig. 41), is applied, and is buckled to the sides of the frame. If advisable the shoulders may be held down by straps crossing the chest, or by axillary straps connected by a chest band. If still more effective fixation is desired, as in disease of the upper dorsal region, the anterior shoulder brace, as used with the back brace (Fig. 39), may be attached to the axil-

lary straps. In disease of the upper and middle regions of the spine restraint of the legs is not necessary, but in lumbar disease

FIG. 34.

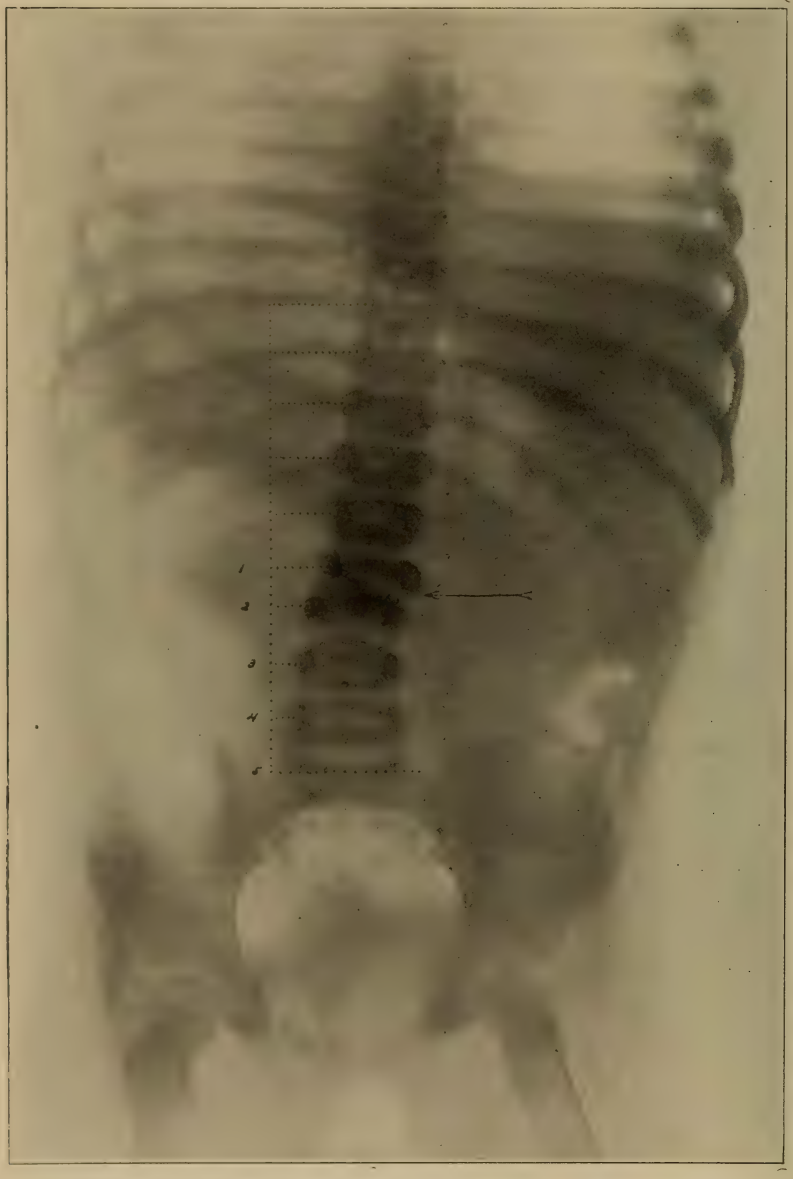

An X-ray picture of the case (Fig. 33) before treatment. The situation of the disease at the junction of the first and second lumbar vertebræ is indicated by the lateral deviation, and by the approximation of the dotted lines 1 and 2 as compared to the others.

a broad swathe should be passed across the thighs, and if psoas spasm is present traction may be employed.

In disease of the upper region of the spine a certain amount of traction is desirable to aid in the reduction of deformity and to prevent the patient from raising the head. This traction is usually applied by means of the halter as used with the jury mast. The straps are attached to a crossbar at the upper extremity of the frame, and traction may be made by simply tightening them, or if the upper part of the frame is somewhat elevated the weight of the patient's body makes the proper extension. This position has the advantage, also, of allowing the patient a better opportunity to see what is going on about him (Fig. 32).

In disease of the middle cervical region traction is usually of service, and fixation of the head is always indicated in addition when the occipito-axoid region is involved, either by sand bags on either side, or, preferably, by some form of metal brace.

Greater fixation of the spine may be desirable in cases of more acute disease. This may be attained by the use of a light back brace, or a plaster jacket, in connection with the frame. Such support should not be applied, however, until the recession of deformity, which is to be expected under treatment by the horizontal fixation and overextension, has been obtained (Fig. 27).

As this frame is simply a horizontal brace the child may spend as much time in the open air as would be practicable were any other appliance used.

Personally, I have never seen other than favorable results from this method of treatment. Pain and discomfort are, as a rule, relieved almost immediately, and there is a corresponding improvement in the general condition of the patient. Meanwhile the growth of the trunk, which is so often checked by the disease and by the deformity, appears to progress with normal rapidity, so that the apparatus may be actually outgrown before the termination of this part of the treatment. Horizontal fixation is, of course, a treatment not complete in itself, since it must be supplemented by the usual supports when the erect attitude is again assumed. Its duration varies from six to eighteen months. The indications for its discontinuance are the correction of deformity, the apparent quiescence or cure of the local disease as indicated by the physical signs, and by the behavior of the patient, who, as repair advances, becomes restless when removed from the frame, evidently desiring to sit and to stand.

At this stage it is well to apply the ambulatory support some

time before the patient is released from the frame, allowing little by little the changes in attitude and habits. If the plaster jacket is to be used it may be applied during longitudinal suspension or otherwise, after which the child is immediately replaced upon the frame, where the plaster is allowed to harden; thus it holds the spine in an attitude to which it has become accustomed. (Fig. 58.)

Ambulatory Supports. The two types of ambulatory supports are the steel brace and the plaster jacket.

FIG. 35.

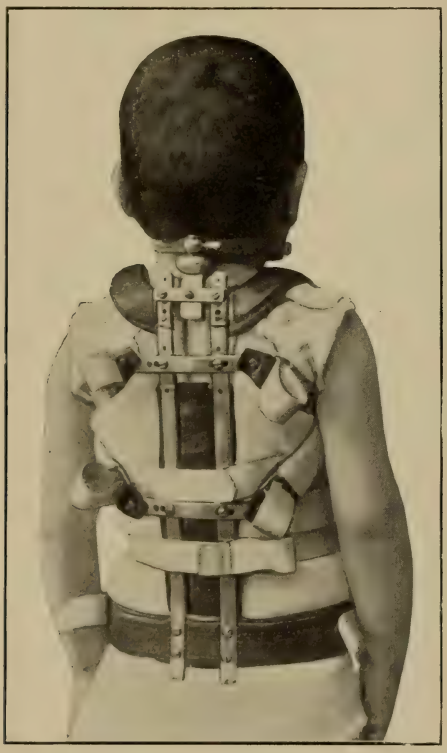

The Taylor brace and head support applied for disease of the upper dorsal region.

The Back Brace. The spinal brace, or spinal assistant, as the original appliance of Dr. C. F. Taylor was called, consists essentially of two steel bars that are applied on either side of the spinous processes from the top to the bottom of the spine. At the seat of the disease pads are placed to provide for greater pressure and fixation, and to form a fulcrum over which the spine may be straightened or held erect, when the two extremities

of the brace are firmly attached to the pelvis and to the shoulders. The attachment at the lower end is made by means of a pelvic band of sheet steel (gauge 18) from one and a half to two inches in width, long enough to reach from one iliac spine to the other; it is placed as low as possible on the pelvis; in other words, just above the upper extremities of the trochanters. To this the uprights are firmly attached at an interval of from one and a quarter to one and three-quarter inches from one another, so that the spinous processes may pass between them, while pressure is made on the lateral masses of the vertebræ. The uprights are made of varying strength, according to the age of the patient, usually about one-half an inch in width (of gauge 8 to 12) and of such quality of steel that, although unyielding to the strain of use, it may be readily bent by wrenches, and thus accurately adjusted to the back. The uprights reach to the root of the neck, or to about the level of the second dorsal vertebra; from this point two short arms of metal project forward and outward on either side of the neck, reaching to about the middle of the clavicles. To these padded shoulder straps are attached, which pass through the axillæ to a crossbar on the back brace; thus, downward pressure on the shoulders is avoided and increased leverage is assured (Fig. 35).

Fig. 36.

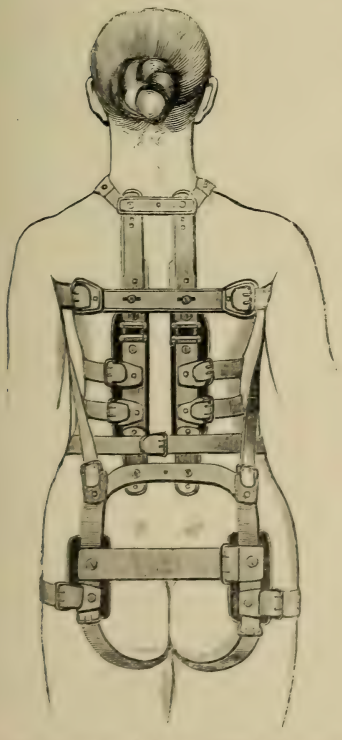

The Taylor back brace. (H. L. Taylor.)

Opposite the area of disease two strips of thin steel about three inches in length are fixed; these are slightly wider than the uprights and are

Fig. 37.

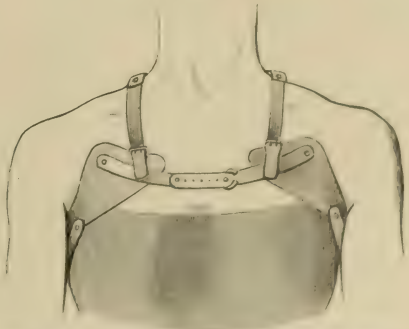

The Taylor chest piece. Two triangular pads of hard rubber connected by a bar.

perforated for the attachment of the pressure pads. These may be made of layers of canton flannel or felt, or unyielding material, such as leather or hard rubber, may be used instead. The pads should project from a quarter to a half-inch in front of the uprights in order that firm and constant pressure, to the extent that the skin will tolerate, may be made at the seat of disease (Fig. 36).

In measuring for this brace the patient is placed in the prone posture and a tracing of the outline of the back is made by means

FIG. 38.

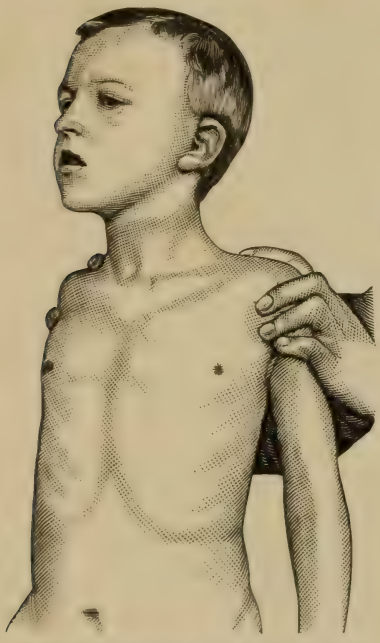

Backward traction on the shoulders fixes the upper dorsal region.

FIG. 39.

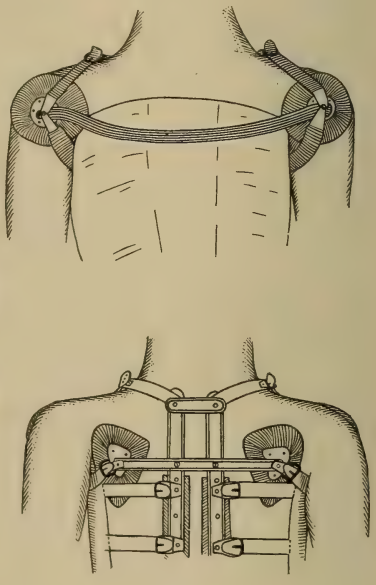

The anterior shoulder brace and its attachment.

of the lead tape. This outline may be cut in cardboard and fitted to the back; in fact, if the mechanic is unfamiliar with the work, each part of the brace, uprights, pelvic band, etc., may be cut in cardboard and attached to one another to serve as a model. Before the brace is finished it should be applied to the back and should be adjusted carefully by means of wrenches. The pelvic band and the parts that come in direct contact with the skin are usually covered with leather, or, in the treatment of young children, with rubber plaster and canton flannel to prevent rusting.

If the brace is applied before the stage of deformity it should follow the exact shape of the spine, but if deformity is present, particularly in disease of the thoracic region, it should be made somewhat straighter, in order to permit a gradual correction of the compensatory lordosis in the lumbar region, and for increased leverage above the deformity. As has been stated, a certain amount of recession of deformity can be obtained by rest in the horizontal position, and if practicable this improved contour should be attained before the brace is applied. The apparatus is held in place by an "apron" (Fig. 41), which covers the chest and abdomen, to which straps are attached. Ordinarily this is made of strong linen or cotton cloth, but a canvas front shaped accurately to the body and strengthened with whalebone, is a more comfortable and efficient support. In applying the brace the pelvic band is first attached to the apron, then the straps in order, from below upward, and, finally, the shoulder straps. Each strap is tightened until the brace is firmly fixed in proper position. When a brace is properly applied and properly fitted it holds its place by friction, but when the disease is of the lower lumbar region, or if the brace has a tendency to upward displacement perineal straps should be used to hold the pelvic band firmly in its place (Fig. 36). At first the brace is removed once a day in order to wash and powder the back, the same care being observed in moving the child as in the treatment by the frame; but when the skin has become accustomed to the pressure the brace should be removed only at infrequent intervals, and thus, if desirable, only under the supervision of the surgeon.

This description indicates the essential qualities of the back brace. It has been modified in various ways; for example, Dr. Taylor long since discarded the straight pelvic band in favor of one of a U-shape (Fig. 36). This makes the brace somewhat lighter and relieves the sacrum from pressure, but it does not add to its effectiveness. The efficiency may be increased, however, by improving the attachment at its upper extremity, as is illustrated in Fig. 37, in which two triangular pads of hard rubber connected by a metal bar are employed.

This is an improvement on the simple shoulder straps of the original brace, but it does not provide the quality of support and fixation that is desirable when the disease is of the upper or middle segment of the thoracic region. In such cases the upper part of the chest is flattened, the inclination of the ribs is increased, and the shoulders droop forward, carrying with them the

scapulæ. Thus, the weight and the strain of the motion and use of the arms tend to increase the deformity.

In health direct forward or reaching movements of the arms are always accompanied by an increase in the posterior curvature of the dorsal spine. On the other hand, if the shoulders are drawn backward and held in this attitude, the curvature of the spine is lessened and the chest is elevated and expanded (Fig. 38).

FIG. 40.

The Taylor back brace and head support combined with the Whitman anterior support.

In the treatment of disease of the upper dorsal region it should be the aim, in the application of a brace, to follow this indication and to apply pressure directly upon the extremities of the shoulders to assure the greatest possible fixation of the spine and to restrain the movements of the arms that tend to increase the deformity.

The accompanying diagrams (Fig. 39) show how such support

may be applied. Two saucer-shaped plates of hard rubber or padded metal (Fig. 40) cover the heads of the humeri and are joined by a rigid bar of steel, which passes across but does not touch the chest. On the back brace are placed two triangular pads of similar construction which cover and press upon the scapulæ. These pads are, however, not essential and are often omitted. The back brace is applied, the shoulders are then drawn backward and the shoulder-cups are firmly attached by straps to the neck bars of the brace above, and by axillary bands below in the usual manner. By this means the thorax is elevated and the

FIG. 41.

The anterior shoulder brace.

FIG. 42.

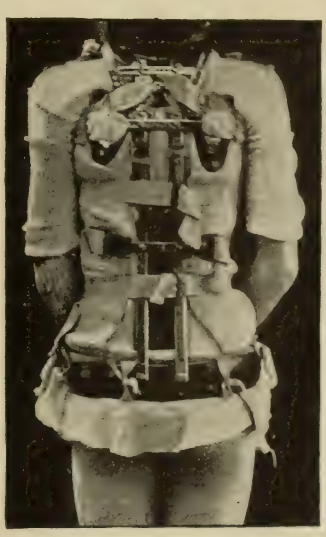

The scapular pads.

spine is more effectively fixed, while direct movement of the arms forward is made impossible. It would seem that such restraint would be irksome to the patient, but in an extended use of the apparatus this has never caused complaint. In many instances, even when the disease is as low as the tenth dorsal vertebra, it may be used with advantage, but it is especially indicated when the disease is in the neighborhood of the seventh dorsal vertebra. In connection with the shoulder brace it is usually advisable to apply a support beneath the chin to prevent the forward inclination of the neck and to tilt the head somewhat backward. A

very simple and inoffensive support of this character is a loop of steel surrounding the neck and attached by screws to a back bar on the brace (Fig. 43). If a more efficient brace is required, as when the disease is of the upper dorsal or cervical regions, the Taylor head support should be used. This is an oval ring of steel which may be clasped about the neck by means of a lateral hinge. On the front a cup of hard rubber supports the chin and behind the ring fits upon an upright pivot that may be raised or lowered upon a crossbar on the upper part of the brace; free lateral motion is allowed, or it may be checked by means of a screw (Fig. 45).

If absolute fixation of the head is indicated, as in disease at or near the occipito-axoid region, two steel uprights may be attached to the back of the ring; these are bent to fit the posterior and lateral aspect of the head closely, and a band of webbing is passed from one upright to the other and about the forehead.

In applying the support the chin should always be tilted slightly upward in order to throw

FIG. 43.

The loop head support.

FIG. 44.

Disease of the middle cervical region, showing the deformity and attitude. This patient had been paralyzed for one year before treatment was begun (See Fig. 45.)

the weight of the head backward (Fig. 45). The adjustment of the head support is made easier if the pivot is attached to the upright by means of a ball and socket joint (Shaffer) (Fig. 35) that may be regulated by a screw and key; this arrangement is of service when the head is distorted, but it is by no means necessary.

FIG. 45.

The Taylor brace and head support applied to the patient shown in Fig. 44.

FIG. 46.

The Taylor brace with jury mast.

When the Taylor head support or similar appliances are used the greater part of the pressure is sustained by the chin, which may, after a time, undergo an unsightly recession. It may be of advantage, therefore, in such cases, and particularly when restraint of the motion of the neck is desirable to transfer this pressure to

the forehead and occiput by extending the back bars upward over the back of the head, as in Fig. 51.

A jury mast may be used to support the head also; its adjustment will be described in connection with the plaster jacket, with which it is usually associated (Fig. 46).

The Plaster Jacket. It was claimed at one time that a plaster jacket applied while the body was partially suspended would actually relieve the weakened area of superincumbent weight by holding the diseased surfaces apart. This is not the fact. The jacket supports the spine as does the brace by holding it in the erect or extended position. One is a circular and the other is a posterior splint. There is this difference, however: the brace fits the spine accurately and holds its place by pressure and friction; the jacket is held in place by the support of the projecting pelvic bones; it lacks the accuracy of adjustment of the brace at the seat of disease, but, on the other hand, it provides a solid support on the front and sides of the body.

Each appliance has advantages and disadvantages that become apparent in the treatment of certain phases of the disease or conditions of the patient.

The plaster bandage is a simple support, whose efficiency depends upon the accuracy of its adjustment to the irregularities of the body, and upon the leverage that it exerts above and below the weakened part. It should be applied while the body is held in the best possible position; its inner surface should be smooth, and the bony prominences that are susceptible to friction and pressure should be protected.

A seamless shirt should be worn; these are made in several sizes and are sold by the yard at a low price. The shirt should fit the body closely, and should be long enough to reach to the knees. On the front and back bands of linen or China silk or other material, about three inches in width and three feet in length, should be placed beneath the shirt. These bands, or, as Lorenz calls them, "scratchers," are for the purpose of keeping the skin clean. The patient is then placed upon a stool, and the halter of the suspension apparatus is carefully adjusted; the arms are extended over the head and the hands clasp the straps or rings; thus, the chest is expanded to its full limit. Sufficient tension is made upon the rope to partially suspend the body and to draw the spine into the best possible attitude; in most instances the heels should be slightly lifted from the stool.

Dr. Sayre, to whom we are indebted for the exposition of this valuable means of treatment, insisted that the sensations of the patient should be the guide, and that traction should be made only to the point of comfort. This is a valuable indication in the treatment of the adult, but it is not often of service in childhood.

Before applying the plaster bandage pieces of piano felting or canton flannel of sufficient thickness are placed about the anterior pelvic spines, over the upper part of the sternum, and a thin strip is sometimes used to cover the spinous processes. Finally, long strips of saddlers' felt, or of other material of sufficient thickness, are applied on either side of the prominent spinous processes to protect them from friction and to provide greater pressure and fixation at the seat of disease. In the treatment of adolescent or adult females the breasts should be covered with a layer of cotton, which may be removed later if necessary, to prevent pressure. The "dinner pad" is now not often used, except in the treatment of adults and in certain cases in which the abdomen is retracted. In childhood the abdomen is usually prominent, and in most instances no extra space is required. Occasionally, however, one is told that the patient complains of discomfort after meals, evidently due to constriction, and in such cases proper allowance must be made. The pad, which is supposed to represent the space necessary after a full meal, is made by folding a small towel into the shape of a sandwich; this is attached to a bandage and is placed beneath the shirt just below the ensiform cartilage; when the jacket is completed it may be drawn out by means of the hanging bandage, leaving the additional space for emergencies.

The materials for the jacket should be of the best. Fresh dental plaster should be rubbed by hand into strips of crinoline, free from glue. The bandages should be from three to five inches in width and six yards in length, from three to six being required for a jacket, according to the size of the child. They should be placed on end, in a pail of warm water, one at a time as they are used. No salt or alum should be used to hasten the setting of the plaster; in fact, if such aid is necessary, it is unfit for use. When the bubbles have ceased to rise the bandage is squeezed gently until no water drips from it, and the loose threads are removed from the ends.

One person should sit behind the patient and one in front, while a third may hold the rope and check the swaying of the

body. The one who sits behind the patient may clasp the child's legs between his knees and thus assure better fixation of the pelvis. The pads are held in position until they are fixed by the plaster bandages, which should be applied with a slight and even tension.

As a rule, the jacket should be of uniform thickness throughout. This thickness need not exceed one-eighth to one-fourth of an inch, and it may even be lighter in certain cases. It is well to make the first turns about the waist, and to use the first bandage about the pelvis, since the pelvis is the base of support; and, as the most important point for counter-pressure is the chest, this part should be made especially strong and resistant.

During the application of the jacket it should be rubbed constantly, in order that the different layers of bandage may adhere to one another, and that it may fit the projections of the pelvis and body closely. Meanwhile the attitude of the patient should be carefully watched, in order to prevent lateral inclination of the body. In some instances it is possible to lessen the deformity by the extension and by backward traction on the shoulders and forward pressure on the trunk while the jacket is hardening.

When the jacket is nearly firm it should be trimmed. In many instances this may be done while the patient is in the swing, but if he is fatigued he may be placed in the recumbent posture.

As a rule, the front of the jacket should reach from the upper margin of the sternum to the pubes; behind, from about the mid-line of the scapulæ to the gluteal fold; laterally, it should be cut away sufficiently to prevent chafing of the arms; and on either side of the pubes an oval section is cut out, to allow for the flexion of the thighs in the sitting posture. Particular attention is called to the importance of making the jacket as long as possible, so that the abdomen may be contained within it instead of being forced out beneath its lower border (Fig. 48). After the application of the jacket the patient should remain in the recumbent posture for at least half an hour. A much longer period of recumbency is always advisable, as it does not become absolutely firm for several hours. The shirt is then drawn up over the jacket and is sewed to the neck portion; this adds much to neatness and cleanliness. The shirt must be drawn tightly about the neck, in order to guard the body from the crumbs or other objects that may fall beneath the jacket, and in many

instances a special protector in the form of a wide collar bib may be used with advantage.

The upper and lower ends of the cleansing bandages are joined to one another with tape, and with them the skin is carefully rubbed twice daily. When soiled they may be replaced.

FIG. 47.

The plaster jacket, illustrating the arrangement of the shirt.

FIG. 48.

The plaster jacket supporting the abdomen. The cleansing bandages are not shown.

It may be mentioned in this connection that even the slightest excoriation or irritation of the skin beneath the jacket can be detected by the peculiar odor. Of this parents should be in-

formed, so that it may be cut down and the source of the irritation removed at once. With ordinary care "sores," the bugbear of the plaster jacket, may be avoided or so quickly detected that they are of little consequence.

If the disease is of the middle region of the spine, backward traction on the shoulders is indicated, by means of the anterior

FIG. 49.

The jury mast and the anterior support.

shoulder brace described in connection with the spinal brace (Fig. 49); or, if this is not at hand, padded straps may be passed about the shoulders and attached to buckles placed on the back of the jacket. Traction applied in this manner aids in preventing deformity and assures better expansion of the chest.

In many instances a head support is required, and it is, of course, always indicated in disease of the upper dorsal and cervical regions. For this purpose a jury mast or a posterior support may be employed.

The jury mast should be of tempered steel, strong enough to hold its shape under the tension of the halter (Fig. 50). Its base should be incorporated firmly in the jacket below the seat of the disease; it should be long enough to reach well above

the head, and the crossbar should be placed directly over the ears (Fig. 53).

FIG. 50.

Jury mast.

FIG. 51.

A fixation support for the head. This may be used with the brace or with the jacket.

FIG. 52.

Front view of the same patient.

The halter should be applied with as much tension as can be borne comfortably by the patient, so that the weight of the head may be at least partly supported. The straps should be adjusted to tilt the chin slightly upward, the aim being to draw the head backward and thus to extend the spine. In disease of the cervical region the crossbar should be fixed to check lateral motion of the head, but this is unnecessary when the disease is at a lower level.

FIG. 53.

The jacket and jury mast applied. The same patient is shown in Fig. 32.

If more complete fixation of the head is desired, or if the jury is ineffective, an appliance similar to that shown in Fig. 51 may be used. This consists of two light steel bars, incorporated like the jury mast in the jacket, and adjusted to the neck and back of the head. Their upper extremities are joined by a band of light steel of U-shape, long enough to reach from ear to ear, the circumference being completed by a band of tape across the forehead. In certain instances additional straps may be placed beneath the chin and the occiput, as in Figs. 51 and 52. In this

connection it may be stated that the support provided by the jury mast is only effective when it is carefully adjusted and carefully watched. In most instances, therefore, a rigid apparatus, though less comfortable, is to be preferred.

FIG. 54.

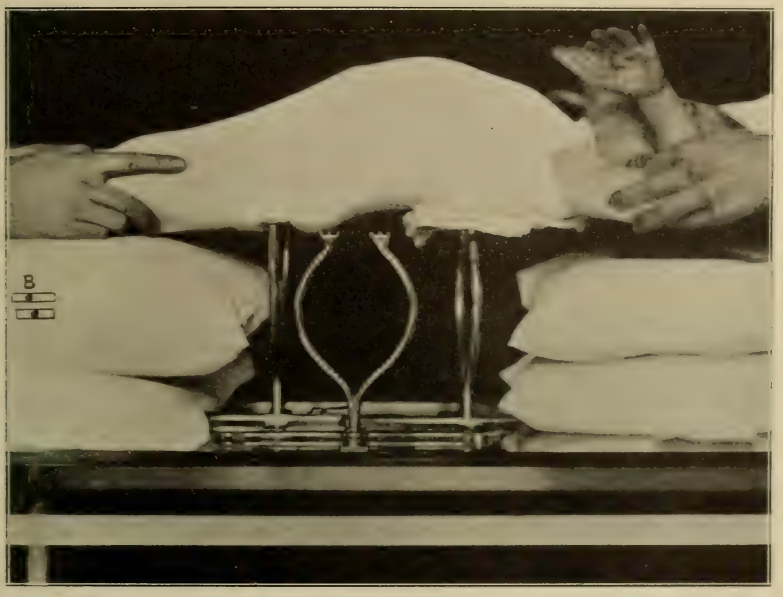

The application of the jacket in the recumbent posture by means of the Goldthwait appliance. *A*, the support, similar to that upon which the patient is lying; *B*, two thin bands of steel, similar to those used in the Taylor brace.

FIG. 55.



R. Tunstall Taylor's apparatus for the application of the plaster jacket in the recumbent posture, consisting of an adjustable back support and pelvic rest connected by a sliding bar. (See Fig. 56.)

The Application of the Jacket in the Recumbent Posture. The jacket may be applied while the patient lies extended in the prone posture, by the *hammock* method suggested by Davy, of London.

A long, narrow strip of cotton cloth is passed under the shirt and is drawn tight enough, by means of a pulley or by manual traction, to support the child in the proper attitude, preferably, of course, in overextension. An opening is cut for the face, and, if advisable, traction may be made on the arms and legs of the patient. The bandages are then applied in the ordinary manner, after which the cloth may be cut short at one end and removed.

This method is of service in the treatment of weak or paralyzed patients, but the adjustment is somewhat less accurate than by the ordinary method. The jacket may be applied in the supine posture by means of the *Goldthwait* apparatus. This may be employed with advantage in the routine application of the plaster jacket, and it has supplanted in some degree the suspension method.

FIG. 56.

The Taylor appliance in use, showing the hyperextension of the spine. The plaster jacket having been applied, the back rest is removed by pressing the bandages from side to side or by enlarging the opening. If desirable, the defect is then concealed by a turn of plaster bandage.

This consists essentially of a support (Fig. 54) carrying on its upper extremities two thin strips of perforated metal. To these strips, felt is attached, forming pads similar to those used on the back brace. The patient is then placed with his back resting on the pads at the seat of the disease. The buttocks and the head are allowed to sink downward to the point of toleration, thus an extending force is exerted on the spine. The plaster bandages are then applied in the usual manner about the body on either side of the support. When it is completed the patient is lifted from the support, the pads being included, of course, in the jacket. An opening remains at this point that may be closed if desirable by an additional bandage.

Other supports of a similar nature are in use, but as they do not differ from it in principle a detailed description is unnecessary (Figs. 55 and 56).

The Application of the Jacket to Patients who have been Treated on the Stretcher Frame. A satisfactory method of applying a plaster jacket in young subjects, when the deformity has been corrected in whole or part by recumbency on the frame in the over-extended position, is the following: The patient is suspended face downward in the horizontal position by two assistants, one holding the arms and the other the thighs; thus, a certain amount of traction is exerted, while the weight of the body tends to over-extend the spine.

In this attitude a jacket is quickly applied, and the child is at once replaced upon his frame, which has been protected by a rubber sheet (Fig. 57). The plaster jacket, during the hardening process, must conform to the habitual posture of recumbency. The pressure pads of the frame indent the bandage on either side of the spinous processes (Fig. 58), and thus afford better support and fixation. This is a very satisfactory method of apply-

FIG. 57.



The stretcher frame on which the patient is replaced while the jacket is hardening.

ing the jacket in this class of cases, because it is not necessary to retain the child in an uncomfortable position while the bandage is hardening, and because accuracy of adjustment in the best possible attitude is assured.

These methods, in which the object is to overextend the spine, are especially indicated in cases in which the deformity is slight. If it is fixed and well marked, suspension is preferable.

As a rule, a jacket may be worn for two months, although not infrequently it may remain for six months, or even longer, and yet be fairly efficient. Usually one jacket is removed and another applied on the same day, but if the skin is at all sensitive it is well, after the washing and powdering, to reapply the old jacket, closing it with adhesive plaster, and allow an interval of a few days before applying the permanent one.

The Plaster Corset. In the stage of recovery the jacket may be replaced by a corset. A jacket, made and trimmed as already described, is cut down the centre and removed from the body. It is carefully readjusted to its former shape, bandaged with the cut surfaces in close apposition, and is thoroughly dried or baked. All wrinkles are then cut away from the inner surface, and extra padding is applied if necessary; the shirt is drawn tightly about the borders of the jacket and strips of leather provided with hooks are sewed in front so that it may by laced like an ordinary corset. It may be removed from time to time to allow for bathing, but it should always be removed and reapplied while the patient is suspended or in the recumbent position.

FIG. 58.

Jacket applied by the stretcher method, showing the depressions on either side caused by the frame pads.

The corset is sometimes used in place of the jacket during the active stage of the disease, but it is less effective, since the repeated stretching during removal and reapplication weakens the appliance and impairs the accuracy of adjustment. In addition, one of the strongest arguments in favor of the use of plaster of Paris, that treatment is under the control of the surgeon, is nullified.

Comparison of the Two Forms of Ambulatory Support. The most severe criticisms of the jacket have been made by those unfamiliar with its use, on theoretical grounds rather than from actual observation. While it may be admitted that there are certain objections to the support, yet experience has shown that when it is applied in a proper manner under proper conditions it is a thoroughly reliable, efficient, and often indispensable means of treatment. Indeed, it may be stated that by means of the jacket and the stretcher frame it is possible to treat nearly every case of Pott's disease without the aid of the professional brace-maker, and with success.

It is evident, however, that under certain conditions the jacket must be inferior to the brace, in early childhood for example, when the pelvis is not sufficiently developed for proper support. Again, when the disease is low down, at or near the lumbosacral junction, the lower border of the jacket does not hold the pelvis with sufficient security to provide the proper fixation. In the upper dorsal region the attachments for accurate fixation may be adjusted more readily to the brace, and in disease of the cervical region the metallic head support is to be preferred to the halter of the jury mast, for the reason that it cannot be removed by the patient. The traction of the jury mast is very effective when properly used, and particularly so when painful distortion of the head is present, but the tension on the straps is rarely constant, and thus loses in efficiency. A rigid support is, of course, preferable in the disease of the atlo-axoid region.

The jacket is most serviceable in the region from the tenth dorsal to the second lumbar vertebra. It is not only effective, but it is often a more comfortable support than the spinal brace. It is more efficient than the brace when lateral deviation of the spine is present; and from the clinical standpoint it is often more efficacious in relieving pain in this region when the disease is at all acute. One may conclude, then, that each form of support may be used according to the indications. The absolute control of the treatment, assured by the use of the plaster jacket, will often overbalance the claims of the brace. In practice among the poor, when choice of means is not always permitted, it is indispensable; and it may be used with fair success even under conditions that theoretically contraindicate its employment.

Modifications of the Jacket. Occasionally, the form of the jacket may be changed to meet special indications; for example, backward traction may be secured by carrying the bandages over

the shoulders; or the head may be fixed in the support, if the jury mast is not at hand (Fig. 59); or one or both thighs may be included in a spica jacket in painful disease of the lower region, when psoas spasm is present. Such modifications are required rather for emergencies than for continuous treatment.

Dr. H. L. Taylor has recommended what he calls the bivalve plastic splint of plaster of Paris.

"A paper pattern of the posterior valve is made from the patient's back, allowing one inch extra around the edge to be

FIG. 59.

Plaster bandage including the head to hold the spine in the extended position, as applied for disease of the upper dorsal region.

folded back. From this pattern eight or ten thicknesses of crinoline are cut of the same size and shape. The patient being supported face downward on a rest under the pelvis and another under the upper part of the sternum, the crinoline sheets are dipped into plaster cream in a large flat pan, applied to the back, the felt pads being in position; the edges are folded back for greater rigidity and the whole carefully moulded to the patient

and allowed to set, after which the patient is turned on his back and the anterior valve made in a similar manner.

"The support should be made firm and rigid, especially at the edges, and should reach in front from the pubes to the top of the sternum. Such an apparatus is rigid, removable, and adjustable, and brings the pressure to bear on definite areas selected with regard to its mechanical action. The splint may be removed to cleanse the back or to note its efficiency, taking the impressions made by the felt pad either side the spinous processes as a guide. If more leverage is needed, the felting may be reinforced or the depth of casing reduced by paring the lateral edges. In other words, the jacket has ceased to be mainly a casing and has become a mechanism under the surgeon's control and capable of being manipulated to produce definite mechanical results."

Corsets of Other Material Than Plaster of Paris. Corsets of wood, leather, paper, poroplastic felt, and celluloid are sometimes used. These are constructed on a plaster cast of the body, a thin, accurately fitting jacket being used as a mould.

FIG. 60.

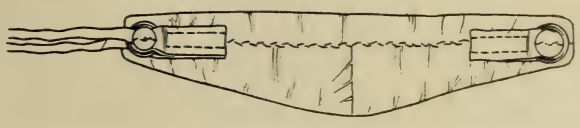

The Thomas collar of leather stuffed with cotton. (Ridlon and Jones.)

Such corsets have certain advantages of durability and elegance, but none of them has the accuracy of fit of the plaster-of-Paris corset, which is moulded directly on the body by constant manipulation during the stage of solidification. Corsets of this class are usually somewhat expensive, and on that account are often worn after they are outgrown or when they no longer fit the patient. Their use is practically limited to the stage of recovery or for other affections than Pott's disease.

Of these corsets, one of the best is that used by Weigel, of Rochester, made of alternate layers of linen cloth and wood-pulp matrix paper, fixed by a mixture of paste and glue.

A more durable corset may be constructed of aluminum, as suggested by Phelps. This may be obtained in thin sheets, which may be hampered upon a metal cast of the trunk into the proper shape. The two halves are attached by hinges in the back and are perforated to allow for ventilation.

In the final stage of treatment, the Knight brace, a light steel

frame with corset front, may be employed (Fig. 143) or a long corset similar to that ordinarily worn by women, but strengthened by the insertion of light steel bars along the spine, may be sufficient.

Other Forms of Support. In certain cases of disease of the lower lumbar region of the spine it may seem advisable to restrain the movements of the thighs, although ordinarily, when this is necessary, ambulation should be discontinued. Such restraint may be attained by making the back bars of the brace stronger and extending them down the back of the thighs to the knees like a double Thomas hip brace.

If the jacket is used it may be extended to a single or double spica for the same purpose as has been mentioned. Such appliances are useful when psoas spasm and "cramp" are troublesome symptoms.

FIG. 61.

The Thomas collar for permanent use. A piece of thin sheet metal is cut wide enough to reach from the sternum to the chin, and from the back of the neck to the base of the occiput. The edges are turned out and the whole properly covered with felt and fitted. (Ridlon and Jones.)

In disease of the cervical region a certain amount of support and fixation may be obtained by collars of poroplastic felt, plaster of Paris, or other material. The *Thomas collar* (Figs. 60 and 61) is the best of this type of support, but none of them is thoroughly efficient unless used with a brace to control the larger movements of the spine. They are useful in emergencies, but they are not often required when proper braces can be obtained.

Many other forms of apparatus of greater or less merit might be described, but space has permitted only a detailed account of three forms that, it would seem, best represent the essential principles involved in the treatment of Pott's disease.

The Principles of Treatment in Their Practical Application. After the description of the special forms of appliances used in the routine treatment of Pott's disease, one may consider with advantage the treatment in its more direct relation to the patient. The object of this treatment is to relieve the symptoms, to main-

tain and to improve the vital resistance of the patient, to check, to remedy, and to prevent deformity. Under favorable conditions the death-rate is small, and pain is easily relieved, but prevention of deformity is often extremely difficult

The effect of treatment must be estimated not simply by its relief of the symptoms of the disease, since deformity may steadily advance in spite of the apparent well-being of the patient, but it must be selected and continued or changed with the aim of combating ultimate deformity, and on this standard success or failure must be determined. It is probable that noticeable deformity

FIG. 62.

The Thomas collar applied. (Ridlon and Jones.)

might be prevented, nearly always, if treatment were applied in season. But practically such opportunity is not often offered, and the local deformity that represents destruction of bone may be considered as irremediable. There is also a dwarfing and blighting effect of the disease, which, although it is usually associated with marked deformity, is always to be feared, particularly when the disease affects the middle or lower region of the spine in early childhood, and is severe and prolonged in its course. By proper treatment one may hope to check the progress of the disease and even to remedy the deformity in great degree by freeing the spine from the deforming influence of local disease, and

by preventing or removing the symptomatic distortions such as psoas contraction or wryneck.

Indications for Treatment by Recumbency. As has been stated already, the most important influence toward deformity when the spine has been weakened by disease is the force of gravity; therefore, horizontal fixation in overextension is the most efficient means of preventing deformity, and it assures the rest for the diseased spine that favors repair.

FIG. 63.

Pott's disease of the middle dorsal region, a type of disease in which horizontal fixation is always indicated. H. S., aged fourteen months.

This is always the treatment for emergencies and in many instances the treatment of choice and routine. It is indicated as the routine treatment in infancy and in early childhood up to the age of three years at least.

In many instances absolute recumbency may not be required, but the period of activity must be carefully regulated, and must be discontinued when there is evidence of discomfort or weakness or pain. If the period of activity must be short, it should be passed in the open air. The passive attitude of sitting, although less strain is thrown upon the spine than during activity, may be

even worse for the patient; thus, the reclining or semi-reclining posture should be assumed as a rule, when the child is in the house, at least during the active stage of the disease. Even if the spine appears to be perfectly supported, the time spent in bed should be long, and a period of rest in the middle of the day should be enforced.

The arguments in favor of horizontal fixation in early childhood do not apply to disease in the adult. At this stage the structure of the spine is resistant, and deformity is little to be feared, while such confinement would be irksome and impracticable; thus, local support, supervision, and, if possible, a change

FIG. 64.

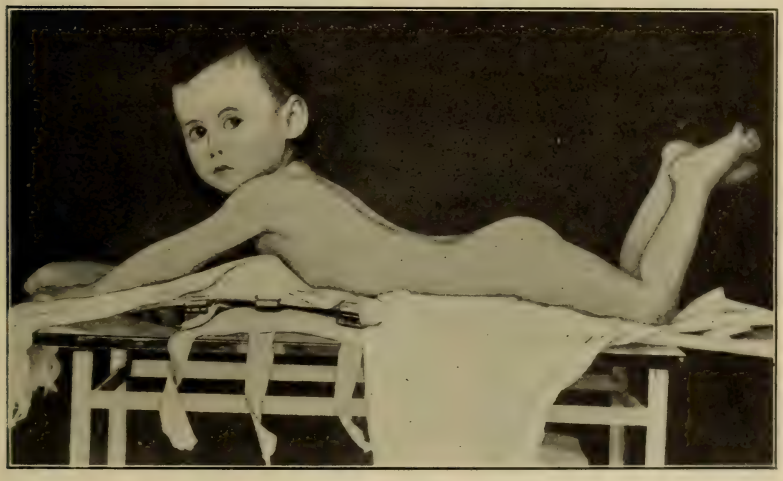

H. S., after fourteen months of fixation on the modified Bradford frame, shows the recession of deformity. Compare with Fig. 63.

of climate, must be the treatment of selection for the adolescent or adult.

In the middle period of childhood, from the fifth to the tenth year, horizontal fixation is the treatment for emergencies; for paralysis, for abscess, for dangerous disease of the atlo-axoid region, for progressive deformity, and for pain that cannot be relieved by the ordinary means.

Special Indications for Treatment of Disease of the Different Regions of the Spine. In the selection of treatment, and in the general management of Pott's disease, each region of the spine must be judged by itself, since in each there are special difficulties to be met, and complications to be feared that may

L. of C.

influence the prognosis and lead to modifications of the routine of treatment.

The Lower Region. The prognosis is good in disease of the lower region, the symptomatic attitude is favorable, the part may be supported easily, the cases are often seen before the deformity is at all extreme, and one may, as a rule, predict recovery without noticeable deformity, at most, but a slight shortening and broadening of the body and a peculiar erectness of attitude. Uncomplicated cases may be treated with the brace or jacket. The brace is the better support when the disease is near the sacrum, while the jacket is often more comfortable and more effective than the brace when the middle or upper lumbar region is diseased, particularly when lateral deviation of the spine is present. Whenever the tendency to psoas contraction is at all marked or when pain or cramps in the legs are complained of, the period of activity should be carefully restricted; in fact, the "night cry" is an indication for a day of rest in bed.

FIG. 65.

Final result of lumbar disease; spontaneous absorption of abscess, and but slight deformity. (See Fig. 13.)

The most troublesome complications of this region are psoas contraction and the abscess with which it is often combined.

As has been stated, psoas contraction changes the attitude of over-erectness, favorable to repair, to a forward stoop that increases the pressure and friction at the seat of disease. If this attitude persists and if it becomes fixed by permanent changes such as are likely to follow the burrowing of a pelvic abscess, most disastrous deformity may follow; the body and the thighs are approximated and the erect attitude is made impossible. In neglected cases of this character, tenotomy and forcible correction or even subtrochanteric osteotomy may be necessary to overcome the

secondary deformity. In ordinary cases of psoas contraction, and when one limb only is flexed, the patient may be allowed to go about using a high shoe on the unaffected side, and crutches, so that the flexed leg need not affect the attitude. If, however, the contraction persists, it is well to place the patient on a frame, and to reduce the flexion by traction in the line of deformity, as will be described in the treatment of disease of the hip-joint. Persistent psoas contraction is almost always a symptom of abscess about the origin or in the substance of the muscle, and when it is accompanied by pain it is always an evidence of progressive disease.

Abscess may be expected as a complication in at least 50 per cent. of the cases of disease of this region, but it is by no means always accompanied by psoas contraction, any more than psoas contraction is always caused by abscess. Abscess unaccompanied by contraction more often has its origin above the lumbar region, and in its descent it passes along the surface without involving the substance of the muscle.

Attention is especially called to the fact that the bad results of Pott's disease of this region are caused almost invariably by allowing psoas contraction, whether it be symptomatic of abscess or not, to persist; therefore, the importance of preventing and correcting this deformity cannot be overestimated. It should be stated, however, that in dispensary practice, when special care cannot be provided, one often sees psoas contraction that may have persisted for months relax, if the progress of the disease is favorable, without treatment other than the routine fixation of the spine by the brace or jacket.

The Lower Dorsal Region. Disease of the lower dorsal region is very favorably situated for effective mechanical treatment, and psoas contraction and abscess are much less troublesome than in the lower part of the spine.

Deformity sometimes increases, almost imperceptibly, by a progressive forward bending or lordosis of the flexible lumbar spine below the projection. One must guard against this by applying the jacket firmly while the spine is made as straight as possible, or, if the brace is used, the lumbar spine should be drawn firmly against it.

If lateral inclination of the body is so marked as to interfere with the proper application of a brace, preliminary rest in bed is indicated. Lateral deviation can be corrected, as a rule, by the jacket without recumbency, although this, as other forms of symp-

tomatic distortion, should be treated ordinarily, if not by complete rest, at least by careful regulation of the period of activity.

Disease of the Middle and Upper Dorsal Region. This is, from the standpoint of prevention of deformity, the most difficult region of the spine to treat, although the symptoms of the disease may be easily relieved.

Deformity is present in nearly all cases when treatment is sought, and, deformity having begun, is very difficult to check, for the reasons that have been stated already.

The final result in the majority of cases is what appears to be exaggerated round shoulders; the neck is shortened and projects forward, the chest is flat, and the shoulders are high.

It is only by an early diagnosis and by efficient and long-continued treatment, beginning, if practicable, with horizontal fixation, that recovery from disease in this region without noticeable deformity may be hoped for.

In all cases of disease above the ninth vertebra, the anterior brace for backward traction of the shoulders may be used with great advantage to secure greater fixation of the spine; and in all cases above the seventh or eighth vertebra a head or chin support to restrain the forward inclination of the neck is indicated in addition.

With the plaster jacket the jury mast or posterior support is employed; with the brace the looped chin rest or the ordinary Taylor support may be used.

In disease of the upper dorsal region the brace is to be preferred to the jacket, because of the greater accuracy of adjustment, and because the halter of the jury mast is rarely retained in proper position when the patient does not, as in these cases, feel the need of such support.

In this region of the spine *paralysis* frequently occurs as a complication. When it appears after treatment is begun, it is usually a result of inefficient fixation of the spine or of want of caution in regulating the strain to which the diseased part is subjected. Its symptoms and its treatment will be considered later.

Disease of the Upper Dorsal and Middle Cervical Region. This is the most favorable region of the spine for treatment. The disease is usually not extensive because of the small size and compact structure of the vertebræ; and the mobility of the cervical region is so great that it readily compensates for the local rigidity.

Under efficient treatment one may predict recovery without

noticeable deformity, and in the less successful cases the deformity is not, as a rule, offensive. The shoulders appear high, the neck is short, the head inclines forward, while the back is abnormally flat in compensation for the change in contour of the part above.

When the case of cervical disease is first brought for treatment a *wryneck* deformity, often made more persistent by the infiltration of an abscess or by enlarged cervical glands, is almost always present. As a means of correcting this distortion, the jury mast and traction halter, attached to the jacket or brace, is a very efficient and comfortable support. Under the constant tension the deformity may be corrected with ease, but as a permanent treatment the brace and head support are to be preferred to the jury mast, because a more exact fixation is assured.

Disease of the Occipito-axoid Region. Under efficient treatment the prognosis is good, and recovery without deformity should be the rule. The course of the disease, although it is often accompanied by acute symptoms, is usually short, as compared with that of other regions of the spine. It may be assumed that, in many cases, it is a primary arthritis, or, at least, that the primary focus in the atlas or axis is very small. The disease at this point is, however, in close proximity to the vital centres, and sudden death from displacement of the weakened parts is not uncommon. Abscess is frequent, and it is often a troublesome and dangerous complication.

As has been mentioned, wryneck deformity is a very constant symptom, and there is also a strong tendency toward a forward and downward inclination of the head, so that in neglected cases the chin may rest upon the chest. The indications for treatment are to overcome the distortion and to hold the head fixed in the middle line, the chin being somewhat elevated above the right-angled relation with the spine. In the mild cases the jacket with jury-mast traction may be used to overcome the distortion, but the metallic head support with the fixation attachment to prevent motion in the diseased joints, is always indicated as the treatment of selection, because by such apparatus the danger of displacement may be avoided.

When the disease is acute in character, and especially if abscess is present, recumbency on the frame with fixation of the head and slight traction by the weight and pulley, or by the jury-mast attachment, is indicated. Traction should not be sufficient to cause discomfort; counter-traction may be supplied by the weight

of the body and by slight elevation of the head of the bed. The head sling may be that used with the jury mast, or a simple band about the head may be used. Under this treatment slight deformity of any part of the cervical region will practically disappear, and, as a rule, the course of the disease is very favorably influenced by the period of complete rest.

In certain cases of disease of this region, accompanied by acute symptoms, the attitude of recumbency is extremely uncomfortable. The discomfort is caused apparently by the forward projection of the upper part of the spine, so that when the head is drawn upward and backward in the recumbent attitude the calibre of the throat is lessened. In other instances the pain may be due to pressure of the atlas against the odontoid process of the axis. In such cases, if recumbency is desired, the head must be elevated by pillows to the point of comfort, the support being removed when the child has become accustomed to the position, or when the deformity has been corrected.

The Complications of Pott's Disease. **Abscess.** It may be assumed that a limited collection of tuberculous fluid is present at some time during the course of Pott's disease in the great majority of cases, but unless it appears as a palpable tumor above or below the thorax or upon the surface of the body its presence is not often detected.

Townsend,[1] in 380 cases of Pott's disease examined with reference to the occurrence of abscess as a complication, found that it was present or had been detected in 75 (19.7 per cent.); in 8 per cent. of the cases of cervical disease; in 20 per cent. of the dorsal, and in 72 per cent. of those in which the lumbar region was involved.

Dollinger,[2] in 700 cases under treatment from 1883 to 1895, found abscess in 154 (22 per cent.); in 13 of 63 cases in the cervical region (22.6 per cent.); in 47 of 403 cases in the thoracic region (11.6 per cent.), and in 94 of 234 cases of lumbar disease (40.17 per cent.).

Ketch,[3] in 75 cured cases of Pott's disease treated at the New York Orthopedic Dispensary, selected for the purpose of contrasting the behavior of the disease in the different regions of the spine, found that abscess had appeared in 19 (25.3 per cent.). In the upper region abscess was detected in but 1 of the 25 cases

[1] Transactions American Orthopedic Association, vol. iv. p. 166.
[2] Loc. cit.
[3] Transactions American Orthopedic Association, vol. iv. p. 200.

(4 per cent.); in the middle region in 8 of the 25 cases (32 per cent.), and in the lower in 10 (40 per cent.).

In 354 autopsies by Mohr, Nebel Bouvier, and Lannelongue abscess was found in 281, or nearly 80 per cent. Although cases of Pott's disease that come to autopsy may be supposed to represent a severe type of disease, yet it is evident, by contrasting the statistics, that a large proportion of the abscesses escape detection in the living. One may conclude, then, that abscess may be expected as a more or less serious complication in 25 per cent. of all cases of Pott's disease, and in at least half of those in which the lower region of the spine is involved. The greater frequency here is explained by the large size and less resistant structure of the vertebral bodies, as compared with those of the upper regions.

The tuberculous abscess is separated from the neighboring parts by a limiting wall varying in thickness according to its age, the outer layers of which are of fibrous and cellular tissue, the inner of granulation tissue covered with yellowish-gray or pinkish-gray, necrotic membrane, which is easily separated from the underlying parts. The fluid of the abscess is usually of a whitish or whey-like color, composed of serum, leucocytes, and emulsified caseous material and fibrin. Floating in it are large masses of cheesy, necrotic tissue and sometimes minute fragments of bone, which settle to the bottom of the glass if the fluid is allowed to stand. Certain of the smaller quiescent abscesses contain only this whitish semi-solid material. The fluid of abscesses in process of resolution is often clear, like serum, but if secondary infection has taken place the pus is of a greenish-yellow color, and is of uniform consistency. At any stage of its progress the abscess may become stationary and its contents may be absorbed, in fact, such an outcome is not unusual. The fluid of the abscess is usually sterile, and secondary infection, before a communication with the exterior of the body is established, is comparatively uncommon.

It has been claimed that abscess formation is always the result of infection with pyogenic germs, but this may be doubted, since the ordinary tuberculous abscess may be sterile or at most contain but a few tubercle bacilli. It is certain, on the other hand, that the formation and increase of the abscess is favored by irritation and injury, and that the most effective treatment of this complication is to support the diseased spine and to relieve it from overstrain.

Abscess is a symptom of disease, and it is in some degree an

evidence of its character. If it appears early and increases in size rapidly, it usually indicates a destructive and rapidly advancing process, or infection from without. On the other hand, the slowly enlarging or quiescent abscess has but little significance.

In many instances the abscess causes no symptoms whatever, or it may be a source of inconvenience simply because of its size or situation. In other cases a period of malaise or discomfort or pain is followed and explained by the appearance of an abscess, but whether the symptoms are caused by the tension of the abscess or by a more acute phase of the disease itself is not always clear.

Large abscesses that are increasing in size and approaching the surface are usually accompanied by pain and by elevation of temperature. This indicates, probably, a slight degree of secondary infection, but the ordinary deep abscess appears to have no other effect than to add, doubtless, to the susceptibility of the patient.

The Course and Peculiarities of Abscess in the Different Regions of the Spine. The tuberculous abscess may remain as a small collection of fluid in the neighborhood of the diseased area. As a rule, however, it slowly increases in size, and under the influences of the force of gravity and the tension of its contents it finds its way down the spine or toward the exterior of the body, following the path of least resistance. The abscesses which have passed below the diaphragm or which have originated below this point may follow various paths. Some enter the sheath of the psoas muscle, and, finally, make their appearance on the inner aspect of the thigh, *psoas abscess*. Others perforate the sheath of the quadratus lumborum muscle and form a *lumbar abscess*, projecting between the twelfth rib and the crest of the ilium at the triangle of Pétit. Those abscesses that escape from the fascia of the psoas muscle or that pass downward on the surface of the iliac fascia, the so-called *iliac abscesses*, may appear as a tumor over the outer extremity of Poupart's ligament at the junction of the transversalis and iliac fasciæ, or the fluid may follow the course of the iliac artery to the thigh, or, escaping from the greater sacrosciatic foramen, form a *gluteal abscess*.

Iliac or psoas abscess is most often confined to one side, but it may be bilateral, the two sacs communicating with one another by a larger or smaller channel. In the *thoracic region* the abscess may remain indefinitely in the posterior mediastinum, where, if large, its presence may be demonstrated by an area of dulness

extending toward the lateral region of the thorax, or it may perforate the intercostal muscles and appear on the posterior or lateral aspect of the chest, or it may pass downward through the aortic opening in the diaphragm and become an iliac abscess.

Abscess caused by disease of the *occipito-axoid* region may force its way forward between the recti muscles and appear behind the pharynx as the retropharyngeal abscess, or the fluid may take

FIG. 66.

Bilateral lumbar abscess.

the opposite direction and distend the suboccipital triangle and then pass forward to the region of the mastoid process. In other instances the abscess may dissect its way about the base of the skull or pass upward through the foramen magnum or downward into the spinal canal.

Abscesses from the *middle cervical region* usually pass outward between the scaleni and longus colli muscles to the interval between the trapezius and sternomastoid, perforating the skin about the middle of the lateral aspect of the neck near the anterior border of the latter muscle.

These are the paths usually followed by the tuberculous fluid, but occasionally it may enter the spinal canal or break into the pleural cavity or lung or intestine or by the side of the rectum or elsewhere.

Treatment of Abscess. Abscess is by far the most troublesome and dangerous complication of Pott's disease. It may interfere with proper mechanical treatment, and it is often a cause of permanent as well as temporary deformity, especially in the lower region of the spine, as has been stated. It prolongs the course of the disease by extending its boundaries, and, although it is not often a direct cause of death, yet many patients die because of the exhaustion of long-continued suppuration that may follow secondary infection, and of the amyloid degeneration that may finally result.

A large abscess is always a source of danger because of the possibility of secondary infection of its contents before it finds an outlet, and because of the probability of infection when a communication with the exterior has been established. Abscess is, however, a symptom and result of disease, and in properly treated cases it is, as a rule, a complication of comparatively slight consequence. If it is not present when treatment is begun, one may hope to prevent it by effective protection of the spine, and if it is present, this protection should be all the more rigidly enforced. An abscess often exists for months before its presence is detected, and after its discovery it may remain quiescent for a long time, and finally disappear.

In a very large proportion of cases the abscess causes no symptoms, but slowly finds its way to the surface of the body. Meanwhile it may be assumed that the disease of the spine, of which the abscess is a result, is in process of cure; so that when the fluid finds an outlet the source of supply will be shut off, and thus the patient is spared the danger and discomfort of discharging sinuses, that so often persist after early operation.

The so-called radical treatment of the abscess of spinal disease is unsatisfactory, not because this is different in character from other tuberculous abscesses, but because it is, as a rule, impossible to remove the disease of which the abscess is a symptom; and incomplete or ineffective surgical operations should be avoided.

As the abscess is a symptom of disease, so, as a rule, its treatment should be symptomatic. The *retropharyngeal abscess* demands prompt evacuation, because it is likely to obstruct breathing and swallowing, because its sudden rupture may cause

death, and because an abscess in such close proximity to the vital centres is always a source of danger. In cases of emergency the abscess may be evacuated by an incision in the middle line of the pharynx, but preferably the opening should be from the exterior. An incision is made along the posterior aspect of the sternomastoid muscle in its upper third. The abscess tumor is easily reached by careful dissection, and drainage is established which has evident advantages over that into the throat.

Abscesses from the *middle cervical region* usually point in the lateral region of the neck and cause but little inconvenience. Abscesses in the *upper thoracic region* may, in rare instances, cause dangerous pressure on the trachea or lungs, as shown by spasmodic attacks of inspiratory dyspnœa, "asthmatic attacks." In some instances an area of dulness near the seat of disease demonstrates the position of the abscess, but if it lies in the median line it cannot be detected either by auscultation or percussion. If the inspiratory dyspnœa is well marked the symptom may be fairly attributed to this cause, and if the spasmodic attacks are frequent and severe the operation of *costotransversectomy* is indicated. An incision is made, preferably on the right side, to expose the articulation between the transverse process and the rib, and one or more of the joints are resected; the finger is then inserted and passed along the surface of the adjacent vertebral body until the abscess sac is reached. This is usually directly in front of the spine at or about the fifth dorsal vertebra. After incision a large drainage-tube should be inserted (Fig. 9).

In the lower region of the spine intervention may be necessary because there is evidence of *secondary infection*. In this event if the abscess distends the lumbar region or forms a sac on either side of the spine, an opening in the loin on one or both sides of the spine is necessary. This is made as in operations on the kidney, by an incision on the outer side of the erector spinæ muscle between the last rib and the crest of the ilium. In certain cases it is possible to expose the spine and to remove fragments of necrosed bone along with the contents of the abscess. As a rule, the complete removal of the lining membrane of the abscess is not practicable, and one must be content to evacuate the solid and semi-solid contents by flushing with hot water, together with as much of the abscess membrane as may be removed by swabbing with gauze. The most important point in the operation is to provide efficient and complete drainage of the cavity. Two or more counter-openings are usually necessary

when the lumbar incision has been made, one just in front of the anterior superior spine and another in the thigh, if the abscess is of the psoas variety. Long drainage-tubes are inserted, and should remain until a proper channel for the escape of pus has been established.

When the abscess is of one side only, not extending into the thigh, and when the symptoms do not indicate infection, but when its evacuation seems advisable because of its size and tension, it may be opened by an anterior incision below Poupart's ligament just to the inner side of the sartorius muscle. After copious injections of hot water a drainage-tube may be inserted long enough to reach to the seat of disease if it be of the lumbar region.

In after-treatment irrigation is not often required; the dressing should be of dry sterile gauze, and great attention should be paid to absolute cleanliness and to effective drainage. As soon as is possible, if the discharge has become slight and if the spine can be properly supported, the patient is allowed to walk about and to go into the open air. In ordinary cases a slight discharge will persist for several months or longer, depending on the condition of the disease; if, however, it be quiescent or cured the sinus will close promptly.

In the symptomatic treatment of abscess, *aspiration* is sometimes of service, for by this means it may be prevented from increasing in size; and if the disease is quiescent, the cure of the abscess may follow the removal of its contents which allows the collapse of its walls. When aspiration is employed it should be repeated systematically as often as the abscess cavity refills. After each evacuation pressure should be applied to favor the adhesion of the apposed walls.

When the contents are of such a nature that aspiration is ineffective, an *incision* may be made, through which the semi-solid substance may be removed by vigorous flushing with hot water. The opening is then closed by several layers of sutures, and pressure is applied with the aim of obtaining primary union. This method is sometimes successful, but usually a sinus forms later at the point of incision.

Until recently the *injection of antituberculous remedies* into the abscess sac was in favor. This is probably of value in diminishing the infective quality of the contents, perhaps, also, in lessening the danger of mixed infection and in stimulating the reparative processes. Clinically, it appears to have little direct

effect upon the course of the tuberculous disease. An emulsion of iodoform in sterilized oil or glycerin (10 to 20 per cent.), in doses of from 4 to 30 grammes, is injected at intervals of from two to four weeks, with or without previous evacuation of the contents; the amount and the frequency of the injection depending upon the age of the patient and upon the effect of the treatment. If used with caution as to asepsis, and to the toleration of the patient for iodoform, no harm will follow, even if the treatment proves to be of little practical value.

When an abscess approaches the surface the skin becomes red and thin, and there is usually some local tenderness and pain. Whenever spontaneous evacuation of the abscess is probable the mother should be instructed as to the necessity of absolute cleanliness, and the proper dressings should be provided. After the abscess has broken the patient should remain in bed for several days, or until the discharge has become small in amount.

In the symptomatic treatment of the abscesses of Pott's disease one may conclude, then, that operation will be indicated in the treatment of the retropharyngeal abscess and in the rare instances when dangerous pressure is exerted by an abscess in the posterior mediastinum. It is indicated, of course, when there is evidence of mixed infection or when the rapidly increasing abscess causes discomfort or interferes with effective support. It is usually indicated when the abscess is of large size if proper care can be provided. The operative treatment is practically free from danger if cleanliness and efficient drainage can be assured. Aspiration is free from danger; it is often of service in preventing the enlargement of the abscess, and it may hasten its absorption. An incision which allows for the evacuation of the solid material, followed by immediate closure of the wound, is in many instances the operation of selection.

Paralysis from Pott's Disease.

The tuberculous process in the vetebral bodies may extend backward, and breaking through the posterior ligament it may enter the epidural space and press upon the spinal cord; then follows paresis or paralysis of the parts below the constriction.

The calibre of the spinal canal is not usually lessened by the characteristic angular distortion of the back, although the weight and forward inclination of the trunk may force the softened tissues backward against the cord and thus increase the direct

pressure; in fact, paralysis is much more often associated with a slight or moderate kyphosis than with extreme deformity.

In rare instances the pressure may be due to a fragment of necrosed bone or to solidification of the tissues in and about the canal during the process of repair. It may be caused, in part, at least, by the pressure of a neighboring abscess, but it is usually the result of the slow advance of the tuberculous granulation tissue. When this has forced an entrance into the spinal canal it sets up a resistant inflammatory thickening of the coverings of the cord, first a peripachymeningitis and then a pachymeningitis. In addition to the direct pressure, there may be an interference with the blood supply and the lymphatic circulation, with resulting local œdema of the cord. An increase in the interstitial connective tissue of its substance and a corresponding atrophy of the nervous elements may follow, and as a sequence an ascending and descending degeneration that, in prolonged cases, may terminate in partial or complete sclerosis. The dura mater is a resistant structure, and direct destruction of the cord by the tuberculous disease is rare. In fact, as a rule, but little permanent damage results, even from long-continued pressure and paralysis, for the cord seems in these cases to possess the power of repair and regeneration to a remarkable degree.

Frequency. In 1670 cases of Pott's disease recorded at the New York Orthopedic Dispensary, paralysis occurred in 218,[1] and in 445 cases in the private practice of Dr. C. F. Taylor[2] 59 cases of paralysis were observed. Thus, in a total of 2015 cases of Pott's disease there were 279 cases of paralysis, or 13.7 per cent.

This proportion is much larger than the normal, however, for many of the patients were taken to the specialist or to the special hospital because of the paralysis, as in 40 of Taylor's and in 133 of the dispensary cases. If these be excluded, the percentage of paralysis occurring in those actually under treatment is reduced to 5.6 per cent. This percentage corresponds very closely to that of Dollinger,[3] viz.: 41 cases of paralysis in 700 cases of Pott's disease under treatment (5.8 per cent.), and it may be accepted as representing the average liability to paralysis among those who have received treatment for Pott's disease, the percentage being much higher in neglected cases.

[1] Myers. Transactions American Orthopedic Association, 1891, vol. iii. p. 209.
[2] Taylor and Lovett. New York Medical Record, June 19, 1896.
[3] Loc. cit.

The Liability to Paralysis in Disease of the Different Regions of the Spine. The liability to paralysis is very much greater in disease of certain regions of the spine than in others.

Thus, 105 of the 209 cases in Myers' list, in which the situation of the disease was recorded, complicated disease of the dorsal region above the eighth vertebra. Of the remainder, in 16 the disease was of the cervical region; in 12 of the cervicodorsal, and in 59 of the lower dorsal and dorsolumbar regions.

Thirty-seven of Taylor's 59 cases were caused by disease of the dorsal region; 8 occurred in the cervical and cervicodorsal, and 11 in the dorsolumbar and lumbar regions.

Twenty-six of the total of 41 cases recorded by Dollinger were caused by disease of the third to the seventh dorsal vertebræ, inclusive, or about 23 per cent. of the cases in which this region was involved.

FIG. 67.

Pott's paraplegia before the stage of deformity. The apparatus used in the treatment of this case is shown in Fig. 51.

Of 132 cases of paraplegia reported by Gibney[1] not one complicated disease of the lumbar region; nearly all were caused by compression in the middle or upper dorsal segment.

These statistics show that the upper and middle dorsal section is the point of greatest liability to paralysis—a fact that is explained possibly by the smaller size of the canal at this point, and by the difficulty in assuring complete fixation at the seat of disease. It may be estimated that in 15 per cent. of the cases of Pott's disease of this region paralysis will appear before cure is established.

Time of Onset. In exceptional cases the paralysis may precede deformity, and it may be the first symptom that attracts

[1] Journal of Nervous and Mental Disease, January 5, 1897.

attention to the disease. In 14 of 74 cases reported by Gibney the paralysis was present when the bone disease was recognized, but it is probable that the primary disease had existed for several months before the appearance of the paralysis. Usually it is a comparatively late symptom, appearing after the stage of deformity and more often from six to twelve months after the recognition of the disease, but its appearance may be deferred until long after apparent cure.

Duration. In exceptional cases the paralysis appears to be caused simply by disturbance of the circulation of the cord, due possibly to the pressure of the superincumbent weight upon the softened and diseased tissues, as it disappears almost immediately when the spine is straightened and supported. Usually the paralysis persists for several months, not infrequently it lasts a year, and partial or even complete recovery is possible after a much longer time. Recovery from the paralysis depends upon the course of the disease of which it is a symptom, upon the absorption and organization of the tuberculous granulations that press upon the cord, and upon the regenerative changes in its structure, if it has been implicated in the disease.

Symptoms of Pott's Paraplegia. The most marked effect of the pressure on the cord is the interference with its conductivity; thus, the reflex centres situated below the point of constriction, relieved from the inhibition of the brain, become overactive, while voluntary motion of the parts below the constriction is difficult or impossible. The pressure of the diseased products is more directly upon the anterolateral columns, so that motion is much more often primarily affected than is sensation.

The early symptoms of Pott's paraplegia, as noticed by the patient or his friends, are weakness, awkwardness, and a stumbling, shambling gait. The symptoms usually increase rapidly until paralysis of motion is complete. At this stage the patella tendon reflex is increased, and ankle-clonus is often present. As a rule, both limbs are affected in equal degree, but occasionally paralysis of one may precede that of the other, and in the stage of recovery power may return more rapidly on one side than on the other. The limbs in the early stage of the paralysis may appear limp and powerless, but when the patient is moved or when the reflexes are stimulated the peculiar spastic rigidity or stiffness appears.

As a rule, the stiffness increases with the duration of the disease, and spastic contractions are often present; thus, the thighs

may be approximated, the knees flexed, and the feet extended. Persistent contractions indicate, as a rule, permanent damage to the cord, and in such cases complete recovery is infrequent.

Sensation is not affected ordinarily, but in the more severe or prolonged cases it may be impaired or lost. Sensation was retained throughout in 24 of the 40 cases reported by Shaffer.

In the cases of partial paralysis control of the bladder may be retained, but usually there is incontinence. As the bladder fills the reflex centre is excited, and it empties itself. The control of the sphincter ani is less often or less noticeably affected.

As the paralysis is the result in many instances of active or of advancing disease, its onset may be preceded by discomfort or pain. Thus, noticeable discomfort attended by an exaggeration of the patella tendon reflex may be considered as an indication for enforced rest of the individual, although increased activity of the reflexes is not uncommon during the more active stage of the disease without apparent involvement of the spinal cord. When paralysis occurs in patients who are under treatment for Pott's disease the onset is not attended, as a rule, by noticeable or unusual pain; nor is pain usually complained of after the paralysis has developed.

The extent of the paralysis depends upon the situation of the disease. In exceptional cases, in which the cervical cord is implicated, both the arms and legs may be paralyzed; this occurred in seven of the cases reported by Myers. As a rule, however, the paralysis is a complication of disease of the dorsal region, above the reflex centres in the lumbar enlargement of the cord, but below the nerve supply of the upper extremities. If the disease were at a lower point, for example, in the dorsolumbar section, so that these reflex centres themselves were directly implicated, then reflex activity would not be increased, and intermittent incontinence would be replaced by constant dribbling of urine. If the cauda equina alone were implicated in disease of the lumbosacral region, the symptoms would be those of neuritis, pain, numbness, and weakness in the area supplied by the affected nerves. Such weakness may be present in the upper extremities when the disease is in the neighborhood of the origin of the brachial plexus, while in the lower limbs the characteristic spastic condition is evident.

The nutrition of the limbs is not as a rule greatly affected, nor do the contractions become permanent; but when the paralysis is prolonged, and when sensation is lost, the muscles waste,

the circulation is impaired, and fixed distortions usually appear. Even in the more prolonged and severe forms of paralysis, occurring in childhood, bedsores are rarely seen.

Prognosis. In properly treated cases the prognosis is very favorable, as is illustrated by the final results of 47 of the 59 cases of paraplegia in Taylor's practice. Of these 39 recovered completely, 5 died of intercurrent disease while apparently recovering, and in 3 the recovery was partial.

Of the hospital cases recorded by Myers, 3 per cent. died of intercurrent disease. The final results could be ascertained in but 55 per cent. of the patients who remained under treatment. All of these recovered.

Of 74 cases of paraplegia treated by Gibney[1] 45 were cured, 12 improved, 8 unimproved, and 9 died. Thus, 77 per cent. were cured or improved. In a similar series of 40 cases reported by Shaffer 80 per cent. were cured and but 10 per cent. of the remainder were considered as hopeless cases.

In a total of 975 cases "abandoned to medical treatment" collected from various sources by Rozoy,[2] there were 429 cures. Of the remainder 16 were improved; 130 were unimproved, and there were 244 deaths. The contrast in the results reported would appear to show the advantage of thorough mechanical treatment.

Recurrence of paralysis after recovery is not infrequent; in 18 cases such recurrences from one to four times are recorded by Myers, and seven successive attacks of paralysis were observed in a patient under treatment at the Hospital for Ruptured and Crippled.

The relapses are due apparently to the renewed activity of the disease, and in many instances this may be explained by the neglect of protective treatment.

Treatment. The treatment of the paralysis is included in the treatment of the disease of which it is a symptom, except that even greater care should be exercised to assure fixation of the spine.

Rest in the position of hyperextension on the stretcher frame is indicated. Direct traction by the weight and pulley should be used if the disease is in the upper dorsal or cervical regions. For bedridden patients a convenient method of assuring extension of the spine in connection with head traction is to suspend the trunk on a sling of canvas drawn transversely beneath the seat

[1] Loc. cit.

[2] Mal. de Pott, Paris, 1901.

of disease and attached to bars on the sides of the bed after the Rauchfuss method. The back brace or the plaster jacket assures additional fixation, and such support should be employed whenever practicable. If, however, the brace has been worn as an ambulatory support, its shape must be modified to accommodate the change in the outline of the spine, induced by recumbency and extension.

Manipulation or massage of the limbs is contraindicated because it stimulates the reflex centres. If constant contractions of the muscles are present, the deformity may be reduced by traction applied in the ordinary manner (Fig. 32), or a fixation brace may be worn. The spasmodic contractions are often painful, and if the paralysis is complicated by tuberculous joint disease, extension and fixation combined may be indicated to relieve the joint from the injury of involuntary motion.

Counterirritation at the seat of disease was by Pott considered of the greatest value, and the application of the actual cautery from time to time, about the kyphosis, seems in certain cases to exert a favorable influence on the underlying disease.

Electricity, particularly galvanism, has been used, and it is of some service in preserving the nutrition of the limbs. Its value in a case must be judged by its effect.

Of the internal remedies the most useful seems to be iodide of potassium. It is supposed to act upon the tuberculous granulation tissue as upon the products of syphilitic disease. A convenient method of administration is a solution of which one drop represents one grain of the drug. This is given in milk or in Vichy water, beginning with five drops three times daily and increasing the dose a drop each day until the point of toleration is reached.

The first indication of improvement is usually lessening of the muscular rigidity; then the ability to move a toe may be regained, after which recovery follows quickly. At this stage massage of the limbs may be employed with advantage. The exaggerated reflexes may persist long after recovery; in fact, as has been stated, this symptom is not uncommon among patients suffering from dorsal Pott's disease who have never been paralyzed.

The Operative Treatment. The operation of laminectomy was at one time in favor, but it has now been practically abandoned, as a treatment of routine at least, for the paraplegia of Pott's disease; because it has been proved that recovery, if somewhat long deferred, is the rule without operation, while the direct

death-rate of the operation is a large one. In 134 cases collected by Rhein[1] the immediate mortality (those dying within a month after the operation) was 36 per cent.

Lloyd[2] has collected 128 "reliable" cases of Pott's disease in which laminectomy was performed. The deaths due directly to the operation were 21 (16.45 per cent.); subsequent deaths, 36 (28.20 per cent.); total deaths, 57 (44.55 per cent.); recoveries, 37 (28 per cent.); improved, 16 (12.5 per cent.); unimproved, 18 (14.06 per cent.).

Laminectomy is an incomplete operation in the sense that the disease of the bone is not removed, and recurrence of paralysis and extension of the disease are not infrequent after a successful immediate result. It should be reserved for those cases in which after a thorough and prolonged trial of ordinary methods the condition does not improve. Eighteen months has been suggested as the proper time in which to test conservative treatment. The operation may be indicated also if the symptoms, in spite of treatment, increase in severity, and when there is evidence that the integrity of the cord is threatened, or when the paralysis is of sudden onset, or when displacement of bone or pressure from an abscess seems probable as the exciting cause, although in the latter instance the direct evacuation of the abscess by costotransversectomy, as advocated by Ménard, should precede laminectomy. Occasionally the operation is indicated as a forlorn hope in adults suffering from cystitis and bedsores.

The usual method in operating is as follows: A long incision is made parallel to and close by the side of the spinous processes. The muscles are drawn to one side, the spinous processes are cut through and drawn with the attached muscles to the opposite side. The laminæ at the seat of disease are then removed with the cutting forceps, exposing the dura mater. The tuberculous tissue is usually found upon the front or lateral surfaces of the canal, and its complete removal is often impossible. The shock of the operation is often marked, so that it should be as rapid as possible, and loss of blood should be carefully guarded against. As a rule, the wound may be closed without drainage. After the operation the spine should be supported by the brace or jacket until the disease is cured.

In several instances forcible correction of the spine (Calot's operation) relieved the pressure on the cord and rapid recovery

[1] Willard. Journal of Nervous and Mental Disease, May, 1897.
[2] Philadelphia Medical Journal, February 22, 1902.

followed. This indicates the importance of assuring overextension of the spine whenever it is possible, but this should be attained preferably by gradual, postural correction rather than by force.

Fortunately, the great majority of cases of paraplegia from Pott's disease occur in childhood, and, as has been mentioned, the complications of later life, bedsores, cystitis, and the like, are rarely troublesome. Such paralysis in the adult is more serious from every point of view. The principles of treatment are the same, but their application is more difficult and the prognosis is more doubtful.

Local Paralysis. In certain cases the extension of the disease may involve the nerve roots at their exit from the spine. This may occur with or independently of the involvement of the cord. The symptoms are those of neuritis in the affected nerves. In extremely rare instances the pressure on the cord may cause hemiplegia.

Forcible Correction of the Deformity of Pott's Disease. Calot's Operation. Forcible correction of the deformities of the spine was advocated by several of the ancient writers, notably by Hippocrates and by Paré, but in modern times, with the better understanding of the pathology of Pott's disease, the direct deformity that a patient presented when coming under treatment was supposed to be irremediable, since it represented actual destruction of bone.

In 1896 this method of forcible correction of deformity which had been revived by Chipault several years before[1] was popularized by Calot, of Berck sur Mèr,[2] who claimed that it was particularly adapted to the treatment of the kyphosis of tuberculous disease. Originally he advocated the immediate correction of such deformity, although of long standing, even if chiselling through the anchylosed vertebræ and removal of the spinous processes were required. This has been abandoned long since, and even the treatment to be described has fallen into practical disuse at least in this country.

At the Eleventh Congress of French Surgeons at Paris in 1897 Calot outlined the operation as follows: In the recent cases the deformity was corrected by direct manual traction and by pressure on the kyphosis. The traction employed was estimated at sixty to one hundred and sixty pounds, the pressure at thirty to eighty pounds, but in the more resistant type it was well to reduce the

[1] Travaux de neurologie Chir., 1895, 1896, 1897.
[2] Archiv prov. de Chir., February, 1897, T. 6, n. 2.

deformity gradually at several sittings. Of 204 patients treated by this method, 2 died within two days and 3 others several months after the operation. In 1 case partial paralysis appeared, and in another an abscess appeared soon after the procedure.

Since Calot's original publication hundreds of operations have been performed with results not differing essentially from those that he reported. It has been demonstrated that the deformity of Pott's disease in more recent cases can be partly or entirely corrected by force in one or more sittings with but little danger to the patient.[1] If the disease is in the progressive stage, and if the operation is undertaken before adhesions and contractions have formed, the correction will be easy. If the disease is in the stage of repair, the correction will necessitate forcible separation of contracted tissues and the breaking up, it may be, of an actual anchylosis. If an abscess is present, whose coverings are adherent to the surrounding parts, the forcible correction may rupture its walls and allow the escape of the pus into the lung or pleural cavity. The more remote dangers are abscess or paralysis due to a direct extension of the local process, or general dissemination of the tuberculous disease.

If the deformity is corrected it is evident that there must be an actual separation of the diseased parts; the spine is, as it were, straightened on the hinge formed by the articulating surfaces of the transverse processes (Fig. 4). This is an attitude favorable to repair, since compression and attrition can no longer aggravate the destructive process. If paralysis is present, induced in part by the compression of the softened tissues at the seat of disease, it may be relieved by the correction of the deformity.

It must be borne in mind, however, that the operation is undertaken for the relief of deformity. It is certain that the spine can be straightened and that it can be retained for a time in the corrected position, but it is unlikely that the interval left between the upper and lower segments of the spine will be filled

[1] Bradford and Cotton (Boston Med. and Surg. Journ., September 20, 1900) have analyzed the literature of Calot's operation, viz.:

Six hundred and thirty-nine corrections were performed by thirty-four operators. Time elapsed varied from a few days up to three years or more. Of the separate detailed cases in 7 more than one year had elapsed; in 35 more than six months.

Deaths reported from all causes, 25; various diseases, 5; general tuberculosis, 4; trauma of the operation and chloroform, 5; intercurrent disease, 7.

Immediate results: Respiratory embarrassment, 7; pain, 6; severe shock, 3.

Abscess present before operation, 19; ruptured, 4; benefited or absorbed, 6; appeared after operation, 2.

Paralysis present before operation, 23; relieved, 17; not relieved, 2; made worse, 1.

Paralysis appeared after correction in 4.

Direct effect on deformity in 224 cases: Complete correction, 130; incomplete, 94.

Result in 77 cases: No relapse, 20; some relapse, 50; total relapse, 7.

with new bone, because the capacity for bone formation is in this locality very feeble.

There is, as a rule, an immediate recurrence of a certain amount of deformity because of the natural recoil toward the habitual posture, and because in many instances the straightening of the spine has been due to an obliteration of secondary curvatures rather than to actual separation at the seat of disease. Even if the deformity were obliterated, and if the interval between the segments were filled with calcified tissue, such bone cannot grow; consequently the irregularity must become more and more marked with the growth of the child. In other words, although the effect of the destructive disease on the spine may be modified it cannot be entirely remedied even by the most successful operation.

The Selection of Cases for Forcible Correction. The favorable cases are those in which the deformity is of comparatively short duration, cases in which the adhesions and the accommodative changes in the soft parts are not sufficient to offer resistance to correction, and in which the internal organs have not been long displaced or compressed. Well-marked deformities of the middle and lower dorsal region are especially suitable for the operation.

The most unfavorable cases are those of fixed deformity, in which repair is progressing or is completed, and in which the organs and tissues of the body have been changed in shape and function to accommodate the new conditions.

As a rule, deformity of the lumbar and of the cervical regions is not sufficient to require forcible correction.

The presence of an abscess in the posterior mediastinum or elsewhere, if it be in the active or progressive stage, should contraindicate the operation. On the other hand, paralysis, which is most often a complication of disease in the dorsal region, is not a contraindication.

The Operation. As ordinarily performed the patient having been prepared as for the application of a plaster jacket is anæsthetized and is then suspended face downward in the horizontal position by five assistants, who make moderate steady traction upon each extremity and upon the head while the surgeon, standing by the side of the patient, gently presses downward directly upon the kyphosis, which, in the favorable cases, is gradually obliterated, the straightening of the spine being accompanied by the audible separation of adhesions.

As a rule, the force required is much less than that stated by Calot. Jones states that a traction force of nearly six hundred

pounds is required to dislocate the neck of a child two and one-half years of age; that five men pulling in the manner above described, with a force that soon tires, rarely exceed a traction force of one hundred and seventy-five pounds.

If the correction is to be completed at the first attempt the spine is overextended, and while it is held in this attitude a plaster jacket is applied. If the disease is of the middle of the back, the head need not be included, but it is better to fix and draw the shoulders backward by including them in the plaster. Great care should be taken to prevent excoriations. Very long, thick, wide pads should be placed on either side of the spinous processes; the iliac crests and other prominences should be protected, and a so-called dinner pad should be inserted below the sternum, which may, when removed, allow additional room for respiration. This is of great importance if the patient has not worn a plaster jacket before the operation. If the disease is of the upper dorsal region, the head must be included in the bandage. Calot suspends the anæsthetized patient as in the ordinary manner for applying a jacket; other surgeons suspend the patient with the head downward during the application of this part of the bandage, but with a little care the head support may be applied with the patient in the horizontal position.

The hair should be cut closely, and protected from the plaster by a well-fitting skull cap. The bandage is then continued over the head and neck as in the illustration (Fig. 59). A strip of malleable steel, bent to fit the occiput, may be incorporated in the bandage to give it sufficient strength.

Many surgeons employ other supports than the plaster. One of the best forms of apparatus is the double Thomas brace used by Jones. The stretcher frame may be used with the plaster jacket to assure recumbency.

In properly selected cases there is little shock after the operation, but if the change in the contour of the spine has been considerable, respiration may be somewhat embarrassed by the plaster jacket. In such cases it must be split through the front and separated. In all cases it is well to cut through the plaster at points where direct pressure is likely to be exerted, in order to guard against excoriations.

As a rule, the operation should be followed by prolonged rest on the back, three to six months or longer, to allow for adaptation to the new position and for consolidation.

As has been stated, there is a marked tendency toward recur-

rence of deformity. On this account some surgeons advocate wiring the spinous processes to one another as originally suggested by Hadra and practised by Chipault. The operation is a simple one, but its efficacy is more than doubtful.

In cases in which the deformity is of the resistant type it is well to divide the rectification into several sittings at intervals of a week or more. In many instances anæsthesia is not required after the first operation; for traction and even the forcible pressure at the seat of disease do not appear to cause particular discomfort.

Gradual Correction of Deformity. Corrective force may be applied also by methods that do not deserve the name operation. For example, a certain amount of traction and pressure may be employed with advantage during the application of the plaster jacket in the ordinary manner if the cases are properly selected, and the effect of posture in correcting deformity is illustrated by the use of the stretcher frame.

An efficacious method of gradual or non-violent correction is that employed by Goldthwait[1] by horizontal traction and leverage. This method is described by him as follows:

"The apparatus which has been used consists of a strong gas-pipe frame, six feet long by two feet wide. Suspended from this is a bar (*a*), in the centre of which is a vertical rod (*b*), forked at the top and long enough to reach to the level of the frame. This crossbar is simply suspended from the frame so that its position can be changed as desired. Below this is another crossbar (*c*), which rests on the frame and can also be adjusted as to position. Upon this latter piece (*c*) and upon the fork of the rod (*b*) rest two malleable steel bars (*d*), about eighteen inches long. These rest in grooves one inch apart, and should be bent to partly conform with the lumbar curve of the spine, after which they are heavily padded with felt and the patient laid upon them. The upper end of the bars (*d*) should just rest upon the fork, not projecting over, and when the patient is in position the rod should be one inch above the apex of the deformity. The buttocks rest upon the crossbar (*c*), and the legs are supported by one or more heavy webbing straps which can be tightened or loosened at will. No support whatever is given the upper part of the body, except that the head is steadied by the surgeon with the hand until a satisfactory amount of correction has been accomplished, and then

[1] Transactions American Orthopedic Association, vol. xi. p. 95.

a strap similar to those used below gives the support so that the operator's hand is free. If traction is desirable, it can be applied by means of a windlass, which is attached to each end of the frame. This makes it possible to obtain much more definite and steady traction than would be possible with assistants, but its use has not been found necessary in the majority of the cases, simple overextension of the spine accomplishing the same results.

"When the maximum overextension that is desirable is obtained, the strap under the head is fastened and the patient allowed to lie in this position while the jacket is applied. In applying this the iliac crests should be generously padded with heavy felt, and a similar pad should be placed over the upper part of the sternum,

FIG. 68.

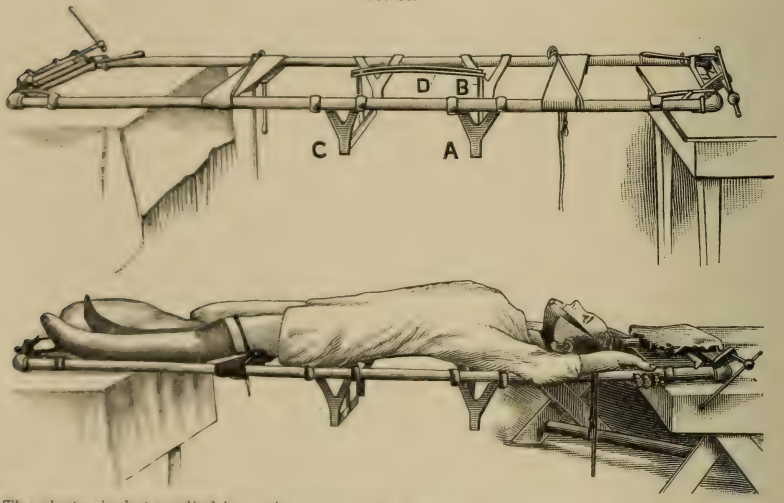

The plaster jacket applied in supine posture by means of the Metzger-Goldthwait apparatus.

so that the jacket can be carried high up to prevent the upper part of the body with the shoulders from drooping forward. In the cases with disease in the upper dorsal region the jacket should be moulded about the anterior part of the neck so that erect position of the head is necessary. The forked rod (*b*) is easily avoided by a few figure-of-eight turns of the bandage, so that when the plaster has set the patient can easily be lifted off, and as the rod (*b*) should be placed one inch above the apex of the deformity this weak spot in the jacket is not objectionable.

"When the patient is taken off the frame the two rods (*d*) are slipped out from below, leaving the padding in place.

"As a matter of experience it has been found necessary to prac-

tically always cut a small window over the point of greatest deformity, as otherwise when the body settles down, as is inevitable, a slough will form even though a liberal amount of padding has been used. This procedure is repeated from time to time until the best possible attitude has been obtained."

This method, originally devised as a modification of the Calot method of forcible correction of defomity, is now employed in the routine application of the plaster jacket. For this purpose Goldthwait uses a portable frame, as shown in the illustration (Fig. 69).

The appliances shown on page 89, in which the force of gravity is utilized to straighten the spine, are now more commonly used for the application of the jacket in the recumbent posture.

FIG. 69.

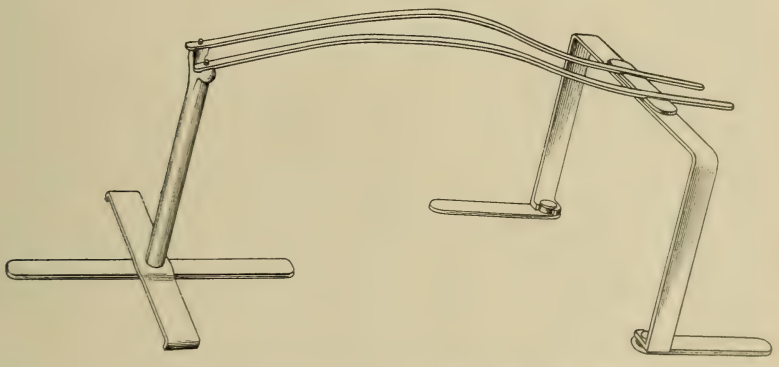

Goldthwait's portable frame for applying the plaster jacket.

It may be stated of forcible correction of the spine (Calot's operation), that it is in no sense curative ; that although it has been proved that the back can be straightened, in many instances with ease and in most cases with but little danger, yet the retention of the spine in the corrected position is difficult, and a certain immediate recoil toward deformity is the rule. Even if the interval between the two segments be filled with new bone, the growth of the spine at this point being checked, an increase of the irregularity with advancing years may be expected. In fact, correction of deformity is in no sense a substitute for prevention.

The operation in its original form should be reserved, in the writer's opinion, for cases in which the deformity is sharply angular, showing that the destructive process is limited in its extent. If correction is attained, horizontal fixation should be

continued, if possible, for many months as an essential part of the treatment.

The final judgment cannot be passed upon this procedure at the present time. It has rapidly lost favor recently, partly because of recurrence of deformity, and partly because experience has shown that the same degree of rectification may be attained by milder methods.

The Duration of the Treatment of Pott's Disease. The duration of the treatment must depend upon the extent and severity of the disease. It may be divided into two periods: one during which the disease is active, when absolute fixation is indicated, and a stage of recovery, during which supervision is required. During the first stage the destructive process may increase the absolute deformity; during the later period of weakness the distortion may increase, simply because of the general inclination toward deformity and because of the atrophy of the supporting muscles.

Tuberculosis of the spine is slow in its progress, and recovery is often insecure. The course of the disease is shortest in the cervical region, but even here two years of brace treatment will probably be required, and in the lower region double this time, even in the milder type of cases. Active treatment should be continued as long as there is evidence of disease. The absence of actual pain and discomfort is of little value in determining the absolute cure if braces have been employed. The absence of muscular spasm is more significant, since it usually persists as long as the disease is active. The presence of pain on passive motion or muscular contraction or abscess would, of course, indicate the necessity of further treatment.

Direct palpation is of some value in determining the condition of the affected part. During the progressive stage, careful, deep pressure over the spinous processes may show greater mobility of those involved in the disease. During the stage of repair and consolidation the mobility is replaced by rigidity. The appearance of the kyphosis has some significance. In the early stage of the disease its area is not clearly defined, but when consolidation has taken place its extent is shown by the rigid vertebræ, which stand out separated from the remainder of the spine by a well-marked sulcus, which is much deeper below than above the kyphosis.

Even when the disease appears to be cured, *removal of support* should be gradual and tentative; the jacket should be replaced by the corset, or the brace by a lighter appliance; then support

may be removed at night, later for part of the day, and at last, after many months, it may be discarded. Then may follow massage of the atrophied muscles of the trunk and gentle exercise.

Such careful supervision must be continued for a much longer time if the best ultimate result is to be attained, for, as has been mentioned, one should guard against the secondary distortions, which may be due simply to weakness and to the unfavorable mechanical conditions induced by the primary deformity. If curvatures of the spine are so common among those whose backs may be supposed to be fairly normal, how much more likely is such secondary deformity to result when the back has been weakened by disease and by long disuse of the muscles.

This secondary increase of deformity is not so much to be feared after the cure of the disease in the lumbar region, because of the favorable attitude of erectness, nor is it likely to be marked after cure in the cervical region of the spine; but in disease of the upper and middle dorsal region support must be continued long after the disease is cured, and supervision must be exercised until after the period of adolescence, if the increase of deformity is to be prevented.

Recurrence of Disease and Later Effects of Deformity. The disease may recur after an interval of many years of apparent cure, and such recurrences are sometimes accompanied by the formation of an abscess or by paralysis.

If recovery from Pott's disease has been complete, and if deformity has been prevented, the condition of the patient is to all intents normal, but if the course of the disease has been prolonged and if the deformity is great his condition is abnormal; he is unfitted for ordinary occupations, and comparative comfort is assured only by constant care. Such individuals are likely to suffer from neuralgic pain about the weakened spine on overexertion or whenever the general condition is depressed from any cause. In such cases the use of some form of light corset adds to the comfort of the patient.

In certain instances pain localized in the lateral region of the trunk may be caused by compression of an intercostal nerve, or it may be due to compression of the tissues between the last rib and the chin. In several cases of this character, reported by Goldthwait, resection of a portion of a rib at the seat of pain relieved the discomfort.

Secondary Deformities. While the patient is under treatment for Pott's disease one should be on the alert to prevent other

deformities that may follow the general weakness and restriction of normal functions. One of these is the *weak foot*, sometimes called weak ankle or flat foot, and with it is often associated a moderate degree of knock-knee. This may be prevented by the use of a shoe of proper shape, of which the heel and sole are thickened slightly on the inner side.

Recapitulation. Fixation on the stretcher frame is the treatment of choice in infancy and early childhood, without regard to the situation of the disease. Ambulatory treatment is the treatment of selection in later childhood, adolescence, and adult life.

Ambulatory treatment must always supplement that by recumbency, and in the great majority of cases it is the treatment of necessity and routine. Its efficiency will depend, in great measure, upon the careful regulation of the strain which the erect posture and the activity of the patient throws upon the weakened spine.

Of the relative merits of the supports that have been described it may be stated that the plaster jacket has the great advantage of cheapness; its use places the treatment in the hands of the surgeon, and in the middle region of the spine it is equal to, and may even be superior to, the brace. The laced corset is not equal as a support to the solid jacket.

The back brace has a wider range of adaptability than the jacket. Its disadvantages are the original expense, the difficulty of accurate adjustment, and the fact that it can be removed by the parents, who are inclined to neglect medical supervision, when the use of the apparatus has become familiar to them.

The jury mast, although a very useful appliance under certain circumstances, is inferior to the metallic head rest when accurate fixation or support is desired.

The complications of Pott's disease, abscess and paralysis, should be considered and treated as symptoms only—symptoms that may or may not require direct treatment according to the indications that have been described. Finally, one should always bear in mind that the final cure of the disease depends upon the increase of the vital force; thus, the importance of fostering and improving the general well-being of the patient cannot be too strongly urged.

CHAPTER II.

NON-TUBERCULOUS AFFECTIONS OF THE SPINE.

Syphilis.

Syphilis, in the inherited or in the later stages of the acquired form, may affect the bones of the spine and cause local deformity and symptoms that cannot be distinguished from those of Pott's disease.

Diagnosis. As compared with tuberculosis, it is a rare disease of the spine.[1] Its manifestations are likely to be general in character, the deformity of the spine being but one of many evidences of disease.

Fig. 70.

Vertical anteroposterior section of lumbar spine, showing deposit of gumma in the posterior part of the third and fourth vertebræ. (After Fournier.)

If syphilis were limited to the spine and simulated the symptoms and the deformity of Pott's disease, it would demand the same local treatment. Specific remedies should be administered when one has reason to suspect the presence of the syphilitic taint, even if the local disease appears to be tuberculous in character.

Malignant Disease of the Spine.

Malignant disease of the spine is a rare affection, particularly so in childhood. Sarcoma is more common than carcinoma, and it may affect the spine primarily. Carcinoma is almost always secondary to a primary tumor elsewhere, the spine becoming involved by metastasis or by contiguity. Schlesinger,[2] in 3720 cases of carcinoma, found secondary growths in the spine in 54.

[1] Jasinski. Archiv f. Dermat. u. Syph., Bd. xxiii. S. 400.
[2] Buckley. Journal of Nervous and Mental Disease, April, 1902.

Diagnosis. Malignant disease differs from tuberculosis of the spine in that its symptoms are usually more severe; the pain is usually persistent, and it is not relieved by support or recumbency, as is that of Pott's disease. The constitutional symptoms are more marked, and the steady progress of the disease toward a fatal termination is soon apparent. Locally, the angular deformity is usually slight, and it may be absent. Not infrequently the tumor may be palpated through the abdominal wall.

Paralysis is a frequent and often an early symptom. In a case of melanotic sarcoma of the spine in a boy aged twelve years, seen recently, complete paralysis of motion and sensation in the lower extremities preceded noticeable symptoms pointing to the local disease.

As has been stated, *carcinoma* is almost always secondary to disease elsewhere; thus, if after the operation for the removal of carcinoma symptoms of disease of the spine appear, one should suspect this complication.

Malignant disease of the spine is a fatal affection, and the treatment can be but palliative.

Acute Osteomyelitis of the Spine.

Infectious osteomyelitis of the spine is comparatively uncommon. The lower vertebræ are more often affected. In 5 of 41 cases reported by Eichel[1] the atlo-axoid region was involved.

Symptoms. The symptoms are similar to those of acute infectious processes elsewhere, and are characterized by sudden onset, with pain, fever, and constitutional depression. There is local pain and tenderness about the spine. Abscess quickly forms; and paralysis from the rapid extension of the disease is a common complication.[2] The symptoms due to pyogenic infection and to deep-seated abscess are often pyæmic in character, and necrosis of the affected vertebral bodies may result in the formation of large sequestra.

A more localized and more chronic form of osteomyelitis may occur, and abscess may be the first sign of the disease. In all cases of this character, whether acute or chronic, other bones or joints or other tissues are often involved, and in many instances an infected wound or discharging ear, for example, may indicate the source of infection.

[1] Münch. med. Wochen., 1900, No. 35.
[2] Müller. Deutsche Zeits. f. Chir., Bd. xli.

Treatment. The treatment consists in the immediate evacuation and drainage of the abscess, the removal of the necrosed bone if possible, and in supporting the spine during the subsequent stage of weakness.

Actinomycosis of the Spine.

Actinomycosis of the spine is an extremely rare disease, and need only be mentioned as a possibility. The spine was involved secondarily in about 2 per cent. of the reported cases.[1] The diagnosis may be made by the microscopic examination of the discharge from the sinuses that almost always form when bone is affected.

Injury of the Spine.

Severe sprains or fractures may simulate disease very closely and in some instances, particularly injury of the cervical region, diagnosis is practically impossible until after treatment by support and fixation has been applied, when, as a rule, if disease be absent, the symptoms, even though of long standing, quickly subside.

Fracture of the spine in the middle region may result in angular deformity; and when proper support has been neglected, symptoms of pain and weakness, similar to those of Pott's disease, may persist indefinitely.

Sudden forcible compression of one or more of the vertebral bodies without displacement and without severe immediate symptoms, other than the slight deformity, may be the result of injury, especially falls from a height. These cases are not uncommon, and, as the severity of the injury is not often recognized, the local deformity, which may not attract attention until several weeks after the accident, combined with stiffness and weakness, lead to the mistaken diagnosis of Pott's disease.

Rupture of spinal ligaments may be caused by forced forward bending of the spine. The resulting deformity and weakness resemble those caused by a crush of one of the vertebral bodies. A number of cases have been described by Painter and Osgood.[2]

[1] Erving. Johns Hopkins Bulletin, November, 1902.
[2] Boston Medical and Surgical Journal, January 2, 1902.

Traumatic Spondylitis.

Kummell[1] has described a form of rarefying ostitis of the spine of non-tuberculous origin, apparently caused by injury. It is characterized by symptoms of pain and weakness referred to the back, and by pronounced rounded kyphosis of the dorsal region. Motor disturbances of the lower extremities are frequent.

FIG. 71.

Rhachitic kyphosis.

Kummell's cases do not differ particularly from those of injury that have been described. In fact, in the neglected cases of injury of the spine the pain and weakness may persist indefinitely, and the deformity may increase. In certain instances there may be a secondary infection, tuberculous or otherwise, at the seat of injury, and in others the injury may be the exciting cause of spondylitis deformans, but such results are unusual.

[1] Deutsche med. Wochen., 1895, No. 11.

Treatment. In all such cases, and whenever weakness of the spine persists, and when motion causes pain, a support should be employed as in the treatment of Pott's disease. If possible, deformity if of recent origin should be corrected, in part at least, either by the method of Calot or by recumbency before the support is applied.

The Rhachitic Spine.

The rhachitic spine has been described in the consideration of the differential diagnosis of Pott's disease (p. 50). It most often develops during the first or second year of life, in children who sit the greater part of the time; it is, in fact, simply an exaggeration of the contour which is normal in the sitting posture. The typical rhachitic kyphosis is thus a rounded projection of the lower region of the spine, which is more or less rigid according to its duration. If the deformity is extreme there may be a compensatory backward inclination of the head which may be accompanied by contraction of the posterior group of muscles, "cervical opisthotonos."

Treatment. Aside from the constitutional treatment of the rhachitic condition, and from the measures that should be employed to improve the nutrition of the muscles in general, the indications are to overcome the rigidity and the limitation of motion of the spine; to support it, if necessary, during the stage of weakness; and to remove, if possible, the predisposing causes of the deformity.

The correction of the deformity may be accomplished by massage, and by direct manipulation of the spine. The child is placed, face downward, on a table; one hand is applied over the projection, and with the other the legs are raised to throw the spine into a position of overextension. This stretching is performed slowly and carefully over and over again at morning and night, and the manipulation is followed by thorough massage of the muscles. If the deformity is marked and if the general rhachitic process is still active, the infant may be kept for several months in the recumbent posture, on a light frame, in an attitude of overextension, as described in the treatment of Pott's disease.

In older subjects some form of light back brace may be sufficient in connection with the massage, and systematic correction of the deformity.

The Natural Cure. It may be stated that the rhachitic spine is to a certain extent corrected when the erect posture is assumed,

by the inclination of the pelvis and accompanying lordosis. This natural cure is, however, often rather a distribution of deformity than a cure, for the upper part of the projection may remain as an exaggeration of the normal dorsal kyphosis balanced by an exaggerated lordosis, "*the rhachitic attitude.*" And in other instances the persistence of the lumbar kyphosis may induce a compensatory flattening of the normal dorsal kyphosis. Thus, rhachitis may cause the so-called *flat back* as well.

It may be mentioned that rotary lateral curvature of the spine is one of the common deformities induced by rhachitis. This distortion is far more serious than the anteroposterior curvature with which it is occasionally combined. Its treatment is considered in Chapter III.

Infectious Disease of the Coverings or Articulations of the Spine. "The Typhoid Spine."

During the course of or during convalescence from typhoid fever, and occasionally after apparent recovery from the disease, symptoms of pain, weakness, and stiffness of the back may appear. These are caused apparently by secondary infection of the fibrous coverings and attachments of the spine, similar to the more common but more severe forms of periostitis of the tibia or other bones, from the same cause. There is usually pain on motion, reflected along the nerves. In some instances this is extreme, and there may be accompanying muscular "cramps" and spasm, and pain on pressure over the affected vertebræ.

In many instances a neurotic element is present, induced, doubtless, by the preceding disease. In 8 of 26 cases investigated by Lord[1] kyphotic deformity indicated apparently local destructiveness of the process.

Diagnosis. The diagnosis is usually made clear by the history of the disease of which it is a complication.

Treatment. The treatment should be symptomatic. During the active stage, if pain is severe, the patient should be kept in the recumbent position and opiates may be administered if necessary. Locally, the application of the Paquelin cautery is of service. As soon as is practicable a back brace or other support should be applied, which should be worn until the symptoms have subsided. Recovery may be predicted, the duration of the symp-

[1] Boston Medical and Surgical Journal, June 26, 1902.

toms averaging about six months. Slight restriction of motion may persist in the more severe type of cases.

This description applies particularly to a class of cases of a mild type described by Gibney as typhoid spine. Disease of the spine complicating typhoid fever was first described by Maisonneuve in 1835. Terrillon[1] classifies the lesion of typhoid infection of the spine as:

1. Simple periostitis.
2. Periostitis with subperiosteal abscess.
3. Periostitis with ostitis.

In sixty-eight cases tabulated by Würtz[2] six were in children under ten years of age.

Symptoms resembling those described may follow other forms of contagious disease, notably scarlet fever, but, as a rule, they are much less persistent and severe.

Infectious Arthritis of the Spine.

"Gonorrhœal rheumatism" of the spine is uncommon. Its symptoms and pathology resemble those of the typhoid spine. Anchylosis is, however, more common as a result than after other forms of infection; in fact, gonorrhœa is supposed to be one of the causes of spondylitis deformans.

The treatment, aside from that of the exciting cause, is symptomatic. Local support is indicated in many instances.

The articulation of the occipito-axoid region are sometimes affected by what appears to be a form of acute or subacute infectious arthritis similar in characteristics to acute rheumatism. It may follow tonsillitis, diphtheria, or other contagious disease. It may be distinguished from tuberculous disease by its acute onset and from acute torticollis by the fact that all motions are restricted.

Treatment. The treatment consists in support during the acute stage, followed by massage, manipulation, and exercise to overcome the subsequent stiffness.

Spondylitis Deformans.

Synonyms. Osteo-arthritis of the spine; rheumatism of the spine; spondylose rhizomélique; stiffness of the vertebral column.

[1] Le Prog. Méd., April 12, 1884.
[2] Jahrbuch für Kinderheilkunde, July, 1902

Spondylitis deformans is an inflammatory affection of the spine terminating in anchylosis and deformity.

Pathology. The disease is apparently a chronic inflammation which affects primarily the ligaments and the periosteal coverings of the spine, a form of ossifying periostitis which binds the vertebræ firmly to one another (Fig. 72). It may begin on the lateral or on the anterior aspect of the spine; it may be limited to a particular region, but in most instances it involves the entire

FIG. 72.

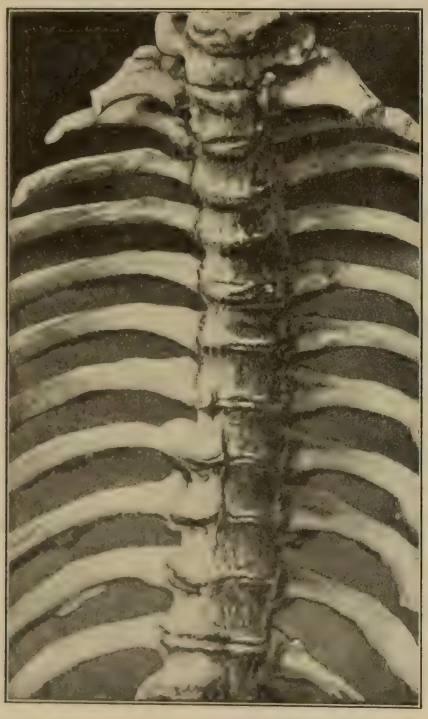

Spondylitis deformans (osteo-arthritis). (Goldthwait.)

spine and often the articulations of the ribs as well. The intervertebral disks atrophy, and the spine becomes anchylosed. In some instances the margins of the cartilages proliferate and become ossified in a manner characteristic of osteo-arthritis of the joints.

Under the general term of spondylitis deformans are included, in all probability, several varieties of disease, for example:

1. The affection of the spine may be simply one of the manifestations of general rheumatoid arthritis—rheumatoid arthritis of the spine.

2. The spine may be involved together with one or more of the adjacent joints which present the characteristic symptoms of

FIG. 73.

Spondylitis deformans, illustrating the characteristic deformity. Age of the patient, thirty years. Spine rigid, with the exception of the occipito-axoid articulation. Duration two years; cause unknown. No joints involved.

FIG. 74.

Spondylitis deformans in a child.

the so-called hypertrophic form of arthritis deformans—osteo-arthritis of the spine. This form has been designated by Marie spondylose rhizomélique, spondylos-spine, rhizo-root, melos-extremity, signifying a disease of the spine together with the adjoining "root" joints.[1]

[1] Marie. Revue de Méd., 1898, vol. xviii.

3. The disease may be limited to the spine, and in such cases it appears to be entirely distinct from characteristic rheumatoid arthritis or osteo-arthritis. It may follow acute rheumatism, it may be induced apparently by gonorrhœa, or by other forms of infection or by injury—traumatic spondylitis. It may begin acutely, like inflammatory rheumatism, or it may be chronic in character and progress slowly.[1] It may be limited to a particular section of the spine, although, as a rule, the other regions are progressively involved.

Symptoms. In the ordinary cases there is usually an acute onset from which the patient dates the beginning of his trouble, often so-called lumbago, followed by a gradually increasing stiffness of the spine and accompanying deformity. The patient complains of stiffness, weakness, pain in the loins, and of pain radiating forward along the ribs. Sometimes of weakness in the limbs, headache, nervousness, and the like—symptoms that may be explained in part by the inflammatory process and by implication of the nerve roots, and in part by an accompanying neurasthenia. The direct symptoms are increased by jars which are exaggerated by the inelasticity of the spine. The disease is usually progressive, and terminates finally in complete rigidity of the spine, which is bent into a long kyphosis most marked in the upper dorsal region, the lumbar lordosis being obliterated in many instances (Fig. 73).

The straightening of the spine in the middle and lower region exaggerates the forward thrust of the neck, and in some instances the patients complain of a disturbance of equilibrium, especially of a tendency to fall forward.

When the disease is limited to the spine or to the spine and one or more of the larger joints, the occipito-axoid articulations are not usually involved; but in the general form of the disease—rheumatoid arthritis—they are often primarily affected.

The types of the disease may be illustrated by a brief description of five cases recently under observation.

Case I. *Chronic Rheumatoid Arthritis of the Spine.* In this case, in a boy ten years of age, there was characteristic general rheumatoid arthritis that involved nearly every joint of the body. The entire spine, even including the occipito-axoid joints, was rigid and the head was fixed in an attitude of extreme torticollis.

[1] Bechterew. Neurol. Centralbl., vol. ii. p. 426. Senator. Berlin. klin. Wochen., November 20, 1897.

Case II. *Osteo-arthritis of the Spine.* "Spondylose rhizomélique." A man, aged forty-six years, after repeated attacks of so-called rheumatism involving the larger joints, became gradually disabled because of pain and stiffness of the back and because of his inability to stand erect. In this case there was complete anchylosis of the spine, except of the small joints of the

Fig. 75.

Extreme posterior curvature of the spine in adolescence, showing retraction of the abdomen. This deformity may be mistaken for spondylitis deformans.

cervical region, and in addition the right thigh was flexed upon the body at such an angle that the patient could walk only with an exaggerated stoop. The joints of the feet were slightly involved also. No cause other than exposure to cold and dampness could be assigned. The symptoms were of two years' duration, periods of comfort alternating with disabling attacks of "rheumatism."

Case III. *Spondylitis Deformans.* The spine of this patient, a man aged forty-six years, was absolutely anchylosed in the characteristic position. The occipito-axoid joints were not involved. Fourteen years before he had suffered from a severe and prolonged attack of "inflammatory rheumatism," affecting nearly every joint, but not the spine, and during a succeeding period of nine years he had been disabled several times from the same cause. Each illness was coincident with gonorrhœa. Five years before examination the "rheumatism" had involved the spine, and since then he had suffered from persistent "lumbago." Gradually the stiffness of the spine had increased, but during this time he had been free from gonorrhœa and from rheumatism as well. The joints were normal in appearance and function. This patient suffers principally from nervousness and irritability; he is easily startled; he feels as if his forehead were clasped by a tight band. His direct symptoms are pain in the loins and pain radiating under the shoulder-blades, increased by walking or by jars. His equilibrium is disturbed by the forward projection of the head and by the obliteration of the normal lordosis, so that he feels himself constantly inclined to fall forward, whether he is sitting or standing.

Case IV. In another case very similar to this, in a man aged thirty years, the spine had become rigid in a few months. The patient ascribed the disease to sleeping out of doors. There was in this case coincident tuberculous disease of the lungs.

Case V. A man, aged sixty-two years, presenting the characteristic deformity and symptoms of the subacute type, gave the following account of the affection: Fifteen years before he had suffered from "chronic lumbago." The pain and stiffness, at first limited to the lower region of the spine, had, with intervening periods of remission, gradually ascended, and at the time of examination the cervical region was the seat of the more active process. He had been treated by internal remedies, by baths, and by change of climate, without avail. He knew he had the "old man's stoop," but he was surprised to learn that the source of his symptoms was a disease of the spine. The spine was rigid, although not anchylosed, as indicated by the discomfort on changing from one position to another. The occipito-axoid articulations and the other joints were free from disease.

This subacute form of the affection is very common, and, as in this instance, the patients are usually treated for rheumatism, muscular or otherwise, for many years before the true diagnosis is made.

Treatment. The local treatment is symptomatic. Massage of the muscles, hot baths, and the like, may add to the comfort of the patient, but violent exercise or passive movements of the spine are harmful. Support is always indicated during the progressive stage of the affection, and it is the only efficient remedy. The support may be in the form of a light brace or jacket. It is particularly efficacious when the disease is limited to the lower and middle region of the spine. In such cases under efficient protection the muscular spasm subsides, and motion returns in some degree. Even in progressive cases one may hope to preserve the lumbar lordosis, and thus lessen the general effect of the deformity when the spine becomes rigid. In certain instances in which anchylosis is not established, force may be employed to improve the contour of the spine, particularly with the aim of re-establishing the lumbar lordosis, and thus enabling the patient to stand erect. The patient learns by experience what exercise or posture increases the discomfort, and this should be avoided if possible. The application of cautery is often of service, and self-suspension at intervals may relieve the dragging sensation in the muscles. Rubber heels are of service in lessening the jar. As has been stated, in some cases the disease remains localized, but ordinarily it extends along the spine. When a part of the spine becomes firmly anchylosed the local discomfort lessens or ceases, and is transferred to the part where the process is still advancing.

Kyphosis of Adolescents. A form of extreme kyphosis accompanied by stiffness and discomfort is sometimes seen. It appears to be a static deformity induced by overwork in rapidly growing adolescents, which finally becomes fixed by accommodative changes in the bones and neighboring tissues. It can hardly be classified with spondylitis deformans, although there may be some difficulty in distinguishing between the two (Fig. 75). In favorable cases partial rectification of the deformity by force (the Calot operation) is indicated. Afterward support, manipulation, and exercises should be employed.

Osteitis Deformans.

Synonym. Paget's disease.

Osteitis deformans is a general disease characterized by hypertrophy and softening of the bones. The deformity of the spine is similar to that of spondylitis deformans, but the rigidity is not

as marked, and the discomfort is far less than in this affection. The disease is described elsewhere.

Tabetic Deformity of the Spine. In rare instances deformity of the spine, either posterior or lateral, appears as a compli-

FIG. 76.

The neurotic spine. Characteristic attitude.

cation of locomotor ataxia. Fifteen cases are recorded.[1] The characteristics of this form of osteo-arthropathy are described elsewhere.

The Neurotic Spine.

The "neurotic" spine is much more common in adolescence and in adult life than in childhood, and the subjects, usually females, are often of a nervous or neurasthenic type. In certain

[1] Cornell. Bulletin Johns Hopkins Hospital, October, 1902.

instances the symptoms appear to be induced by injury, and in others by worry or overwork.

Symptoms. The patient usually complains of a dull pain in the back of the neck, or in the lumbar or sacral region, of a constant tired feeling, and, not infrequently, of sharp neuralgic pain localized about a certain point in the spine, often the vertebra prominens. The contour of the spine may be normal, but most often there is a well-marked tendency toward a forward droop, the curve of weakness (Fig. 76). One of the common symptoms of the neurotic spine is the *extreme local tenderness*, or hyperæsthesia, of the skin at certain points along the spinous processes. Thus, if one passes the finger gently along the spine the patient will often shrink or cry out because of the pain. As a rule, there is no limitation of motion or muscular spasm. The pain is local, not referred to the terminations of the nerves; in fact, the symptoms are in great part subjective and irregular in character, as contrasted with those of Pott's disease, which are objective and well defined.

Treatment. The treatment of the neurotic spine must be general in character, as indicated by the condition of the patient. Locally, a light back brace or a long corset, reinforced if necessary by light steel back bars, adds greatly to the comfort of the patient. The application of the cautery is particularly efficacious in relieving the local sensitiveness. Massage and light exercises may be employed in the later treatment. Complete recovery is usually long delayed.

The Hysterical Spine.

The hysterical spine is considered usually as synonymous with the neurotic spine, but as there are many individuals who suffer from sensitive spines who are not hysterical, it would seem proper to limit the latter term to the hysterical class.

Symptoms. The local symptoms do not differ particularly from those of the neurotic spine except that in certain instances actual deformity may be present. This is usually an exaggerated lateral distortion, most marked in the lumbar region. Like hysterical distortions elsewhere, it may follow injury, and it may be claimed that this injury was the direct cause of the deformity. Except, however, as a possible cause of the appearance of a particular manifestation of the mental condition, it is evident that no form of injury could explain the symptoms or the deformity.

Treatment. The local treatment is similar to that of the neurotic spine.

Pain in the Lower Part of the Back.

Discomfort in the lumbar region of the character of tire, weakness, or even of actual pain is sometimes an accompaniment of disease or displacement of the pelvic or abdominal organs. Pain in this region is also a common symptom among overworked women. It is particularly troublesome when for any reason the lumbar lordosis is exaggerated temporarily, as during pregnancy, or permanently as a compensatory deformity for dorsal Pott's disease, or because of flexion of the thigh after hip disease.

As a result of strain or other injury symptoms of pain and weakness in the lumbar region, increased by sudden motions or

FIG. 77.

Small pelvis of Prague (median section). Instance of slight forward displacement of fifth lumbar vertebra. (Neugebauer.)

overexertion, may be persistent and disabling. Such cases are often classed as chronic lumbago, but it is probable that there is in many instances a distinct injury of the ligaments or deep muscles of the spine aggravated, it may be, in certain instances, by rheumatism or other general affection of like character.

The *treatment* must be primarily directed to the condition of which the pain is a symptom.

When motion causes pain and when the symptoms are persistent, as in the lumbago type of cases, support is indicated, the Knight brace or plaster corset being convenient forms. During the more acute stage the application of the cautery and the support of intersecting strips of adhesive plaster, covering a wide

area, will often relieve the pain. Later, massage, electricity, and the like are of service.

In the milder cases, in which the symptoms may be dependent on a general descent of the abdominal and pelvic organs, an abdominal belt will afford great relief.

Spondylolisthesis.

Spondylolisthesis is a deformity in which the body of one of the lower lumbar vertebræ, most often the fifth, is displaced forward and downward (Fig. 77). The displacement is peculiar in that the spinous process may remain in its normal position, while the laminæ become elongated or separated from the displaced body. The condition was first described by Killian in 1854, and it was thoroughly investigated by Neugebauer[1] in 1890.

The supposed causes are congenital malformation, injury, and possibly disease of the lumbosacral articulation. Lane states that slighter degrees of the deformity are often observed among laborers. The effect of the displacement is to exaggerate the *lumbar lordosis*, to increase the prominence of the sacrum, and of the iliac crests, and to shorten the trunk. The deformity is most often seen in women; in fact, its chief interest lies in its effect upon childbirth. As a rule, however, as has been stated in the preceding section, an increase of the lumbar lordosis is usually attended by a certain degree of discomfort and pain. In some instances the deformity induces a swaggering gait resembling that of bilateral congenital dislocation of the hips.

Lovett[2] has described a case in which the deformity was the result of direct injury. The patient, a young man, was successfully treated by a plaster jacket. Such cases, and those in which displacement is the result of disease, may require orthopedic treatment by braces or other support for the relief of pain and for the prevention of further deformity. In the milder type exercises and posture are, as a rule, sufficient.

Deformity Secondary to Sciatica.

Synonym. Sciatic scoliosis.

Chronic sciatica often induces a change in the attitude and contour of the spine that may become a permanent deformity if its

[1] Lovett. Transactions American Orthopedic Association, vol. x. p. 22.
[2] Transactions American Orthopedic Association, vol. x.

cause persists. As a rule, the patient habitually inclines the body away from the painful part in order to relieve it from weight, and bends the body slightly forward and abducts the limb to relax the tension on the sensitive nerve or plexus of nerves. Thus, the pelvis on the affected side projects, there is a lateral lumbar convexity toward the opposite side, and often the normal lumbar lordosis is lessened or lost so that the final result may be a persistent lateral curvature, together with a change in the anteroposterior contour of the spine. If the deformity persists a second compensatory curve may appear (Fig. 78). If the sciatica is a symptom of a more widespread neuritis, muscular weakness and muscular spasm may cause variations in the typical attitude, the muscles of one side being persistently contracted.

It must be borne in mind that disease of the lumbar spine, or of the pelvic bones or joints, or disease of the adjacent organs or parts may set up sciatica; thus, the cause of pain should be carefully sought for.

Aside from the direct treatment of sciatica, support for the spine, preferably a light corset, may be indicated, if motion aggravates the pain. If the deformity persists it should be corrected gradually by repeated applications of the plaster jacket.

Neuritis in other regions of the spine may cause symptoms of reflected pain and local sensitiveness. These symptoms are increased by motion, and a certain amount of local deformity, similar in character to that due to sciatica, may be present.

The *treatment* is similar to that indicated in the former affection.

Sacro-iliac Disease.

Tuberculous disease of the sacro-iliac articulation is a rare affection, and extremely so in childhood.

Symptoms. The symptoms are pain, weakness, limp, and change in attitude. The pain is referred to the side of the pelvis or radiates over the buttock or thigh. It is increased by jars, by turning the body suddenly, sometimes by coughing or laughing; and a peculiar feeling of insecurity and weakness is sometimes complained of. As a rule, the body is inclined toward the sound limb; thus the pelvis is lowered on the affected side and the leg seems longer than its fellow. In the early stage of the disease there is no deformity of the limb, but if a pelvic abscess forms the thigh may become flexed. Locally, there may be sensitiveness to pressure on the articulation, and swelling in the

neighborhood of the disease, although this is usually a late symptom. Pain is induced by lateral pressure on the pelvis or by any manipulation that disturbs the articulation.

Abscess finally forms in the majority of cases. It may be extrapelvic or intrapelvic. The intrapelvic abscess may present above the crest of the ilium, or the pus may pass through the sciatic notch, or appear in the ischiorectal fossa, or break into the rectum.

FIG. 78.

Deformity caused by persistent sciatica of the right side. This attitude is similar to that symptomatic of sacro-iliac disease.

Diagnosis. Sacro-iliac disease may be mistaken for *sciatica* or for disease of the *hip* or *spine*. The freedom of motion and the absence of muscular spasm when the pelvis is fixed, if the examination is carefully conducted, should exclude both the one and the other, although the pain on lateral pressure, which is described as the most characteristic symptom, may be simulated closely by primary acetabular disease. The attitude is similar to that of sciatica, but the symptoms of local sensitiveness to jars and to manipulation are much more marked.

Prognosis. According to the statistics the prognosis is very unfavorable, probably because the majority of the reported cases were in adults and were complicated by infected and burrowing abscesses, which constitute the chief danger of this form of tuberculous disease.

Treatment. The local treatment consists in protecting the diseased parts from injury and in the radical removal of the disease if it has reached the stage of abscess formation, if this be feasible.

In the ambulatory treatment of advanced cases a plaster spica bandage or a double Thomas hip brace may be indicated, but in most instances a broad, strong pelvic girdle, which may be drawn tightly about the pelvis, will be most efficient. As a temporary support wide, encircling bands of adhesive plaster may be used. If motion of the spine causes discomfort a spinal brace provided with a wide pelvic band of thin steel that may clasp the pelvis firmly is more efficacious. If the disease is progressive rest in bed will be necessary.

When abscess is present radical treatment is usually indicated. The articulation should be freely exposed and the diseased bone should be entirely removed, if possible. Intrapelvic abscess should be drained through a direct communication in order to check, if possible, the tendency toward burrowing.

Injury of the Sacro-iliac Articulation.

In some instances the symptoms of sacro-iliac disease are apparently due directly to falls on the buttock or pelvis or to strains. In such cases the symptoms are similar in character to those described, and they are readily relieved by the same treatment.

CHAPTER III.

LATERAL CURVATURE OF THE SPINE.

Synonyms. Rotary lateral curvature—scoliosis.

Lateral curvature of the spine is an habitual or fixed deformity in which the spine is deviated in whole or part to one or the other side of the median line.

FIG. 79.

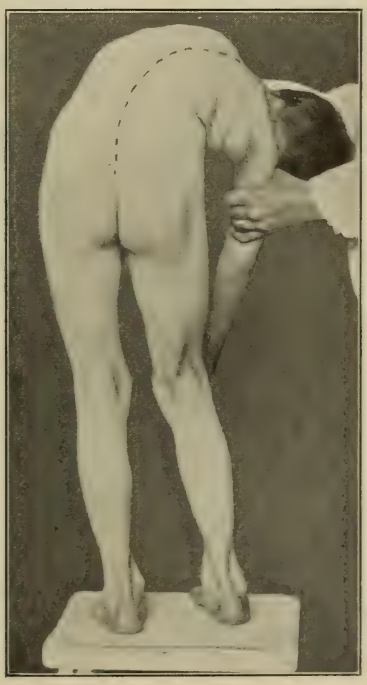

Physiological rotation accompanying flexion and lateral inclination of the trunk in the normal subject.

By limiting the term to habitual deformity one excludes simple postural inclination of the spine. For example, if one leg were considerably shorter than the other the pelvis would be tilted downward on the short side, and there would be a compensatory curvature of the spine in the erect attitude, which would disappear in the sitting posture. This accommodative or compensa-

tory inclination, and those of similar origin, are not, in the proper sense, lateral curvatures.

In persistent lateral curvature the anterior part of the column, made up of the bodies of the vertebræ that support the weight, is more distorted than are the spinous processes, because lateral distortion is always accompanied by a certain degree of twisting or rotation of the vertebral bodies. This rotation is in the direction

FIG. 80.

Congenital total scoliosis. Compare with Fig. 81.

of the convexity of the curve, and, as the bodies rotate, the spinous processes are carried in the reverse direction. Thus, it is that well-marked rotation may be present, although there may be comparatively little lateral deviation of the line of the spinous processes.

In the physiological movements of the spine, simple, direct lateral motion—that is, motion allowed by the small joints of the spine and by the lateral compression of the intervertebral disks—

is very limited. The larger movements must be accompanied by rotation of the vertebral bodies by which this continuous or solid part of the column is, as it were, forced from the shortened toward the lengthened side (Fig. 79). When, for example, one flexes the head to bring the ear as near the shoulder as is possible there is necessarily an accompanying rotation of the chin in the opposite direction caused by the twisting of the bodies of the cervical vertebræ toward the convexity of the curve. Thus torticollis, in which the neck is held in this attitude, causes often a fixed rotary lateral curvature of the cervical vertebræ.

In the simple accommodative lateral inclination of the body to one side or the other, the change in contour of the spine would be more noticeable if it could be observed from the front rather than from the back, and as lateral curvature is simply a persistent deviation of the spine, one of the so-called static deformities which are directly induced or exaggerated by superincumbent weight, it is probable that rotation of the vertebral bodies precedes, in most instances, the lateral distortion that first attracts attention.

It is probable, also, that slight rotation may not cause at once an appreciable degree of external distortion, and, although marked lateral curvature is necessarily combined with rotation, yet it is possible that a slight degree of direct lateral deviation may exist unaccompanied by appreciable rotation. Rotation is usually understood to imply fixed deformity, while lateral deviation may mean simply an habitual posture ; but it is far simpler to consider the two as parts of one distortion. The true and important distinction is between *habitual deformity*, implying the habitual assumption of an improper attitude in which the accommodative changes in structure have not advanced sufficiently to prevent voluntary or passive correction, and *fixed deformity* in which the changes in the bones and other tissues have made cure difficult or impossible. The evidence of fixed deformity is rotation that persists after the lateral deviation has been overcome. It persists because the early and important changes must take place in the bodies of the vertebræ that support the weight, but there is no reason to believe that habitual rotation as an accompaniment of habitual lateral curvature may not be corrected if it be treated at the proper time.

The necessity for dividing the weight about the centre of gravity in order to balance the body in the upright position accounts for the distribution and effects of lateral curvature. As the normal contour of the spine is the necessary result of static

conditions, a change from this normal relation of one part necessitates a corresponding change elsewhere. If there be a primary lumbar curvature and rotation to the left in the lower region, a corresponding lateral deviation and rotation to the right in the region above usually develops, thus restoring the balance of the body. This explains the ordinary S-shaped or double curve of scoliosis, one of which is primary and the other secondary. These curves may divide the spine equally or there may be a long and a short one, and occasionally three distinct curves may be present. If the primary curve is slight, the secondary curvature will be

FIG. 81.

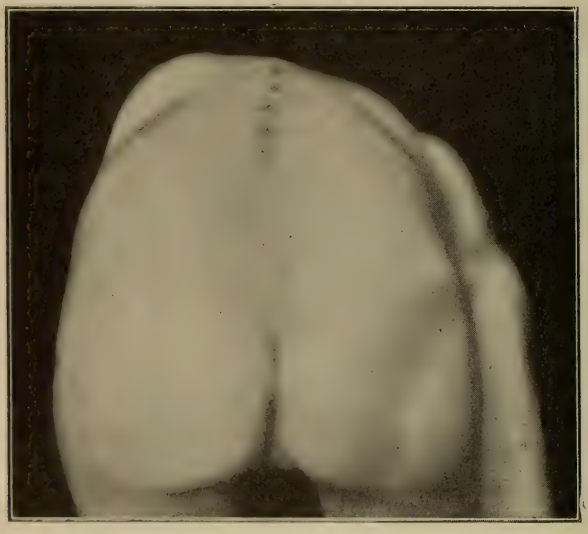

Congenital total scoliosis. The rotation is much greater than the lateral deviation. Compare with Fig. 80.

slight also, and the primary curve persists doubtless for a time before the secondary distortion appears. In some instances the spine may be bent laterally into one long curve, "total scoliosis" (Fig. 80). This is probably, in many instances at least, the initial stage of the ordinary type of scoliosis, the long curve being afterward divided, although it may persist. In childhood total scoliosis is often combined with general posterior curvature, and it is peculiar in that the torsion of the vertebræ may be toward the concave instead of the convex side, as is usual, the torsion representing probably the early stages of the secondary or compensatory curve.

It has been stated that deformity of one part of the spine is usually balanced by deformity of another. This enables the trunk to hold the erect posture, and it restores its general symmetry. If, however, a long lateral or a long posterior curvature

FIG. 82.

Primary lumbar curvature to the left. A "flat back" marked rotation with but slight lateral curvature.

persists, the weight can be balanced only by swaying the entire body on the pelvis, in the direction opposed to the distortion. This restores the balance, but not the symmetry (Fig. 94).

Rotation and Lateral Deviation.

Fixed rotation of the spine carries with it, of course, all the parts that are attached to it. When the patient stands in the erect

attitude the simple lateral distortion is most noticeable (Fig. 80), but when the body is bent forward the twist of the trunk becomes the prominent deformity (Fig. 81). If the thoracic region is involved, the ribs, on the side toward which the spine is rotated, project backward, and on the other side of the spine there is an abnormal flatness or depression. The projection of the ribs due to the twisting of the thorax is far more noticeable than is the simple twisting of the free portions of the spine in the neck or

FIG. 83.

Scoliosis with marked posterior deformity.

loins; and in these regions the projecting transverse processes covered by the thick layers of muscles yet unaccompanied by marked lateral deviation, may cause mistakes in diagnosis. In the cervical region, for example, as an accompaniment of acute torticollis, the projection may be mistaken for abscess; and in the lumbar region it has been mistaken for a new-growth attached to the spine.

Although persistent lateral curvature of the spine is always accompanied by rotation, the degree of rotation does not always correspond to that of the more evident lateral deviation. In the instance cited, rotation in the lumbar region, so extreme as to simulate an abnormal growth, may exist with but slight lateral distortion; while in other cases the body appears to be greatly displaced to one side, although there may be comparatively little fixed rotation. Again, as has been stated, the lateral deviation of the trunk is usually more noticeable than the rotation, which in the slightest grades of deformity is only made apparent when the patient is bent forward so that the back may be inspected in the horizontal position. It may be noted, also, that the degree of habitual lateral distortion of the body does not correspond to the degree of fixed distortion. One individual, by voluntary effort, may practically conceal advanced deformity, while another who makes no effort to correct the improper posture appears to be greatly distorted, although the fixed changes may be very slight.

The effects of the deformity, both general and local, depend upon its situation and its degree. In one instance it may be so slight as to pass unnoticed, and in another the distortion may equal that of Pott's disease (Fig. 83). If compensation be perfect—that is, if the deformity is equally distributed on either side of the median line—the general symmetry of the body may be but slightly disturbed. Or, if the compensation for the primary deformity of the lumbar region is distributed throughout the remainder of the spine, noticeable distortion may be insignificant, but when there is a long curve involving the thoracic region the lateral and posterior displacement cannot be concealed (Fig. 84).

Changes in the Anteroposterior Contour.

Lateral distortion involves, also, secondary changes in the anteroposterior outline of the spine. When the distortion is marked the stature is shortened, sometimes very noticeably. This shortening is, of course, greater when the anteroposterior curves are increased in addition to the lateral deviation. And, in general, one may recognize two types of lateral curvature: one in which the back is flatter than normal, in which the anteroposterior curves are diminished, and another in which they are increased.

It has been stated in the account of Pott's disease that deform-

ity in one segment of the spine always caused a change in the contour of the spine as a whole, that an obliteration or a lessening of the concavity of the lumbar region was accompanied by a corresponding flattening of the normal dorsal kyphosis. On the other hand, that an increase in the backward projection of the dorsal region caused an increase in the concavity of the parts below. The variations in the anteroposterior contour of the spine in lateral curvature may be accounted for in the same manner. In the one instance the primary deformity is of the lower region, and with its accompanying backward twist of the vertebral bodies it lessens the lumbar lordosis and tends to flatten the back (Fig. 82). If, on the other hand, the deformity begins in the thoracic region, the primary effect is to increase the backward projection, and this in turn tends to exaggerate the lumbar lordosis (Fig. 83). Thus, the shortening of the trunk in the lumbar region caused by the lateral deviation may be to a certain extent compensated in the first instance, while in the other both the primary and secondary distortions tend to reduce the height.

The "High" Shoulder and the "High" Hip.

When the convexity of the primary curve is, for example, to the left in the lumbar region, the trunk is displaced somewhat to the left, consequently the right "hip" becomes abnormally prominent; and in compensation for the displacement below there is a corresponding twist in the opposite direction above. The spine bending, and at the same time rotating toward the right, carrying with it the ribs, elevates the shoulder and makes the scapula prominent. Thus it is that in the ordinary S-shaped curve the high shoulder and the projecting hip appear usually upon the same side of the body. But in less regular varieties of distortion, when, for example, there is marked general lateral deviation of the trunk as a whole, the high shoulder may be on the opposite side (Fig. 84). It is probable that the primary curvature is commonly in the lumbar region and toward the left, the compensation to the right appearing at a later time. This is certainly true of the milder types of postural curvature.

Pathology. Lateral curvature of the spine is a deformity, not a disease, nor is it in the ordinary cases an effect of disease. For this reason the description of the pathology which is merely a more detailed account of the deformity and of its secondary effects upon the trunk and its contents may, for convenience, precede the discussion of the etiology.

In such a description one must consider the spine as a whole, a column bent and twisted, in which each component segment bears its share of the general distortion. The vertebra at the apex of each curve shows the greatest change. If the rotation and lateral deviation is to the right the vertebral body is somewhat wedge-shaped, the apex of the wedge being directed backward and to the left. Its lateral diameter is increased and the superior and

FIG. 84.

Scoliosis with extreme lateral deviation.

inferior margins at the narrow side overhang the centre of the body, increasing its lateral concavity (Fig. 88). Similar accommodative changes, although less marked, are to be found in the articular processes and in the laminæ; in fact, all the parts on the concave side are broadened, shortened, and lessened in vertical diameter as compared with those on the convex side of the spine. These changes affect the shape of the neural canal, which becomes

somewhat ovoid in outline, the base being directed toward the convexity of the curve (Fig. 89). In the vertebræ, included in the compensatory curvature, the deformities are reversed, and the intermediate segments show the transitional changes between

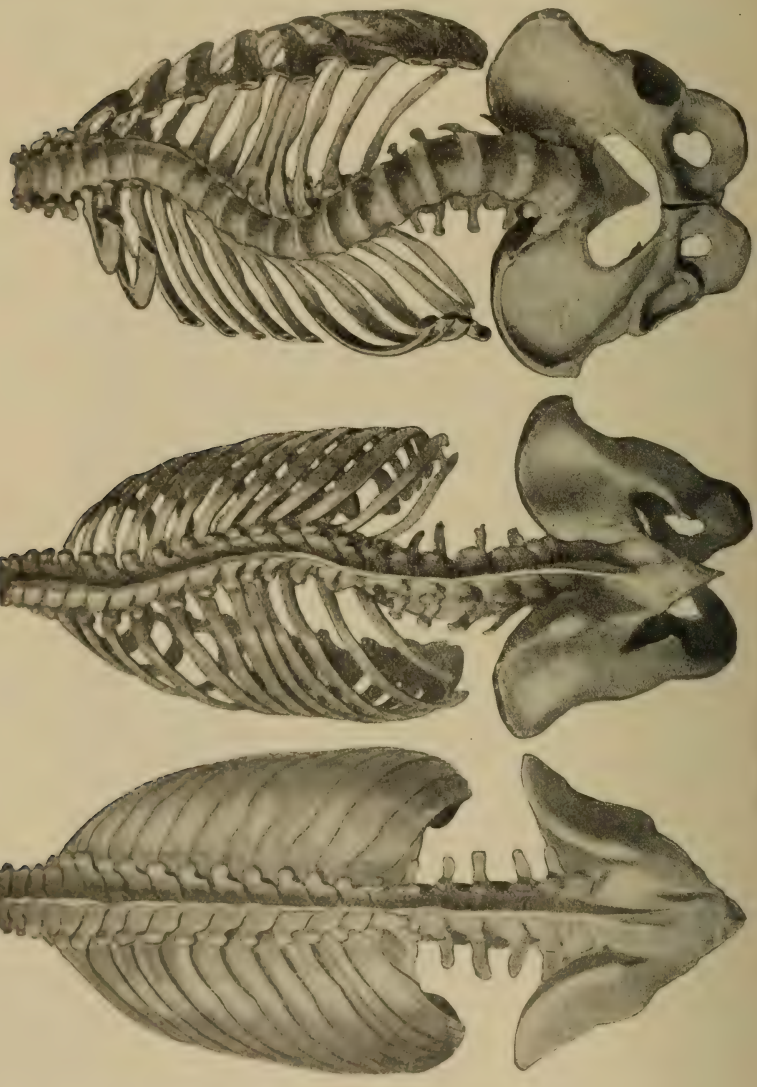

Fig. 87.

Fig. 86.

Fig. 85.

The normal spine contrasted with the scoliotic spine. (Pfeiffer.)

the two extremes. The intervertebral disks become wedge-shaped also, and atrophied on the side subjected to greatest pressure, the changes in these softer tissues preceding, undoubtedly, those in

the bones. The articulations of the vertebræ become changed in shape and position in the general adaptation to the deformity and the ligaments are shortened or lengthened according to their relation to the distortion.

On section the internal structure of the vertebræ shows the same adaptive changes that are evident on the exterior. In the narrowed parts of the bones that bear the weight the tissue is thick and compact, and on the opposite side it is attenuated and atrophied.

The mobility of the spine is lessened by these changes in its shape and structure, primarily by the distortion, later by the

FIG. 88.

Scoliotic vertebræ. (Hoffa).

shortening of the tissues on the concave side, by the irregularities of the vertebral bodies, by the interference of the newly formed or transformed bone which is thrown out about the margins of the vertebræ and the articular processes, and by ossification of the periosteum and ligamentous coverings of the adjacent bones. Thus, in fixed deformity there may be, at the points of greatest distortion, practical anchylosis. The muscles of the back, both intrinsic and extrinsic, undergo adaptative changes, and, as a

rule, they are, in general, relatively weak, especially so if the motions of the spine are much interfered with.

The distortion of the vertebral column causes, of course, a distortion of the trunk of which it is the support, and this distortion is of the greatest importance in its effect upon the thorax. The deformity of the thorax is somewhat difficult to describe, because the distortion of the dorsal vertebræ does not affect the thorax equally; thus, it is not twisted as a whole, nor flexed as a whole. The nature of the deformity may be better understood by considering the sternum as a fixed point; this, as a matter of fact, it is, as compared with the spine. At the apex of the convexity of the curve the ribs are drawn sharply backward with the transverse processes to which they are attached; their angles project by the side of and beyond, sometimes covering and concealing the spinous processes, and the lateral convexity of the chest is diminished or lost. On the opposite side the back is broadened and flattened. The effect of the rotation is to diminish the capacity of the chest on the convex side, and to increase that of the concave side (Fig. 90). On the convex side the ribs are elevated, and their inclination is increased. On the concave side the intercostal spaces are narrowed and the inclination is lessened (Fig. 87). The anteroposterior diameter of the chest is increased or diminished according to the change in the anteroposterior contour of the spine. If the dorsal kyphosis is exaggerated the effect is to deepen the chest (Fig. 83); if it is diminished, the diameter of the thorax is correspondingly lessened.

The cervical section of the spine is not often involved, to a marked degree at least, in the lateral deformity. But in extreme cases, in which the neck and head are habitually distorted, the skull may show secondary changes similar to those induced by persistent torticollis.

At the other extremity of the spine the pelvis is not, as a rule, noticeably deformed. In some instances the oblique diameter, opposed to the convexity of the lumbar deformity, may be increased, and if the lateral deviation of the lumbar spine is extreme the pelvis may be so tilted that the limb on the elevated side becomes practically shorter than its fellow.

In the changes that have been described the contents of the trunk participate to a greater or less degree. The lung on the convex side is more or less compressed by the distorted ribs and by the displaced vertebral bodies. The heart may be displaced laterally or upward, according to the position of the deformity,

and the bloodvessels are changed in direction, and, it may be, altered in calibre. In those cases in which the thorax is markedly distorted the effect is similar to that of the deformity of Pott's disease; respiration is shallow and rapid, the pulse-rate is usually increased, and other evidences of interference with the vital functions may be apparent. The abdominal organs are affected, doubtless, in a similar manner, but symptoms due to this cause are not, as a rule, as clearly marked.[1]

Bachmann investigated the secondary changes induced by severe scoliotic deformity coming under his observation in the pathological institute of Breslau. In 91.3 per cent. of the subjects defect or disease of the circulatory, and in 99.1 per cent. of the respiratory apparatus, was observed.

Etiology. Relative Frequency. Lateral curvature of the spine is one of the most common of deformities. In a period of fifteen

FIG. 89.

Change in shape of the spinal canal, broader on the convex side. (Hoffa.)

years—1885–1899—3252 cases were recorded in the out-patient department of the Hospital for Ruptured and Crippled, a number only exceeded by that of bow-legs, of which 5030 cases were treated during the same period.

The statistics bearing upon the relative frequency of lateral

[1] Bachmann. Die Veränderungen an den inneren Organen bei hochgradigen Skoliosen und Kyphoskoliosen. Bibliotheca Medica, Ab. D. 1, H. 4, 1900.

curvature among children in general are those of Drachmann, who found among 28,125 school-children (16,789 boys, 11,386 girls) of Denmark 368 cases of scoliosis (1.3 per cent.), and those of Scholder, Werth, and Combe,[1] who found 571 cases of lateral curvature among 2314 school-children of Switzerland (24.6 per cent.), a discrepancy that is somewhat difficult to explain.

Sex. Lateral curvature of the spine is far more common among females than males. Of the 3252 cases referred to, 2554 (78.5 per cent.) were in females and 698 (21.4 per cent.) were in males.

FIG. 90.

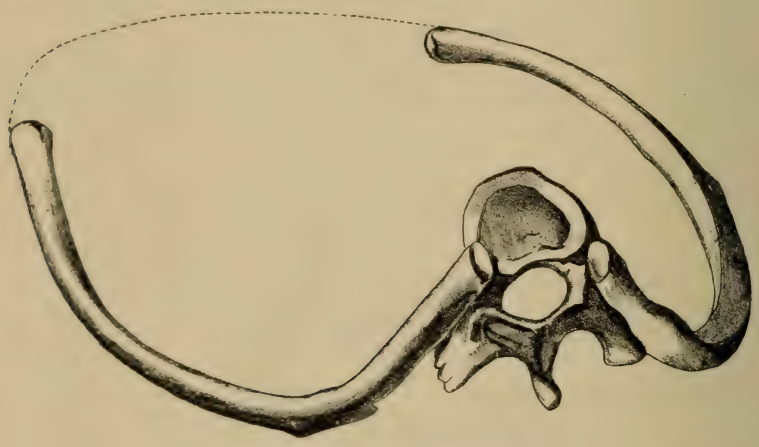

Deformity of the thorax in scoliosis. (Hoffa.)

The lowest percentage of males in any one of the fifteen years was 14.8, the highest 25.1. This proportion of one male to four females is somewhat larger than in the smaller groups of cases reported by other observers.

The unequal distribution of the deformity between the sexes is of great interest as bearing on the question of etiology; especially so as in the cases that develop in early childhood, sex appears to exercise practically no influence. It has been suggested that curvature of the spine in a girl is looked upon with more solicitude by the mother than is the same deformity in a boy, therefore, more girls are brought for treatment. There may be some basis for this argument, for it is certain that distortions of the lower extremities are considered of greater importance in male than in female children, because of the concealment to be

[1] Extrait des Annals Suisses d'Hygiène Scolaire, 1901.

afforded by the skirts, if the deformity is not outgrown. But granting that statistics are somewhat unreliable, there can be no doubt but that this deformity is far more common among girls than boys and that the disproportion may be explained, in great part at least, by the differences in dress and in manner of life.

Age. One thousand two hundred and ninety-nine (39.9 per cent.) of the 3252 patients referred to were less than fourteen years of age; 1576 (48.4 per cent.) were between fourteen and twenty-one; 377 (11.6 per cent.) were more than twenty-one years of age. These statistics simply show the age of the patients at the time treatment was sought, and they are of little value as an indication of the age at which deformity might have been detected had it been looked for.

There is no reason to suppose that lateral curvature of the spine differs in its etiology from similar deformities of other parts, except in so far as each region of the body is more or less susceptible to deforming influences at one time than another.

For example, rhachitic deformities of the upper extremities practically never develop except in infancy, and they begin to correct themselves when the erect posture is assumed or at the very time when distortions of similar origin of the lower extremities appear or increase. When deformities of this class, whether of the spine or limbs, appear in later childhood or adolescence it may be assumed that, in many instances at least, the tendency toward the particular deformity, or even a slight degree of deformity, was acquired at an early age, that it remained latent until the conditions appeared which favored its further development. This point is illustrated by the statistics of Eulenburg of 1000 cases of lateral curvature analyzed with reference to the inception of the deformity.

Between birth and the sixth year	78
" the sixth and seventh years	216
" the seventh and tenth years	564
" the tenth and fourteenth years	107
After the fourteenth year	35
	1000

It will be noted that but 142 (14.2 per cent.) of these patients were more than fourteen years of age as contrasted with the general statistics of the Hospital for Ruptured and Crippled, in which 60 per cent. were beyond this age.

Dr. Walter Truslow, who for several years had the immediate charge of the treatment of lateral curvature at the Hospital for Ruptured and Crippled, has prepared for me statistics of a

number of the cases treated by gymnastic exercises, which illustrate the same point.

A.—Age when Treatment was Begun.

Age when examined.	*Males.*	*Females.*	*Total.*
4 years	0	1	1
5 "	0	1	1
6 "	1	1	2
7 "	4	2	6
8 "	4	7	11
9 "	4	4	8
10 "	2	7	9
11 "	3	13	16
12 "	3	16	19
13 "	4	28	32
14 "	5	25	30
15 "	3	21	24
16 "	8	14	22
17 "	2	6	8
18 "	1	2	3
19 "	0	1	1
20 "	0	1	1
21 "	0	4	4
23 "	0	1	1
24 "	0	1	1
32 "	0	1	1
	44	157	201

B.—Age when the Deformity was Discovered.

	Males.	*Females.*
Congenital (sex not stated)	2	...	...
During infancy (sex not stated) . . .	19	...	...
Between 3 and 6 years	16	10	6
" 6 " 10 "	41	10	31
" 10 " 13 "	62	6	56
" 13 " 15 "	27	3	24
Over 15 years	14	3	11
Unknown	20	...	...
	201	32	128

But 44 of the 181 patients (22.6 per cent.) were more than thirteen years of age at the time when the deformity was first noticed, although nearly 50 per cent. were older than this when treatment was applied for. In the first table it will be noted that of the 38 patients who were ten years of age or less 15, or about 40 per cent. of the number, were males. In 25 of the 37 patients in whom the deformity attracted attention at or before the sixth year rhachitis was the apparent cause.

Lateral curvature of the spine is one of the penalties of the erect posture, and the force of gravity must be considered both as a predisposing and as an exciting cause of the deformity.

The more direct tendency of the force of gravity is to cause the body to fall forward and to increase the posterior curvature of the spine, but whenever there is a persistent inclination of the

spine to one or the other side this inclination is likely to be increased to deformity under favoring conditions. These favoring conditions would include general weakness from any cause; overwork that may induce fatigue, and all factors, mechanical or otherwise, that may add to the difficulty of holding the trunk erect under the pressure of the superincumbent weight.

Although it is not difficult to suggest the predisposing causes of lateral curvature, it is by no means as easy to point out the direct cause of the original inclination of the spine to one or the other side of the median line that is the first step toward fixed deformity. In a certain number of cases, however, the relation between cause and effect is sufficiently evident, and these causes may be enumerated before considering the larger class in which the etiology is more obscure.

1. Lateral curvature secondary to deformity of other parts.
2. Static or compensatory deformity.
3. Deformity secondary to disease of the nervous system.
4. Deformity secondary to disease of the thoracic organs.
5. Incidental deformity.
6. Deformity due to occupation.
7. Congenital deformity.
8. Rhachitic deformity.

1. Lateral Curvature Secondary to Deformity Elsewhere. (*a*) Lateral curvature of the spine may be a compensatory effect of torticollis, either congenital or acquired. (*b*) It may be induced by distortion or inequality of the lower extremities. For example, fixed adduction of the thigh necessitates an upward tilting of the pelvis whenever the limb is brought into the normal line, whether the patient is standing, sitting, or lying; and this deformity when extreme may induce lateral curvature even in bedridden patients.

2. Compensatory Deformity. The same effect is sometimes observed in certain instances of inequality of the length of the lower extremities. In the erect posture the pelvis is tilted downward on one side, and this in turn necessitating a twist of the spine. Simple inequality of the limbs is an occasional but not a common cause of fixed deformity, because its influence ceases in the sitting and reclining postures, and because the inequality is so often compensated, if it be extreme, by walking on the toe or by raising the sole of the shoe.

An increase in the length of a limb, such as may be caused by a fixed equinus of the foot, seems to have more influence in caus-

ing secondary deformity than does shortening, because no attempt is made to compensate for the inequality.

3. Lateral Curvature Secondary to Paralysis. Lateral deformity of the spine may be caused indirectly by a number of distinct diseases of the nervous system, but in this connection only one need be considered—anterior poliomyelitis. This form of paralysis may act in several ways. It may induce deformity by distortion of a lower extremity or by inequality in the length of the limbs due to retardation of growth. It may predispose to deformity by the general weakness that it causes, or the trunk may be unbalanced by loss of function in one of the upper extremities, but the more extreme cases of deformity are caused by unilateral paralysis of the muscles of the trunk. As a result, the expansion of one side of the thorax is interfered with and the unaffected, or less affected, side taking on increased activity, develops at the expense of the disabled part. Thus, the convexity of the curve is usually toward the sound side.

4. Lateral Curvature Secondary to Disease within the Thoracic Walls. The most common cause of deformity of this class is persistent empyema. The lung is primarily compressed by the effused fluid, and its function is finally impaired or abolished by the adhesions that form between it and the chest wall, as well as by the extension of the disease to its structure. As a result, the side of the chest is retracted while the function of the unaffected lung is increased (Fig. 91). Thus, as in paralysis, the spine curves with the convexity toward the active side.

Other affections of the lungs that interfere with the function of one side may induce lateral curvature, but the influence is less marked and direct than in empyema.

5. Incidental Lateral Curvature. Lateral curvature may be caused by direct injury or by disease of the spine; for example, by fracture or by Pott's disease, or by other organic affections of the spine (Fig. 92). Distortion symptomatic of sacro-iliac disease, or the more marked deformity caused by sciatic or lumbar neuritis (Fig. 78), may if persistent finally induce slight permanent deformity, but such cases hardly deserve special consideration.

6. Lateral Curvature due to Occupation. Lateral curvature of a mild degree is incidental to certain occupations that require habitual inclination of the body. It is said to be very common among stone-cutters, for example. Such deformity developing after the growth of the body has been attained is of

interest as throwing light upon the etiology of the ordinary form of lateral curvature. For if habitual attitudes can thus change the contour of the developed spine, it is evident that similar postures, though far less constant, may influence the spine of a growing child, particularly in one predisposed to such distortion.

FIG. 91.

Scoliosis following empyema at the age of two years. Present age nineteen years.

FIG. 92.

Scoliosis secondary to lumbar Pott's disease in early childhood.

7. CONGENITAL LATERAL CURVATURE. Congenital scoliosis is uncommon in infants otherwise normal (Fig. 93), but several cases have come under my observation at an age sufficiently early to make the diagnosis absolutely certain. One case, in an otherwise well-formed male infant, was seen at the age of three months. There was well-marked lateral deviation with rotation in the dorsal region that had attracted attention soon after birth. A second case, in a female child, was seen at about

the same age. The deformity was extreme, and contracted tissues on the concave side prevented the straightening of the spine. There was also an accompanying lumbar hernia.

The first patient was cured by manipulation and posture before the completion of the first year; the second is still under treatment. A number of cases have been collected from literature by Hirschberger.[1]

FIG. 93.

Congenital scoliosis.

FIG. 94.

Rhachitic scoliosis.

8. RHACHITIC LATERAL CURVATURE. Rhachitis predisposes to deformity of all parts of the body by weakening the resistance of all the tissues. As is well known, the common deformities from this cause are the so-called rhachitic kyphosis that develops in the sitting child, and the distortions of the lower extremities in those who stand and walk. Lateral curvature of the spine

[1] Beitrag zur Lehr der Angeboren Skoliosen. Zeits. f. Ortho. Chir., 1899, B. vii., H. 1.

sometimes accompanies the kyphosis in those who do not walk, or it may exist independently of it. The lateral inclination is induced doubtless by the manner of sitting or by the manner in which the child is supported on the mother's arm; for at this period of rapid growth and increased susceptibility to deforming influences, even slight and temporary causes of this nature may be sufficient to induce the distortion (Fig. 94). Again, when the child begins to walk, the tilting of the pelvis due to distortion of the limbs, for example, to unilateral knock-knee, may also serve to disturb the equilibrium of the body and thus to induce lateral distortion.

How common rhachitic lateral curvature may be it is impossible to say, but it is probable that if all rhachitic infants and children were carefully examined this deformity would be discovered in many instances in which its existence had not been suspected.

Mayer[1] examined 220 rhachitic infants with reference to this point, and in all but 3 found scoliotic deformity. This is not in accord with my own experience, but I am convinced that rhachitis is of far greater importance in the etiology of lateral curvature of the spine than is generally believed, and that a large proportion of the severe and intractable cases may be traced to this cause.

In about 15 per cent. of the cases tabulated by Truslow the influence of one or more of the causes that have been enumerated seemed to be apparent, viz.:

Congenital deformity	2
Torticollis	2
Empyema	4
Anterior poliomyelitis	3
Inequality of the legs of more than half an inch	6
Rhachitis	13
Total	30

In the remaining 85 per cent. of the cases the direct cause of the deformity was uncertain.

Hereditary Influence. By many writers the influence of heredity is considered an important factor in the etiology. That there is such an influence, predisposing to disease as well as to deformity, is undoubted, but it is very difficult to establish its connection with the ordinary cases. In eleven of 201 cases, lateral curvature was present in either the father or mother of the patient; and in

[1] Bull. Médical, June 15, 1901.

seventeen others a brother or sister of the patient was deformed in a similar manner.

Occupation. It is well known that occupation may induce deformity in the adult, and one looks naturally to occupation as a factor in the causation of lateral curvature in childhood. Occupation in this class implies school, and it is well known that fatigue during school hours may induce improper postures, especially if the chair is unsuitable or uncomfortable. The influence of habitual posture is indicated in the statistics of lateral curvature among school-children recorded by Scholder, Werth, and Combe,[1] the proportion of deformity steadily rising from the lower to the higher classes (Figs. 95 and 96). Under the influence of constantly recurring fatigue an improper attitude is likely to become habitual, its character being influenced by the arrangement of the light or by the shape of the desk. When a habit of posture is acquired it is likely to persist when the sitting posture is assumed elsewhere than at school, and the greater liability of girls to the deformity may be explained in part by the fact that they sew, or read, or play on the piano, while boys are usually engaged during the same period in active exercise.

In 400 cases of lateral curvature under treatment at the Hospital for Ruptured and Crippled, the occupation and other habits that may have influenced the deformity were recorded :

Occupation :		
School		285
Factory		19
Clerk		13
Domestic		8
Millinery, dressmaking, etc.		8
Messenger		3
Housewife		3
Teacher		2
No occupation		59
Total		400
Posture :		
Weight on right foot	48	
" " left "	48	
		96
Carries books or baby on right arm	38	
" " " " left "	36	
		74
Sits at desk or work in faulty attitude		57
Carries heavy load on one shoulder		2
Excessive use of right arm in occupation		3
Total		232

The sitting posture is not the only one in which improper attitudes may be persistently assumed, in fact, it has been suggested that the posture during sleep may influence the inclination

[1] Loc. cit.

of the body during the hours of activity. But the sitting posture is the one in which the muscular support is most likely to be relaxed, and in which a tendency toward lateral inclination is most likely to be acquired, since children do not often retain a fixed attitude in the erect posture for any length of time. Bradford and Lovett record an observation of the attitudes of sixty-seven healthy adults undergoing a written examination. At the end of the second hour a lateral inclination of the body was evident in all, and in three-fourths of the number the general inclination

(*a*) With double lateral curves	22	
(*b*) With triple lateral curves	8	
	—	30
4. Lateral Deviation More Marked than Rotation; Direction of the Curves:		
Right dorsal, left lumbar type:		
(*a*) Single lateral curve	22	
(*b*) Double lateral curves	71	
(*c*) Triple lateral curves	6	
	—	99
Left dorsal, right lumbar type:		
(*a*) Single lateral curve	3	
(*b*) Double lateral curves	8	
(*c*) Triple lateral curves	3	
	—	14
Total		201

It will be noted that in twenty-one instances anteroposterior deformity existed without lateral deviation, and that in thirty-seven instances it was accompanied by lateral deviation. In the remaining 144 cases, rotation was more marked than lateral deviation in 30 cases, and lateral deviation more marked than rotation in 113. In the entire number of cases in which lateral deviation was present it was single in 39 cases, double in 117 cases, triple in 24 cases.

In 890 cases of lateral curvature tabulated by Schulthess the deformity was as follows:[1]



Posture induced by improper desk and chair. (Scudder.)

of the body was to the right. In about this proportion of the cases of lateral curvature the type of fixed deformity is to the left in the lumbar and to the right in the dorsal region, and it is natural to look upon the occupation as the important factor in determining the direction of the deformity. If it be assumed that the distortion is caused or influenced by the attitude assumed during school hours it would appear that the primary deformity should be more often of the lumbar region, for in the sitting posture the lumbar lordosis is lessened or lost, thus the bodies of

the vertebræ in the lumbar region are subjected to greater pressure than in the dorsal region—a pressure which might induce the accommodative changes in the bones that accompany persistent deformity.

The possibility of distinguishing the varieties of lateral curvature in which the primary distortion is lumbar from those in which it is dorsal, by the flattening of the dorsal kyphosis in the former, and its exaggeration in the latter instance, has been mentioned.

[illegible] Fig. 96, [illegible], and Combe,[illegible] the proportion of deformity steadily rising from the lower to the higher classes (Figs. 95 and 96). Under the influence of constantly recurring fatigue an improper attitude is likely to become habitual, its character being influenced by the arrangement of the light or by the shape of the desk. When a habit of posture is acquired it is likely to persist when the sitting posture is assumed elsewhere than at school, and the greater liability of girls to the deformity may be explained in part by the fact that they sew, or read, or play on the piano, while boys are usually engaged during the same period in active exercise.

In 400 cases of lateral curvature under treatment at the Hospital for Ruptured and Crippled, the occupation and other habits that may have influenced the deformity were recorded :

Occupation :	
School	285
Factory	19
Clerk	13
Domestic	8
Millinery, dressmaking, etc.	8
Messenger	3
Housewife	3
Teacher	2
[illegible]	59

Varieties of Deformity. According to statistics from various sources, about three-fourths of the well-developed double curves of the spine are convex to the right in the dorsal and to the left in the lumbar region, and, as the distortion of the thorax is more noticeable of the two, it usually classifies the deformity as right or left. The dorsal curvature may be either primary or secondary, and the relative frequency of the original deformity, whether lumbar or dorsal, is in doubt, with the probability in favor of the former.

Summary of varieties of deformity of the spine under treatment, 1899–1900, at the Hospital for Ruptured and Crippled, tabulated by Dr. Truslow :

1. Simple Anteroposterior Deformities:		
(*a*) Kyphosis	10	
Kypholordosis	1	
Lordosis	1	
	—	12
Round shoulders:		
(*b*) Abducted scapulæ	7	
Elevated scapulæ	2	
	—	9
2. Anteroposterior Abnormalities Most Marked, but Accompanied by Lateral Deviation:		
(*a*) With single lateral curve	14	
(*b*) With double lateral curves	16	
(*c*) With triple lateral curves	7	
	—	37
3. Rotation More Marked than Lateral Deviation:		
(*a*) With double lateral curves	22	
(*b*) With triple lateral curves	8	
	—	30
4. Lateral Deviation More Marked than Rotation; Direction of the Curves:		
Right dorsal, left lumbar type:		
(*a*) Single lateral curve	22	
(*b*) Double lateral curves	71	
(*c*) Triple lateral curves	6	
	—	99
Left dorsal, right lumbar type:		
(*a*) Single lateral curve	3	
(*b*) Double lateral curves	8	
(*c*) Triple lateral curves	3	
	—	14
Total		201

It will be noted that in twenty-one instances anteroposterior deformity existed without lateral deviation, and that in thirty-seven instances it was accompanied by lateral deviation. In the remaining 144 cases, rotation was more marked than lateral deviation in 30 cases, and lateral deviation more marked than rotation in 113. In the entire number of cases in which lateral deviation was present it was single in 39 cases, double in 117 cases, triple in 24 cases.

In 890 cases of lateral curvature tabulated by Schulthess the deformity was as follows:[1]

	Left.	*Right.*	*Total.*
Total scoliosis (single curve affecting the entire spine)	173	23	196
Lumbar scoliosis (single curve limited to the lumbar region)	63	34	97
Lumbodorsal scoliosis (single curve limited to lumbodorsal region)	184	164	348
Complicated scoliosis:			
(*a*) Right dorsal, left lumbar	...	191	...
(*b*) Left dorsal, right lumbar	58	...	249
	478	412	890

It will be noted that a very large proportion of these cases were in the early stage of deformity, as indicated by the absence of compensatory curves; that in 80 per cent. of the 293 cases in

[1] Zeits. f. Orth. Chir., 1902, Bd. x.

which the curve was general or most marked in the lumbar region, the inclination was to the left, and of the complicated or more fully developed cases in which the curve was double, 73 per cent. were of the right dorsal, left lumbar type.

Symptoms. In the large proportion of cases the first symptom is the deformity. This is often discovered by the dressmaker at the age when the clothing is made to fit the figure more closely. In certain instances the deformity may be preceded or accompanied by pain. This was present to a greater or less degree in about one-quarter of the cases examined by Truslow. Pain may be simply the discomfort or the "dragging" sensation of fatigue, usually referred to the lumbar region, or it may be severe and neuralgic in type. The latter variety is more common in the cases in which the deformity is extreme. It is said to be the result of pressure on nerves, but this cause is exceptional in ordinary cases, as it is as often referred to the convex as to the concave side. When the deformity is extreme—for example, when the ribs and the iliac crest are in contact—direct pressure undoubtedly explains the local discomfort referred to this region. There are also more general symptoms of a neurasthenic or hysterical nature that may be due in part to the deformity and in part to the debility of which it may be a result or accompaniment. For it must be borne in mind that lateral curvature is often symptomatic of general weakness, as is shown by the fact that it is often accompanied by other deformities, particularly by the weak foot. In many instances symptoms of weakness and awkwardness precede the deformity. Truslow states that in a large proportion of the cases investigated the patients had been distinctly less active than their companions, that they did not enjoy exercise, and were inclined to lead sedentary lives. Teschner[1] has called attention to the same peculiarity. He states that the patients are often indifferent, apathetic, and lazy. He has noted also a peculiar lack of co-ordination and muscular control as a common accompaniment of the deformity. These symptoms apply particularly to the period of adolescence, the time of rapid growth and instability, when any latent deformity or weakness is likely to be exaggerated. In younger subjects such symptoms are far less marked or are absent. In the cases in which the deformity is extreme, symptoms due to interference with the respiratory and circulatory apparatus, or to

[1] Medical Record, December 16, 1893.

displacement of the abdominal organs, may be present. These are, however, rather unusual.

Diagnosis. Posture. Lateral curvature of the spine is a simple deformity unaccompanied by the symptoms of disease. When the patient stands with the back and hips bare, the inclination of the body to one or the other side and the general want of symmetry are usually apparent, even in the earliest stage of the affection. For, as has been stated, the habitual assumption of a certain posture precedes fixed changes in and about the spine, and this posture will appear when the patient is asked to stand in the usual manner. If the inclination of the body is toward the left (Fig. 80), the left arm will hang in close apposition to its lateral border, while on the right side an interval will appear between the arm and the trunk. If there be a slight lumbar curve to the left (Fig. 82), the right iliac crest will be accentuated. The curvature in the dorsal region makes one shoulder higher than the other (Fig. 91), the scapula on the affected side projects, and the distance between its posterior border and the median line is increased. Rotation of the spine is shown by the fulness or projection of one side accompanied by a corresponding flatness on the other. This is more noticeable when the patient bends the body forward so that the horizontal plane of the back is brought into view (Fig. 81). Corresponding changes, though of a less marked degree, appear on the anterior surface of the body; for example, the apparent diminution in the size of the mamma on the side opposite the convexity of the posterior curve and its relative depression or elevation may attract attention.

It seems probable that a change in the anteroposterior contour of the spine precedes, in many instances, the lateral deviation. Thus, a general droop of the body associated with round shoulders and a flattening of the chest may be regarded as a predisposing cause or an early symptom of more serious deformity.

Mobility. As has been stated, it may be assumed that habitual posture precedes actual deformity. Habitual posture implies disuse of certain attitudes and motions, thus limitation of the normal flexibility of the spine may be considered as one of the earliest signs of progressive deformity. The test of the motion of the different regions of the spine is, therefore, a necessary part of the examination. To test the motion in the lumbar region, one fixes the pelvis with the hands while the patient sways the body in the four directions and rotates it from side to side. It is suggested by Bradford and Lovett that direct lateral flexibility may

be tested by placing blocks of wood under one foot until the limit of lateral flexion is reached, as shown by the inability of the patient to hold the elevated limb in the extended position. The experiment is then repeated on the opposite side. The flexibility of the upper part of the trunk may be tested by fixing the part below with the hands while the patient flexes, extends, and rotates the body. It is important, also, to test the range of motion at the shoulder-joints. The normal individual should be able to

FIG. 97.

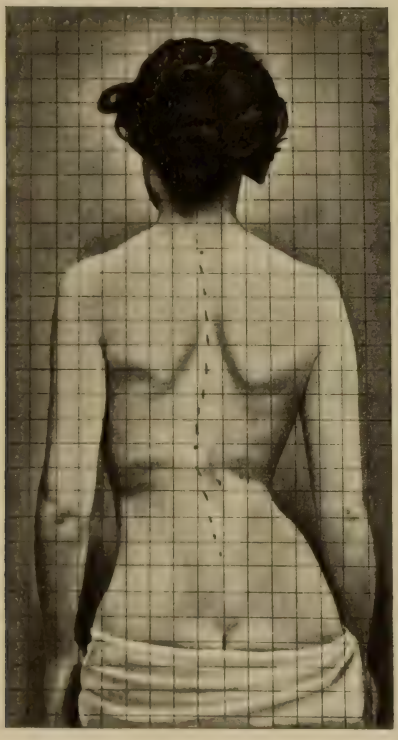

The thread screen. From the Boston Children's Hospital Report.

hold the arms extended directly above the head without increasing the lumbar lordosis. In many instances, however, it will be found that there is a marked restriction of this motion; in fact, such restriction is almost always an accompaniment of so-called round shoulders.

The height and weight, the circumference and the expansion of the chest should be investigated, and a test of the muscular

strength, not only of the muscles of the trunk, but of the members as well, is of advantage as throwing light on the etiology and indicating the general line of treatment.

Record. The most reliable of the graphic records to be used in connection with the history are photographs. The patient may stand behind a thread screen (Fig. 97) in the habitual attitude. The spinous processes, the iliac crests, and the angles of the scapulæ having been marked, the exact amount of lateral deviation of the trunk will be shown. The rotation may be indicated also by photographing the patient in the recumbent posture.

The rotation of the spine is the most important indication of deformity. This may be recorded with sufficient accuracy by taking direct tracings of half the trunk at fixed points by means of a lead or zinc tape while the patient lies in the recumbent posture.

At the Hospital for Ruptured and Crippled the shadow of the trunk cast by an electric light at a fixed distance is traced upon a large sheet of paper. Upon this outline the position of the more important landmarks is indicated. The degree of rotation is shown by transverse tracings and the line of the spinous processes is ascertained by applying a broad strip of adhesive plaster to the back upon which the tip of each spinous process is marked. The anteroposterior outline of the spine should be recorded, also the general attitude and the presence or absence of other evidences of weakness such as knock-knees and weak feet.

Prognosis. In the development of lateral curvature there is doubtless a preliminary or predisposing stage—a stage of progression and a stage of arrest. All deformities of this class are more likely to progress during the growing period. They are likely to become stationary when the period of growth is completed. Thus, the prognosis is worse when the deformity begins at an early age than when it first appears in adolescence. The most extreme and intractable of the simple cases are the result of rhachitis, in which the deformity appearing in infancy or early childhood has increased with the growth of the child.

If the causes of deformity are such that they operate to check the equal development of the affected part, the prognosis is even more directly influenced by the age of the patient. For example, empyema, even if the lung is irreparably damaged, does not cause appreciable deformity in the adult, but in childhood the functional activity and the growth of the side of the thorax are checked, in

addition to the direct effect of the adhesions and contractions due to the disease; thus, the deformity is likely to be progressive in spite of the treatment. The same is true of paralytic deformity. In the ordinary type of lateral curvature in the adolescent girl, the prognosis is influenced, of course, by the general condition of the patient and by the character of the occupation. As far as the local deformity is concerned, the prognosis as regards improvement or cure depends in great measure upon the fixed changes that have taken place, and upon the degree of voluntary and involuntary rectification that is possible. In some instances the postural distortion may be considerable, yet the fixed deformity may be very slight, while in other instances the fixed rotation of the spine may be marked, although the lateral distortion is less noticeable.

A single curve is more amenable to treatment than is a double or triple distortion, because it indicates an earlier stage of deformity and because the treatment may be more effective when applied to one deformity than to several. If, however, the single curve is fixed, the appearance of a secondary or compensatory curve at another part of the spine is probable, in spite of preventive treatment.

In the majority of cases, fixed deformity of the spine as indicated by rotation is already present when the patient is brought for treatment. This fixed deformity might be overcome doubtless in certain cases, and complete cure might be obtained were all the conditions favorable. But in the ordinary sense a cure means the relief of symptoms, the checking of the progress of deformity, and the restoration of the general symmetry of the trunk. Such a cure may be obtained in most instances. The deformity of the spine becomes symmetrically divided on either side of the median line, the changes incident to maturity, particularly the increased amount of adipose tissue, serve to conceal the irregularities of the outline, and the history of the distortion is completed.

In certain instances, particularly in well-marked cases, the deformity may increase in adult life and even in old age. In such cases, the symptoms of discomfort and actual pain may be troublesome throughout life, especially in the overworked and debilitated class. The symptoms directly incident to the compression and distortion of the internal organs have been mentioned.

The great majority of cases that develop or that are discovered

in adolescence progress for a time and come to an end on the cessation of growth, causing finally no symptoms other than the loss of symmetry that may be more or less satisfactorily concealed by the art of the dressmaker and by the corset.

It would appear, then, that lateral curvature of the spine is always of sufficient gravity to merit treatment and supervision until its cure or arrest is assured. If its discovery leads to active efforts to improve the general condition and to avoid unhealthful influences it may be even of benefit to the patient.

Lateral curvature in a young child is of far greater importance because of the probability of an increase of deformity. Extreme deformity is always a source of weakness and usually of discomfort to the patient. Incipient deformity may be cured and cure is not impossible even when deformity is more advanced, but in this more than in any other postural deformity, absolute cure implies early diagnosis and prevention, rather than the correction of fixed distortion.

Recapitulation. It seems probable that in the ordinary type of lateral curvature of the spine the first step is a change in the relation of the bodies of the vertebræ to one another; that a persistent lateral inclination and rotation of the anterior part of the column precedes the lateral inclination of the trunk which first calls attention to the deformity. This postural distortion becomes fixed by accommodative changes in the muscles and other tissues about the spine, and, finally, it is confirmed by changes in the shape of the vertebral bodies and by the general changes in the trunk as a whole. Thus, if one might observe the inception and development of lateral curvature of the common type he would note, first, that the trunk was more often flexed to one side than to the other, and that this attitude gradually became habitual. Lateral inclination of the trunk necessitates, of course, lateral deviation and rotation of the bodies of the vertebræ, and the habitual assumption of such a posture implies disuse of other postures and thus disuse of normal motion.

Disuse of motion in any direction is followed by diminished power in the inactive muscles, and, as has been stated, habitual deformity is followed by accommodative changes to a greater or less degree in the various tissues whose functions have been changed or modified.

Thus the progress of the deformity would be shown:

1. By the habitual assumption of an attitude simulating deformity.

2. By limitation of motion in the directions opposed to the habitual attitudes.

3. By fixed lateral deviation of the spine accompanied by rotation or twisting of the column.

One rarely has the opportunity to note the development of lateral curvature, and when patients are brought for treatment fixed deformity is usually present. It is extremely difficult to entirely overcome fixed distortion, while it is comparatively easy to correct simple postural deformity in which the secondary changes are absent or but slightly advanced. On this account it is customary to divide lateral curvature into two classes—the *true* and the *false*—or to speak of rotary lateral curvature as distinct from lateral curvature. Thus, the term true or rotary curvature would be limited to those cases in which the changes are fixed and in which cure is practically impossible, while false or simple or postural lateral curvature would include the early or curable class. But as the two forms are simply stages in the same process it would seem preferable to speak of the incipient and the later stages of lateral curvature, or of *reducible* or *irreducible* deformity, the distinctions that are made in classifying distortions of similar origin elsewhere.

This point of view is of advantage because it relieves the subject of much of the obscurity that has resulted from this arbitrary division. It emphasizes the fact, also, that the habitual assumption of an improper attitude that simulates deformity is the first step toward permanent distortion, particularly in individuals who by inheritance or by constitutional tendency or by occupation are predisposed to such deformity.

The Prevention of Deformity. Prevention includes the avoidance of all the predisposing or exciting causes of weakness as well as of deformity. These it is hardly necessary to enumerate.

The first and most important preventive measure is the discovery of deformity or the tendency to deformity at a time when it may be checked or cured. To discover deformity at this period of its development one must look for it, and it would seem that a yearly inspection at least of the naked bodies of all children should become a routine practice of the family physican. Deformity in this sense includes not only fixed distortions, but improper attitudes and postures of every variety as well.

The importance of the attitude which is habitually assumed during occupation has been mentioned. Therefore, the provision

of proper *desks and seats for school-children* is a very essential part of preventive treatment.

The seat of the chair should be deep enough to support the thighs, yet it should not interfere with flexion at the knees. It should be of such height as to allow the feet to rest firmly on the floor, and it should be inclined slightly backward. The back of the chair should extend to about the level of the shoulders; it should be inclined slightly backward, but arched somewhat forward in the lumbar region in order to conform to the normal lordosis when the child sits in the erect posture. The desk should be as close to the body as is possible, so that the child need not lean far forward when reading or writing. The height

FIG. 98.

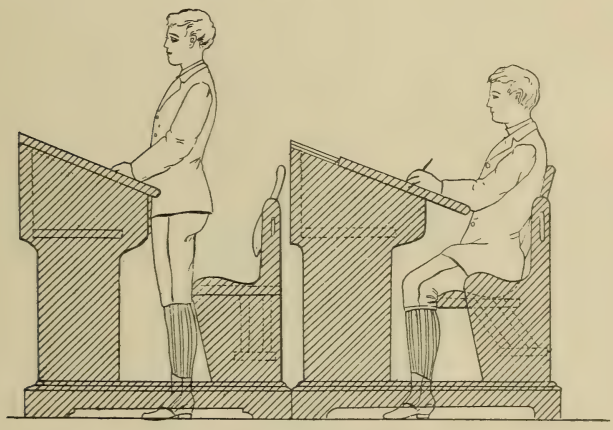

Adjustable school desks and seats. Scheiber and Klein. (Rédard.)

of the desk should be slightly less than the level of the elbows when the child sits erect, and the inclination should be sufficient to hold the book at the proper distance from the eyes (Figs. 98 and 99). The vertical handwriting is of advantage in that the children are taught to face the desk squarely, as contrasted with the lateral twist of the body, the usual attitude for writing.

Treatment. The treatment of rotary lateral curvature of the spine does not differ in principle from the treatment of any other weakness or deformity, but the application of this principle is difficult and the results are far from definite and satisfactory. This explains, doubtless, the apparently opposing theories and methods of treatment that are still advocated.

A brief account, then, of the rules of treatment as applied to

weakness in general and of the exceptions that must be made in their application to curvature of the spine may be illustrated by comparing this deformity with another of similar causation.

One may take for comparison the weak foot, since the foot corresponds more nearly to the spine than does a simple joint, because of the number of bones of which it is made up. In the treatment of the weak foot one must first overcome all restrictions to passive motion, even by force, if this be necessary. One next endeavors to strengthen the muscles that support the foot, by

FIG. 99.

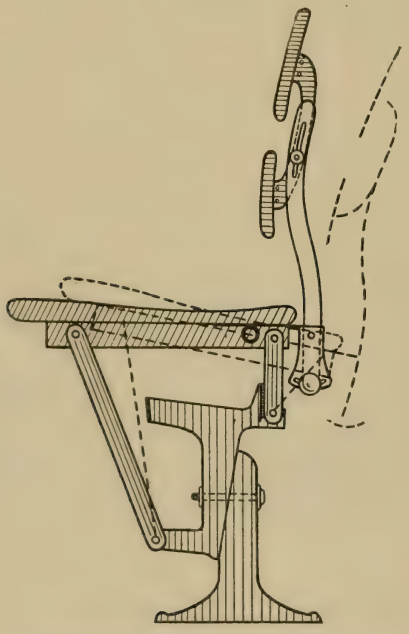

Adjustable school seat. (Miller and Stone.)

appropriate exercises, particularly those whose action is opposed to the habitual deformity. The avoidance of improper attitudes and of overfatigue that favor deformity is also essential. Finally, if persistent deformity makes it evident that the voluntary or natural efforts of the patient are inefficient, a brace is employed to support the foot in proper position in order to aid the weakened muscles and to hold the joints in the normal position in which they may work to advantage. Under these conditions one would expect an immediate relief of discomfort and a progressive transformation of the internal structure of the foot, which in favorable

cases would lead to complete cure of the deformity and of the weakness as well.

The principles of the treatment of any variety of weakness not directly induced by disease are, then:

1. To overcome all restriction to passive motion.

2. To strengthen the weakened muscles, especially those whose action is opposed to habitual deformity.

3. To insist on the avoidance of overfatigue and improper postures.

4. To support the weak part by a brace if deformity cannot be prevented otherwise.

In applying these principles to the treatment of the distorted spine the first step, the removal of restriction to passive motion in all directions, is difficult because of the variety of muscles and other tissues that may have become involved, and because the bodies of the vertebræ lying within the trunk, of which the distortion is always greater than of the spinous processes, can be only indirectly affected by voluntary or by passive movements.

The cultivation of the muscular system, and particularly of those muscles whose action is opposed to the habitual deformity, is the second indication in treatment. As applied to the treatment of the weak foot in which the adductor and extensor muscles are at fault, this treatment is simple, but as applied to the trunk it is difficult, because there are in nearly all developed cases two curves, the one primary and the other secondary, in direction directly opposed to one another. These opposing curves are supplied in great part by the same muscles, and it is difficult by voluntary effort to straighten the convexity of one without at the same time increasing that of the other.

The third principle in treatment is the avoidance of predisposing attitudes and of overwork. This again may be more easily applied to the treatment of the weak foot; first, because it is relieved from strain when the sitting posture is assumed, and because active use, as in walking, may be utilized as an exercise for strengthening the muscles. But the muscles of the trunk are not exercised to any extent in ordinary walking, which is for many individuals the only form of activity, nor is the spine relieved from weight when the patient is seated. On the contrary, it is in this restful attitude that the deformities of the spine are usually most marked. Thus, only in the recumbent attitude is the spine entirely relieved from strain, and even at such times

the deformities may be favored by the habitual attitudes of the patient.

The weak foot can be supported by a brace, which does not interfere with its activity, but which, on the contrary, aids normal motion by holding the bones in proper relation to one another. But in the treatment of the spine the conditions are quite different, since the back cannot be supported without at the same time restraining its normal motion. Finally, no brace applied to the trunk is efficient, for while it may prevent the lateral deviation it can exercise little direct action in overcoming the rotation of the spinal column.

This comparative method of exposition has been adopted in order to illustrate the fact that it is not the difficulty of formulating principles, but the difficulty of applying them that makes the therapeutics of rotary lateral curvature of the spine perplexing. In practice one must recognize the limitations of all systems of treatment as applied to this particular deformity, and select and combine methods that may be most applicable to the particular case under treatment.

For example, in the treatment of *rhachitic scoliosis* in a young child one cannot count upon the voluntary assistance of the patient; therefore, treatment by simple gymnastic exercises is impracticable. In this class of cases forcible correction of the deformity and retention by the use of apparatus, combined with massage, and even the removal of superincumbent weight by recumbency would be the treatment of selection. At this age the trunk is flexible and the deformity may be progressively reduced by forcible manipulation, followed by fixation of the trunk in the improved position. By such means one may expect at this period of rapid growth to induce a transformation of the deformed vertebral bodies to an approximation at least of the normal. In such cases the correction of the underlying deformity of the bones which must almost inevitably increase with the growth of the patient would quite outweigh the disadvantage of depriving the muscles of their normal stimulus during the corrective period of treatment.

In the *ordinary type of scoliosis* in older subjects, particularly if the distortion is moderate in degree and the changes in the bones but slight, one would expect to attain the best result by gymnastic training and by regulation of the postures. Although even in this class supports may be of service, if by such means the trunk may be held in an overcorrected attitude until the deformity habit is overcome.

The advisability of a change of occupation has been mentioned. It is probable that if the patient with incipient or even more pronounced curvature of the spine were removed from school, were transferred to the country where during the succeeding years of childhood and adolescence much of the time might be passed in active exercise in the open air, the final result would compare very favorably with that attained by active treatment under less favorable circumstances. Such complete change of occupation and surroundings is, of course, impracticable in most instances. Lateral curvature of the spine is not a serious disease, it is simply an insidious distortion which rarely causes more than comparatively slight discomfort. It is usually overlooked in the incipient stage when it might be checked or cured, and when the deformity finally attracts attention it is often no longer amenable to correction. Under these circumstances, with the uncertainty that exists as to the ultimate prognosis, the tediousness of treatment which cannot offer the assurance of definite cure, it is not strange that the affection is not one for the treatment of which any considerable sacrifice is considered essential.

A third class of cases would include the *fixed deformity in older subjects*, many of whom are obliged to assume in their occupations attitudes that predispose to deformity. In the treatment of this class a support to relieve discomfort and to prevent exaggerated distortion may be essential.

Thus, there are three classes or types of scoliosis in which distinct methods of treatment may be employed.

1. Curvatures in very young children, in which forcible correction and fixation are indicated in the hope of correcting the deformity of the bones and curing the distortion.

2. The milder degrees of deformity for which treatment by exercises and if possible by favoring postures is that of selection, and in which support is a temporary and incidental adjunct.

3. The third class would include fixed deformity in older subjects as well as those cases caused by disease; as, for example, by paralysis, by empyema and the like, for which constant support might be required.

As a rule, however, no absolute therapeutic distinction can be made, and treatment by exercises and by postures should be employed whenever practicable in all cases, whether supports are used or not.

Posture and Exercises. Whatever may have been the original cause of the distortion of the spine and whatever may be its

degree it is more marked when the patient is fatigued. Fatigue in the normal individual is shown by the increase in the normal anteroposterior curves; fatigue in the deformed subject causes an increase in the pathological curves. It requires far more muscular effort to hold the deformed spine in the best possible attitude than to hold the normal spine in the correct posture. Motion in the normal spine is as free in one direction as in another, and it simply requires a proper balancing of the muscular force to hold it in the median line. Under the influence of fatigue it has no more inclination toward one side than the other unless the occupation or the attitude of the patient influences it. But when there is a fixed deformity, to overcome which, even in part, requires the conscious effort of the patient, it is evident that on the relaxation of this effort the spine will sink back into the habitual posture. The more confirmed the deformity the greater must be the effort to overcome it, and the more rapidly will fatigue be manifest. Fatigue, or, rather, the relaxation of conscious muscular effort, is favored by attitudes that do not require the balancing action of the muscles. For example, the sitting posture during school hours favors deformity, while the constant alternation of postures in work or play that requires muscular activity opposes it. Thus, the selection of occupations, or, at least, the restriction of the time passed in inactive postures, is an important part of treatment.

As improper attitudes are favored by weakness of muscles and as the maintenance of the best possible position requires a greater expenditure of muscular force than is required in the normal individual, the strengthening of all the muscles of the body, and particularly of those of the back, by gymnastic exercises, even beyond the normal standard, is the most important indication in treatment.

One of the most effective systems of treatment of lateral curvature is that advocated by Teschner, of New York. On the theory that lateral curvature is induced by or that its development is favored by a general lack of muscular strength and lack of muscular control and co-ordination, Teschner urges the necessity of the systematic cultivation of all the muscles of the body as well as those of the trunk, the part particularly at fault. He also insists upon the importance of exercising each muscular group to the point of fatigue on the theory that a muscle cannot be developed to its full capacity unless it is thoroughly fatigued by uninterrupted automatic contractions and relaxations. The term

automatic implies that the patient shall be so thoroughly trained in the rhythmical movements that they require no thought for their performance. Thus, ease and grace may replace awkwardness and inco-ordination.

The system advocated by Teschner is modified from one taught by Attilla, a "trainer of strong men." It consists of a series of exercises with light dumb-bells, and it is followed by so-called heavy work. The exercises are designed for systematic cultivation of all the muscles of the body, the heavy work more directly for the correction of the deformity of the spine.

General Exercises. The exercises should be performed before a mirror, the patient being clad in a close-fitting rowing suit, so

FIG. 100.

FIG. 101.

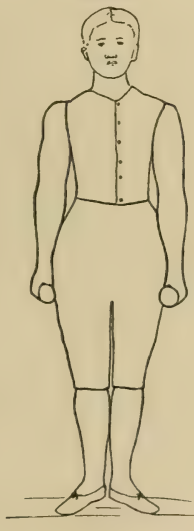

FIG. 102.

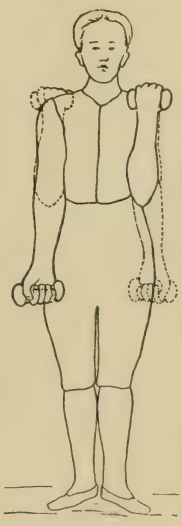

that the attitudes may be constantly observed by the patient and by the instructor. The greatest attention is paid to the perfection of the alternating movements of the limbs in order that they may become in time purely automatic in character. During the performance of the exercises the patient holds himself in the best possible position.

These exercises were described and illustrated by Teschner in the *Annals of Surgery* for August, 1895, from which they are, with his permission, reproduced.

"A pair of dumb-bells, weighing from one-half to five pounds each, according to the ability of the patient, is used in a series of twenty-six exercises.

"The Exercises. The patient stands erect, the heels together, the toes apart, the knees thoroughly extended, the abdomen retracted, the chest high, the head well poised, and the patient

Fig. 103.

Fig. 104.

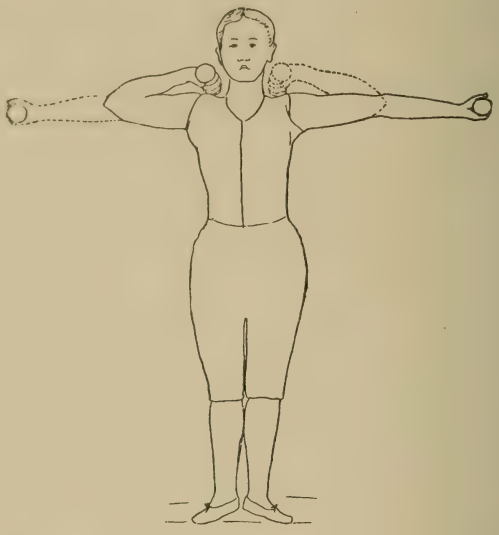

Fig. 105.

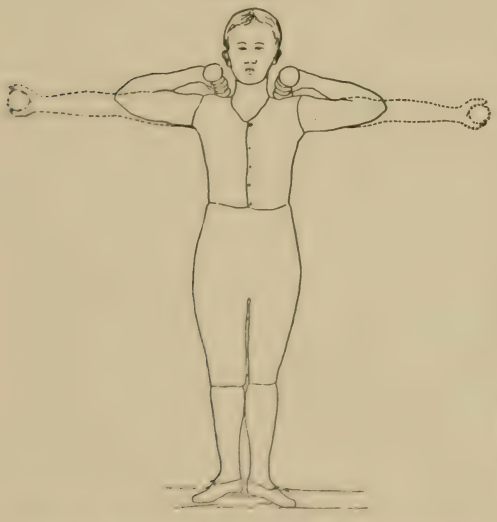

Fig. 106.

looking intently and sharply into his or her own eyes in the mirror, the lips being evenly, but not too firmly, closed, and the facial muscles in repose. The patient should breathe easily and regularly while exercising (Figs. 100 and 101).

"1. The upper extremities are fully extended downward, the forearms supinated, the elbows remaining close to the sides of the

Fig. 107.

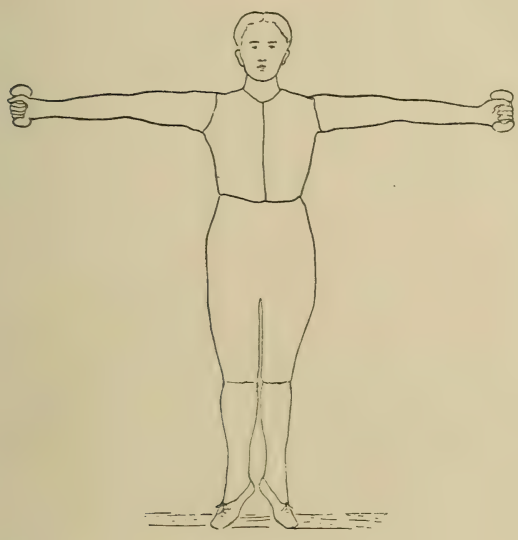

Fig. 108.

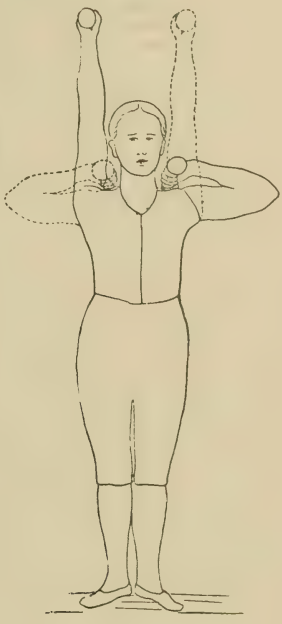

Fig. 109.

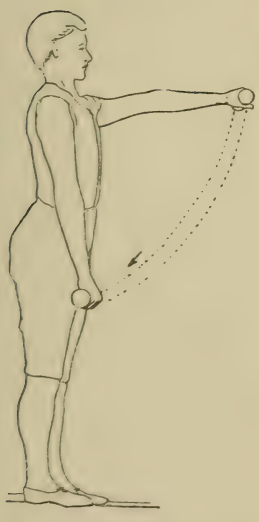

Fig. 110.

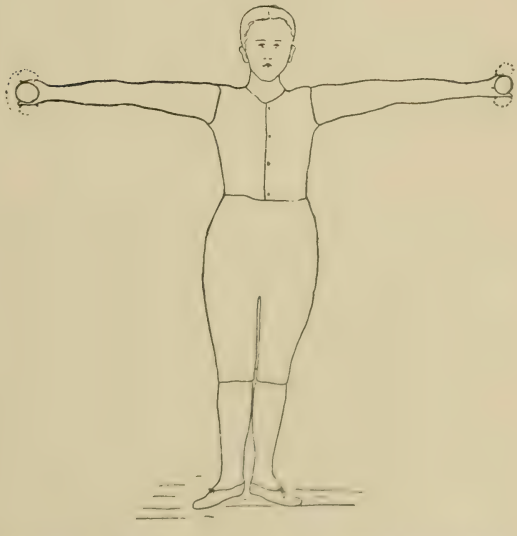

body, and the upper arms being fixed; the forearms are alternately and automatically fully flexed and extended, the wrists and

entire body being fixed and immovable. Twenty to fifty times (Fig. 102).

"2. The same position and exercise, except that the forearms, are fully pronated, and remain so during alternate flexion and extension. Twenty to fifty times (Fig. 103).

"3. Both bells over the shoulders, the arms abducted at right angles to the body and in the same vertical and horizontal planes, the forearms fully flexed upon the arms, and the wrists fully flexed upon the forearms. The forearms and wrists are then alternately and automatically extended and flexed. Ten to twenty times (Fig. 104).

FIG. 111.

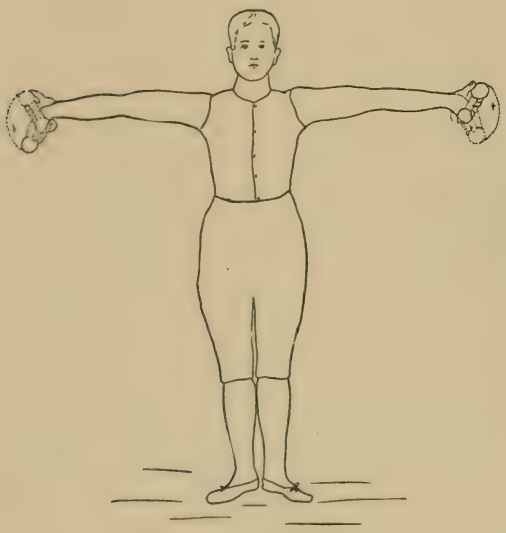

FIG. 112.



"4. The same position and exercise, except that both upper extremities are flexed and extended at the same time. Five to fifteen times (Fig. 105).

"5. Both upper extremities fully extended forward on a level with the shoulders, the dorsum of the hands outward. They are then fully and forcibly abducted on a horizontal plane, the patient at the same time raising the body upon the toes, and are then permitted to recede to the original position, the body resting on the toes and heels, the elbows and wrists still rigid, the bells not being permitted to touch as they approximate each other. Five to ten times (Figs. 106 and 107).

"6. Bells in the position of exercises No. 3 and No. 4. The

arms are fully extended alternately above the head. Ten to twenty times (Fig. 108).

"7. Bells in front of the thighs, forearms pronated, and bells alternately raised to the level of the shoulders, the elbows and wrists being fixed. Ten to twenty times (Fig. 109).

"8. The arms abducted at right angles to the body, the bells rotated rapidly and forcibly forward and backward, the elbows being fixed. Five to ten times (Fig. 110).

"9. The arms abducted at right angles to the body, the thumbs upon one ball of each bell, the hands circumducted forward from

FIG. 113. FIG. 114. FIG. 115.

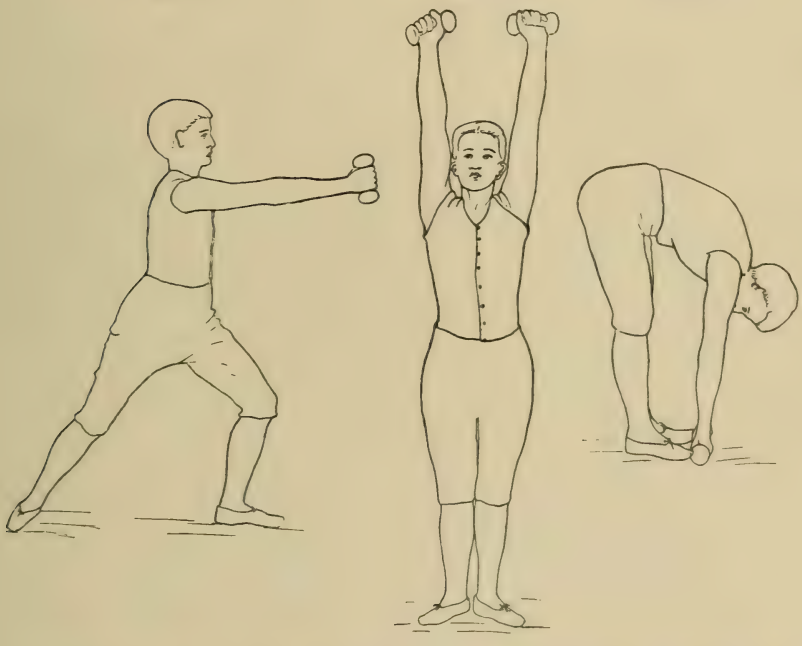

above downward, the ball upon which the thumbs rest describing circles, the elbows and shoulders being fixed. Five to ten times (Fig. 111).

"10. The same as No. 9, the hands being circumducted backward. Five to ten times (Fig. 111).

"11. The bells to the side. Right face upon left heel, then placing the foot at right angles to right foot opposite the arch, the knees slightly flexed, the right hand at waist-line against the body, the bell being perpendicular. Second part of motion: strike from the shoulder to level of the face, advancing a step

upon the left foot, rapidly extending the right thigh and leg, the right foot being fixed upon the floor, and quickly back to position. Ten to fifteen times (Figs. 112 and 113).

"12. Exactly the reverse of No. 11. Ten to fifteen times.

"13. Bells extending above the head, palmar surfaces looking forward, bending down to the floor, the knees remaining extended, and return. Five to fifteen times (Figs. 114 and 115).

"14. Bells downward at the sides, raising and dropping the shoulders. Ten to twenty times (Fig. 116).

"15. Bells downward at the sides, flexing the spine laterally, first to the right and then to the left. Ten to twenty times (Fig. 117).

FIG. 116.

FIG. 117.

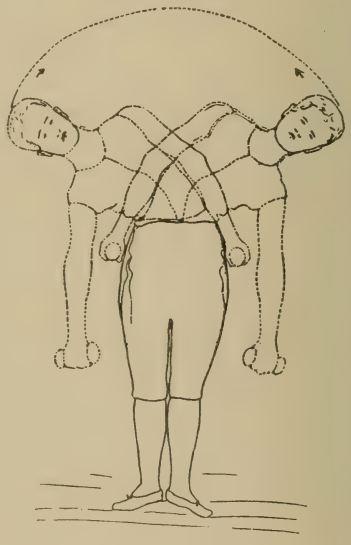

"16. Both arms are extended forward to about forty-five degrees and abducted at about the same angle, then forcibly crossed in front of the chest, causing the pectoral muscles to contract vigorously, the elbows and wrists being fixed, and then back to the original position. Five to twenty times, alternating the right and left hands above (Fig. 118).

"17. Bells at the sides, palmar surfaces looking forward. Extend arms backward in a vertical plane as forcibly as possible, holding them rigid in the fully extended position for a few moments, and then returning the bells to the sides. Five to fifteen times (Figs. 119 and 120).

"18. Bells to the sides. Raise the body upon the toes and sink to the original position. Ten to twenty times (Fig. 121).

FIG. 118.

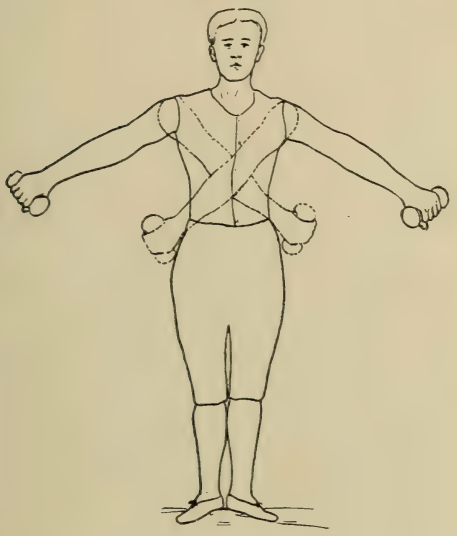

FIG. 119.

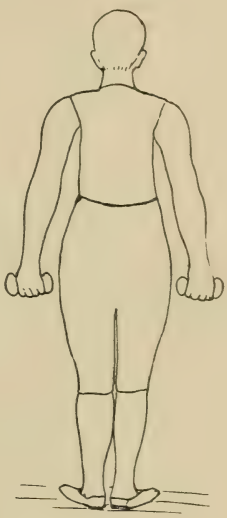

FIG. 120.

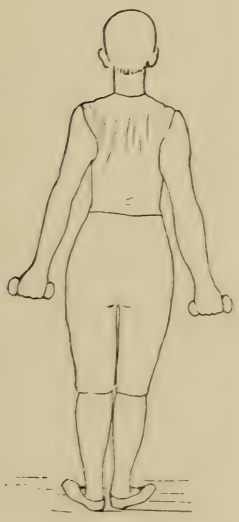

FIG. 121.

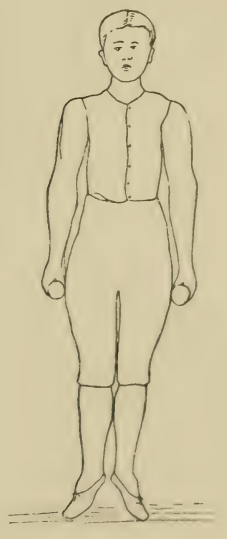

"19. Same position. Raise the toes as far as possible from the floor, the body remaining erect. Ten to twenty times (Fig. 122).

"20. Same position. The patient squats, abducting the knees and resting upon the toes, the heels being raised, the trunk perfectly erect, then resuming first position. Five to twenty times (Fig. 123).

FIG. 122.

FIG. 123.

FIG. 124.

FIG. 125.

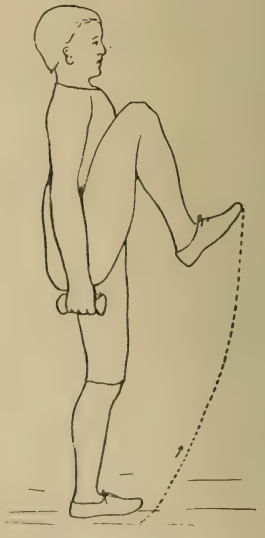

"21. Same position. Standing upon left foot. Flexing the right thigh to a right angle to the body, extending the knee and

ankle fully. The patient squats on the left ham, the left heel remaining on the floor, and then resumes the first position. Two to five times (Fig. 124).

"22. The same standing upon the right foot. Two to five times.

FIG. 126.

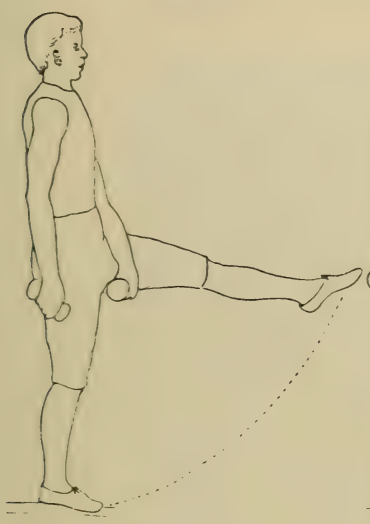

FIG. 127.

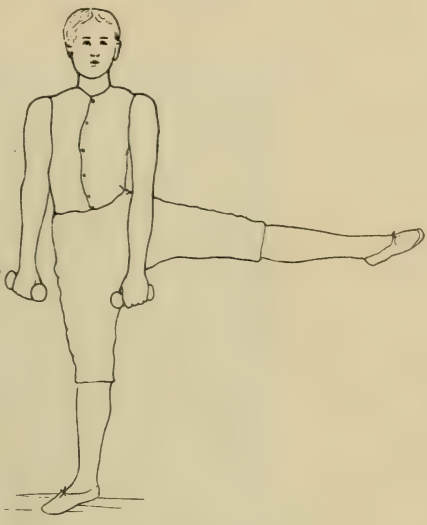

"23. The same position. Alternately and forcibly flexing the thighs and legs, causing the knees to touch the shoulders. Ten to twenty times (Fig. 125).

FIG. 128.

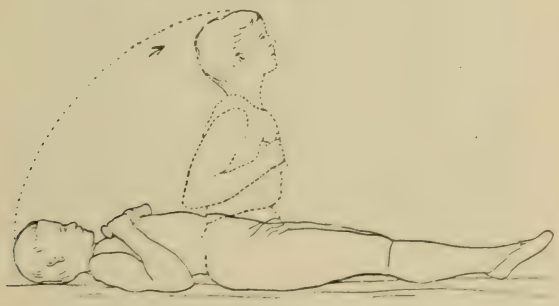

"24. The same position as in No. 21, extending the right lower extremity, the right bell inside the thigh, the right foot moved in a circle on a horizontal plane to complete extension backward, and resuming the first position. Two to five times (Figs. 126 and 127).

"25. The same as No. 24, standing upon the right foot. Two to five times (Figs. 126 and 127).

"26. The patient lying supine upon the floor, the lower extremities fully extended, the bells resting upon the chest, then raising the trunk to the sitting position, the lower extremities remaining extended, and the eyes being fixed upon the ceiling,

FIG. 129.

Scoliosis of an advanced type accompanied by dyspnœa and cyanosis. (Teschner.)

and returning to the original position, touching the back of the head only on the floor; thus the hyperextension of the spine is maintained. Five to twenty times (Fig. 128)."

I consider these floor exercises especially useful, and, in practice, add several others to those described by Teschner, viz.:

27. The patient lying as in Fig. 128, lifts each fully extended leg alternately a distance of about two feet from the floor, then lets it slowly sink to its original position. Ten times.

28. Both limbs together. Five times.

29. The patient lying extended in the prone position, places the palms of the hands on the hips and "looks at the ceiling," overextends the spine as much as possible, then sinks slowly to the original position.

FIG. 130.

The same patient swinging 30-pound bell, showing the muscular development. (Toschner.)

30. Each leg fully extended is lifted upward alternately as far as possible (hyperextension at the hips). Ten times.

31. Hyperextension at both hips simultaneously if possible. Five times.

"When the patient has become proficient in these exercises, they should be done at home every morning and evening.

"The Heavy Work. Bells, weighing from five to eighty pounds each, and steel bars and bar-bells, weighing from twenty-six to over one hundred and eleven pounds, are used in different ways. Bells are pushed from the shoulders above the head alternately as often as the patient is able (Figs. 131 and 132).

Fig. 131.



The patient pushing 25-pound bells; the right arm up. (Teschner.)

Fig. 132.

The patient pushing 25-pound bells; the left arm up. (Teschner.)

"The patient is instructed to swing a heavy bell with one hand from the floor above the head and down again, the elbow and the wrist being fixed, and the motion repeated as often as possible in a systematic manner; then with the other hand the same number of times and later with both. This exerts all the extensor muscles from the toes to the head in rapid succession.

(For this exercise the patient stands firmly, with the legs astride of the heavy bell, and then, bending over, he seizes it and throws the extended arm upward entirely by the action of the back muscles. The bell is poised for a moment above the head, and it is then swung downward, carrying the extended arm between and behind the legs.)

"When a heavy bell is pushed or swung above the head on the side opposite the scoliosis, the action of the back muscles, to sustain the weight and equilibrium, is such as to cause the curved spine to approximate a straight line (Fig. 132). A similar result is produced when a heavy weight is held by the side of the erect body on the scoliotic side, the arm being at full length.

"When a heavy bar is raised above the head with both hands the patient must fix the eyes upon the middle of the bar to maintain an equilibrium. This necessitates the bending of the head backward, the straightening and hyperextending of the spine, and consequently correcting a faulty position with a weight superimposed. The heavier the weight put above the head, whether with one hand or with two, the more the patient must exert himself or herself to attain and maintain a correct or an improved attitude in order to sustain the equilibrium. (By an improved attitude I mean the greatest amount of correction of the deviation of the spine that the fixation of a deformity will allow of.) Hence, the greater the weight, the more forcible the actions of the muscles become, and the greater the temporary reduction of a deformity. It is by means of frequent and forcible temporary reductions of deformities, by voluntary muscular action, that we can hope to improve, and do improve, those cases which are amenable to any form of active treatment.

"When a patient, lying supine upon the floor, raises a heavy bar above the head so that the arms are perpendicular to the floor, the weight of the bar, the position and weight of the body, and the action of the muscles tend to broaden the entire back and shoulders, and a slow downward movement tends to widen the entire chest, and most markedly at the shoulders. The frequent repetition of the upward and downward movements plays an important part in the rapid development of the chest and back. Pushing the bells above the head, swinging them with each hand separately and with both hands together, raising a bar above the head, standing and lying down, and the exercises before enumerated, constitute one day's work.

"As the amount of work performed by a patient depends

upon the last previous record of that patient, that record must be improved upon at each succeeding visit, unless there be a good reason to the contrary. Most patients can well stand three treatments a week (*vide* table). In mild, habitual cases improvement in deportment is noticed by the patient's relatives and friends and by the patients themselves within the first two weeks. In these cases two months' treatment usually suffices to effect a 'complete' cure. In the more severe cases such rapid results cannot be expected, but a certain appreciable improvement is effected, and the amount of improvement depends upon the persistent continuance of the treatment. When there is fixed rotation of long standing, with bony and ligamentous changes, the prospects are not so good; but even in those cases considerable improvement will be evident."

"Patients are not permitted to wear supports of any kind, not even corsets. They should not exercise until at least two hours after a meal, nor when menstruating. The general health is improved by the exercises; the patients gain in height and weight. The girth and breadth measurements, chest depth, strength tests, and lung capacity are generally increased, and the depth of the abdomen is usually decreased. In some cases, especially those of undersized patients, the increase in height is very rapid, and it is certainly more than the increase by ordinary growth. There were marked cases of flat foot which were benefited. The flat feet became shorter through the exercises by the increase in depth of the inner arches."

RECORD OF THE WORK PERFORMED BY A GIRL FOURTEEN YEARS OF AGE (TESCHNER).

Date, 1895.	Regular exercises. Bells.	Pushing two 10-lb. bells.	Swinging with each hand one 15-lb. bell, right to left	Swinging with both hands two 15-lb. bells.	Pushing two 20-lb. bells.	50-lb. bar above the head.	
						Standing.	Lying down.
April 6	3 lbs.						
" 9	"	100	10–10	5	....	Instructed.	Instructed.
" 11	"	150	25–25	15	10	2	5
		2 15-lb. bells	1 20-lb. bell				
" 13	"	50	25–25	25	12	5	10
" 16	"	54	30–30	35	18	7	12
" 18	"	60	35–35	40	20	7	15
			1 25-lb. bell	2 20-lb. bells			
" 20	"	70	20–20	20	30	10	15
" 25	"	90	22–22	25	33	15	16
" 27	"	100	35–35	30	50	17	20
" 30	"	110	50–50	35	60	20	22
May 2	"	120	60–60	36	70	20	25
			1 30-lb. bell		2 25 lb. bells	64-lb. bar	64-lb. bar
" 4	"	140	20–20	40	25	5	10
" 7	"	150	25–25	45	30	7	12
" 14	"	160	27–27	50	34	9	13
" 16	"	170	30–30	55	40	10	14

This system of exercises combines the forcible correction of deformity and the overcoming of restriction of normal motion by means of the "heavy work" with muscle building. It has the merit also of making an immediate mental impression upon the patient which no other system can make; for if the patient does not "strain every nerve" he must certainly exercise every muscle to preserve the equilibrium while supporting the heavy weights, and this mental impression is, undoubtedly, one of the important elements in successful treatment.

The system has the disadvantage, if disadvantage it may be called, of making class work impossible, for the patient must be under constant supervision, not only that he may be urged to the limit of his capacity, but that overstrain may be avoided as well.

It might appear from the description that the danger of overwork is great, but in a long series of cases, some of which were complicated by defects of the heart and lungs, no unfavorable symptoms have been observed by Teschner. The system is, however, one that can only be practised by a physician.

Another system of exercises, modified somewhat from the so-called Swedish system, more suitable for class work is that followed at the Hospital for Ruptured and Crippled. Dr. Truslow has been kind enough to outline for me some of the more important exercises, and to illustrate them with the photographs that are reproduced here.

The objects of the treatment are: (1) To overcome the patient's faulty habits of posture by the repeated purposeful assumption of proper postures; in other words, to counteract the deformity habit by training the mental and muscular perception of symmetry. (2) To stimulate and to strengthen the weakened muscles, particularly those muscular groups that are especially concerned in overcoming the deformities, and which, for the present purpose, may be considered as weak.

For convenience of description the exercises are divided into two classes: (1) self-correction; (2) muscle building.

Self-correction, Postures. The first exercises (*a* and *b*) in self-correction are for the purpose of overcoming the anteroposterior deformities that usually accompany lateral deviation of the spine.

(*a*) Head Bending Backward. In this exercise the chin is not tilted upward, but, the head being held level, the neck is drawn directly backward until the cervical and upper part of the

dorsal segments of the spine are completely extended. Thus, by increasing the distance between the points of attachment of the sternomastoids and the scaleni, strong traction is made upon these muscles with the effect of elevating the upper part of the thorax—an important feature in the exercise.

(*b*) Trunk Bending Forward and Trunk Raising. The patient stands in the erect posture with the spine extended and the chest expanded as in the previous exercise. The trunk is then bent forward (similar to Fig. 138), the only motion being at the hip-joints. The trunk is then raised again to the former position, care being taken to keep the hips farther back than the chest. In both flexion and extension the spine must be rigidly held in the corrected attitude, and there must be no motion at the knees. There is, of course, a movement corresponding to extension at the ankle-joints when the legs and buttocks are thrown backward to compensate for the forward bending of the body. The object of this exercise is to train the patient to keep the hips back and the chest forward.

The other exercises in self-correction are for the purpose of overcoming lateral deviation of the spine, the right dorsal, left lumbar curve being taken as the type (Fig. 133).

This series is arranged in a progression, and each one must be learned before the next in order is attempted.

(*c*) Left Neck Firm. The left hand is placed behind the neck, the left shoulder is raised, and the left elbow is held well back. This posture impresses upon the patient the necessity of approximating the left shoulder and the neck (Fig. 134).

(*d*) Body Inclination to the Left. This is a most important posture; it is intended to correct mechanically the faulty inclination to the right and to overcome the upper curve by traction on its concavity. The patient holding the arm in the first position is instructed to stretch well out with the left elbow, rotating upward and abducting the left scapula as much as possible. This puts upon the stretch the rhomboidei and the lower half of the trapezius of the left side, thus making strong traction upon their points of attachment in the dorsal concavity. At the same time the patient is directed to sway the pelvis to the right. This usually requires assistance at first, for it brings into action certain deep back muscles, over which one has ordinarily but little control. The shoulders must be kept level and the proper relation of the head and neck to the left shoulder must not be disturbed in this forced stretch to the left (Fig. 135).

(*e*) Chest Pressing with the Right Hand. The patient holding the left arm in the first position presses the right hand firmly against the dorsal convexity. This posture may be em-

Fig. 133.

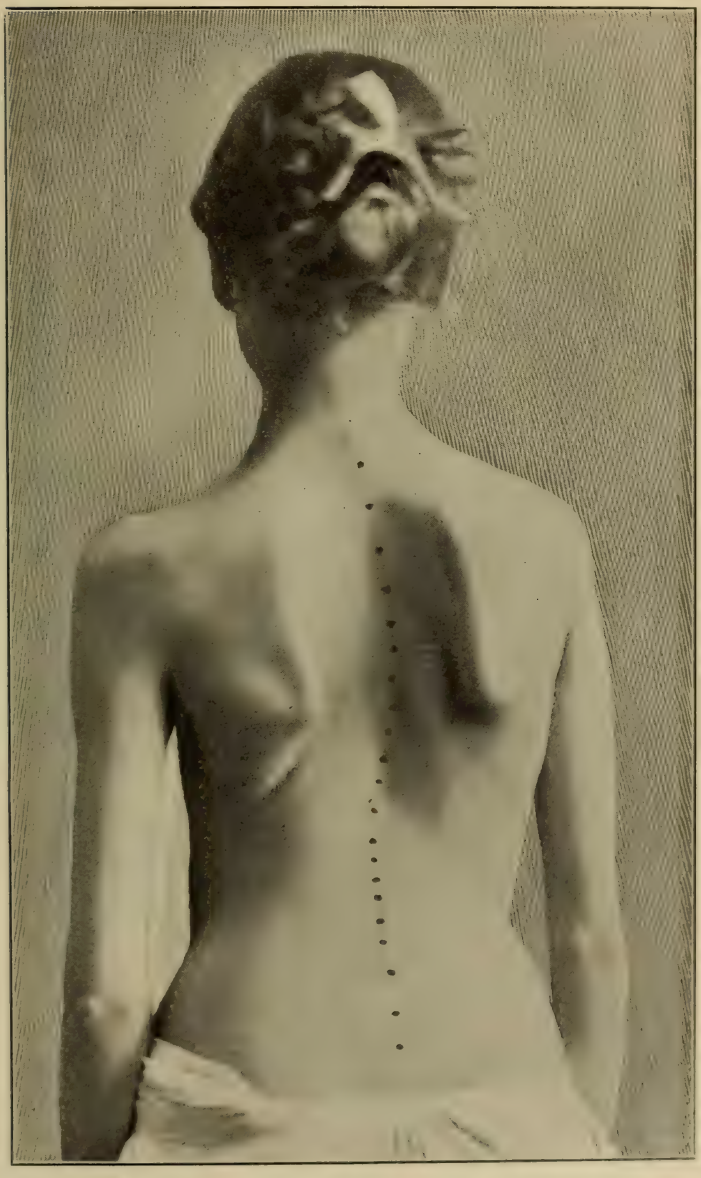

Typical lateral curvature. Right dorsal. Left lumbar.

ployed to advantage if there is a long right dorsal curve, when it is an efficient aid to the left-sided pull of the two former exercises.

(*f*) Right Neck Firm. The right hand is placed behind the neck, without, however, disturbing the improved position induced by the first exercises. With both hands placed behind the head,

Fig. 134.

Left neck firm.

the arms being in a symmetrical position, there is better mechanical fixation of the head, neck, and upper part of the trunk during the next exercise (Fig. 136).

(*g*) Left Hip Twisting Backward. In posture (*d*) the pelvis was swayed slightly to the right; it is now twisted slightly

backward on the left side to overcome the twist in the lumbar spine which usually throws this side of the pelvis somewhat forward. This correcting motion should be carried out in the lower dorsal and lumbar segments, and it should not affect the attitude of the remainder of the trunk.

FIG. 135.

Body inclination to the left.

(*h*) LEFT OBLIQUE STRIDE STANDING. The pelvic twist and right-sided sway being rigidly maintained, the left foot is placed about two foot-lengths forward and a little outward. Upon this leg the greater part of the weight of the body is now supported. This allows a slight downward tilt of the pelvis to the right, and lessens the left lumbar convexity (Fig. 137). The positions,

attained by the progressive exercises to this point, being maintained, the patient continues with

(*i*) Trunk Bending Forward. In this posture, motion takes place in the hip-joints only, as in the first exercise. This exercise further emphasizes the symmetrical position of the head and neck, the left-sided inclination of the upper half of the trunk, the right-sided inclination of the lower half, the twist and down-

Fig. 136.

Right neck firm.

ward tilt of the pelvis (Fig. 138). The return to the improved standing position should be made in this order: (1) trunk raising; (2) replacement of the left foot; (3) return of both arms to the sides. This is done slowly and carefully by the patient, who attempts to maintain the improved posture.

The postures constitute a progression which cannot be learned in less than seven treatments; often much more time is required.

As each part is learned it should be practised at home until the next treatment, when a new posture is added, if it appears that progress can be made.

Fig. 137.

Left oblique stride standing.

These successive postures are in reality exercises in that it requires constant muscular effort to retain them, but they are not exercises in the sense of repeated alternations of position. The series is simply an elaboration of what is called the keynote

FIG. 138.

Trunk bending forward.

posture. The raising of the left elbow, for example, makes it easier for the patient to overcome the distortion of the upper part of the spine; it also instructs him in the manner of holding the spine in the improved position after the arm is placed by the side.

The same is true of all the postures ; each one suggests and makes correction easier, and after sufficient practice the patient should be able to assume the corrected position without placing the arm or the leg in the preliminary attitude. Thus the successive postures are, as it were, letters, which, placed together one by one, make a complete word, or the best possible position that the patient can assume. At first the patient must use the letters and slowly spell out the corrected attitude, but after the muscles have been educated by the repeated assumption of each posture, and when the perception of symmetry has been acquired, the corrected attitude may be assumed at will. Finally, the improved posture will be instinctively retained, and will become habitual.

Muscle Building Exercises. In the treatment of lateral curvature one aims to strengthen :

1. The posterior cervical muscles.
2. The dorsal and lumbar muscles.
3. The muscles of vertebroscapular attachment.
4. The abdominal muscles.
5. The thigh and leg muscles.
6. The chest-expanding muscles.

The following exercises have been selected as best adapted for this purpose. Each one should be performed five or more times according to the strength of the patient.

(*a*) Opposite Standing, Head Bending Backward, Resisted. The patient stands before a wall or a shoulder-high horizontal bar, on which the hands are placed with the arms extended. The head is bent forward, and is then forced backward, the latter movement being resisted by the hand of the surgeon. This exercise is designed to strengthen the posterior cervical muscles.

(*b*) Opposite Bend Standing, Trunk Raising, Resisted. The patient stands with the upper part of the thighs in contact with a table or horizontal bar. The hands are placed behind the neck and the body is bent forward on the hip-joints as in the first exercise. The surgeon, standing behind, places his right hand over the posterior dorsal prominence and his left over the lumbar projection. The patient then raises the trunk to the erect position against the combined resistance (Fig. 139). With a little practice the surgeon learns to give an outward twisting motion to his hands while resisting, which tends to untwist the spinal rotations. When the dorsal rotation to the right is marked this untwisting may be facilitated by encircling the patient's chest with the left hand, while with the right strong forward and out-

ward pressure is made as the patient raises the body. This exercise is for the purpose of developing the muscles of the erector spinæ group.

Fig. 139.

"Opposite bend standing," trunk raising, resisted.

(*c*) Prone Lying, Head and Shoulder Raising "the Seal." The patient lies upon a table or upon the floor, and raises the head and chest—"looks at the ceiling." Progression is made in the increased leverage of arm-weight transference.

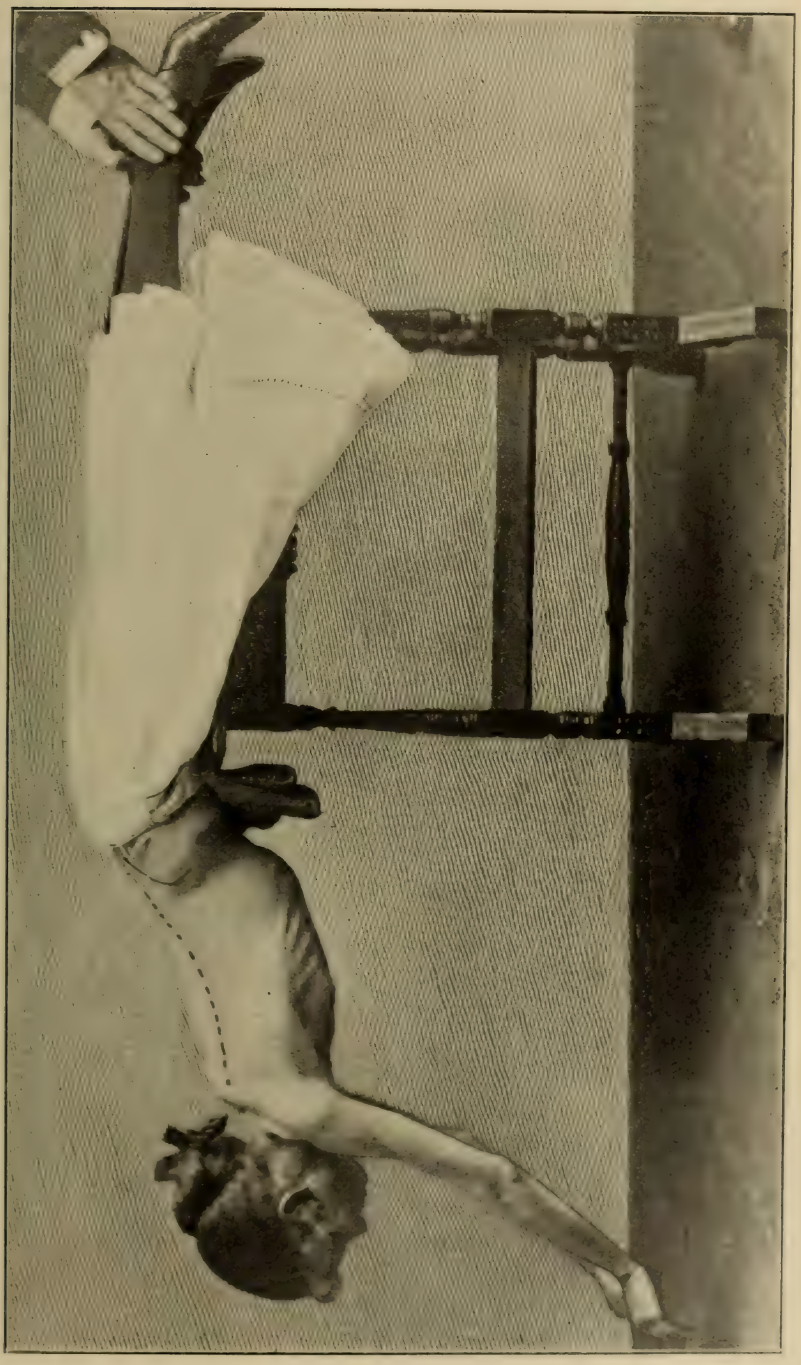

Fig. 140.

Prone lying, "diving."

1. With the hands on the backs of the thighs.

2. With the left hand behind the neck and the right hand on the back of the thigh.

3. With both hands behind the neck, and with the elbows well out and back.

4. "Swimming." The arm motions of swimming, in three counts. This exercise is to strengthen the muscles of the back from the head to the pelvis.

(*d*) Prone Lying, "Diving." The patient lies upon a table, the trunk and pelvis projecting beyond its edge, the limbs being fixed by a strap or by the weight of another person. The body is then bent downward and is raised again to the horizontal position (Fig. 140). In this exercise assistance will be required at first. Progression is made by transference of arm weights, as in the former exercise, thus:

1. With the hands on the hips.
2. With the arms stretched out at right angles to the body.
3. With the hands behind the neck.
4. With the arms extended in the line of the body.

This exercise is for the purpose of strengthening all the muscles of the back.

(*e*) Prone Lying, Leg Raising. The patient, lying in the prone posture upon the floor or table, lifts the limbs (overextends) alternately, the raised leg held perfectly straight. When the left thigh is extended, as much as the iliofemoral ligament will allow, the left side of the pelvis is tilted upward also, thus untwisting the lumbar spine. Progression in this exercise is made as follows:

1. Alternate leg raising, unresisted.
2. Alternate leg raising, resisted.
3. The leg motions of swimming, in three counts.

In this exercise the entire lower extremities must project beyond the supporting table. The exercises are for the purpose of strengthening the lumbar muscles and the extensors of the thigh.

(*f*) Opposite Sitting, Backward Bending of the Trunk. The patient is seated upon a bench, and the feet are fastened to the floor. The trunk being held in a position of complete extension, is bent slowly backward, motion being at the hip-joint only. Progression.

1. With the hands behind the hips.
2. With the left hand behind the neck, the right hand on the hip.
3. With both hands behind the neck.
4. With both arms extended upward.

At first the body is bent backward about forty-five degrees, later until the head touches the floor. This exercise is to strengthen the abdominal muscles.

(*g*) THE HORIZONTAL BAR. "PULL-UPS." The patient hangs by the hands and is assisted to "chin the bar." The body is then allowed to sink slowly back into the former position, the elbows are held well back, and the patient is instructed to bear as much of the weight as is possible with the left arm and shoulder. This exercise corrects the dorsal curve by means of muscular activity, and the lumbar curve by the weight of the suspended pelvis and limbs. The muscles used are those with vertebroscapula attachment.

(*h*) LEFT LEG STANDING, PELVIS TILTING. The patient stands upon the edge of a bench, supporting the weight on the left leg, the right leg being suspended beyond the side of the bench. While the head and trunk are kept in the corrected position, the pelvis is made to tilt sharply downward on the right, by lowering the right leg, while the left is kept perfectly stiff. This has the effect of straightening the lumbar curve.

(*i*) LEFT LEG "HOPPING." Both hands are placed behind the neck and the weight is supported entirely upon the ball of the left foot. In this attitude the patient hops ten or more times. This exercise, like the last, tends to straighten the spine and to strengthen the muscles of the left leg, which are often somewhat weakened from disuse.

(*j*) RESPIRATORY, HALF RECLINING, ARM EXTENSIONS AND FLEXIONS, RESISTED. The patient sits in a chair with an inclined back, or lies upon a low table with hard pillows under the mid-dorsal region, so that the upper dorsal and cervical segments of the spine must be overextended. The arms are stretched upward and backward, and the hands are grasped by the surgeon, who stands behind and resists the patient's downward pull. With the upward stretch of the arms and pull by the surgeon the patient inhales forcibly. With the downward pull against resistance, the patient exhales forcibly. This exercise is made in the rhythm of slow breathing.

When the patient has been thoroughly instructed in self-correction and in the exercises for muscle building, general gymnastics for systematic motor training may be given effectively to groups of fifteen or twenty pupils.

The exercises illustrated on pages 187–195 will serve this purpose satisfactorily.

These two systems of treatment by gymnastics have been selected as the most practicable of the many that have been devised. It may be stated that any treatment that makes the spine more flexible, that overcomes faulty attitudes, and that strengthens the muscles, must be of benefit to the patient, the degree of benefit corresponding to the persistence and energy of the pupil and the instructor rather than to any particular theory on which such treatment is based. The rotation of the vertebral bodies is increased by forward bending of the trunk, and, as this is the more important element of lateral curvature, it is evident that extension or overextension of the spine, combined with lateral twisting in such a manner as to reverse the habitual inclination, will most directly lessen or correct the distortion. If improvised exercises are conducted from this standpoint they will always be effective.

The Removal of Superincumbent Weight. The removal of superincumbent weight by the assumption of the reclining posture whenever the patient is fatigued is an important adjunct in the treatment of a certain class of cases. The patient should lie, preferably, upon a hard support in the supine posture, with the arms extended above the head. If the dorsal kyphosis is exaggerated, a firm cushion between the shoulders or under the projecting ribs will aid to expansion of the chest and favor the correction of the deformity.

Self-suspension. Self-suspension, by means of the halter and pulley, is of service in overcoming secondary contractions of the tissues, and thus it aids in the correction of deformity. It is often efficacious, also, in relieving the discomfort that is sometimes a troublesome symptom when the distortion is extreme. While the patient is suspended forcible manual correction of the deformity can be applied to advantage.

Suspension from the horizontal bar acts in a similar manner, although it is less effective than when the traction is made upon the entire spine. In this form of suspension the bar should be oblique in direction, the high side for the low shoulder. Thus, a passive "keynote" is induced while the patient is suspended. Exercises in this position, for example, flexion, extension, and abduction of the thighs, swaying the trunk from side to side, "chinning" the bar, and the like, are useful.

The Use of Braces or Other Supports. In the treatment of the ordinary type of lateral curvature, when there is an opportunity for proper gymnastic training, direct support is not usually

indicated. There are, however, cases even in this class in which the deformity habit is so persistent, and in which the voluntary efforts of the patient to assume a better attitude are so ineffective, that support may be employed for a time with advantage.

FIG. 141.

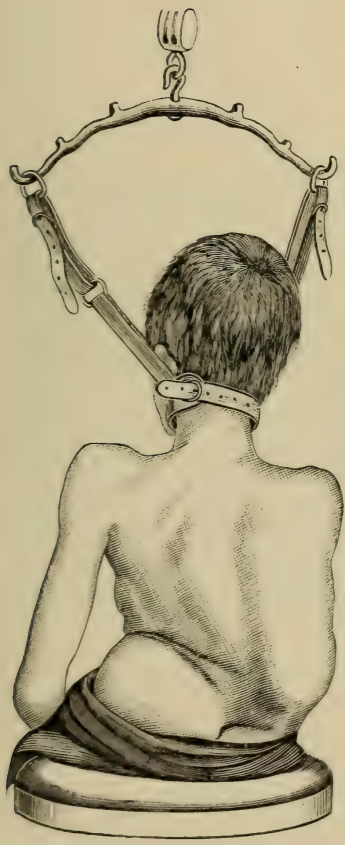

FIG. 142.

Self-suspension, illustrating the effect of traction in lessening deformity induced by paralysis. (Gibney.) In such cases support is essential.

The best support is a plaster corset applied with as much manual corrective force as is practicable while the patient is suspended in the upright posture if lateral deviation is most marked or if the

curvature is flexible; in the horizontal preferably if the rotation is the prominent feature of the deformity.

If correction is attempted in the horizontal attitude the patient may be suspended in the prone posture on a strip of cotton cloth (the hammock method). As this sinks under the weight of the trunk, it falls into the attitude of overextension, which is that most favorable for the untwisting of the rotated spine. When the deformity is marked, the body may be suspended in the lateral attitude by means of a sling of cotton cloth passed about the prominent ribs; thus the weight of the body acts as a correcting force during the application of the corset.

In using such corrective force one endeavors, if possible, to overcorrect the habitual deformity and the less marked changes in the anteroposterior contour as well. For example, if the lumbar region is flat one attempts to reproduce the normal lordosis, and if the body is habitually inclined in one direction one endeavors to sway it to the opposite side, and to efface the so-called high hip.

This attitude of overcorrection assured by the corset, combined with exercises, is especially efficacious from the curative standpoint in the treatment of single flexible curves. If the second or compensatory curvature has already appeared, one attempts to overcorrect the primary deformity and directs exercises for the purpose of straightening the second curve while the patient is wearing the corrective corset. For as the compensatory curvature is usually in the dorsal region, it may be considerably influenced by postures of the arms and shoulders. As often as possible during the day the patient should endeavor to improve upon the attitude which the corset enforces, by assuming the keynote position and by flexing and extending the trunk on the hips. For general exercises the corset may be removed, and, as a rule, it need not be worn at night, although in the treatment of young subjects its constant use for one or more weeks is of service in enforcing a proper attitude.

When the deformity is dependent upon irremediable injury or disease, such, for example, as anterior poliomyelitis or empyema, some form of brace must be employed constantly to prevent excessive lateral deviation of the trunk; and in cases of fixed deformity in older subjects, especially if the patient's occupation is fatiguing, a support may be indicated to relieve symptoms of discomfort or pain.

Support is employed primarily with the aim of preventing an increase of deformity and to relieve symptoms incidental to the

deformity. It may serve, also, in some degree as a corrective appliance. If it holds the spine in the extended position or induces lordosis, it may, by relieving the anterior portion of the column in part from the deforming influence of superincumbent weight, induce or permit a slight lessening of the rotation of the vertebral bodies. On this principle a light steel brace after the Taylor model may be as effective as any of the more complicated appliances, as was suggested many years ago by Judson. Corsets of other material than plaster, for example, of paper, or of aluminum, as suggested by Phelps, may be employed when the deformity is fixed and when no change in the position or size of

FIG. 143.



The Knight spinal brace, as used in lateral curvature. A leather or canvas band, made adjustable by lacings, is stretched from the posterior upright to the side bar on the side of the dorsal convexity.

the trunk is to be expected. The Knight brace, when carefully adjusted, appears to meet the requirements fairly well, and when less support is needed an ordinary corset strengthened by light steels may be sufficient.

Forcible Correction of Deformity. In the treatment by gymnastic exercises the patients are supposed to overcome by voluntary effort, as far as is possible, the secondary accommodative contractions of the soft parts that prevent the correction of the deformity, the heavy work of the Teschner system being particularly effective for this purpose. But in many instances the voluntary correction of deformity may be supplemented with advantage by the

employment of force. For example, the patient may use the weight of the body as a means of correction by forcibly flexing the trunk over a padded bar (Fig. 149) and a variety of similar postures, either active or passive, with or without suspension, may be utilized with the same object. Corrective force applied by the hands, the patient's trunk being flexed and rotated in the directions opposed to the deformities, although the most effective method, is the most fatiguing, and machines have been constructed with the aim of applying the force in a similar manner. This is illustrated by the appliance of Hoffa, which has been modified by Schede and others. In this machine the patient is suspended, the hips are fixed, and the pressure screws are applied upon the convexities of the double curve, with the aim of untwisting the spine. The correction is maintained for fifteen minutes or longer, and it is then followed by the regular exercises of the day (Fig. 144).

Fig. 144.

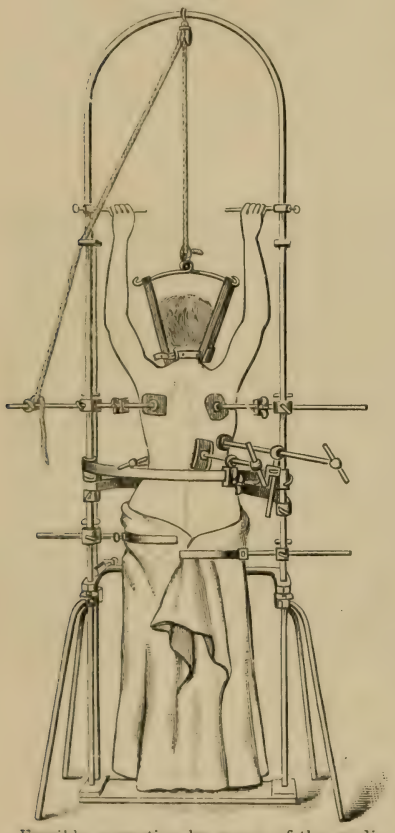

Forcible correction by means of the modified Hoffa appliance. (Bradford and Brackett.)

The Forcible Correction of Deformity Combined with Fixation. Forcible correction and fixation is the treatment of selection for resistant lateral curvature in early childhood, because one cannot command the cooperation of the patient in maintaining the proper attitude, and because the rapid growth at this age, which favors the increase of the deformity, is equally favorable to its cure if the static conditions can be changed.

For example, one treats the severe rhachitic kyphosis of infancy by fixation on the stretcher frame in the attitude of overextension, and by daily manual correction of the deformity. And in the treatment of older children, in whom posterior or lateral

deformity is fixed, one is justified in using the same method for its relief and cure that would be employed in the treatment of Pott's disease. In this class the plaster-of-Paris jacket, applied while the trunk is held in the best possible position, is the treatment of selection—a treatment that should be continued until the deformity is cured or until further rectification by this means is found to be impossible.

The most convenient method of applying the jacket is by means of the ordinary suspension apparatus. The back having been carefully padded at the points of pressure, the patient is suspended, and while traction and manual corrective force are

THE HIGH SHOE. The same object may be attained in the erect posture by the use of a higher heel, or heel and sole. The elevation may be from a half-inch to an inch and a quarter, the amount being regulated by its effect upon the contour of the trunk.

POSTURE AND SUPPORT DURING RECUMBENCY. The attitudes habitually assumed during recumbency should be investigated. The bed should be provided with a hard mattress and a low pillow, and the patient should be encouraged to lie habitually upon the side which opposes the deformity, or upon the back. The rectification induced by such an attitude may be still further increased by the use of a hard pillow beneath the convexity or beneath the back, and in certain instances the Barwell sling may be employed with advantage.

General Treatment. The importance of improving the general condition of the patient by regulation of the diet, by cold

exerted the plaster bandages are applied. In this correction two points are of especial importance: to attain as much extension or overcorrection as possible, and to sway the entire body in the direction opposite to the habitual inclination. By overextension one removes the weight in part from the vertebral bodies that are primarily deformed, and by lateral correction one endeavors to change the relation of the weight to the distorted part. This improved position must be carefully maintained by the hands until the plaster bandages have become firm. The jackets may be changed at intervals of about a month, and at each application one attempts to improve upon the former position.

Lovett[1] has urged the importance of correcting anteroposterior

[1] Transactions American Orthopedic Association, 1901, vol. xiv.

deformities by straightening the compensatory curves. For example, if a dorsal convexity is accompanied by a lumbar concavity the jacket should be applied while the lumbar segment is straight. This may be accomplished by supporting the trunk in the prone posture on a hammock, the legs hanging downward on either side, or in the sitting posture. The effect of flexion of the thighs in straightening the lumbar spine is illustrated in Fig. 145. Theoretically, if this attitude persists, it should induce a flattening of the abnormal kyphosis of which the lordosis is the effect, particularly if the improved position is favored by appropriate postures and exercises.

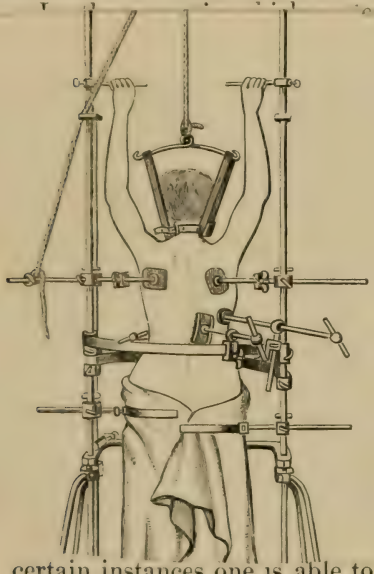

or applying the force in a similar manner. This is illustrated by the appliance of Hoffa, which has been modified by Schede and others. In this machine the patient is suspended, the hips are fixed, and the pressure screws are applied upon the convexities of the double curve, with the aim of untwisting the spine. The correction is maintained for fifteen minutes or longer, and it is then followed by the regular exercises of the day (Fig. 144).

The Forcible Correction of Deformity Combined with Fixation.

certain instances one is able to correct the deformity more effectually by horizontal than by vertical suspension in the manner already described.

When the deformity has been overcome, or when the continuation of the treatment seems undesirable, the jacket may be replaced by a corset, which may be removed for daily massage and for exercises. This may be finally discarded when the muscular strength has been regained.

As has been stated, forcible correction and fixation is essentially a treatment of deformity in early childhood. But in certain instances, when, for example, the deformity is extreme or is increasing rapidly, it may be employed in adolescence. In the treatment of this class of cases the plaster jacket is usually applied while the patient is fixed in the best possible position by

means of some form of pressure apparatus, as is illustrated in Fig. 144.

Forcible correction of deformity in this manner, under anæsthesia, with subsequent fixation of the trunk and of the head, if possible, in the overcorrected position, is advocated by Wullstein,[1] and it may be of service in certain cases.

The Volkmann Seat. In cases of primary lumbar curvature, or when the secondary curve of this region is pronounced, the attitude may be improved and the deformity may be corrected in part by seating the patient on an inclined plane, the high side beneath the low hip, thus lessening the convexity of the curve.

The High Shoe. The same object may be attained in the erect posture by the use of a higher heel, or heel and sole. The elevation may be from a half-inch to an inch and a quarter, the amount being regulated by its effect upon the contour of the trunk.

Posture and Support during Recumbency. The attitudes habitually assumed during recumbency should be investigated. The bed should be provided with a hard mattress and a low pillow, and the patient should be encouraged to lie habitually upon the side which opposes the deformity, or upon the back. The rectification induced by such an attitude may be still further increased by the use of a hard pillow beneath the convexity or beneath the back, and in certain instances the Barwell sling may be employed with advantage.

General Treatment. The importance of improving the general condition of the patient by regulation of the diet, by cold baths, and by active exercise in the open air is self-evident. The strain upon the back should be lessened by providing proper seats and by limiting the time passed in passive attitudes, and by lessening, as far as possible, the restraint of the clothing. These precautions are of almost equal importance with the active treatment.

The Duration of Treatment. The duration of treatment depends, of course, upon the character of the deformity and upon its causes. In the ordinary type of adolescent scoliosis the duration of active treatment is usually from three to six months. In this time the muscles may be so strengthened and the necessity for constant attention to the attitudes may be so impressed upon the patient that the simple exercises which may be performed at home may

[1] Zeit. f. Orthop. Chir., 1902, Bd. x. H. 2.

be sufficient. In such exercises the most important postures are those which hyperextend the spine. The constant effort should be to make motion in one direction as free as in another, and to practice postures that tend to reduce deformity. In all cases it is well, if possible, to keep the patient under supervision during the period of growth.

CHAPTER IV.

DEFORMITIES OF THE SPINE (CONTINUED). DEFORMITIES OF THE CHEST. THE FUNCTIONAL PATHOGENESIS OF DEFORMITY.

Variations in the Contour of the Spine.

ONE recognizes a certain contour of the spine as normal, but there are variations from this type which, within certain limits, can hardly be classed as abnormal. Two of these have been

FIG. 146.

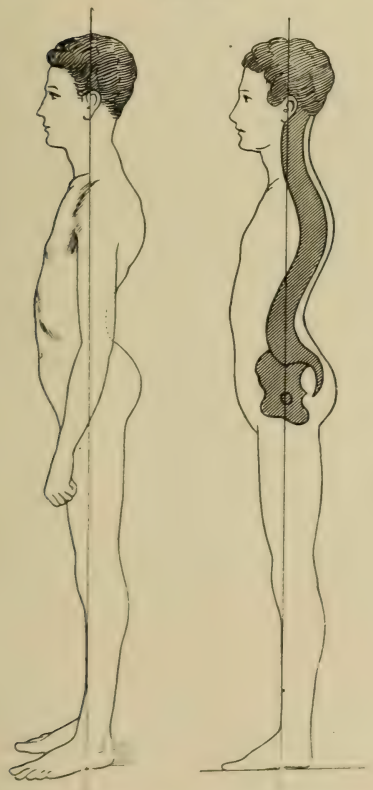

The hollow round back. (Hoffa.)

FIG. 147.

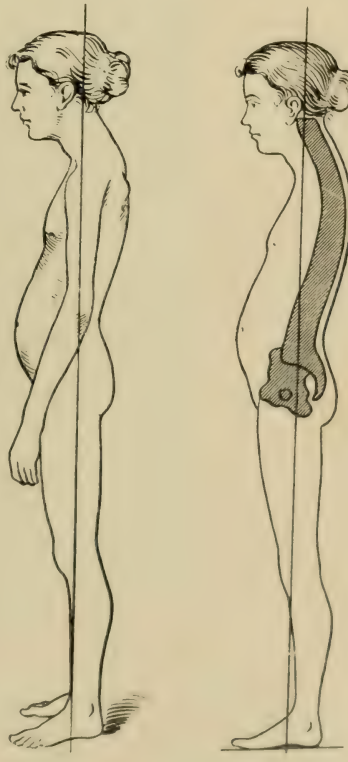

The round back. (Hoffa.)

mentioned: the *round back* (Fig. 147) in which there is a general forward droop most marked at the shoulders, and the *hollow*

round back (Fig. 146) in which the dorsal kyphosis and the lumbar lordosis are somewhat exaggerated. A third type is the *flat back* (Fig. 82) in which there is neither a lumbar lordosis nor a dorsal kyphosis. In the marked cases there is an actual prominence in the lumbar region, while the scapulæ project backward, overhanging the flattened dorsal spine. This type of back is the result, in many instances, of a rhachitic kyphosis which was most prominent in the lumbar region, and it often follows a primary lateral rotation of the lumbar vertebræ. The flat back and the round back predispose to lateral curvature. Deviations from the normal contour of the spine are attended by a change in the inclination of the pelvis and in the relation of the support of the limbs and trunk. The round back (Fig. 147) is almost always indicative of weakness, and it is often accompanied by other postural deformity, especially often by weak feet.

Anteroposterior Deformities of the Spine.

Kyphosis. As has been stated in the chapter on Pott's disease, the spine is practically straight at birth. If during the early weeks of life an infant be placed in the sitting posture the head falls forward and the spine bends into a long posterior curve, the posture of weakness. The normal anterior convexity of the cervical section is established when the gain in muscular power enables the infant to hold the head erect, and that of the lumbar region when the pelvis is tilted downward by the extension of the thighs in the erect posture.

In the erect posture the constant tendency of the weight of the head and of the thoracic and abdominal organs is to draw the spine forward and to re-establish the original posterior curve. This tendency is resisted by the action of the posterior muscles of the trunk. Whenever, therefore, the muscular power is lessened or the body is overburdened, or whenever the spine is weakened by disease, the tendency toward the original curve of weakness becomes apparent (Fig. 148). Thus, the causes of an abnormal increase in the posterior curvature of the spine are very numerous. It is, as has been stated, the characteristic attitude of weakness, as is illustrated in infancy and in old age. It is one of the common occupation deformities of adult life; it is a common postural deformity of childhood and adolescence. It may be induced by a variety of diseases that lessen the resistance of the spine or that interfere with its function. For example,

by rhachitis, spondylitis deformans, osteitis deformans, Pott's disease, and affections of a similar nature.

The kyphosis of rhachitis is most marked in the lower region, that of spondylitis deformans may involve the entire spine, while the simple postural curvature is most marked in the upper dorsal region—"round shoulders." In a number of the postural deformities the increase in the dorsal kyphosis is balanced by an increased lordosis, and in this form there is simply an exaggera-

FIG. 148.

Marked posterior curvature of the spine apparently induced by weakness incidental to illness.

tion of the normal curves of the spine—the "hollow round" back. In other instances there is a general forward droop of the trunk in which the lumbar lordosis may be lessened; this form is more common in childhood—the "round" back.

The forms of kyphosis that are the direct result of disease have been described elsewhere. *Postural kyphosis*—"round shoulders"—is one of the common deformities, and in childhood

its etiology is similar to that of lateral curvature, of which it may be a predisposing cause. Round shoulders and the accompanying flat chest may be induced also by obstructions in the respiratory passages, such as enlarged tonsils, adenoids, and the like, or by bronchitis or heart disease. Another predisposing cause is clothing that prevents the full expansion of the chest and the extension of the arms, and even the weight of clothing suspended from the shoulders may be a factor in the etiology.

FIG. 149. FIG. 150.

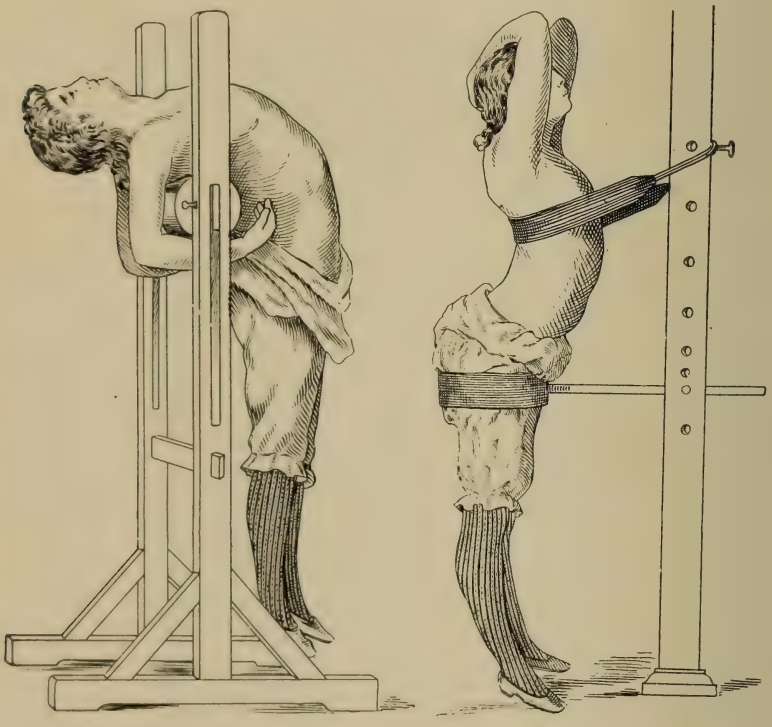

Exercises for the correction of posterior curvatures of the spine. (Hoffa.)

These and other possible contributing causes should be investigated in all cases of this type.

A marked type of deformity is sometimes seen in adolescents (Fig. 75), induced apparently by posture and by overwork, although in most instances it may be assumed that a slighter deformity of long standing serves as a predisposing cause. In this type the deformity is resistant, and there is, as a rule, pain or discomfort most marked in the lumbar region.

Treatment. The treatment is similar to that of lateral curvature. The assumption of the military attitude with the head erect, the chin depressed, the shoulders thrown back, the chest expanded, and the abdomen retracted, should be encouraged. And those exercises that expand the chest and that strengthen the muscles of the upper part of the spine are especially important. (Such exercies are illustrated by Figs. 97, 98, 105, 106, 111, 112, 121, 127, 129, 131, 149, and 150.) If the range of vertical extension of the arms is limited, this restriction must be overcome before the deformity of the spine can be permanently

FIG. 151.

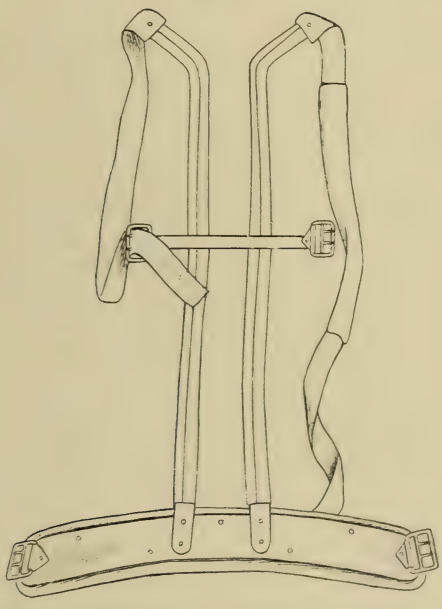

Tempered steel uprights for round shoulders. (Bradford and Lovett.)

improved. In well-marked cases the patient should be encouraged to read or study in the prone posture; in this attitude, in which the trunk must be supported upon the elbows and the head held backward, there is necessarily an involuntary correction of the deformity. In certain instances a light spinal brace or corset may be employed during the hours when the passive attitude must be assumed (Fig. 151). Shoulder braces, so-called, are useless, because the lumbar lordosis is increased when the shoulders are drawn backward. Clothing should not restrict the movements of the arms or trunk, and as little weight as possible should be suspended from the shoulders. In the more extreme cases, in which the

kyphosis is of long duration and rigid, forcible correction after the Calot method is indicated as a preliminary treatment. Fixed support, preferably the plaster corset, is employed until the patient has become accustomed to the new attitude. Afterward treatment by exercise and posture is continued as in the ordinary type. Whenever a patient is under treatment for deformity of the trunk the attempt should be made to restore the proper relation of the body and limbs, and thus to restore the general symmetry of the body.

Lordosis. Lordosis, or an abnormal hollowness of the back, is far less common than kyphosis. It is not a simple postural deformity, but it is usually secondary to disease or deformity either of the spine or of the adjoining members. For example, lordosis may be induced by flexion contraction of the thighs; it is a symptom of congenital displacement of the hips; it is sometimes a result of certain forms of nervous disease, in which, because of muscular weakness, the body is swayed backward to retain the balance, as in pseudohypertrophic paralysis. Lordosis in the lumbar region may be a compensation for a kyphosis in the upper segment. It is caused directly by spondylolisthesis. It may be a congenital deformity, and it is said to be a peculiarity of contortionists.

Treatment. As lordosis is usually a secondary deformity its treatment would be included in the treatment of its causes. In some instances the discomfort which is usually present when the deformity is well marked may be relieved by a proper corset sufficiently strong to support the back.

Congenital Elevation of the Scapula.

Synonym. Sprengel's deformity.

Sprengel's deformity is a congenital elevation of the scapula above the level of its fellow, an elevation accompanied in most instances by rotation, so that its lower angle is brought nearer to the spine. The cervical muscles passing to the scapula are shortened and changed in direction. Thus, its mobility is lessened and consequently the range of vertical extension of the arm is restricted. In many instances the deformity is accompanied by a lateral curvature of the spine, the convexity being usually toward the deformed side. In a case treated at the Hospital for Ruptured and Crippled the elevation of the scapula was accompanied by marked torticollis and asymmetry of the face, and in

2 cases reported by Wilson and Rugh[1] the posterior border of the scapula was attached by a bony process to the spine of the seventh cervical vertebra. In 4 cases—3 reported by Kölliker[2] and 1 by Hoffa—the projecting upper border of the scapula, reaching nearly to the clavicle, was mistaken for an exostosis.

The first adequate account of the deformity was that of Sprengel,[3] who described 4 cases in children from one to seven years of age. In 1898 Pitsch[4] described 17 other cases collected from the literature, and two years later Roger[5] reported 32. Of these, 30 were unilateral and 2 were bilateral.

Etiology. The etiology is doubtful, but the deformity appears to be the result of a constrained position of the fœtus *in utero*. In two of Sprengel's cases, seen soon after birth, the arm appeared to have been fixed behind the back of the child.

It is of interest to note that, according to Chievitz, the upper limb is in its origin a cervical appendage retaining an elevated position during fœtal life, and that interference with its descent by constraint or otherwise may explain the etiology.

Congenital elevation of the scapula may be simulated by the distortion and muscular atrophy resulting from birth palsy, or even by certain cases of rotary lateral curvature in which the scapula is elevated and prominent.

FIG. 152.

Congenital elevation of the left scapula. (Wilson and Rugh.)

Treatment. If the case is seen in childhood and if the contraction of the vertebroscapula muscles is extreme, the shortened tissues may be divided by open incision as in torticollis, and if the scapula is joined to the spine, the bony process should be removed. In older subjects no treatment other than that for the lateral curvature is, as a rule, indicated.

[1] Annals of Surgery, April, 1900.
[2] Centralbl. f. Chir., 1895.
[3] Archiv f. klin. Chir., 1891, Bd. xlii.
[4] Zeit. f. Orth. Chir., Bd. vi. H. 1.
[5] Ibid., 1902, Bd. ix.

The Absence of Vertebræ.

Absence of vertebræ is usually associated with rhachischisis. Several cases, however, have come under my observation in which there was absence of vertebræ without other malformation. In two of the cases the deficiency was in the cervical region, in the others in the lumbar. The noticeable shortness of the affected section of the spine was the only symptom.

Deformities of the Chest.

The Flat Chest. The so-called flat chest is an accompaniment of the round back (Fig. 147). In most instances the chest is not actually flattened in the sense that its anteroposterior diameter is diminished. It appears flatter because the shoulders and scapulæ are displaced forward.

Woods Hutchinson has called attention to the fact that the so-called flat chest is usually a round chest, in the sense that it is actually deeper than the normal, a persistence of the fœtal type. He suggests that such persistence may be one of the causes of so-called round shoulders, the round chest affording no adequate support for the scapulæ.

Hutchinson[1] has presented an index showing the relative depth of the chest at different ages, illustrating the progress from the keel chest of the lower orders to the bellows-shape of the adult human form. This index is found by dividing the anteroposterior diameter at the nipples by the transverse diameter at the same level; hence the lower the index, the longer and flatter, more bellows-like the chest.

Fœtal index	103
Infantile index	87
Child "	90
Adult "	72

Treatment. The treatment of the so-called flat chest is similar to that of the round shoulders with which it is often combined—that is, by exercises conducted with the special object of improving the strength of the muscles of the back and increasing the expansion of the upper part of the chest. The importance of correcting the deformity, which interferes with the proper expansion of the lungs and thus predisposes to disease, should be evident.

[1] Journal American Medical Association, September 11, 1897.

Pigeon Chest. Synonym. Pectus carinatum.

The pigeon, or keel-shaped, chest resembles the quadrupedal type in that the anteroposterior is increased at the expense of the lateral diameter. The sternum is thrust forward and downward like the keel of a boat, the lateral compression being most marked at the junction of the ribs and the cartilages. This deformity is almost always acquired (Fig. 153); it is usually an effect of

FIG. 153.

General rhachitic distortions and pigeon chest.

rhachitis, and it is described under that heading. It may be induced by obstruction of respiration caused by enlarged tonsils and the like, if this is present at an early age. It may be a secondary effect of the sinking forward and downward of the upper half of the trunk, as in Pott's disease of the middle of the spine.

Treatment. The treatment of secondary deformity would be included in the treatment of the affection of which it is the result.

Manipulation, massage, and breathing exercises may be employed in the treatment of simple pigeon chest. The tendency is toward spontaneous cure; it is rarely seen in adult life.

The Funnel Chest. Synonym. Pectus excavatum.

This deformity (Fig. 154) is the reverse of the pigeon chest. The sternum is depressed and the lateral diameter of the thorax is correspondingly increased. The milder types of the affection in which there are one or more depressions or hollows in the

FIG. 154.

Pectus excavatum. This patient has ocular torticollis also.

sternum are common. The extreme form, in which the entire sternum is depressed, is rare. It is practically always a congenital deformity, and it is not susceptible to direct treatment.

Minor Deformities of the Chest. As has been stated, distortions of the chest secondary to deformity of the spine are often discovered before the original cause is suspected. And the importance of the various minor irregularities of the chest or in the

direction of the ribs when once discovered is often exaggerated. They are usually the result of preceding rhachitis. The increase of the capacity of the chest by appropriate exercises aids in the correction of asymmetry.

Absence of Ribs. Absence or defective formation of ribs is uncommon. In such cases there is usually defective formation of the corresponding muscles, and lateral curvature of the spine is a common accompaniment.

Defective Formation of the Pectoral Muscles. Several instances in which one or both of the pectoral muscles were defective or absent have been observed at the Hospital for Ruptured and Crippled. The malformation in these cases caused no direct symptoms.[1]

Absence or Defect of the Clavicle. A number of cases of defective formation of the clavicle on one or both sides are recorded. In most instances a portion of the sternal extremity is present. The defect appears to cause but slight inconvenience.[2]

Acquired Luxation or Subluxation of the Clavicle.

Partial displacement of the sternal end of the clavicle is not particularly uncommon. In some instances it is caused by injury; in others no cause can be assigned. Most often there appears to be a laxity of the capsular ligament that allows a displacement during certain movements of the arm. The displacement is readily reduced, but the weakness and insecurity may cause discomfort and disability.

Treatment. In some instances the displacement may be prevented by the pressure of a pad and truss spring, attached behind to the corset or braces and passing over the shoulder close to the neck. Such an appliance is especially useful if the displacement occurs at certain times only, as in dressing the hair, playing on the violin, etc. Cures are reported as the result of the injection of alcohol into the joint from time to time, and Wolff[3] has operated with success as follows: The joint is opened by a straight incision. A fragment of bone is detached from the clavicle above and a similar one from the sternum; these, still adherent to the periosteum, are overlapped in front of the joint and the capsule is then sutured. As a rule, the affection is not of particular importance.

[1] Martirené. Revue d'Orthopédie, May, 1903.
[2] Schornstein and Carpenter. Lancet, January 7, 1899.
[3] Centralbl. f. Chir., November 30, 1893.

Asymmetrical Development.

In normal individuals there is often a slight difference between the two halves of the body, and, as is well known, inequality in the length of the legs is not at all uncommon. Inequality of the two halves of the body may be congenital, and it may be evident at birth, but usually it does not attract attention until adolescence. In many instances this inequality is a slight atrophy, the result of a cerebral hemiplegia of early childhood.

Fig. 155.

Hypertrophy of the right forearm and hand, due to congenital nævus.

In other instances the inequality may be due to congenital hypertrophy that may affect the entire limb. In such cases the enlargement may be due to an abnormal amount of normal tissue, but in most instances the hypertrophy, which becomes more marked with the growth of the child, is caused by an abnormal blood supply, a form of congenital nævus (Fig. 155).

TABLE OF WEIGHT, HEIGHT, AND CIRCUMFERENCE OF THE CHEST IN CHILDHOOD. (BOAS.)

		Pounds.	Kilos.	Height.		Chest.	
				Inches.	Cm.	Inches.	Cm.
Birth	Male	7.55	3.43	20.6	52.5	13.4	34.2
	Female	7.16	3.26	20.5	52.2	13.0	33.2
6 months	Male	16.0	7.26	25.4	64.8	16.5	42.0
	Female	15.5	7.03	25.0	64.6	16.1	41.0
1 year	Male	20.5	9.29	29.0	73.8	18.0	45.9
	Female	19.8	8.84	28.7	73.2	17.4	44.4
18 months	Male	22.8	10.35	30.0	76.3	18.5	47.1
	Female	22.0	9.98	29.7	75.6	18.0	45.9
2 years	Male	26.5	12.02	32.5	82.8	19.0	48.4
	Female	25.5	11.56	32.5	82.8	18.5	47.0
3 "	Male	31.2	14.14	35.0	89.1	20.1	51.1
	Female	30.0	13.60	35.0	89.1	19.8	50.5
4 "	Male	35.0	15.87	38.0	96.7	20.7	52.8
	Female	34.0	15.41	38.0	96.7	20.5	52.2
5 "	Male	41.2	18.71	41.7	106.8	21.5	54.8
	Female	39.8	18.06	41.4	105.3	21.0	53.5
6 "	Male	45.1	20.48	44.1	112.0	23.2	59.1
	Female	43.8	19.87	43.6	110.9	22.8	58.3
7 "	Male	49.5	22.44	46.2	117.4	23.7	60.6
	Female	48.0	21.78	45.9	116.7	23.3	59.5
8 "	Male	54.5	24.70	48.2	122.3	24.4	62.2
	Female	52.9	24.01	48.0	122.1	23.8	60.8
9 "	Male	60.0	26.58	50.1	127.2	25.1	63.9
	Female	57.5	26.10	49.6	126.0	24.5	62.5
10 "	Male	66.6	30.22	52.2	132.6	25.8	65.6
	Female	64.1	29.07	51.8	131.5	24.7	63.0
11 "	Male	72.4	32.83	54.0	137.2	26.4	67.2
	Female	70.3	31.87	53.8	136.6	25.8	65.8
12 "	Male	79.8	36.21	55.8	141.7	27.0	68.8
	Female	81.4	36.90	57.1	145.2	26.8	68.3
13 "	Male	88.3	40.04	58.2	147.7	27.7	70.6
	Female	91.2	41.36	58.7	149.2	28.0	71.3
14 "	Male	99.3	45.03	61.0	155.1	28.8	73.3
	Female	100.3	45.50	60.3	153.2	29.2	74.1
15 "	Male	110.08	50.26	63.0	159.9	30.0	76.6
	Female	108.04	49.17	61.4	155.9	30.3	79 8

The Functional Pathogenesis of Deformity.

Wolff's Law. "Every change in the form and function of the bones or of their function alone is followed by certain definite changes in their internal architecture, and equally definite secondary alterations of their external conformation, in accordance with mathematical laws."

Mention has been made, and will be made again from time to time, of the adaptation of members or parts to abnormal conditions, and of the transformation of deformed parts to the normal when the improper relations of weight and strain have been removed. This theory or law of functional adaptation has been established by Professor Julius Wolff, of Berlin, who has shown its application to the bones, the most unyielding structures of the body. He first called attention to the fact that the shape of a bone is the effect of function. It is the effect of function in that if the work required of it had been different its shape would have

been different. This function has shaped not only the external contour but the internal structure as well. If a bone is broken, for example, the neck of the femur, and deformity results, the internal architecture is no longer suitable for the new conditions of weight and strain, and immediately a rearrangement begins, which finally transforms the internal structure, not only in the neighborhood of the injury, but in the extremity of the bone also, to adapt the deformed part as well as may be to the work that is now demanded of it.

FIG. 156.

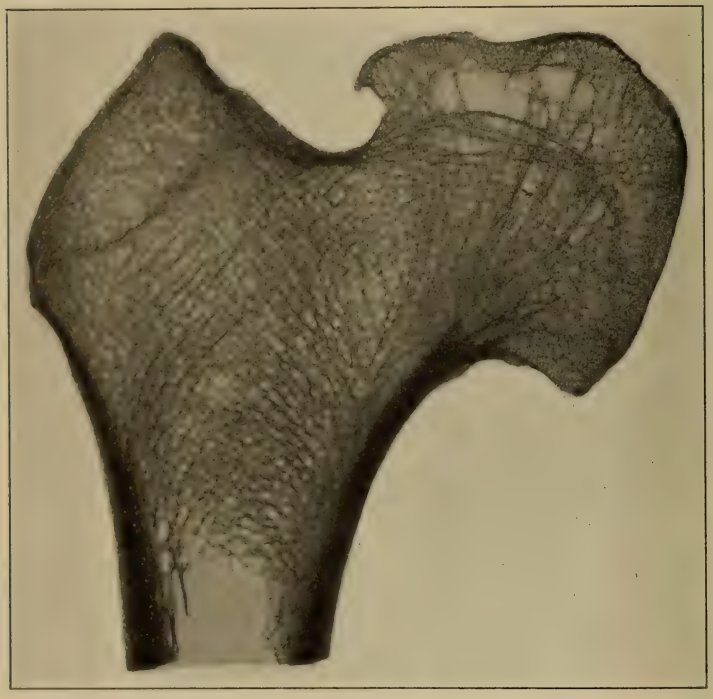

Dislocated femur, showing the atrophy and re-arrangement of the internal structure as compared with the normal (Fig. 157). (Freiberg.)

The normal bone is braced most thoroughly, and is most resistant at the points where most work is required of it. If the weight and strain are for any reason transferred to another part, its structure becomes hypertrophied there, and correspondingly weakened at the point from which the strain has been removed. With this change in the internal structure a change in the external contour keeps pace. For, according to this theory, "the external contour represents mathematically simply the last curve uniting

the ends of the various trajectories which make up the internal structure."

For the further exposition of this theory I quote from Freiberg's[1] review and abstract of Wolff 's[2] final article.

"In showing that improper static demands made upon an extremity resulted in the formation of new masses of bone upon the surface of the bone of this extremity, or that they produced

FIG. 157.

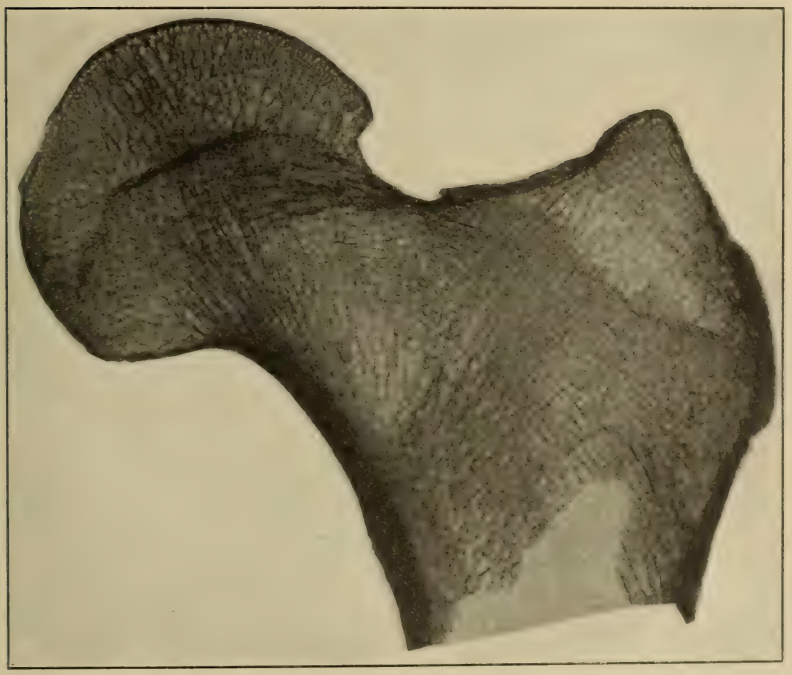

Normal femur from same subject. (Freiberg.)

the disappearance (atrophy) of bone masses according to the nature and degree of these disturbances in static requirements, it has at once been shown in what manner deformities have their origin. For these transformations on the surface of bones are nothing other than 'deformities' in the wider or narrower sense of the term.

"Taking genu valgum or habitual scoliosis as example, the

[1] Annals of Surgery, July, 1897; and American Journal of the Medical Sciences, December, 1902.

[2] Die Lehre von der functionellen Pathogenese der Deformitaten, Archiv für klinische Chirurgie, Bd. liii. H. 4.

development of a deformity in the narrow sense is thus explained. In the beginning of either of these conditions the shape of the bones is perfectly normal. As the result of excessive fatigue in their too weak muscles the patients are frequently assuming a faulty position of limb or body; they seek to control excessive excursions of their joints by the interference of the articular structures themselves instead of by muscular activity. The result is a continual alteration in the static requirements made upon the bones and the internal architecture; internal and external configuration of the bones accommodate themselves to the new conditions. Since, according to this reasoning, deformities are nothing less than the result of these transformations which the external form of bones or joints undergo in accom-

FIG. 158.

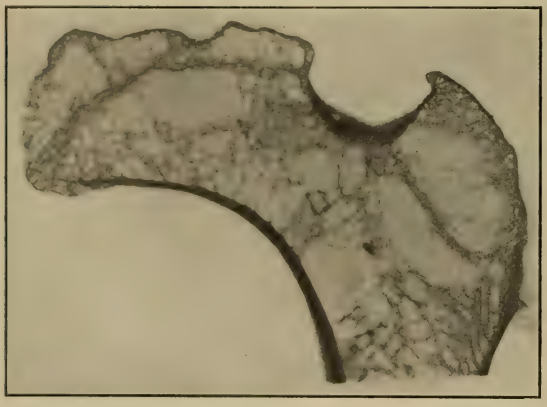

Section of femoral head of a paralytic idiot, aged thirty-five years, showing the extreme atrophy caused by disuse. (R. T. Taylor.)

modating itself to faulty demands made upon them, it must be self-evident that these deformities are to be considered pathological only in the sense that hypertrophy of the cardiac muscle in valvular insufficiency is pathological. That which is really pathological is only the altered static requirements, the abnormal mechanical function. Far from being pathological the deformity is the only suitable or even possible form by means of which bone or joint can withstand the altered forces bearing upon it; it is nature's way of securing the greatest possible service and strength, under the new conditions, with the use of the least possible amount of material.

"The pathogenesis of deformities is, therefore, functional.

Genu valgum, for instance, represents only the functional accommodation of femur, tibia, and knee-joint to the improper static demands made by the outward deviation of the leg. Just so are the shapes of the bones in club-foot the expressions of similar functional accommodation to an inward rotation of the foot, or even, sometimes, an inward turning of the whole lower extremity. The faulty position of an extremity under these circumstances is to be regarded rather as a cause of the deformity than as an effect. This faulty position must always occupy a place intermediate between the remote causes of deformity (hereditary predisposition, habit, muscular weakness, external conditions causing pressure or narrowing space of growth), and the anatomical results which these various remote causes bring about.

"When the altered demands upon an extremity do not occur spontaneously, as in the above instances, but, on the other hand, result from a primary disturbance in the shape of the bones, due to trauma or bone disease with consequent softening or destruction of tissue, there is added to this a secondary change in the external configuration of the bones, and there is thus caused a 'deformity in the broad sense of the word.' The difference between the two varieties of deformity, therefore, lies only in the addition of a second etiological factor (the trauma, etc.) to the deformity in the broad sense. Both varieties have it in common that the shape of the bones and joints of the deformed part represents nothing else than the expression of a functional accommodation to the faulty static demands made upon it.

"As a second example by means of which to explain the correctness of the doctrine of functional pathogenesis the author has selected scoliosis. In the first chapter the author showed in detail that the altered conditions in the length and height of the transverse processes of scoliotic vertebræ as well as corresponding conditions in the ribs of the scoliotic thorax are so evident as not possibly to escape notice, and that they can be explained in no other way than as functional accommodation to the circumstances of space, changed and brought about by the continual, faulty, and cramped position of the thorax; this is as true of the convex as of the concave side of the vertebral column, to which the transverse processes and ribs in question belong. It must be manifest that changed relations of one part of the skeleton to any other part of the skeleton (as far as space conditions are concerned) necessarily bring about changes in the mechanical demands made upon this part, and, therefore, changes in the directions and values

of the pressure, tension, and shearing strains of each and every point in this part of the skeleton. The conclusion thus drawn, that accommodation to space means the same as accommodation to function, is of greatest importance to the *general* doctrine of functional accommodation.

"The origin of the wedge-shape of the scoliotic vertebra now comes under discussion. It is assumed by the majority of writers that an abnormal softness of the bones is present in scoliosis by means of which a faulty position can model the bodies of the vertebræ as it does in the case of rhachitic disease of the bone, or as is really the case with the intervertebral disks in cases of 'habitual scoliosis.' While unsupported by any pathologico-anatomical investigations, it is allowed possible, or even probable, that such softness of the bones plays a rôle in many cases of scoliosis. It is certain, however, that this is by no means always the case; as evidenced by the development of scoliosis after empyema in adults, and the great exaggeration in adult life of very slight scolioses originating during youth. It is concluded, on the contrary, that the vertebra may acquire its scoliotic wedge-shape entirely independent of the pressure of the superincumbent weight. Furthermore, in the absence of any abnormal softness of the bones, the body of a vertebra may lose height on the concave side and gain the same on the convex side through the 'tropic stimulus of function' purely; being simply an accommodation to the diminished space on the concave side and increased room at the convexity and the change of mechanical conditions consequent thereupon.

"This simple and natural conception of the circumstances concerning the scoliotic wedge must obtain credence, especially since the old view, corresponding to the 'pressure theory,' has been long ago disproved by Hoffa and Nicoladoni—namely, that the concave side of the wedge is the seat of atrophy, and that this atrophy accounts for the loss in height of the vertebral body on this side."

The importance of Wolff's theory, which shows how deformity may be acquired and how it may be avoided, is very evident. It is of equal importance in indicating the principles of treatment. For example, from the anatomical description of a club foot the distortion might appear to be irremediable, but on this theory one feels assured that if the foot can be fixed for a sufficient time in the overcorrected position, the influence of the new static conditions will immediately induce a transformation, not only in soft

parts, but in the bones as well, that will finally effect a complete and absolute cure. So, also, the correction of a distorted bone by operative means is at best but imperfect; if, however, the static conditions have been changed, nature will in time reconstruct the entire bone so perfectly that in a few years practically no trace of the former distortion, either in contour or internal structure, will be evident. Scoliosis might be cured as perfectly as the club foot or the bow-leg, were it possible to restore as easily the normal conditions of weight and strain.

Atrophy of Bone.

The writings of Wolff have called especial attention to the fact that bone is a living tissue very readily affected by changing conditions, and that atrophy or hypertrophy of bone may be local or general, according to the change in functional use of the affected part.

Since the Roentgen ray has come into general use particular attention has been called to the atrophy of the internal structure of bone that follows lessened use or disuse, or from what is called trophic disturbance of nutrition from any cause. For example, after fracture or joint disease, or nervous affections, or even slight injuries of the nature of sprains, eccentric atrophy is apparent—that is, weakening of the lamellæ of the spongy portion and decrease in thickness of the compact substance of the bone.

This atrophy is not only rapid, but it may be widespread, as proved by the investigations of Sudeck,[1] who could distinguish atrophy of the bones of the foot within six weeks after fracture of the leg. Atrophy of bone is especially rapid as a result of acute affections of the joints, corresponding in this to the atrophy of the muscles under similar conditions. In the X-ray negative such atrophy is indicated by a loss of clearness of outline which is replaced by a peculiar blur, resembling closely the infiltration due to disease.

Weigel has called attention to cases in which general trophic disturbance of an entire extremity was induced by injury of a joint. This disturbance was indicated by congestion, coldness and persistent weakness of the extremity, and it was always accompanied by marked and general atrophy of the bones. Such atrophy

[1] Fortsc. auf dem Gebiete. der Röntgenstrahlen. Bd. iii. H. 6.

may explain the delay in recovery after apparently slight injury or disease of a joint or other tissue. The treatment should be stimulative, and functional use of the weak part should be encouraged as soon as possible.

After long-continued disuse the bones may be extremely fragile. This fact must be borne in mind when one attempts to correct deformity caused by paralysis, by rheumatoid arthritis, and the like.

CHAPTER V.

TUBERCULOUS DISEASE OF THE BONES AND JOINTS.

Etiology. Three factors are recognized in the etiology of tuberculous disease: the infectious element (the tubercle bacillus), the general predisposition of the patient, and the local condition that favors the reception and the growth of the bacilli.

Predisposition. The predisposition, both general and local, is spoken of as lessened vital resistance. A general predisposition to disease may be inherited or it may be acquired. Thus, a history of tuberculosis in the immediate family of the patient is supposed to imply a lessened resistance to this form of disease. In a certain proportion, perhaps 25 per cent. of the cases, this inherited predisposition is very direct and positive, but in the larger number the family history is as indefinite as in a similar class of patients under treatment for any other form of ailment. The acquired predisposition is of more direct importance since it would include the lowering of the vitality due to improper food and improper hygienic surroundings of every variety, together with the greater liability to depressing diseases and the more constant exposure to tuberculous infection that such conditions imply. Thus, tuberculous disease of the bones, as well as of other parts, is more common among the poor of cities than among the more favored classes.

Mode of Infection. The tubercle bacilli may be introduced to the body by inhalation and find their way to the bronchial glands, or by the mouth and set up disease in the mesenteric glands, or, after infection of the nasal passages or neighboring parts, secondary disease of the cervical lymphatics may cause the so-called scrofulous glands of the neck.

Latent Tuberculosis. It may be assumed that disease of the bronchial and mesenteric glands is not uncommon in individuals of apparently perfect health, since it is often discovered at autopsies in those who have died from other causes. This form of glandular disease is called latent tuberculosis, and it usually precedes a local outbreak in the bone or elsewhere. In many instances the disease may remain latent and finally disappear, or it may persist, and from time to time free bacilli or bits of in-

fected tissue may escape into the blood current; by it they are deposited in other parts, where, under favoring conditions, local disease may be set up. Depression of the vitality from any cause may be supposed to favor the progress of the glandular disease, which may lead to a dissemination of the infectious elements, and at the same time it may lessen the resistance of other tissues that may be exposed to the infection. This accounts for the well-known influence of certain diseases, such as measles and whooping-cough, not only in predisposing to local tuberculous disease, but in favoring its progress when it is already established. It is possible, also, that the bacilli that have found their way into the blood current more directly, as, for example, through wound infection, may set up primary disease of a bone or joint. In fact, it is stated by Koenig[1] that in fourteen of sixty-seven autopsies on subjects who had suffered from tuberculous disease of the bones and joints, no other foci were found in the body. In other instances the source of infection may be pre-existent disease of the lungs or of other internal organs.

In 769 autopsies on children under twelve years of age, at the Hospital for Children, Great Ormond Street, London, reported by G. F. Still,[2] 269 presented tuberculous lesions. Of these, 117 were less than two years of age.

The apparent channels of infection, as evidenced by the appearance of the glandular lesions, were as follows:

Respiratory:		
Lungs	105	
Probably lungs	33	
Ear	9	
Probably ear	6	
	153	= 57 per cent.
Alimentary:		
Intestines	53	
Probably intestines	10	
	63	= 23.4 per cent.
Other cases:		
Bones or joints	5	
Fauces	2	
Uncertain	46	
	53	

Northrup and Bovaird[3] have made similar observations at the New York Foundling Hospital:

Infection by respiratory tract	148
Infection by mesenteric lymph nodes	3
Indeterminate	48
	200

[1] Deutsche Chir., 1900, L. 28a, S. 157. [2] British Medical Journal, August 19, 1899.
[3] Northrup. New York Medical Journal, February 21, 1891. Bovaird, ibid., July 1, 1899.

In sixteen instances the process was confined to the bronchial glands, and in no instance were these glands found to be free from disease.

Bovaird[1] has collected the reported autopsies on tuberculous children with reference to primary intestinal infection, and has called attention to the fact that the English observations are not in accord with others:

	Autopsies.	*Primary intestinal disease.*	
German	236	9 = 4	per cent.
French	128	0	
English	748	136 = 18	"
American	369	5 = 1	"
	1481	150	

Haushalter,[2] in 78 autopsies upon children dying from acute miliary tuberculosis, found in all but 4 disease of the tracheo-bronchial glands. In 44 this disease was the most ancient focus in the body.

Local Predisposition. The local conditions that favor the growth of the tubercle bacilli may be induced by injury. Slight injury sufficient to cause, for example, a hemorrhage into the substance of the cancellous tissue induces a local congestion during the process of repair that provides the proper soil for the growth of the bacilli when they are deposited in its neighborhood. This has been proved experimentally by Krause, and it is supported by clinical evidence. The great preponderance of disease in the lower over that of the upper extremities in childhood is supposed to be another argument in favor of the influence of injury in the causation of disease.

In 513 of 3398 cases of tuberculosis of the bones and joints reported by Hildebrand,[3] Koenig, Mikulicz, and Bruns injury seemed to be a direct predisposing cause of the local disease (16.5 per cent.). A much higher percentage than this has been assigned by certain writers, but the exact relation of traumatism to disease can only be conjectured.

The primary disease is almost always in the newly-formed bone about an epiphyseal cartilage. This tissue is vulnerable; it is, therefore, more exposed to direct injury; it is subjected, also, to the strain of motion at the neighboring joint, and as the circulation is here more active the bacilli are more often deposited in this situation.

[1] Archives of Pediatrics, December, 1901.
[2] Archiv. de Méd. des Enfants, March, 1902.
[3] Deutsche Chir., 1902, L. 13, S. 168.

The vulnerability of growing bone accounts also for the relative frequency of bone disease in childhood, as compared with adult life. Injury not only causes a local predisposition to disease, but it favors its progress when it is once established.

Distribution of the Disease. In 13,308 cases of tuberculous disease of the bones and joints treated at the Hospital for Ruptured and Crippled the distribution was, in order of frequency, as follows:

Vertebræ	5,662	=	42.5 per cent.
Hip-joint	4,048	=	30.5 "
Other joints	3,598	=	27.0 "
	13,308		

In a total of 3561 cases treated at the Hospital for Ruptured and Crippled and at the Vanderbilt Clinic during a period of five years, the distribution was as follows:

Vertebræ	1432	=	40.2 per cent.
Hip-joint	1123	=	31.5 "
Knee-joint	699	=	19.6 "
Ankle-joint	196	=	5.5 "
Elbow-joint	62		
Shoulder-joint	42	=	3.1 "
Wrist-joint	7		
	3561		
Trunk	1432	=	40.2 per cent.
Lower extremities	2018	=	56.6 "
Upper "	111	=	3.1 "

The correspondence between these two tables of statistics is striking, and the number of cases is so large that the proportions may be accepted as approximately correct as applied to the distribution of the disease in childhood.

At the Boston Children's Hospital in a period of twenty-five years, 1869–1893, 3820 cases were treated.[1] The distribution was as follows:

Vertebræ	1964	=	51.4 per cent.
Hip	1402	=	36.7 "
Ankle	300	=	7.8 "
Knee	104	=	2.7 "
Wrist	20		
Shoulder	15	=	1.3 "
Elbow	15		
	3820		
Trunk	1964	=	51.4 per cent.
Lower extremities	1806	=	47.2 "
Upper "	50	=	1.3 "

Side Affected. Disease of the joints is slightly more common on the right than on the left side of the body. At the Hospital

[1] Report of the Boston Children's Hospital.

for Ruptured and Crippled the proportions in the cases treated during a recent period of ten years are as follows:

Hip, right	53 per cent.
Knee, right	55 "
Ankle, right	50 "
Shoulder, right	64 "
Elbow, right	60 "

It has been stated that one of the explanations of the great preponderance of the disease of the lower over the upper extremity is the greater liability to injury. The same explanation has been advanced to account for the greater frequency of disease on the right side, which is more marked in the upper than in the lower extremity, because the right arm is more liable to overwork as well as to injury.

Sex. Tuberculous disease of the joints is somewhat more common among males than females.

Of 3822 cases of Pott's disease treated at the Hospital for Ruptured and Crippled, 2037, or 53 per cent., were in males.

Of 3307 cases of disease of the hip-joint treated at the same institution, 1731, or 52.3 per cent., were in males.

Of 1218 cases of disease of the knee-joint, combined statistics of Koenig and Gibney, 703, or 57.6 per cent., were in males.

Age. In 5461 cases of tuberculous disease treated at the Hospital for Ruptured and Crippled, about seven-eighths of the patients were less than fourteen years of age.

Less than 14 years of age	vertebræ,	87.7 per cent.
	hip,	88.2 "
	other joints,	71.7 "
Between 14 and 21 years of age	vertebræ,	7.7 per cent.
	hip,	9.2 "
	other joints,	10.7 "
More than 21 years of age	vertebræ,	4.5 per cent.
	hip,	2.5 "
	other joints,	17.5[1] "

Of 1259 cases of Pott's disease treated recently at the same institution, 1075, or 85 per cent. of the patients, were in the first decade; 50 per cent. were three to five years of age, inclusive, at the inception of the disease.

In 1000 cases of disease of the hip-joint the ages of the patients correspond closely to these; 87.2 per cent. were in the first decade, and 45.2 per cent. were from three to five years of age, inclusive.

In 1000 cases of disease of the knee-joint, 75 per cent. were in

[1] Knight. Orthopedia.

the first decade and 40 per cent. were from three to five years, inclusive.

In 339 cases of the ankle-joint, 70 per cent. were in the first decade and but 35 per cent. were included within the three years.

The distribution of the disease and its relative frequency at the different ages is shown by Alfer's table of statistics from Trendelenburg's clinic at Bonn.[1]

	0–5	5–10	10–15	15–20	20–25	25–30	30–35	35–40	40–45	45–50	50–55	55–60	60–65	65–70	Total
Vertebræ	89	59	32	23	9	10	3	6	3	1	4	0	0	0	239
Hip	58	59	43	46	9	11	6	0	4	1	1	3	0	0	241
Knee	47	52	47	37	20	11	23	11	11	3	2	8	6	3	281
Ankle	5	9	10	5	2	1	1	3	2	0	3	0	2	0	43
Shoulder	0	2	2	6	3	5	3	1	1	2	2	1	0	0	28
Elbow	7	14	14	21	12	9	6	5	9	8	5	2	2	0	114
Wrist	1	0	0	1	5	0	0	3	1	3	2	1	3	0	20
Total	207	195	148	139	60	47	42	29	31	18	19	15	13	3	966

This table illustrates the well-known fact that disease of the upper extremity, relatively infrequent at all ages, is proportionately far more common in adult life than is disease of the lower extremity. Of the joints of the lower extremity, the knee and the ankle are proportionately more often diseased in later life than is the hip.

Pathology. When the bacilli are deposited in a part, the irritation of their toxins causes a proliferation of the fixed cells which lie in direct contact with the germs, and about these a ring of leucocytes forms. The bacilli, the epithelioid cells including often one or more giant cells, together with the surrounding leucocytes, constitute the visible tubercle of bone, a minute grayish speck in the cancellous structure. The central cells about the bacilli, increasing in number, deprived of nourishment and poisoned by the toxins, die and are disintegrated to granular material, "caseate," and the tubercle changes to a yellow color; but the bacilli, multiplying and escaping, form new tubercles about the original focus, which coalesce as the area of the disease enlarges. Meanwhile the surrounding tissue becomes congested, as the result of the irritation, and the fixed cells become organized, or partly organized, into a feeble, ill-nourished form of granulation tissue, representing the effort of the part to shut out and to expel the foreign substances formed by the disease. Or, if this local resistance is effective, the cells become actually organized into firm granulations which surround and destroy the germs, and

[1] Beit. zur klin. Chir., 1891, Bd. viii. H. 2.

then are further transformed into scar tissue. But in most instances, either because the irritation is insufficient or because of the deficient vitality of the part, the granulations are feeble and unstable, and they in turn becoming infected by the multiplying bacilli serve only to extend the area of the disease. This granulation tissue, before and after the stage of infection, absorbs and destroys the bone. If the progress of the disease is slow, the cancellous structure is completely absorbed or is represented only by bone sand, but if the disease infiltrates the bone more rapidly it may destroy its vitality while its structure is still retained, and a sequestrum is formed. Such sequestra, consisting of rounded, yellow, crumbling masses of cancellous structure, from the size of a peanut to a hazelnut, are especially common in epiphyseal disease of childhood. In rare instances wedge-shaped sequestra are found with the base at the periphery of the epiphysis. These are supposed to be caused by the lodging of an infected embolus in a terminal vessel, thus cutting off the blood supply.

By the formation of new tubercles at the periphery, and by the caseation of material in the centre of the diseased area, a cavity in the bone is formed, containing the débris of the granulation tissue and often sequestra of larger or smaller size, and a variable amount of fluid, made up of serum and leucocytes, that has exuded from the surrounding granulations. The walls of this cavity are formed by the tissue in which the disease is active; the inner layer containing the tubercles in the various stages of formation and decay, the outer, composed of feeble, ill-nourished, granulation tissue as yet not infected, and beyond this the softened and infiltrated bone. If the disease has ceased to progress in any direction, the granulations contain more bloodvessels, they are of firmer consistency and more perfectly organized, and the substance of the bone is harder, showing the evidence of repair.

One termination of epiphyseal disease is by enclosure of the focus by resistant granulations, behind which the bone solidifies and shuts in the disease, or, in favorable cases in which its area is small, completely absorbing and replacing it by scar tissue.

Extra-articular Disease. As a rule, the tendency of the process is to expand and to force an opening through the cortex of the bone to the exterior. In certain cases this opening may form outside the capsule of the joint, and through it the products of the disease may be discharged into the overlying tissues, forming a *tuberculous abscess*. Here, the same process of infection and extension of the area of disease continues, but more rapidly than

when it was confined within the bone. The surfaces of the muscles and fascia are infected, and are covered with an abscess membrane of violet or grayish-yellow color, made up of tubercular tissue and masses of fibrin, lying upon and loosely attached to the outer inflammatory or healthy granulations.

The cavity of the abscess is distended with tuberculous pus usually of a thin consistency, composed of serous exudation, leucocytes, fibrin, masses of degenerated tissue and fragments of bone or bone sand. It is commonly of a whitish color, occasionally reddish from mixture with blood, and, in the later stages, yellow and serous-like. The abscess enlarges in the direction of least resistance, and in most instances finally perforates the skin by one or more openings through which its contents are discharged. Or, its boundaries may cease to extend, its contents may be absorbed, adhesions may form between its walls, and a spontaneous cure is effected. Extra-articular disease, without ultimate involvement of the joint, is unusual. It is more common at those joints like the knee, elbow, and ankle, in which the bones are superficial; it is very uncommon at the hip-joint, and it is practically impossible in disease of the spine.

Perforation of the Joint. Usually the tuberculous process within the epiphysis, enlarging its area, comes into contact with cartilage, and, perforating this, finds its way into the joint. While the disease is still confined within the bone, the tissues within the joint are involved in a sympathetic irritation or inflammation. The synovial membrane becomes congested and hypertrophied; the synovial fluid is increased and changed in quality; fibrin forms and is deposited upon the cartilage and upon the lining membrane of the capsule. It is stated by Koenig that the organization of these fibrinous deposits upon the cartilage plays an important part in its destruction, even when actual tuberculous disease is absent. As a result of the sympathetic inflammation within the joint, adhesions may form which may limit the area of the tuberculous disease and retard its progress after perforation has taken place. This process is similar to the inflammatory changes in the pleura caused by the underlying tuberculous disease.

When the disease comes in contact with the cartilage it disintegrates; the tuberculous granulations breaking through and spreading over its surface destroy it in piecemeal, or, advancing beneath it, separate it from the bone in large, necrotic fragments. The synovial membrane becomes thickened and infiltrated,

numerous tubercles appear upon its surface, which undergo the secondary changes that have been described, and the joint becomes, practically speaking, an abscess cavity. The surfaces of the bones are disintegrated by the disease, and the destruction is hastened by the pressure and friction due to muscular spasm and to functional use. The thickened capsule, distended by the fluid and solid products of the disease, is usually perforated, and a secondary abscess, communicating with it, is formed in the surrounding tissues. As results of the disease, *secondary changes* appear in the neighboring parts. The irritation of the periosteum, if the disease is of a quiescent type, may induce the formation of irregular layers of bone or osteophytes about the joint. A new formation of connective tissue proceeding from the layer of granulations that surround the disease may extend to the muscles and tendon sheaths, binding them together, and causing limitation of motion. The newly-formed connective tissue may be very vascular and irregular in formation, and intermixed with it may be masses of gelatinous or myxomatous tissue. This, according to Krause, is due to the venous stasis and œdematous infiltration caused by the pressure of the capsular contents and extracapsular proliferation of granulation tissue. These changes in the appearance and in the consistency of the tissues about the joint are characteristic of the so-called white swelling.

Other Forms of Tuberculous Disease of Joints. All of the German writers describe forms of primary synovial disease, its frequency varying from 16 to 35 per cent. of the cases. It is more common in adult life than in childhood, and at the knee than at other joints. But Nichols[1] states that he has examined 120 tuberculous joints, and has found in every instance one or more foci in the bone that apparently preceded the disease in the joint.

Whatever may have been its origin, from the clinical standpoint, one must recognize a form of disease in which the symptoms differ from the ordinary osteal type. It begins as a chronic synovitis, although the tissues are more thickened and infiltrated than in simple synovitis, and the muscular atrophy is more marked. Reflex spasm and limitation of motion are slight, and the symptoms are rather discomfort and fatigue after exertion than actual pain. After many months or years, when it may be assumed the bones are involved, the characteristic symptoms of

[1] Transactions American Orthopedic Association, vol. xi.

tuberculous disease appear. In one form of synovial disease the amount of effused fluid is large, and it is clear and serous-like in character—hydrops tuberculosus; but usually it is cloudy, and it may be purulent in character.

As has been stated, Koenig lays stress upon the important part played by fibrin in the changes that take place within a joint. Fibrin deposited from the effused fluid forms in successive layers upon the cartilage. Into this fibrin vessels grow from the hypertrophied and infected synovial membrane, destroying the cartilage together with the underlying bone. If the synovial disease is primary the bone is destroyed superficially, but if it is secondary to synovitis disease within the epiphysis it is usually more extensive. Synovial tuberculosis is essentially a chronic affection and is often mistaken for simple or so-called rheumatic synovitis.

Arborescent Synovial Tuberculosis. In this form the interior of the joint is covered with villous proliferations of the synovial membrane. It is not a distinct disease, but is an irritative hypertrophy that is present in syphilitic and rheumatic as well as in tuberculous joints. Its especial interest lies in the fact that the hypertrophied synovial growths may cause mechanical interference with the function of the joint.

FIG. 159.

Lipoma arborescens. (Painter and Erving.)

Lipoma Arborescens. Arborescent villous proliferations are formed of adipose and fibrous tissue covered with a layer of round cells. The hypertrophied masses which project into the joint are often of large size, attached to the synovial membrane by a smaller pedicle. They are single or multiple, and vary in color

from yellow to deep red. They may be of a soft or firm consistency. In this form of disease, as in that described in the preceding section, there is usually pain, limitation of motion; often the swollen joint is irregular in outline; the hypertrophied synovial prolongations are sometimes apparent on palpation.[1] The exact diagnosis is usually made only after an exploratory incision, and in such an event the removal of the larger prolongation would be indicated. The outcome depends, of course, upon the cause, the hypertrophy depending usually on an underlying tuberculous, syphilitic, or so-called rheumatoid disease. In the instances in which the hypertrophied tissue is in itself the cause of the disability, cure may follow its removal.

Rice Bodies. Rice bodies are numerous small, grayish-white bodies resembling cucumber seeds that are found in certain forms of synovial disease, and particularly in tuberculosis of tendon sheaths. They are formed of fragments detached from the proliferating synovial membrane and possibly of simple fibrin, which, under the influence of pressure and attrition in the movements of the joint or of the tendon, assume the characteristic shape and appearance. These bodies, within a tendon sheath or joint, cause a peculiar creaking, perceptible to the touch when the part is moved.

Dry Caries. Caries Sicca. In this form of disease, which is apparently primarily synovial, there is but little formation of fluid, and there is but little tendency toward cheesy degeneration of the tuberculous products. The infected granulations destroy the bone without forming sequestra, and usually without suppuration. This form more often occurs at the shoulder-joint, and it is characterized by marked limitation of motion, extreme atrophy of the surrounding parts, and sometimes by forward displacement of the partly destroyed head of the humerus that may be mistaken for a primary dislocation.

Septic Infection. When a tuberculous abscess has opened spontaneously, or when it has been incised, infection with pyogenic germs is common, and it occasionally occurs before a communication with the exterior has been established. After such infection the surrounding tissues become infiltrated, reddened, and sensitive to pressure. The discharge is greatly increased in quantity and changed in quality. The local pain and discomfort are aggravated; if the joint is involved the destruction of the

[1] Painter and Erving. Boston Med. and Surg. Journal, March 19, 1903.

bone goes on with increased rapidity, and the constitutional effects of pyogenic infection appear. If the area of the abscess is small and if the drainage is efficient, this accident is of slight importance, and it may even exercise a beneficial effect in stimulating the circulation and dissolving the effused material about a joint. But if the abscess has burrowed widely into surrounding tissues and if it communicates with an important joint it is a dangerous complication; in fact, the greatest direct danger of tuberculous joint disease. Persistent suppuration exhausts the patient, and by lessening the vital resistance it favors the local advance of the tuberculous disease and its general dissemination. It is in this class of cases that amyloid degeneration of the internal organs is common, induced not by tuberculous disease, but by the secondary infection and its consequences.

Repair. Repair in tuberculous disease may be accomplished by the absorption, ejection, or enclosure of the disease. The process of repair usually accompanies the advance of the destructive process, and examples of the three methods of cure may be found in a single joint.

The curative agent is the granulation tissue which forms about the area of disease, and which, finally becoming sufficiently organized to resist the infection of the bacilli, solidifies into fibrous tissue. In those cases in which the disease is not absorbed or completely thrown off in the abscess formation, but is enclosed, it becomes quiescent. In such cases traumatism, when, for example, the surrounding adhesions are broken down in the attempt to rectify deformity or to overcome anchylosis, may cause local recurrence of the disease.

Prognosis. The prognosis will be considered more particularly in the sections on disease of special parts. The danger to life is direct and indirect, and this varies greatly with the part that is affected and with the age of the patient.

In disease of the spine the direct danger to life is greater than in joint disease, because of its situation, since it may involve the spinal cord or extend to the important organs in the neighborhood. Abscess may in rare instances, merely by its size and situation, endanger life, and when infected it is far more dangerous because of the difficulty in providing efficient drainage. The influence of deformity and its effect in compressing the internal organs and thus interfering with the vital functions is another more remote element of danger in disease in this situation.

The danger to life from disease of the joints is in proportion to their

importance. In rare instances it may extend from the epiphysis to the shaft of a bone and set up an extensive osteomyelitis; or the patient may be weakened by the suffering caused by active disease, but, as has been stated, the most direct and constant danger is from prolonged suppuration that follows septic infection. Danger from this source is much greater at the hip-joint than at the ankle or elbow, for example, because of the greater difficulty in preventing the burrowing of pus when infection has occurred.

The indirect danger of tuberculous disease is its dissemination to more important organs. But it by no means follows that the disease of the joint is the source of the general infection. For, as has been stated, it may be inferred that nearly every patient with joint disease has also disease of the lymphatic glands, and in a small proportion of the cases there may be active disease of other important organs as well. Tuberculosis of the lungs, for example, is often present in the adult before the local outbreak in the joint appears, and it is in great degree because of this liability to disease of the lungs that the prognosis of joint disease becomes progressively worse with the age of the patient.

This point is illustrated by the statistics of Koenig and Bruns on the final results of disease of the knee and hip-joints, to which attention will be called again in the special sections. In Koenig's cases of disease of the knee-joint the influence of age upon the death-rate is illustrated by the following table:

Less than 15 years of age	20 per cent.
From 16 to 30 years	24 "
" 30 to 40 "	44 "
More than 40 "	60 "

In Bruns' statistics the death-rate was of patients in the first decade, 36 per cent.; in the second decade, 44 per cent.; older than this, 72 per cent.

The cure of latent tuberculosis in the lymph nodes as well as of active disease of the lungs or bones depends upon the vital resistance of the patient. This vital resistance is lessened by pain, by confinement and lack of exercise. It is directly impaired by the exhausting suppuration and by the poisoning of the toxins incidental to septic infection. Under these conditions the local disease advances and a general dissemination is more probable. This accounts for the fact that death from general tuberculous infection is much more common in this class than when suppuration has been slight or absent. This point is again illustrated by the statistics referred to. The death-rate in the cases of disease at the knee without abscess was 25 per cent., with abscess

46 per cent. Death-rate in cases of disease at the hip with abscess 52 per cent., without abscess 23 per cent.

It is probable that tuberculosis may be disseminated by operation upon tuberculous joints, although the evidence upon this point is vague and conflicting. Gibney, contrasting two equal periods of thirteen years of service at the Hospital for Ruptured and Crippled, in the first of which no operations were performed on tuberculous subjects, states that in his opinion the deaths from this source have been proportionately no greater during the period of active surgical intervention than before. And an investigation of the causes of deaths among the patients treated at the New York Orthopedic Dispensary and Hospital during a period of twenty years showed that at least 25 per cent. of these were due to tuberculous meningitis.[1] During this period there had been, practically speaking, no operative intervention, yet the proportion of deaths from this cause is certainly as great as in any statistics that have been reported. It would appear, then, that the danger of dissemination is not sufficient to deter one from performing any operation that seems to be indicated by the character of the local disease or by the general condition of the patient.

Diagnosis. Diagnosis is considered at length in the sections on diseases of the special joints. The *tuberculin test*, although of some importance from the negative standpoint, is of no particular value as establishing a diagnosis of joint disease, for the reason that tuberculous disease of the lymph glands is so common even among those whose joints are free from disease. For the same reason it is valueless as a test of cure. This is illustrated by the investigations of Frazier and Biggs[2] of patients clinically cured of local tuberculosis, some by operative means. In 78 per cent. of these a positive reaction to tuberculin was obtained. The *X-ray* is often of value in demonstrating the effects of disease, and in certain instances it may indicate its exact locality and extent. As a means of early diagnosis of joint disease in young subjects, however, it is of little importance as compared to the physical signs, because of the non-development of the bony structure of the epiphysis, which alone appears in the negative.

Treatment. From what has been stated of the causes of disease it follows that the general treatment should include, if possible,

[1] Personal communication from Dr. David Bovaird.
[2] University Medical Magazine, February, 1901.

a change in the hygienic conditions, relief from the danger of further infection, pure air, and proper food. These are as essential in the treatment of tuberculosis of the bones as of other parts.

The importance of the constitutional treatment of tuberculous disease, more particularly the proper environment in which the greater part of the day and even the night may be passed in the open air, can hardly be exaggerated.

As far as the cure of local disease is concerned, no treatment can be as effective as the prompt and thorough removal of the focus of disease, while it is yet limited in extent, and before the joint has become involved. This is practicable, however, in but a small proportion of the cases in childhood, because it is usually impossible to locate the disease accurately and impossible to remove it without sacrificing much of the healthy bone upon which the future usefulness of the part depends. At one time early operation, even complete excision of the joint, was justified on the plea that the disease might thus be eradicated. But now that it is known that in nearly all cases other tuberculous foci exist in the body, and as the functional results after these early operations are far inferior to those attained under conservative treatment, early excisions are limited to the adolescent or adult cases. For in this class growth has been attained and the economic conditions require that the period of disability should be as short as possible. In this class, also, early exploratory operations are often indicated, sometimes for the purpose of establishing the diagnosis, and if the disease is of the synovial type the removal of projecting folds of hypertrophied tissue and the direct application of irritants, for example, of pure carbolic acid, may be of service. Brace treatment is conducted with the aim of relieving the part of function—that is to say, from strain and injury. Functional use of a diseased joint delays natural repair, since it causes pain and thus reduces the reparative force, while it stimulates the disease and increases its destructive action. The details of treatment will be described in the consideration of disease of special joints.

Treatment by Drugs. The administration of drugs occupies a very subordinate place in treatment, since it is not believed that any drug exercises a direct action upon the local disease in the bone.

Cod-liver oil, the hypophosphites, the various preparations of iron or other tonics may be given at certain times with benefit, but the continuous administration of medicine during the years

that are required to complete a cure is, of course, out of the question.

Local Applications. IODOFORM. Iodoform is supposed to exercise a direct germicidal action and also to stimulate the formation of the granulations that cast off or absorb the tuberculous products and then become transformed into fibrous tissue. At one time direct injection of the remedy into the bones was advocated, but this has now been abandoned, and its use is practically limited to the treatment of tuberculous abscesses and certain forms of synovial tuberculosis. Iodoform is ordinarily employed in an emulsion with glycerin or oil, 10 c.c. of 10 per cent. mixture being injected at intervals of two or more weeks. Several deaths from iodoform poisoning have been reported, but injections of this quantity of the drug are apparently free from danger.

CARBOLIC ACID. Carbolic acid in dilute solutions was at one time injected into tuberculous cavities, but its use has been generally discontinued because of the danger of poisoning. Recently Phelps has advocated the use of pure carbolic acid in the treatment of tuberculous abscesses and sinuses. This is injected into the fistulæ or into the abscess cavity, which has been opened, and is allowed to remain for about a minute, when it is neutralized by copious injections of alcohol, after which the part is thoroughly cleansed by salt solution. Carbolic acid doubtless acts as a caustic, destroying the infected granulations and stimulating the reparative processes. Other remedies of this class, for example, tincture of iodine, chloride of zinc, actual cautery and the like, are also used, and in certain cases with benefit. In the treatment of tuberculous ulcerations ichthyol, balsam of Peru, and iodoform are among the drugs employed. Balsam of Peru dissolved in castor oil of a strength of about 10 per cent., as suggested by Van Arsdale, is a very satisfactory application.

X-ray Treatment. The X-ray as a local treatment appears to act as a stimulant of the reparative processes. It is of especial value as an adjunct in the cases in which the tissues about the joint are infiltrated and traversed by discharging sinuses. The exposure of the diseased tissues to the direct rays of the sun is certainly a harmless treatment, and it should be applied if occasion offers.

ACTIVE AND PASSIVE CONGESTION IN THE TREATMENT OF AFFECTIONS OF THE JOINTS.

Bier's treatment of tuberculous joint disease was suggested by the observation of Rokitanski, that phthisis was uncommon in individuals suffering from disease of the heart when the mechanical obstruction was sufficient to cause venous congestion of the lungs.

Passive or venous congestion of a joint is attained by constricting the limb with several circular turns of a rubber bandage above the affected joint sufficiently to interfere with the return of the venous blood, but not with the arterial supply.

The congestion is localized by bandaging the limb firmly with flannel or other somewhat elastic material up to the lower margin of the joint. When properly applied the joint becomes swollen and dark red in color. The local temperature is raised. This is what Bier calls hot congestion, as distinct from œdema (cold congestion) that would result if the rubber bandage were applied so tight as to constrict the arteries. Passive congestion should not cause or increase pain. If it has this effect it is improperly applied or is unsuitable for the case (Fig. 160).

The action of the venous or passive congestion is, according to Bier, as follows:

1. It increases the formation of fibrous tissue and induces hypertrophy of the bones.

2. It has a bactericidal action in infectious joint disease, notably tuberculosis.

3. It exercises an absorptive effect on the effused products of disease and on new formations that check joint motion.

4. It relieves pain and lessens the activity of progressive joint disease.

The most important indication for passive congestion is in the treatment of tuberculous disease.

As applied for the purpose, when the patient has become accustomed to its use, it is continued during the day and discontinued at night, the limb being elevated to allow for the escape of the venous blood. If applied for disease of the wrist-joint it is unnecessary to bandage the fingers, as the finger-joints are usually stiff either from disuse or from adhesions about the tendons—a condition for which treatment by venous congestion is indicated.

Passive congestion for tuberculous joint disease should be sub-

ordinated to protective treatment, although this is not the opinion of Bier, who favors motion rather than fixation of the diseased joint. It may be continued indefinitely according to its effect. As a rule, pain is lessened by the treatment and muscular spasm decreases. This latter effect is in part, at least, explained by the constriction of the muscles of the thigh.

FIG. 160.

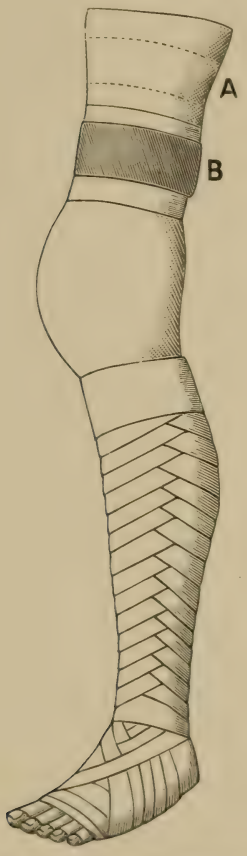

The application of passive congestion. A, the alternate point for the application of the bandage, in order to avoid atrophy from continuous pressure. B, the rubber bandage. (Bier.)

FIG. 161.

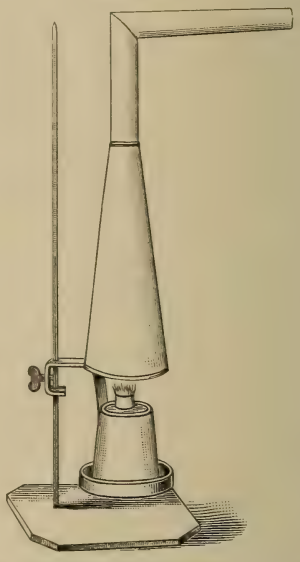

The alcohol lamp and chimney. Used for active congestion. (Bier.)

Abscess formation or appearance at least is apparently favored by the congestion. This may be treated by aspiration or incision, and by the injection of the iodoform emulsion if desirable.

Passive congestion is employed also for the treatment of chronic disability following injury, for chronic disease, such as rheumatoid arthritis or other affection attended by infiltration of the tissues. In this class of cases the local congestion should be reduced by active daily massage instead of by elevation of the limb.

The treatment of acute infectious processes by passive congestion occupies a subordinate or experimental position.

Active Congestion. Active congestion is induced by the local use of heat, ordinarily hot dry air.

In its simplest form the apparatus consists of an alcohol lamp provided with a long metal chimney reaching to a box of wood or metal, into which the limb is inserted through openings at either end. The box has one or more small openings for the escape of air and moisture. The limb is usually wrapped in sheet wadding, and is particularly well protected from the parts of the box which may come in contact with the skin. The heat is then applied, usually to about 250° or 300° F., for from thirty minutes to an hour daily. The degree of heat is indicated

FIG. 162.

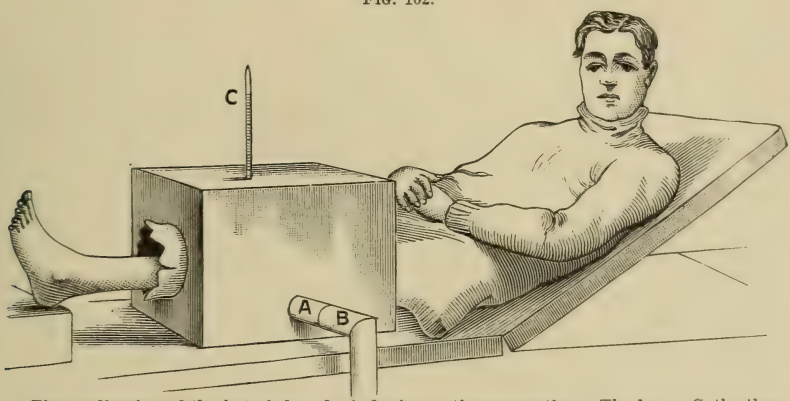

The application of the hot-air box for inducing active congestion. The box. C, the thermometer. A, a metal pipe projecting from the box, into which the chimney of the lamp is placed. B, lamp chimney. (After Bier.)

by a projecting thermometer, and it is regulated by the comfort of the patient and by the observation of its effects.

Bier prefers simple boxes of wood of various shapes suitable for the different parts of the body, lined with packing cloth soaked in a solution of water glass. He considers these as efficacious as the complicated and expensive appliances, and at the command of all who desire to employ the treatment (Fig. 162).

The effect of the heat is to induce arterial instead of venous hyperæmia, and to cause profuse local and general perspiration. Active hyperæmia is not suitable for the treatment of active or progressive joint disease. It exercises a dissolving and absorbing action on effused material and on the tissues of new formation causing limitation of motion within a joint. It increases

local nutrition and it relieves pain. It is especially indicated in the treatment of local disability after injury, chronic effusions into joints, rheumatoid arthritis, chronic rheumatism, and the like.

As a rule, the application of local heat should be supplemented by massage. The profuse general perspiration that is induced by it is a contraindication in weak individuals.

CHAPTER VI.

NON-TUBERCULOUS DISEASES OF THE JOINTS.

Syphilitic Diseases of the Joints.

In *early infancy* the characteristic syphilitic disease of the bones is a form of osteochondritis. Painful, sensitive swellings appear at the epiphyseal junctions, either as small, hard tumors, or as general enlargements, resembling those of rhachitis (Fig. 163). As a rule, several epiphyses are involved, more often those at the distal extremities of the bones of the lower limbs, and in these cases the pain and discomfort may induce an appearance of helplessness of the part called pseudoparalysis (Parrot). In osteochondritis there is a multiplication and irregularity of the cartilage cells of the ossifying layer and premature calcification. As a result, the circulation is insufficient and necrosis of a part of the cartilage may follow, which, acting as a foreign body, sets up inflammatory changes in the adjoining parts. The process is shown by a zone of hard, dry, yellow substance in the ossifying layer, adjoining which is an inflammation of the tissues of the newly formed bone which is in part replaced by granulation tissue. If the disease is progressive, ulceration and suppuration may follow; the cartilage may be destroyed, and the epiphysis may be separated, causing deformity and cessation of growth. The neighboring joint is usually involved in the disease. In the milder cases there is a simple sympathetic synovitis; in the advanced class a destructive arthritis. In one case seen recently the symptoms of pain on motion combined with slight effusion into several joints were present without the epiphyseal enlargement. The affection may be distinguished from rhachitis by the accompanying evidences of inherited syphilis, by the irregularity of the epiphyseal involvements, and by the age of the patient and the absence of the other symptoms of rhachitis.

In the *later manifestations of hereditary syphilis*, in which the bones in the neighborhood of the joint are involved in syphilitic osteoperiostitis, the joint may be sympathetically affected or the disease may actually perforate the joint. In this form of disease

the synovial membrane is usually hypertrophied and it may interfere with the function of the joint. The fluid is increased in quantity and the affection may resemble synovial tuberculosis. A slow, chronic, infiltrating gummatous form of disease appearing in later childhood may simulate very closely the appearances of so-called white swelling. It is more common at the knee, but other joints are often affected as well.

FIG. 163.

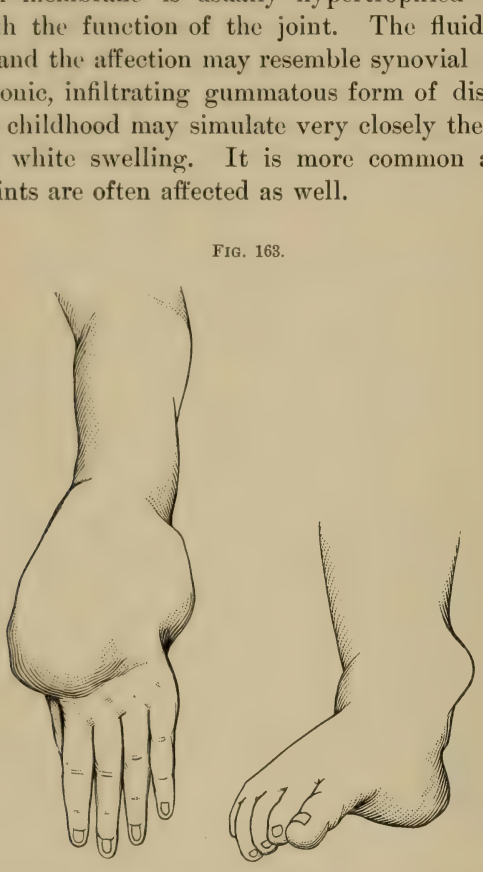

Suppurative syphilitic epiphysitis at lower ends of radius and tibia in an infant aged one month. The child died shortly after the drawings were made, and the epiphyses were found lying loose in purulent cavities. (Tubby.)

In the *secondary stage of acquired syphilis* pain and swelling of the joints, resembling rheumatism, may be present, and in tertiary syphilis the joint may be involved in disease of the neighboring bones, or the joint itself may be primarily implicated.

In most instances the joint affections of syphilis are explained by the history and by the other signs of syphilitic disease. Spina ventosa (Fig. 165), which is classed as one of the evidences of syphilis, is far more commonly of tuberculous origin, as is illustrated by the statistics of Karewski,[1] of 157 cases, in which but three were due to syphilis.

Syphilitic disease of the joints is uncommon in orthopedic

[1] Chir. Krank. des Kindesalters.

clinics as compared with those of tuberculous origin. This is as might be expected, for not only is tuberculosis far more common than syphilis, but a very large proportion, according to Fournier, 77 per cent., of the syphilitic children are stillborn or die shortly after birth. Even in those that survive, disease of the bones or joints in the form that could be confounded with tuberculosis, is uncommon as compared with its other manifestations.

Fig. 164.

Syphilitic osteoperiostitis of the tibiæ resembling anterior bow-leg. This is the most characteristic manifestation of hereditary syphilis.

Treatment. Some writers consider hereditary syphilis to be a very important predisposing cause of tuberculous disease, and believe that many cases classed as tuberculous are in reality syphilitic, even if no history or confirmatory signs of syphilis are present. There is no reliable evidence to support this view. The possibility of the syphilitic taint, remote or direct, should be borne in mind, and in doubtful cases appropriate remedies should be employed.

In general, the treatment of the joint affection would be

included in the appropriate treatment of the disease of which it is a complication. If the joint is involved in a destructive process appropriate apparatus to insure rest and protection is indicated. The removal of irritative disease in the neighborhood

FIG. 165.

Hereditary syphilitic disease of the metacarpus and phalanges.

FIG. 166.

Hereditary syphilitic disease of the joints. In this case the interior of the right knee-joint was lined with hypertrophied folds of synovial membrane. A complete cure followed the administration of appropriate remedies.

of a joint is sometimes possible in older subjects, and in this class of cases an exploratory incision for inspection of the joint is sometimes advisable (Fig. 166).

Gonorrhœal Arthritis.

Synonym. Gonorrhœal rheumatism.

So-called gonorrhœal rheumatism is an inflammation of a joint caused by the presence of gonococci. It is said to complicate from 2 to 5 per cent. of all the cases of gonorrhœa, usually appearing in the later stages of that affection, and it is more common among those who are in a debilitated condition.

Distribution. In about 40 per cent. of the cases it is monarticular and the knee-joint is most often involved. In 375 cases collected by Finger the distribution was as follows:[1]

Knee	136	Shoulder	24
Ankle	59	Hip	18
Wrist	43	Jaw	14
Finger-joints	35	Other articulations	21
Elbow	25		375

Bennecke[2] has tabulated 78 cases recently under treatment. The 78 cases occurred in 56 patients, of whom 18 were males, 38 females. The distribution was as follows:

Knee	31	Shoulder	4
Hip	8	Elbow	10
Ankle	9	Wrist	6
Other joints of foot	6	Fingers	4
			78

In 46 cases recorded by Markheim[3] one joint was involved in 13 cases, two joints in 12, three joints or more in 18. The order of frequency was knee, hip, shoulder, wrist, and elbow.

Symptoms. The affection is usually of a subacute character. The joint becomes swollen and there is discomfort, and particularly weakness, and stiffness on use. If the infection is more severe there may be local heat, pain, and infiltration of the tissues with accompanying muscular spasm.

In all the forms the infiltration of the subsynovial tissues of the capsule and of the superficial tissues is more marked than the actual effusion within the joint. The more serious cases are characterized by a peculiar œdematous, boggy swelling of the tissues, and the skin is hot, sensitive, and glazed. There is usually intense pain on motion of the limb or on jar. After the subsidence of the acute symptoms the thickening persists, and practical anchylosis may result.

[1] Taylor. Venereal Diseases, p. 263.

[2] Die Gon. Gelenkentzündung nach beob., der Chir. Univ. Klin. in der K. Charité zu Berlin. Hirschwald, Berlin, 1899.

[3] Deutsche Archiv f. klin. Med., 1902, vol. lxxii. p. 186.

Gonorrhœal arthritis has been divided into three classes according to its symptoms and physical characteristics: the serous, the serofibrinous, the purulent.

The *serous form* is, as its name implies, a simple effusion resembling other forms of subacute synovitis, although it is of a more chronic character.

The *serofibrinous variety* is the so-called plastic type of inflammation. In this form fibrin is deposited upon the cartilage and it is afterward organized by the growth of vessels into it from the synovial membrane, a process which erodes the cartilage upon which the granulations rest. The folds of the synovial membrane adhere to one another, the capsule is thickened, and ligaments and tendons may be involved in the adhesive inflammation. These changes within and without the joint may seriously impair its function after the cure of the active disease.

The *purulent form* is uncommon; it is similar in its characteristics to suppurative arthritis from other causes. It is attended by great local heat, pain and swelling, and by constitutional disturbance.

In orthopedic clinics gonorrhœal arthritis is usually seen in its later stages when the acute symptoms have subsided. In these cases swelling and pain persist in many instances, and in the more severe class motion is limited or the limb may be fixed in an attitude of deformity. An obstinate, monarticular, painful swelling of a joint suggests gonorrhœa, and its presence or absence should always be determined, since the effective treatment of the primary cause is essential to the cure of the secondary affection of the joint. The same statement is true of painful, persistent affections of bursæ and tendon sheaths, and of obstinate forms of weak foot.

Treatment. The treatment of the early stage of this form of arthritis is rest and compression, together with hot or cold applications, as may seem to be indicated. Ichthyol ointment in a proportion of about 40 per cent. appears to relieve the pain and to stimulate the absorption of the effusion. If the symptoms are acute and if there is constitutional disturbance, the joint should be aspirated, and if the examination shows the effusion to be seropurulent, it should be treated by incision and drainage. In the chronic form, also, when the capsule is distended by the serofibrinous effusion, incision and removal of the contents is indicated.

In the latter stages of disease of the ordinary subacute type, the treatment is directed to the absorption of the effused material

within and without the joint, and to the restoration of functional activity. The use of hot air, massage, the hot and cold douche, static electricity and the like are of service in stimulating the circulation. If the limb has become deformed, and if it is fixed by adhesions and by contractions, the distortion may be corrected and adhesions may be ruptured by forcible manipulation under anæsthesia. And it may be stated that in this class of cases restoration of function to a greater or less degree is often accomplished by this means.

If, however, the limb is fixed in the proper position it is well to postpone forcible measures until the effect of the massage and gentle passive movements have been observed.

Functional use is the most effective restorative treatment after the acute symptoms have subsided. This is made possible by the employment of apparatus which limits motion to the degree the joint permits without causing discomfort.

Puerperal Arthritis. This is so similar in its characteristics to gonorrhœal arthritis that a detailed description is unnecessary. It may be stated, however, that puerperal arthritis is usually of a more severe type than the preceding affection.

Arthritis Complicating Infectious Diseases.

The joints may be involved in the course of any infectious disease. A mild form of arthritis, often involving several joints, is common after *diphtheria* or *scarlatina*, and it is occasionally observed as a sequel of pneumonia.[1] This is usually of a more severe type than the preceding forms.

Arthritis following *typhoid fever* is often of a severe and destructive type. Keen[2] has tabulated 84 cases. In 43 per cent. of these the hip-joint was affected and in 40 per cent. spontaneous dislocation occurred. In a case treated recently at the Hospital for Ruptured and Crippled there had been a destructive arthritis of one hip-joint, spontaneous displacement of the femur on the other side, and secondary contractions at the knees and ankles, so that the patient was bedridden.

Treatment. The treatment in all forms of arthritis complicating diseases of this class is to place the affected joint at rest, to apply heat or cold as may be indicated by the local condition,

[1] Herrick. American Journal of the Medical Sciences, July, 1902.
[2] Surgical Complications and Sequels to Typhoid Fever.

and to prevent the secondary distortions that lead to fixed deformities. The presence of pus is, of course, an indication for immediate incision and efficient drainage; thus, in all doubtful cases the character of the effusion should be ascertained by aspiration.

Spontaneous dislocation, which is comparatively common when the hip-joint is suddenly distended with fluid, is not likely to occur unless the limb is flexed and adducted. This attitude should be prevented by the use of traction or support.

The after-treatment has been indicated already.

Prognosis. It is evident that the immediate reaction to bacterial infection and the final results will vary with the virulence of the infection, the natural resistance of the individual and of the part involved. According to Poynton and Paine[1] the bacteria reach the synovial membrane through the capillaries of the areolar tissue, beneath the endothelium, which if uninjured serves as a barrier to protect the joint cavity. If the joint is not actually involved the restriction to motion will depend upon thickening of the tissues of the joint and upon disuse of the muscles. In such cases the prognosis is good. If, however, the interior of the joint is invaded by a process that causes adhesions, and partial destruction of the cartilaginous surfaces, anchylosis is likely to follow.

Marsh[2] divides infectious arthritis into four classes:

1. Simple infiltration of the subsynovial tissues and slight synovitis.
2. Effusion of fluid into the synovial sac—synovitis.
3. Infiltration of the periarticular tissues—plastic inflammation.
4. General destructive arthritis. In the first and second classes complete recovery may be anticipated. In the third class a varying degree of functional disability is to be expected In the last it is inevitable.

Acute Arthritis of Infancy.

A form of acute suppurative arthritis primarily within the joint or more often secondary to disease of the neighboring epiphysis is not uncommon in infancy.

Etiology. The disease is usually caused by staphylococci, occasionally by other forms of infection. In the early weeks of

[1] British Medical Journal, November 1, 1902.
[2] Ibid., December, 1902.

life it may follow infection at the umbilicus or other surface lesion. It may be secondary to one of the exanthemata or to gonorrhœa, but in many instances the origin is not apparent. Falls or blows upon the part appear to be predisposing causes.

Townsend[1] tabulated 73 cases of acute arthritis, 18 of which were personal observations. To these I am able to add 12 others, making a total of 85 cases. In 64 of these the infection was monarticular; in 21 more than one joint was involved. The distribution was as follows:

Hip-joint	45	=	53 per cent.
Knee-joint	32	=	37 "
Other joints	8	=	10 "

The sex was specified in 61 cases: males, 38; females, 23. It is of interest to note that in all reported cases the males outnumber the females. In 285 cases, including the above and others reported by Gonser, Demme, Lücke, Billroth, Schede, and Müller, the proportion was nearly 3 to 1.[2]

Symptoms. If the infection is severe there is immediate local heat, redness, swelling and œdema, great pain, and corresponding constitutional disturbance. But in many instances the local and general symptoms are less marked, the child is fretful, and the evident discomfort caused by motion at the affected joint is mistaken for result of injury or rheumatism. In this class of cases the patient is not, as a rule, seen until several weeks after the onset of the affection. The joint is then somewhat infiltrated and enlarged, motion is painful and restricted, and the general appearances are very similar to tuberculous disease. There are also, without doubt, even milder forms of synovial infection from which recovery is rapid and practically complete. These cases are usually classed as monarticular rheumatism.

Treatment. The treatment of the suppurative form is, of course, free incision and efficient drainage. In all cases the joint must be fixed, preferably by a light wire splint, during the active stage of the disease. An apparatus is usually required to prevent deformity or to support the weak limb when the patient begins to walk.

Prognosis. If the arthritis is a primary disease within the joint complete recovery may follow evacuation of the pus, but, as a rule, the neighboring epiphyseal junction is diseased, suppuration is prolonged, and a part of the epiphysis is destroyed

[1] American Journal of the Medical Sciences, January, 1890.
[2] Gonser. Jahrbuch f. Kinderheilk., July, 1902.

before the disease comes to an end; thus, subluxation or displacement with subsequent deformity and loss of growth are the usual results of this form of disease. At the hip-joint, for example, the laxity of the ligaments and the upward displacement of the femur that follow destruction of the head of the bone cause symptoms that in later life are often mistaken for those of congenital dislocation.

In some of the cases there is, in addition to the arthritis, an osteomyelitis of the shafts of one or more of the bones. These cases are usually fatal, or, if the patient survives, there is usually necrosis of the affected bones and consequently extreme deformity.

In the cases reported by Townsend the death-rate was, in the monarticular form, 18 per cent.; in the multiple form, 73 per cent.

In a total of 122 cases of all varieties tabulated by Hoffmann, the death-rate was 46 per cent. In 87 the affection was confined to one joint; in the remainder from two to five joints were involved.[1]

Acute Tuberculous Arthritis. In early infancy forms of acute tuberculous disease, especially at the knee-joint, may simulate closely infectious arthritis. The joint may become swollen, hot, and sensitive to pressure, and the onset may be sudden and accompanied by constitutional disturbance. Such cases are more often observed in the children of mothers suffering from advanced disease of the lungs.

Acute Osteomyelitis.

Infectious osteomyelitis is most common in early life, and the extremities of the bones in the neighborhood of the epiphyseal cartilages are most often involved. The symptoms are local sensitiveness of the bone, pain, and constitutional disturbance. The neighboring joint is usually distended by a sympathetic synovitis, and the overlying tissues are usually infiltrated. The treatment consists in immediate opening of the bone at the suspicious point, in order to relieve the tension and to establish drainage. In certain instances the joint itself may be directly involved in the disease. This may be inferred if the symptoms do not subside after the bone has been opened. In doubtful cases the joint should be aspirated for the purpose of bacteriolog-

[1] Medical Bulletin, Washington University, September, 1902.

ical examination, but even if pathogenic bacteria are found the treatment by incision or otherwise must be decided on the clinical symptoms.

FIG. 167.

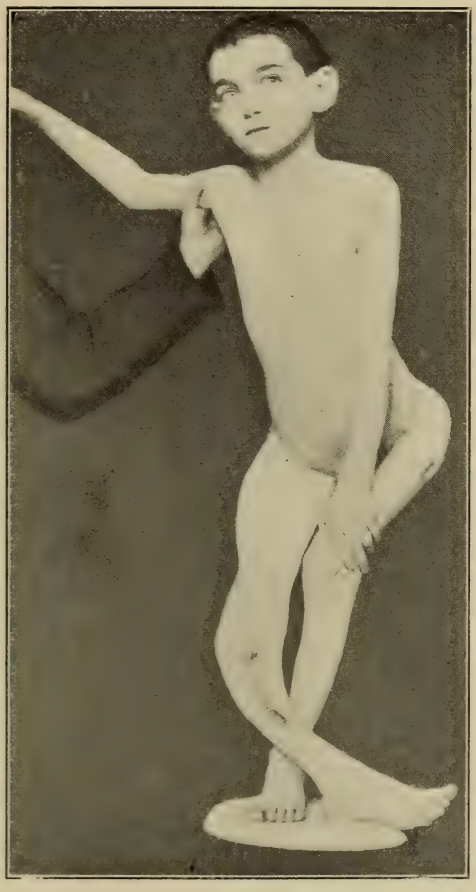

Deformities resulting from infectious osteomyelitis.

Subacute Osteomyelitis.

In older subjects localized infectious osteomyelitis in the neighborhood of a joint may simulate tuberculous disease. The onset of the affection is, however, more abrupt, the surrounding tissues are infiltrated, and the symptoms are usually more acute than in the latter affection. In this class of cases, of the subacute type, the lesions are often multiple, and in many instances the source of the original infection is evident. The treatment of choice is the

operative removal of the diseased area, which is indicated by local sensitiveness, and which in many instances may be demonstrated by the X-ray.

FIG. 168.

Loss of growth following osteomyelitis of the tibia, necessitating removal of part of the shaft.

Osteoarthritis and Rheumatoid Arthritis. Arthritis Deformans. Rheumatic Gout.

Under these titles are included a group of chronic diseases of the joints whose etiology is obscure. At the present time these diseases are usually classed as varying manifestations of one pathological process, and the titles are usually considered as synonymous.

Clinically, however, the characteristic types differ markedly from one another. In one form bone destruction is combined with bone formation, and the final result is an irregular solid enlargement of the joint, usually combined with distortion of the limb.

It has been suggested by Goldthwait that the term osteoarthritis should be applied to this type.

The second form resembles somewhat rheumatism in its course and distribution. The disease is primarily of the soft parts of the joint, the bone is only secondarily and superficially involved, and the final result is limited motion or anchylosis without enlargement of the joint. This form is sometimes classed as atrophic to distinguish it from the former or hypertrophic variety

FIG. 169.

Osteoarthritis. The hypertrophy of the extremities of the bones of the terminal phalanges (Heberden's nodes) is accompanied by erosion of the cartilage. The second interphalangeal joint of the second finger shows hypertrophy, combined with destruction and lateral displacement. (See Fig. 170.)

of arthritis deformans, but the term rheumatoid arthritis seems to be preferable, as indicating that the two varieties of chronic joint disease are distinct.

Pathology of Osteoarthritis. The disease appears to begin in the cartilage, which becomes fibrillated and destroyed in the parts subjected to greatest pressure, while it is thickened and heaped up

into irregular layers at the periphery, as if under the influence of pressure it had been squeezed out from the interior of the joint (Fig. 171). The process is supposed to consist in a multiplication of the cartilage cells which in the free portion of the cartilage escape into the joint, while in those parts covered by synovial membrane they are retained. When the cartilage disappears the bone,

Fig. 170.

Rheumatoid arthritis. Slight superficial erosions of the bones are to be seen at several of the joints. Contrast with osteoarthritis.

deprived of its natural protection, is worn away, and under the influence of pressure and friction it becomes increased in density and hardness, "eburnated." Meanwhile the irregular projections of cartilage at the periphery become in part ossified, and this, together with a formative periostitis of the adjoining bone, causes the irregular bony enlargement characteristic of the disease.

The contour of the bones and their mutual relation to one another are changed. The synovial membrane becomes hypertrophied and its villi, some of which may contain cartilaginous nodules, project into the joint in shaggy fringes. These may be detached from time to time and may form loose bodies within the capsule. The synovial fluid may be greatly increased in quantity, distending the capsule, or, communicating with bursæ, it may form cysts, as is sometimes observed at the knee-joint. But more commonly the fluid is decreased in amount. The ligaments are weakened and destroyed, and the tendons about the joint become adherent to their sheaths and to the neighboring tissues. The muscles atrophy and become contracted and structurally shortened in accommodation to the deformity.

Etiology of Osteoarthritis. Little that is positive is known of the etiology of osteoarthritis. Two factors are sufficiently evident. These are age and injury or overstrain. The wearing out of the joint is suggested by the appearances, and, as is well known, similar changes in slight degree are not uncommonly found in the joints of laborers of middle age. So, also, similar changes may follow injury, particularly fracture at the hip-joint. Lessened local and general resistance are, of course, predisposing causes. In locomotor ataxia, a disease accompanied by loss of sensation and by diminished control of movement, the nutrition of the joint is lowered and its natural safeguards against injury and overwork are removed. Joint disease (Charcot's disease) of the character of osteoarthritis in such instances is undoubtedly an indirect effect of disease of the nervous apparatus, but it by no means follows that such or any disease of the nervous system is necessary to explain the lesions of the ordinary form. It may be mentioned in this connection that a form of disease of similar character is very common among domestic animals in old age. It has been suggested, and it is probably true, that defective assimilation may be a causative factor in both man and animals.

Symptoms. In its typical form osteoarthritis is an affection of middle life and of old age. It may be confined to a single joint, and in these cases one of the larger joints of the lower extremity is more often affected, particularly the hip or knee. As a rule, however, several joints are involved to a greater or less degree. Its onset is usually insidious, and the progress is slow, accompanied by remission of the symptoms.

These symptoms are usually pain, discomfort in changing from one position to another, "creaking" sensations in the affected

joints, gradually increasing local enlargement, limitation of motion, and distortion of the limb. Typical examples are found in the hip-joint (malum coxæ senile) and knee, and these are described elsewhere.

Heberden's Nodosities. Although typical osteoarthritis may be confined to one or more of the larger articulations, it is often accompanied by enlargement of the joints of the fingers. It should be stated, also, that there is a form of osteoarthritis of comparatively slight importance in which the disease is confined

FIG. 171.

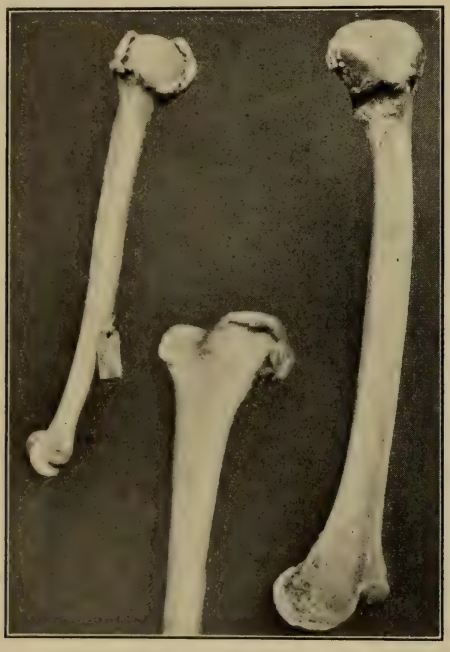

Arthritis deformans, from the Museum of the College of Physicians and Surgeons, New York.

to the joints of the fingers. The bases of one or more of the distal phalanges become enlarged (Heberden's nodosities), and the fingers become somewhat stiff and painful. Gradually other phalangeal joints become involved until the fingers become deformed and function is somewhat interfered with. The disease is slowly progressive, pain lessening as the enlargement and stiffness become more apparent. When the disease begins in this manner the larger joints are not often implicated. It is interesting to note, however, that this form of disease is far

more common in women than in men, and it may be accompanied by enlargements of the larger joints of the nature of rheumatoid arthritis (Fig. 169).

Treatment. In general, this should be directed to the improvement, if possible, of the condition of the patient; the daily routine should conform to what experience shows to be that best adapted to the disability. The local nutrition may be maintained by massage, electricity, and the like. Deformity may be prevented and pain may be relieved by regulating the strain to which the weak part is subjected. In certain instances operative removal of villous proliferations of the synovial membrane or of solid projections that interfere with movement may be of service. (See Spondylitis Deformans and Osteoarthritis of the Hip and knee.)

Rheumatoid Arthritis.

Rheumatoid arthritis differs from the preceding type in that it is rather an affection of childhood and of early adult life than of old age. It is more common among females than males. It is more acute in its onset, more rapidly progressive, and more general in its distribution than osteoarthritis.

In typical osteoarthritis the cartilage is worn away at the centre of the joint and heaped up at the periphery. In typical rheumatoid arthritis the affection is primarily of the fibrous coverings and of the membranes of the joint, and the cartilage is destroyed in the later stages by a pannus-like growth from the periphery. There is erosion of the cartilage and of the underlying bone unaccompanied by the hypertrophy characteristic of the preceding disease. In rheumatoid arthritis a spindle-shaped enlargement of the finger-joints is common, but the X-ray picture will not show irregular bone formation as in typical osteoarthritis (Heberden's nodosities), but a normal contour of the bones or superficial erosions entering into the formation of the joint. The second interphalangeal joints are usually involved primarily. There is usually flexion, contraction, and in many instances general deviation of the fingers toward the ulnar side. In younger subjects, particularly in the class of cases in which the onset of the disease is acute, and in which there is considerable effusion, there may be subluxation or actual luxation of the phalanges, more often at the metacarpal articulations. In such instances motion is preserved in the affected joints.

In typical cases the final result in any joint is either anchylosis or limited motion accompanied by flexion deformity. There is,

of course, general atrophy of the long bones in degree corresponding to the functional disability that is present.

The onset of rheumatoid arthritis may be acute, resembling rheumatism, many joints being involved simultaneously. It may be subacute and even limited primarily to a single joint.

The larger joints may be involved before those of the hands, or *vice versa*. In childhood the disease often begins in one of the larger joints, causing stiffness, deformity, and pain on motion. There is usually some local heat and infiltration, increasing and diminishing according to the strain or injury to which the joint may be subjected. In cases of this character the affection is

FIG. 172.

Rheumatoid arthritis in a child, showing the characteristic deformity. Nearly every joint in the body is involved.

usually mistaken for tuberculous disease, until the involvement of other joints indicates the true character of the affection. As a rule, the affection is progressive in character, both locally and generally. The range of motion in the affected joint becomes more and more restricted, the limb becomes flexed, and, finally, there is practical anchylosis, usually due to adhesions and contractions within and without the joint. In those cases in which the cartilage is in part destroyed by the growth of granulation tissue from the periphery there may be actual bony union. In many instances the spine becomes rigid, including the occipito-axoid articulations, and practically every joint of the body may be finally involved, so that the patient is bedridden and helpless.

The disease is more serious and more rapidly progressive in the young than in older subjects. There are periods of remission

FIG. 173.

Still's form of polyarthritis, showing the general atrophy, the enlarged joints, and the prominence of the stomach, due to amyloid degeneration of the liver and spleen.

and of exacerbation. In some instances the disease appears to come definitely to an end, leaving the stiffened joints, and occasionally complete recovery takes place, but this is unusual.

FIG. 174.

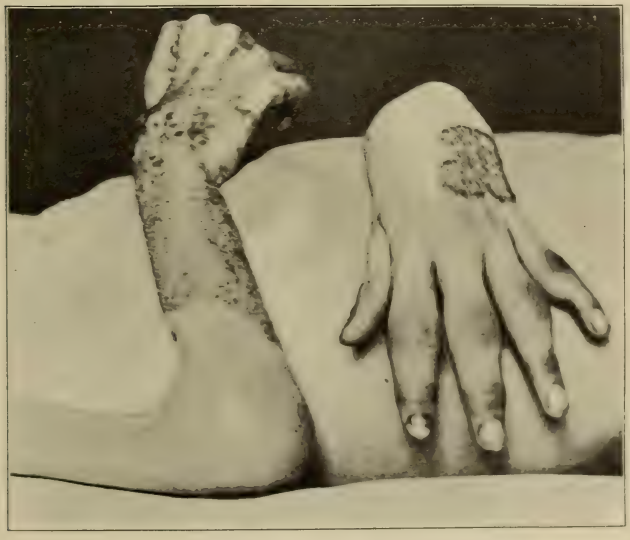

The hands in the case shown in the preceding figure.

A peculiar form of the affection, first described by Still,[1] occurs in childhood. This begins usually in one or more of the larger joints. As a rule, it progresses rapidly, and it is accom-

[1] Medico-Chir. Transactions, 1897.

panied by enlargement of the lymphatic glands particularly those of the inguinal region and axilla, and of the liver and spleen. There is, as a rule, moderate effusion into the joints and thickening of the overlying tissues. As the muscular atrophy is extreme, the joints appear by contrast very much enlarged. The final outcome of the disease is anchylosis and deformity, as in the ordinary form. Occasionally complete recovery occurs.

Etiology. Of the etiology of rheumatoid arthritis little is known. Certain aspects of the disease resemble closely those caused by infection from without. This is particularly noticeable in those cases in which the disease begins in one or more of the larger joints. On the other hand, infectious joint disease is not slowly progressive, as is rheumatoid arthritis in its typical form. It is probable, however, that certain forms of infectious arthritis of a mild character are included in what is now known as rheumatoid arthritis. Auto-infection, due to defective assimilation, is probably a predisposing and exciting cause, as it is well known that this aggravates the symptoms of the disease when it is once established.

Other causes are apparently lack of vital resistance due, it may be, to overwork or strain, mental or physical, and exposure to cold or wet. It may be stated, also, that some obscure affection of the nervous system has been assigned by certain writers as a probable cause.

Treatment. In general, this must be directed to improving the condition of the patient by the regulation of the diet, which must be nourishing and easily assimilated. Exposure to cold and wet and overexertion must be avoided. The use of static electricity, the hot-air and the electric-light baths, as general and local stimulants are of service. Ichthyol ointment, the cautery, and the like may be employed locally. If the joints are sensitive motion should be restricted to the painless area by apparatus. Passive motion or massage that increases the pain or discomfort is harmful, but motion should be encouraged when the disease is quiescent. Contraction deformity may be overcome by forcible manipulation, and, if necessary, by tenotomy when the disease is quiescent. Excision of an anchylosed joint, as of the lower jaw or elbow, may re-establish painless motion.

It may be noted as of interest that what appears to be typical rheumatoid arthritis in childhood may be induced apparently by

[1] Whitman. Medical Record, April 18, 1903.

infectious disease, such as diphtheria for example, and that improvement, or even disappearance of the local symptoms may follow intercurrent attacks of scarlatina or measles. It is possible, therefore, that serum-therapy may be employed in the future.

Although, as has been indicated, typical cases of rheumatoid arthritis differ so essentially from osteoarthritis as to be classed as distinct diseases, yet there are types that it is difficult to classify as the one or the other, and in certain instances the two forms may be combined in one individual.

Hæmophilia—Hemarthrosis.

Hemorrhage into a joint may occur in a so-called "bleeder." In this class, which is pratically limited to the male sex, the knee-joint is most often involved. As a rule, it is the result of injury, and if the peculiarity of the patient is known the nature of the effusion—hemorrhagic—is hardly doubtful, particularly as there is in many instances discoloration of the skin, either over the joint or elsewhere. In some instances there is no history of traumatism, and the swelling may be accompanied by fever. This is probably the effect of the hemorrhage rather than its cause.

The peculiar interest in the affection, aside from the importance of a proper diagnosis, lies in the fact that the further organization of the effused blood may cause symptoms and changes about the joint that may be mistaken for those of tuberculous disease. There may be, for example, persistent swelling, thickening of the tissues, limitation of motion, and deformity combined with more or less weakness and discomfort. These symptoms are explained by the irritation of the effused blood and by its further absorption and organization, which necessitates the formation and growth of new bloodvessels; practically, a granulation tissue is formed that may erode the cartilage upon which the fibrinous deposits rest. These secondary changes resemble the early stage of osteoarthritis.

Treatment. The local treatment is rest and protection combined with stimulating applications to hasten the absorption of the effused blood. Several deaths have been reported from hemorrhage after operative intervention in cases in which the affection had been mistaken for tuberculous disease.

Hemarthrosis.

Hemorrhage into a joint may occur in normal individuals, and its presence is not always indicated by superficial discoloration.

The swelling is more resistant than is the ordinary effusion, and it is far more persistent. This suggests the advisability of incision and removal of the blood clots in certain instances in order to relieve the joint of burden of their organization and absorption.

Scorbutus—Scurvy.

This affection is sometimes attended with hemorrhage into and about the joints. It will be considered in connection with infantile rhachitis.

Charcot's Disease.

Charcot's disease is a form of destructive arthritis which is secondary to locomotor ataxia.

Pathology. It resembles somewhat in its pathology osteo-arthritis. The cartilage degenerates, and, together with the

FIG. 175.

Charcot's disease of the knee-joint.

underlying bone, is worn away by the movements of the limb. Accompanying the destructive process there is an exaggerated and irregular formation of cartilage and bone about the periphery of the joint. The synovial membrane is hypertrophied, and may

be covered in places with calcareous plates; the contents of the joint is usually increased in quantity.

The joint disease usually appears early in the course of locomotor ataxia, often before its existence is suspected, and it is sometimes caused by injury.

Charcot's disease is said to affect about 5 per cent. of the ataxic patients; it is more common in the lower extremity, and one or more joints may be involved. In the cases tabulated by Flatow the distribution was as follows:

Knee	60;	in 13	cases	both knees.
Foot	30;	" 9	"	" feet.
Hip	38;	" 9	"	" hips.
Shoulder	27;	" 6	"	" shoulders.[1]

Chipault[2] notes the distribution in 217 cases, as follows:

Knee	120
Hip	57
Foot	40

Fifteen cases of Charcot's disease involving the spine have been reported.[3]

Symptoms. The symptoms are the swelling due to the effusion, laxity of the ligaments, and deformity. There is but little pain, and the patient's chief complaint is of the weakness and distortion of the limb. In certain cases the progress of the affection is very rapid, and the destruction of bone may be so extensive that there is an actual luxation at the affected joint.

Diagnosis. If the patient is known to have locomotor ataxia the diagnosis will be evident, and in any event the peculiar enlargement, and thickening of the tissues, together with the excessive laxity of the ligaments, characteristic of this affection, which has been called a caricature of osteoarthritis, should call attention to the disease of the spinal cord.

Treatment. The treatment of the local disease is efficient support to prevent progressive distortion. Excision of the knee has been performed, but in many cases the bones have failed to unite, and on this account the operation is contraindicated.

Disease of joints *secondary to other forms of disease of the nervous system* may occur. It is most common as a complication of syringomyelia, in which, in contrast to locomotor ataxia, the joints of the upper extremity are far more often involved than of the lower.

[1] Deutsche Chir., 1900, vol. l. p. 28. [2] Le Dentu et Delbet, Traité de Chir.
[3] Abadie. Nouv. Icon. de la Salpêtrière, T. xiii., 1900. Cornell, Johns Hopkins Hosp. Bull., October, 1902.

In Schlesinger's cases the distribution was as follows :[1]

Shoulder	29
Elbow	24
Wrist	18
Hip	4
Knee	7
Foot	7
Other joints	8
	97

In all forms of joint disease secondary to disease of the nervous system the influence of injury on the ill-nourished or ill-protected part is recognized in the causation and in the progress of the disease.

This indicates the principles of local treatment.

Anchylosis.

Anchylosis implies fixation in an attitude of deformity, and the term should be restricted to practical fixation caused by tissue changes within or without a joint, but it is often incorrectly applied to limitation of motion, such as may be caused, for example, by muscular spasm.

Etiology and Pathology. Anchylosis may be the result of actual union of two bones whose cartilages have been destroyed, a synostosis. This is sometimes called true, as distinguished from false or fibrous anchylosis.

It may be caused by adhesions between the folds of synovial membrane, by adhesions and contractions of the capsular and other ligaments, by adhesions between the tendons and their sheaths, by the general adhesions and contractions caused by burrowing abscesses, and by the retraction and structural shortening of muscles when the deformity has persisted for a sufficient time. It may be caused, also, by fractures or dislocations or by marginal exostoses.

Anchylosis is usually secondary to an inflammatory affection of the joint during which the adhesions have formed within and without the capsule, and if deformity has been allowed to persist the muscles are atrophied and structurally shortened on the contracted side.

Prevention and Treatment. The danger of anchylosis may be lessened by the proper treatment of the disease of which it is a result. In tuberculous disease, for example, motion may be preserved in many instances by efficient protection, by which the

[1] Die Syringomyelie, Wien, 1895.

area of the disease is restricted and its destructive effects checked. In this class of cases the joint should be fixed during the progressive stage of the disease, in the attitude in which anchylosis, if it be unavoidable, will least inconvenience the patient, and, if possible, efficient traction should be employed with the aim of separating the surfaces of the adjoining bones.

FIG. 176.



A useful form of brace for weak knee, in which the range of motion is regulated by means of an adjustable wheel. (Shaffer.)

Formerly it was believed that prolonged fixation of a diseased joint would of itself induce anchylosis, but now that it is known that final limitation of motion is dependent upon the severity and the duration of the disease, prolonged rest is believed to be the most efficient means of assuring motion.

In tuberculous cases, when the disease is cured, functional use will ordinarily restore all the motion of which the part is capable.

In other inflammatory affections of the joint which are usually of infectious origin the violence of the initial process may be restrained by the local application of cold or heat, or by the removal of the contents of the joint if the infection is severe. In all cases the joint should be properly supported in order to relieve pain and to prevent deformity.

FIG. 177.

Anchylosis at the hip, showing masses of new bone. (From the Museum of the College of Physicians and Surgeons.)

Passive Motion. When the acute symptoms have subsided the absorption of the plastic material may be hastened by massage, the hot-air bath, and the like, and by carefully regulated passive and active motion. Passive congestion after the method of Bier may be of service in certain cases. It is highly recommended by Blecher.[1] In the final stage, when there is no longer evidence of active disease, passive movements under anæsthesia may be of service in breaking adhesions, especially if these are without the joint. Passive movements that cause persistent discomfort or pain, which are often employed in the treatment of stiff joints, even when the disease is active, are absolutely contraindicated. If, however, the limb during the course of the disease has become deformed, it should be restored to its proper position as soon as possible, even though force is required. This treatment is indicated in order to prevent secondary retraction of the muscles and fasciæ.

Forcible Correction. The class of cases in which the limb has become fixed in deformity is the most favorable one in which

[1] Deutsche Zeits. f. Chir., Bd. lx. p. 250.

to perform the so-called brisement forcé, because the rectification of deformity is always indicated, and in accomplishing this there is always the prospect of regaining a certain degree of motion. If, however, there is no deformity the advisability of forced movement will depend on the character of the preceding disease as well as upon the condition of the joint. It is rarely advisable to disturb a tuberculous joint, or at least not until long after the cure of the disease; but if the anchylosis has followed infectious arthritis of a mild form, or monarticular "rheumatism," forcible manipulation may be attempted. If under gentle manipulation the adhesions give way suddenly, allowing free motion, the prognosis is good; but if there be a peculiar, elastic, continuous resistance, as when there are extensive adhesions within the joint, there is little likelihood of attaining motion by this means. If but slight force has been exerted there is usually but little reaction, and massage and passive motion may be employed at once; but in other instances the manipulation is followed by swelling and pain, and until these symptoms have subsided fixation may be indicated.

Afterward, passive movements within the range that is practically painless may be carried out manually, or by means of one of the so-called pendulum machines, by which the joint is moved back and forth at frequent intervals until the part is fatigued. Functional use, when the joint is protected by apparatus that limits the range of motion to the painless area, is also of service.

The X-ray may be of value in demonstrating the condition of the joint and the degree of atrophy of the bones, but the history, which may indicate the character of the disease, and the physical examination are far more reliable from the standpoint of prognosis. In some instances *operative exploration* of the joint may be indicated. This permits the removal of exostoses or displaced fragments of bone after fracture that may limit motion mechanically. Recently the attempt has been made to prevent reunion of the surfaces of the adjoining bones by the insertion of thin plates of magnesium or other absorbable substance, as one prevents union in smaller joints by interposing muscular or other tissue in a similar manner. As yet the method is in the experimental stage.

True bony anchylosis in the lower extremity admits of no remedy as far as the restoration of joint function is concerned, although the symmetry of the limb, if it be deformed, may be restored by osteotomy.

In the upper extremity motion may be restored by excision

of the joint, and in some instances this is advisable, particularly for anchylosis at the elbow.

It may be mentioned that anchylosis following disease is usually accompanied by marked atrophy of the bones, and fracture may occur during forcible correction. In cases of this character the rare complication of fat embolism is sometimes encountered.

CHAPTER VII.

TUBERCULOUS DISEASE OF THE HIP-JOINT.

Synonyms. Hip disease, morbus coxæ.

Hip disease is a chronic destructive disease that results in loss of function and deformity. At one time a number of pathological processes and even simple deformity (coxa vara) were included under the title, but it is now limited to tuberculous disease.

Pathology. Tuberculous disease of the hip-joint usually begins in several minute foci in the neighborhood of the epi-

FIG. 178.

Section of the hip-joint at the age of eight years, showing the epiphyses and the relation of the capsule. (Schuchardt.) At birth the entire upper extremity of the femur is cartilaginous. According to Jacinsky, ossification begins in the head of the femur at about the tenth month; in the trochanter major at from the fourth to the eighth year; in the trochanter minor at the eleventh year. Ossification is complete at all points at about the eighteenth year.

physeal cartilage of the head of the femur. Here the circulation is most active, and here the newly-formed bone is least resistant. Thus the bacilli, carried by the blood, are more often deposited at this point, where, under favoring conditions, induced it may be by slight traumatisms, the disease is established. These foci coalesce and an area of infected granulations replaces the normal

structure. If the local resistance is sufficient the disease may be confined to the interior of the bone, but in most instances it gradually forces its way into the joint, and the granulation tissue, spreading under and over the cartilage, destroys it in its progress. The lining membrane of the joint becomes involved in the disease, and, finally, the adjoining surface of the acetabulum as well. In a certain indeterminate number of cases the tuberculous process begins about the epiphyseal junctions of the acetabulum, and primary disease of the synovial membrane may occur, although this is certainly uncommon in childhood.

Fig. 179.

"Wandering of the acetabulum" in hip disease. (Krause.)

From the clinical standpoint, primary disease of the acetabulum may be inferred when the patient is particularly susceptible to movements of the trunk, or when lateral pressure on the pelvis causes pain; or when a Roentgen picture shows greater erosion of the acetabulum than of the head of the femur (Fig. 192). There are other cases, in which the symptoms of the disease are slight and in which the swelling of the joint is well marked; in such cases it is probable that disease of the synovial membrane is present, without marked involvement of the head of the femur or of the acetabulum.

In the common or osteal form of disease, while the tuberculous process is still confined within the head of the femur, the joint shows evidences of sympathetic irritation; the synovial membrane is congested, and the fluid within the joint is increased in quantity. These changes become more marked as the disease progresses, the lining membrane becomes thickened and granular, and adhesions between its folds lessen the capacity of the joint. An amount of tuberculous fluid, large enough to be recognized as an

"abscess," is present in about half the cases at some time during the course of the disease. This fluid usually finds an exit from the capsule into the tissues of the thigh, but occasionally it may pass through the acetabulum into the pelvis. In rare instances the disease may not enter the joint, but may find an opening in the neck outside the capsule. In such cases the joint is, in most instances, finally involved unless the disease is removed by surgical means. There are cases, also, in which the disease, confined within the head of the bone, so weakens it that it becomes distorted to a marked degree.

FIG. 180.

Erosion of the head of the femur and of the upper border of the acetabulum. Formation of new bone (osteophytes) about the acetabulum.

If the disease involves the neck of the bone it may sink downward, a form of coxa vara; or the head of the bone may be separated at the epiphyseal junction, with consequent upward displacement of the shaft.

In by far the larger number of cases the joint is perforated and the head of the femur and the acetabulum are eroded to a greater or less degree. In such instances the destructive effects of the disease are increased by the pressure and friction of the

softened bones on one another, aggravated by the spasm of the surrounding muscles. Thus at the upper margin of the acetabulum and the inner and upper surface of the femur there is greater loss of substance than elsewhere (Fig. 180).

The appearances in advanced cases of this type, as seen at operation or autopsy, may be summarized somewhat as follows: The head of the femur is deeply eroded, its cartilaginous covering has practically disappeared, or is in part still adherent in necrotic shreds. It lies in seropurulent fluid, embedded in the gelatinous necrotic granulations that line the capsule and partly fill the enlarged acetabulum.

FIG. 181.

Erosion of the head of the femur and of the upper margin of the acetabulum. A, anterior superior spine. B, anterior inferior spine.

In certain instances the disease may extend over the adjoining surface of the pelvis, or the acetabulum may be perforated (Fig. 182), or the medullary cavity of the femur may be implicated. Occasionally the disease may be from the first of an acute destructive type, whose course is but little influenced by treatment, but in the majority of cases the progress of the disease and its destructive effects may be greatly modified by efficient protection of the joint.

In the natural cure of the disease the focus within the bone, if it be small, may be absorbed and replaced by scar-like tissue; or the products of the disease may be separated from the healthy parts, and discharged by abscess formation. In other instances a part in which the disease is still active may be enclosed within the newly-formed tissue. Here the process may remain quiescent or it may cause relapse, many years after the apparent cure. Or portions of necrosed bone, enclosed within the capsule, may prolong suppuration after the tuberculous disease has ceased to progress.

Etiology. The etiology of tuberculous disease is discussed in Chapter V.

Relative Frequency. Tuberculous disease of the hip-joint is the most common and the most important of the affections of the joints, ranking second to Pott's disease. In a total of 7845 cases of tuberculous disease treated in the out-patient department of the Hospital for Ruptured and Crippled during a period of fifteen years—1885–1899—3203 were Pott's disease, 2230 were hip disease, while the remaining 2408 cases included all the other joints.

Age. Hip disease is essentially a disease of early childhood, although no age is exempt. In a series of 1000 consecutive cases of hip disease tabulated for me by Dr. D. D. Ashley, formerly an assistant in the department, 88.1 per cent. of the patients were in the first decade of life, and 45.6 per cent. of these were from three to five years of age, inclusive.

AGE AT INCIPIENCY.

Less than 1 year	9	Between 16 and 17 years	11
Between 1 and 2 years	39	" 17 " 18 "	4
" 2 " 3 "	107	" 18 " 19 "	5
" 3 " 4 "	155	" 19 " 20 "	0
" 4 " 5 "	158	" 20 " 21 "	3
" 5 " 6 "	139	" 21 " 22 "	3
" 6 " 7 "	90	" 22 " 23 "	1
" 7 " 8 "	51	" 23 " 24 "	2
" 8 " 9 "	51	" 24 " 25 "	3
" 9 " 10 "	40	" 25 " 26 "	1
" 10 " 11 "	33	" 26 " 27 "	1
" 11 " 12 "	19	" 27 " 28 "	1
" 12 " 13 "	18	" 28 " 29 "	1
" 13 " 14 "	23	" 30 " 33 "	4
" 14 " 15 "	7	" 33 " 36 "	1
" 15 " 16 "	8	Age not stated	12
			1000

Sex. Sex exercises but little influence in predisposition, although the disease is slightly more common among males

than among females. In the 1000 cases referred to, 553 (55.3 per cent.) were in males, 447 were in females.

In 3307 cases treated at the same institution, 53 per cent. were in males.

Side Affected. In disease of this as of other joints the right is somewhat more often affected than the left. In the 1000 cases 506 were on the right side, 483 were on the left, and in 11 cases both joints were involved. In a larger number of cases treated in the department 53 per cent. were of the right joint.

Symptoms. Tuberculous disease of the hip-joint is a chronic, insidious affection characterized by occasional exacerbations of

FIG. 182.

Erosion of the head of the femur and destruction of the acetabulum.

more acute symptoms that are induced by overstrain or injury, by a more rapid advance of the destructive process, or by infection with pyogenic germs. In the early stage of the disease the joint is simply sensitive, and the symptoms vary with the activity of the disease, which may increase the tension within the bone, the susceptibility of the patient, and the strain to which the weakened part is subjected. This sensitiveness is first indicated by the involuntary adaptation of the body to the weakness of the affected joint, or, as popularly expressed, the patient favors the leg.

The important symptoms of disease of the hip-joint, in the sense of attracting attention to the affection, are *pain* and *limp*.

Of the two, pain is much the less significant. Hip disease is by no means a painful disease, and although patients are often brought for treatment because of pain, it is usually apparent, on examination, that the disease must have existed long before the acute exacerbation called attention to its serious character. Even in cases in which the disease is far advanced, one may be assured that the patient has never complained of pain.

Pain. The characteristic pain of hip disease is "pain in the knee," referred, as is the pain of Pott's disease, to the more important distribution of the nerves, whose filaments are irritated by the local process. The hip-joint is supplied by the anterior crural, the sciatic, and the obturator nerves, but the pain is more often referred to the distribution of the last, thus to the inner side of the knee. Pain so persistently referred to the knee is misleading, and patients are often treated for obscure affections of this joint long after an examination of the hip would have made the diagnosis evident.

The pain of hip disease is induced by sudden or unguarded movements, or by injury; therefore, in many instances, it is rather an occasional than a constant symptom. Persistent pain almost always indicates the increased tension either within the bone or within the joint that accompanies abscess formation.

Night Cry. Pain at night is of importance, as it more often attracts attention than the occasional complaint of discomfort during the day. It is a common symptom when the disease is at all acute in character, and it is often present when pain, during the period of activity, is apparently absent. It may be inferred, as an explanation of this symptom, that the joint gradually becomes more sensitive under the strain of use during the day, and that the relaxation of the voluntary and involuntary protection of the muscles allows sudden movements that excite spasmodic muscular contractions, which force the sensitive parts against one another. This causes a sharp cry. If the disease is acute, the child is usually awakened and is found holding the thigh with the hands or pressing upon the limb with the other foot, the evidence of pain being unmistakable. In the less sensitive conditions the patient does not wake after crying out, but simply moans or is restless for a time. If awakened it makes no complaint of pain and the cry is supposed to be caused by a "bad dream." This cry may be repeated several times, more often in the early part of the night.

Direct local pain and sensitiveness to pressure are unusual

unless the disease is acute in character, or unless the tissues overlying the joint are implicated, as in abscess formation.

Limp. The limp is the most important of what may be classed as the preliminary signs of the disease. A limp is a change in the rhythm of the gait, a long step alternating with a shorter step. It is evident that any interference with the function of the limb will cause this irregularity which can be concealed or diminished only by accommodating the normal member to its disabled fellow. Thus an inequality in length, or a limitation of motion in the joint, or distortion, or weakness or pain, may cause an arrhythmical gait. Several of these factors may be combined in the causation of the final disability of hip disease, but in the beginning, the limp is due rather to sensitiveness than to any marked restriction of function. Thus the patient favors the joint by resting on the limb for a shorter time than on its fellow, and by bearing more weight upon the front of the foot than upon the heel. If the joint is very sensitive, the patient may bear practically all the weight upon the front of the foot, slight plantar flexion at the ankle being combined with slight flexion at the knee and hip; thus the jar of direct impact of the heel upon an extended leg is avoided.

The limp is a constant symptom of hip disease that is more or less noticeable according to the character of the disease; it is even subject to daily variations in the same patient, being, as a rule, more apparent in the morning or on changing from an attitude of rest than during activity. The limp may be intermittent even, although it is probable that in most instances some change from the normal gait might be detected by a practised eye.

The other symptoms of disease of the hip-joint are more properly physical signs that become evident on examination. These are: *stiffness*, *distortion*, *change of contour of the hip*, *atrophy*.

Stiffness, due to reflex muscular spasm, is by far the most important sign of the disease. It is the instinctive expression of the inability of the joint to perform its full function and especially to allow the full range of motion which puts more strain upon the bones and the other components of the joint. It is the first and the last sign of disease; it probably precedes the limp, and it remains long after pain has ceased to be a symptom, and until repair is complete.

Reflex muscular spasm limits motion in *every direction* to a greater or less degree. At an early stage of the disease the

motion, whether voluntary or passive, may be perfectly free throughout three-fourths of its normal range, but when the limit allowed by the muscular protection is reached motion is checked by a peculiar elastic resistance. If an attempt is made to force the limb beyond the limit set by the muscular resistance the entire

FIG. 183.

Apparent lengthening. Fixed abduction of 45°. When the anterior superior spines are on the same plane, as in the illustration, the deformity is evident. (See Fig. 184.)

body follows the movement. The contraction of the surrounding muscles, including those of the trunk even, may be appreciated by the eye and by the hand, and the expression of the patient's face shows discomfort and apprehension.

The degree of muscular spasm corresponds to the sensitiveness of the joint rather than to the area of the destructive disease.

Thus it may vary from day to day and even from hour to hour, and in the acute exacerbations of the disease motion may be for a time so absolutely restricted as to simulate anchylosis.

Reflex muscular spasm is an infallible sign of a sensitive joint; it is, of course, a symptom not confined to the tuberculous

FIG. 184.

Apparent lengthening. When the distorted limb is brought to the median line the pelvis is so tilted that the abducted leg seems longer. (See Fig. 183.)

FIG. 185.

Right-angle flexion in hip disease partly concealed by the compensatory lordosis and by the flexion at the knee and ankle.

process, but unless it be the direct effect of injury it indicates disease, and if this disease be chronic and confined to a single joint it is, in childhood at least, almost always tuberculous in character. In the early stage of hip disease the restriction of motion is caused almost entirely by reflex muscular spasm, as

is shown by the fact that when the patient is anæsthetized the range of motion becomes practically free. As the destructive process progresses motion is still further restrained by adhesions and contractions within and without the joint.

Distortion of the Limb. Persistent reflex muscular spasm is always accompanied by a certain change in the attitude of the limb, slight flexion being the earliest indication of distortion in disease of the hip, as at every other joint. With this flexion there is usually abduction and slight outward rotation of the limb.

Flexion, Abduction, and Outward Rotation. Apparent Lengthening. This is the passive attitude or the attitude of rest in the normal condition, and in disease it shows the instinctive adaptation of the limb to a sensitive joint which is still capable of a certain amount of work. The flexion lessens the direct jar and the abduction throws the limb aside, as it were, from the active attitude, making it a prop and adjunct of its fellow instead of an active aid in the propulsion of the body. This attitude is not voluntarily assumed by the patient; it is involuntary and persistent. The limb is apparently lengthened, because it is held away from the axis of the body, and in order to bring it into the middle line and parallel to its fellow the pelvis must be tilted downward on the diseased side and upward on the other. The sound leg is drawn upward and the affected leg is lowered according to the degree of abduction (Fig. 184). If, however, the anterior superior spines of the pelvis be placed upon the same plane, the distortion becomes evident (Fig. 183). Thus the deformity of the limb is concealed or compensated by a tilting of the pelvis which twists the lumbar spine into a lateral convexity toward the lower side.

In the same manner persistent flexion of the leg is concealed by a tilting of the pelvis forward, and by an increased hollowness or lordosis of the lumbar region (Fig. 185). Normally, in childhood at least, the lumbar spine and the popliteal surface of the knee should touch the table when the patient lies upon the back, but if the thigh is fixed in flexion the lumbar region must be arched and raised from the table when the leg rests upon it. Thus, in order to make the flexion apparent, the lumbar spine must be forced to touch the table, and this is possible only when the limb is raised to a degree corresponding to the deformity (Fig. 186). If the spine were rigid, as in spondylitis deformans, this compensation would be impossible, and if the patient were placed upon his back the leg could not be brought down to the

table; or if both limbs were distorted, as is sometimes the case when both hip-joints are diseased, the limbs would remain widely separated or crossed over one another, according to the character of the deformity.

Flexion, Adduction, and Inward Rotation. Apparent Shortening. If the disease is of a more acute type, and if locomotion be permitted, the attitude usually changes to one of increased flexion, and adduction and inward rotation replace abduction and outward rotation. This attitude is an indication that the joint is so disabled as to be of little use, thus the limb is instinctively drawn into a more protected attitude where it may be used as little as possible. If the patient is confined to the bed, or does not walk, as in hip disease in infancy, the atti-

Fig. 186.

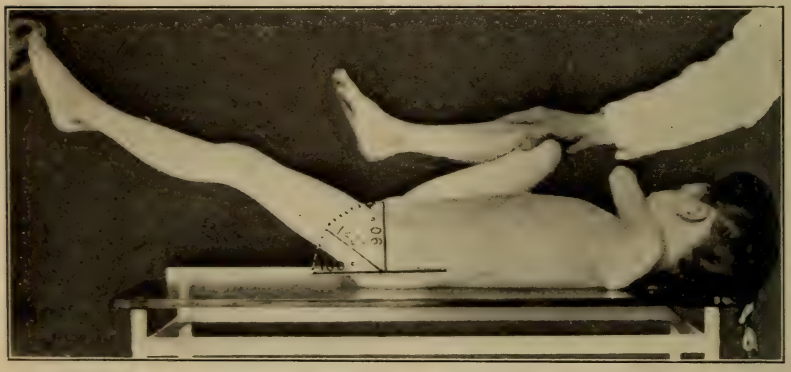

The degree of fixed flexion is shown when the lumbar spine is held in contact with the table by flexing the other thigh.

tude of abduction may persist, although the muscular spasm may be intense. Thus it would appear that locomotion has a distinct influence on the character of the distortion.

Adduction causes apparent or practical shortening; for in order to bring the adducted limb to the middle line of the body and parallel with its fellow, the pelvis must be tilted upward on the affected side and downward on the other, the lumbar spine bending with the convexity toward the lower side (Figs. 188 and 191). If the level of the pelvis be restored, the adducted limb will be crossed over its fellow, and the deformity is made evident (Fig. 187).

As has been stated, the attitude of flexion, adduction, and inward rotation, if it appears early in the disease, is usually an

indication of acute and disabling pain and of corresponding intensity of muscular spasm. But in most instances it is associated with the later and destructive stage of the disease, and it by no

FIG. 187.

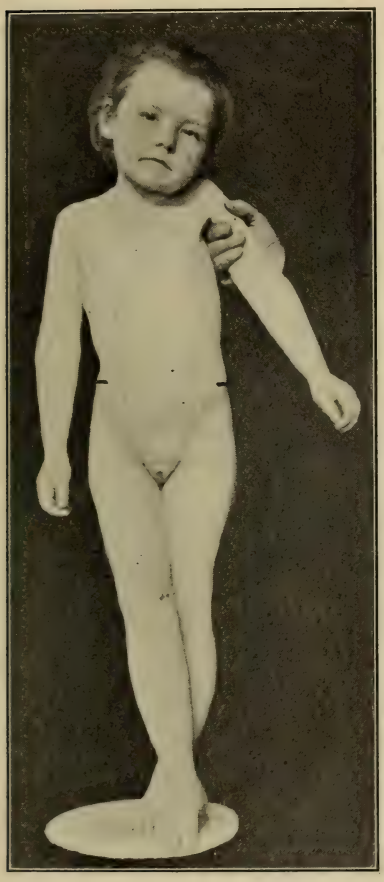

Apparent shortening. The adduction of the right thigh is made evident by the involuntary crossing of the legs when the anterior superior spines are on the same plane.

FIG. 188.

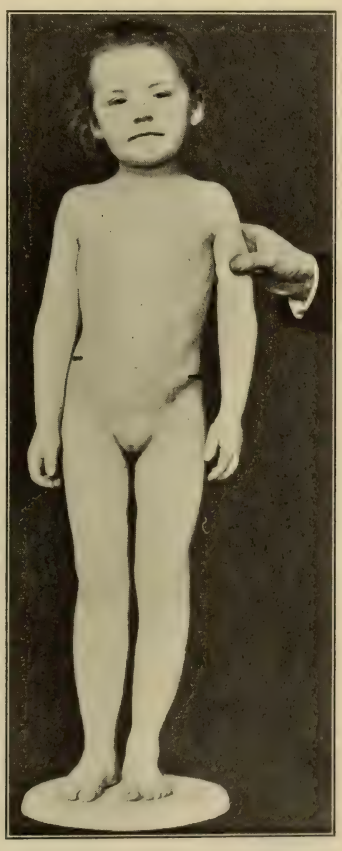

Apparent shortening. When the adducted limb is placed in the line of the body, the pelvis is tilted upward on the adducted side and downward on the other. The patient has compensated for the apparent shortening by flexing the knee on the sound side. This does not appear in the photograph.

means indicates that the preceding symptoms have been more than ordinarily acute. In fact, it is the attitude characteristic of a so-called "natural cure" (Fig. 189) when mechanical treatment has not been employed. It more often accompanies the

later course of the disease, because its causes are in great degree mechanical.

This is illustrated by Koenig's statistics of 499 cases of hip disease.

In 267 cases the limb was abducted, and in 31 per cent. of these there was actual shortening.

In 232 cases adduction was present, and in 70 per cent. the limb was shorter than its fellow.[1]

Fig. 189.

The final effect of hip disease when untreated. The natural cure, with flexion and adduction. Compensatory recurvation of the knee on the sound side is also shown.

The mechanics of the distortion will be made clearer if it be compared to the deformity symptomatic of dorsal dislocation of the hip. In this displacement the femur, forced upward and backward upon the pelvis, is fixed in an attitude of extreme flexion, adduction, and inward rotation. Each of the destructive changes of hip disease, the enlargement of the acetabulum, the depression of the neck of the femur, and the erosion of the head of the bone, is accompanied by an elevation of the femur upon the pelvis or an approximation to a dorsal displacement (Fig. 190). If this displacement occurs suddenly, as in certain cases of acute disease attended by effusion and rupture of the capsule, the limb immediately assumes an attitude typical of dorsal dislocation; but in the ordinary form of disease the changes are very gradual; the pelvis and the femur, being in most instances undeveloped, more easily accommodate themselves to the changed conditions, so that the actual distortion is less marked than in a similar subluxation of traumatic origin in the adult, but the simile will serve to illustrate the mechanical causes of distortion, and why

[1] Koenig. Das Hoeftgelenk, Berlin, 1902.

such deformity may recur after correction, even though the disease has entirely disappeared.

Outward rotation of the limb is usually associated with abduction, and inward rotation with adduction, but in certain instances

FIG. 190.

Untreated hip disease. Flexion deformity to nearly a right angle with the body. Trochanter two inches above Nélaton's line. Compensatory lordosis.

FIG. 191.

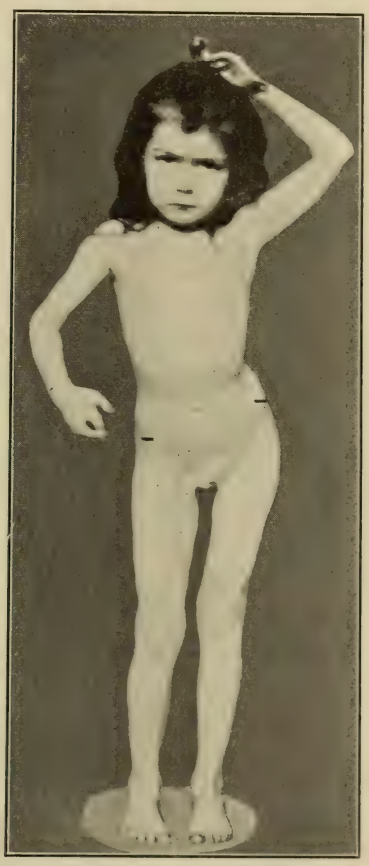

Stage of apparent shortening. The left limb is adducted 35°, making an apparent shortening measured from the umbilicus of more than two inches. In order to reduce the obliquity of the pelvis, the adducted leg must be crossed over its fellow. (See Fig. 187.) The apparent shortening is compensated by the flexion at the knee on the sound side. This is not made clear in the photograph.

outward rotation may be combined with adduction and *vice versa*. These irregular attitudes are more often observed in cases that

have received mechanical or operative treatment than in those in which the disease has pursued its natural course.

As has been stated, the distortions of the early course of hip disease are caused almost entirely by muscular contraction which relaxes under the influence of an anæsthetic, but after a time the attitude is still further assured by accommodative changes in the muscles and fasciæ, and by contractions and adhesions about the capsule. Thus an attitude that was originally a symptom may persist after the cure of the disease.

One may conclude then that flexion is practically an invariable symptom in hip disease because complete extension, the attitude that puts most strain upon the joint, is first restricted. Flexion in the milder or in the earlier class of cases is usually combined with abduction and outward rotation, the attitude of inactivity. Increased flexion, accompanied by adduction and inward rotation in the early stage, is an indication of a more acute phase of the disease. If the attitude is retained for a time it becomes fixed by accommodative changes in the tissues; thus the distortion is not unusual in cases in which the damage to the joint may be very slight, as, for example, when it follows rheumatism or some form of infectious arthritis. But in most instances the attitude is indicative of more advanced disease and of destructive changes within the joint.

Changes in the Contour of the Hip. In the early stage of the disease the changes in contour are caused in great part by the attitude of the limb. If, as is usual, it is flexed, abducted, and rotated outward, the buttock appears somewhat flatter and broader than its fellow. The gluteofemoral fold is lower because of the tilting downward of the pelvis and it is shallower because of the flexion. If the thigh is adducted, the gluteal fold will be elevated and shortened. On the anterior aspect, the inguinofemoral fold is deepened and lengthened by flexion and adduction, while abduction makes it less noticeable. Hoffman has called attention to the fact that the genitals and the intergluteal fold point toward the adducted and away from the abducted thigh. Adduction makes the trochanter more prominent, and abduction makes it less prominent.

To these primary changes in the appearances must be added the effect of atrophy or of infiltration and swelling, due directly to the disease. A certain amount of swelling indicating effusion into the joint is often apparent in the inguinofemoral region, and infiltration of the deeper tissues is sometimes evident on palpation.

In such cases there is usually a certain sensitiveness to deep pressure behind or in front of the trochanter. Palpable or evident abscess is unusual in the early stage of the disease.

Atrophy. Atrophy is an important sign of joint disease. It is often appreciable to the eye and to the hand, and it is always demonstrable by measurement. It is an important symptom, because, if well marked, it shows that the disease must have existed for some time, whatever may be the statement of the patient's relatives.

The atrophy affects the muscles of the entire limb, although it is somewhat more marked in the muscles of the thigh than in the calf. In the ordinary case of hip disease in childhood, when the patient is first brought for treatment, it averages from one-half to one inch in the thigh and somewhat less in the calf. As has been stated elsewhere, atrophy of muscles is usually accompanied by a corresponding atrophy of bone as well.

The Causes of Atrophy. The causes of the atrophy secondary to joint disease have been the subject of much discussion. As it is associated with an increase of the reflex excitability of the muscles, and as it often progresses with great rapidity, the prevailing theory has been that of Vulpian and Charcot, that it is of nervous or reflex origin. According to this hypothesis the atrophy is the result of a change in the trophic centres of the spinal cord, "an inertia," due to irritation of the articular filaments of the nerves.

Another theory has been advanced by Saborin. As branches of the same nerves are distributed to the joint and to the surrounding muscles, he suggests that the atrophy may be caused by a direct implication of the nerves whose filaments are involved in the disease of the joint—a form of molecular neuritis.

Admitting that the secondary causes of atrophy are somewhat obscure, one cause, and by far the most important, is very evident. This is physiological disuse, and thus diminished nutrition of the limb which has become incompetent to carry out its full function. Atrophy is a constant symptom of simple disuse in the absence of disease. If a bone has been broken, atrophy of the surrounding muscles is observed. If anchylosis of a joint occurs from any cause, whether it be from injury or disease, atrophy of the muscles, whose function has been abolished, follows. Even the atrophy caused by disease of the hip-joint is greater when the limb has been fixed in apparatus than when none has been applied, although the treatment has allayed the

pain and has checked the progress of the disease. This point is illustrated by the observations of Brackett,[1] who contrasted the atrophy of hip disease in two groups of patients, in one of which motion had been permitted, while in the other fixation, as complete as possible, had been employed. In the first group the average of atrophy was but 1 per cent. of the volume of the thigh and 0.89 per cent. of that of the leg, as contrasted with 23 per cent. and 17 per cent. in the second class.

It has been stated in objection to this theory, by those who understand disuse as meaning only relief from motion and weight bearing, that atrophy is observed even though the patient be confined to the bed, but under these conditions there would be relative disuse of a limb if motion caused pain or discomfort, in degree proportionate to the intensity of the local disease. Meanwhile a lesser atrophy might be demonstrated in the sound limb that had been deprived of its normal stimulus, just as relative hypertrophy of a limb which has to perform double function is often observed.

The atrophy caused by physiological disuse and diminished nutrition affects all the components of the limb. The skin becomes thinner, the muscles lose in volume, the contractile substance is replaced in part by fat and by fibrous tissue, and the medullary canals of the bones enlarge at the expense of the cortical substance.

In childhood, the period of rapid development, disuse often causes a retardation in growth of the entire extremity. This may be apparent in the foot when it is placed by the side of its fellow, while the diminished growth in the length of the limb may be demonstrated by measurement. Brackett, in a series of cases, found this shortening to be distributed as follows: average loss of the femur 6.6 per cent. and of the tibia 5.4 per cent. of the normal length.

This atrophy, the direct result of the disease and of the long-continued disuse during the period of repair, becomes less noticeable after function is resumed, the degree of final inequality depending upon the severity of the disease, the duration of the treatment, and upon the impairment of function. But even when free motion in the joint is retained, a certain amount of atrophy always persists and the loss in growth is never replaced. If motion is completely abolished the muscles about the joint lose

[1] Transactions American Orthopedic Association, vol. iv.

in bulk in proportion to the disuse of their normal function ; whereas, the bones of the limb which are still used to support the weight retain to a greater degree their normal size and length. Combined with the atrophy of the weak limb there is a relative hypertrophy of the sound leg which is forced to assume more than its share of work.

FIG. 192.

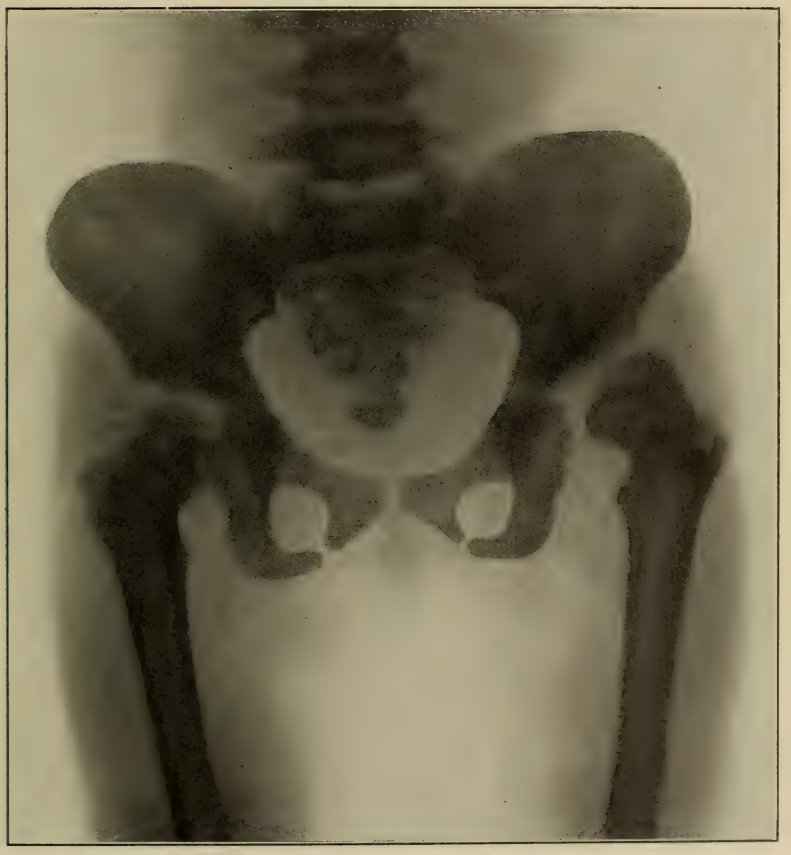

Early stage of disease of the left hip-joint (to the right in the picture) of the synovial type, showing irregularity in the shape of the acetabulum.

ACTUAL SHORTENING. Actual shortening of the limb is a common effect of hip disease, but it can hardly be called a symptom, for it is not present at the onset of the disease.

The causes of actual shortening may be classified as :

1. Disuse of the limb.

2. The effect of the disease upon the epiphysis of the head of the femur.

3. The more general destructive effects of the disease that cause upward displacement of the femur.

(*a*) Erosion of the head.

(*b*) Erosion of the acetabulum.

(*c*) Depression of the neck of the femur.

Disuse, throughout a long period of treatment, may cause a certain amount of shortening of the entire limb. To this the

FIG. 193.

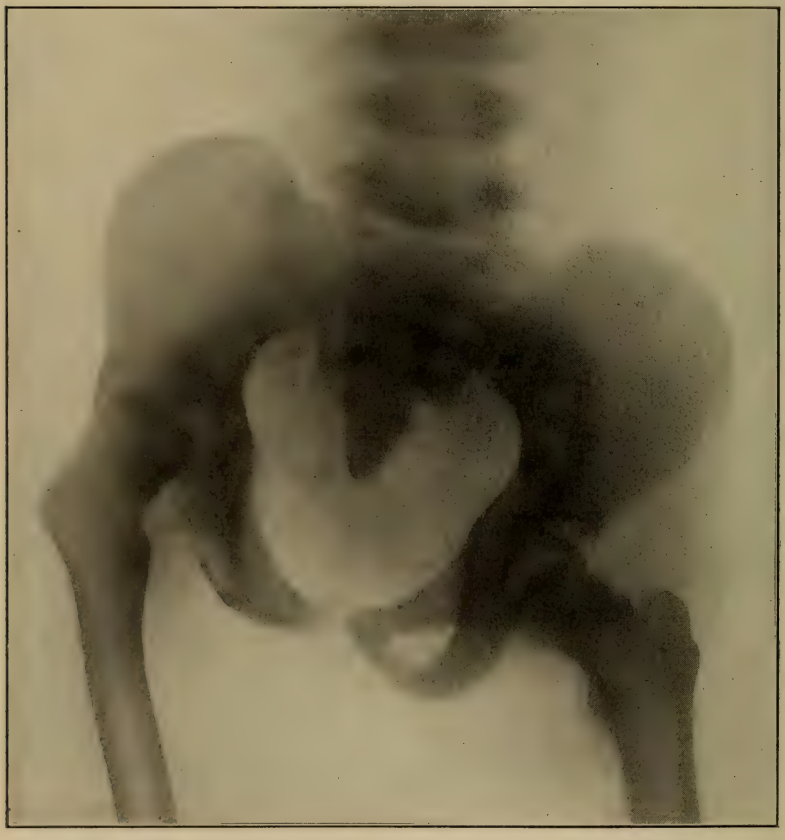

Advanced disease, showing wandering of the acetabulum and the obliquity of the pelvis due to adduction. Actual shortening one inch, apparent shortening three inches.

shortening of the bones of the leg and of the foot may be attributed in great part. If the epiphysis of the head of the femur is destroyed in whole or in part or if the disease hastens its union with the neck a certain loss of growth must follow. This is, of course, slight in degree, because this epiphysis is

relatively unimportant compared with that at the lower extremity of the femur. From these two causes, the atrophy of disuse and the effect of the disease upon the epiphysis, relative shortening of the limb may increase after the disease is cured.

Erosion of the head of the femur and of the upper border of the acetabulum are usually combined in those cases in which the shortening is in part dependent on upward displacement of the trochanter (Fig. 180). Depression of the neck of the femur to an appreciable degree is less common. Elevation of the trochanter, due to one or more of these causes, a form of subluxation, is very common, particularly so in those cases in which the protective treatment has been inefficient. Greater displacement follows fracture of the weakened neck and complete absorption of the head, and occasionally a fairly normal femur may be actually dislocated as a result of sudden effusion into the joint with rupture of the capsule—a form of pathological dislocation.

Retardation of Growth. As has been stated, all the components of the limb are affected by the retardation of the growth. Brackett's observations on this point have been mentioned, and the accompanying table, showing the relative measures of the bones in cases under treatment by Döllinger,[1] of Budapest, presents the subject in a convenient form :

No. of case.	Age at inception.		Duration of disease.		Length of femur in cm.		Difference.	Length of tibia in cm.		Difference.
	Years.	Months	Years.	Months	Diseased.	Normal		Diseased.	Normal	
1	8	6	...	6	28½	28	+½	24	24	...
2	3	4	...	8	23	24	1	19	19	...
3	2	10	1	8	24	24	...	19.5	19.5	...
4	5	...	2	...	29	30	1	23.5	23.5	...
5	6	...	2	...	27	28	1	23	23	...
6	7	...	2	...	32	33	1	27	27	...
7	9	...	2	...	37	37	...	30	30	...
8	1	...	4	...	22	24	2	18.5	19	0.5
9	13	...	4	...	38	41	3	34	34	...
10	4	6	5	...	32	34	2	27	27	...
11	...	2½	6	...	26	27	1	21½	23	1
12	13	...	7	...	38	40	2	33	33	...
13	2	...	8	...	35	36	1	28	28	...
14	6	...	8	...	38	38	...	31	32	...
15	11	...	8	...	40	44	4	34	34	...
16	5	...	10	...	45	46	1	...	...	...
17	5	...	11	...	41	44	3	31	37	6
18	6	...	14	...	44	48	4	36	39.5	3.5
19	2	...	18	...	36	46	10	38	38	...
20	2	...	28	...	44½	45	½	37.5	37.5	...

A similar investigation of thirty-three cases under treatment at the Hospital for Ruptured and Crippled, New York, has been made recently by Taylor. In these cases the shortening of the

[1] Zeits. f. Orth. Chir., 1892, Bd. i.

bones was found to be more generaly distributed than in those reported by Döllinger, as is illustrated by the following table:

Case.	Sex.	Age.	Side.	Duration of disease, years.	Duration of treatment, years.	Abscess	Shortening in inches.				
							Entire limb.	Femur.	Tibia.	Foot.	Patella.
1	F.	3½	Left	1	1	No	½	—	½	⅜	⅛
2	M.	7	Right	1½	1	No	¼	x	¼	⅜	⅛
3	M.	5	Left	2	1	No	⅛	¼	¼	⅛	⅛
4	M.	5	Right	2	1½	No	¾	¼	⅜	⅜	¼
5	M.	6½	Left	2½	1½	Yes	¾	¼	⅜	⅜	¼
6	F.	4½	Left	3	3	No	—	—	—	—	¼
7	F.	6½	Right	3	—	No	½	—	¼	—	—
8	M.	6	Right	3	2½	No	1⅜	¼	¼	¼	⅜
9	F.	13	Left	3½	2	No	¾	—	⅝	⅛	⅛
10	F.	7	Left	3½	3½	No	1⅜	½	¾	⅛	¼
11	M.	7	Right	3½	3½	Yes	1	¼	¾	¾	⅜
12	F.	11	Right	3½	1½	No	1⅜	¼	⅝	¼	⅛
13	F.	9	Left	3½	3½	No	1¼	—	½	½	⅛
Average		7	.....	2½	2	.....	¾	⅛	½	¼	⅛
14	M.	7	Right	4	4	No	1	¾	¼	¾	½
15	F.	8½	Right	4	4	No	1	¼	½	¼	⅜
16	F.	12	Right	5	4	Yes	3¼	½	1¼	⅜	x
17	F.	11	Right	5½	4	Yes	2¼	1	¼	¼	½
18	F.	13	Left	6	3	No	2	½	1⅛	½	¼
19	F.	12	Left	6	4	No	⅞	¾	¾	⅝	⅜
20	F.	10	Left	6½	4	No	1¼	¼	¼	- -	¼
21	M.	14	Left	7	x	Yes	2½	x	¾	¾	¼
22	F.	15	Right	7	5	No	2¼	x	1	½	x
23	M.	9½	Right	7	½	Yes	1¼	—	½	¼	x
Average		11	.....	5½	3½	.....	1¾	½	¾	½	⅜
24	F.	13	Right	8	7	Yes	2¼	¼	1½	1	¼
25	M.	15	Right	9	6	Yes	4½	2	1¾	x	x
26	M.	10½	Right	9	x	No	1½	½	⅛	¼	½
27	F.	18	Right	9	7	No	2¾	x	1	½	¼
28	M.	18	Right	11	10	Yes	2	½	1	⅝	x
29	F.	15	Left	11	7	Yes	3	¼	⅞	¼	⅜
30	F.	15	Right	11	5	Yes	1	¼	¼	½	¼
31	F.	15	Right	11½	9½	Yes	3	¾	¾	½	½
32	F.	16	Left	14	1	No	1½	¾	¾	⅛	½
33	F.	21	Left	17	6	Yes	5½	2½	2½	¾	¼
Average		15	.....	11	6	.....	2¾	⅞	1	½	⅜

— Measurements equal. x Measurements not taken.

Measurements of the femur from the apex of the great trochanter to the knee-joint. Patella measured transversely. The cases are grouped according to the duration of disease and the averages are given separately for each group.

Dr. Taylor measured also ten cases of unilateral poliomyelitis, in patients of an average age of thirteen years, with an average duration of disability of ten years. The average shortening in these cases was one and three-fourths inches, and in no case was it greater than two and one-half inches. It will be noted that the retardation of growth in this group corresponds closely with that of the third group of cases of hip disease, in which the disability was of about the same duration. Taylor concludes that

the retardation of growth from unilateral hip disease in childhood is dependent in great degree upon the duration of the disability and upon the corresponding restraint of function. Similar observations on fifty cases of hip disease have been recorded by Hibbs.[1] In eleven of these cases the femur was found to be slightly longer on the diseased side.

Actual lengthening of the limb as the result of disease is occasionally observed during the active stage of the disease, caused it may be inferred by granulations within the acetabulum that press the femur outward and downward. Actual lengthening of the femur is uncommon, but it does occur, induced, it may be, by stimulation of the growth of the epiphysis of the head; but the most extreme instances are those in which the upper portion of the shaft of the femur is involved, the lengthening being the effect of an irritative hypertrophy. This is more commonly the result of extra-articular disease.

General Symptoms of the Disease. **Debility.** If the disease is sufficiently painful to cause loss of sleep and to affect the appetite, pallor and loss of flesh and strength may be expected. It must be borne in mind, however, that the patient may have been "delicate" long before the local tuberculous disease was acquired. At all events, from the diagnostic standpoint at least, the local disease has no characteristic influence upon the general condition, and the appearance of perfect health is not at all unusual among patients with hip disease.

Fever. It is probable that a slight elevation of temperature might be detected in a large proportion of the patients, and in such cases actual appreciable fever often follows overexertion or injury. Fever, as a symptom of infected abscess in the later course of the disease, is, of course, of importance, but in the early stages of the disease the record of the temperature would be of but little diagnostic value.

The History and the Method of Examination. In considering the differential diagnosis of tuberculous disease of the hip-joint one should keep its characteristics in mind. It is a chronic disease, in that the symptoms may have been present for weeks or months or even years before the patient is brought for treatment. It is a disease confined to a single joint, thus differing from rheumatism and similar affections in which several joints are involved. It does not get well; thus it may be differentiated from injury and from the minor affections that simulate some of

[1] New York Medical Journal, December 16, 1899.

its symptoms. It causes a limp. It is accompanied by reflex muscular spasm, usually by a certain amount of deformity and by general atrophy of the muscles of the limb.

The importance of the inheritance and of the personal history of the patient has been mentioned already in the consideration of Pott's disease. In recording the history in this as in all other chronic diseases of childhood one attempts to ascertain the approximate duration of the pathological process rather than the duration of the more acute symptoms for which the patient has been brought for treatment. One asks, therefore, when the child was last perfectly well, and, bearing in mind the remission of symptoms, one asks if limp or pain had been noticed at any time before the more acute symptoms. In the history there is almost invariably mention of a fall, and one must ascertain whether the fall had any influence in the causation of the symptoms, remembering that the weakness and interference with function due to joint disease more often cause falls than falls cause joint disease.

Physical Examination. One begins the physical examination by the observation of the general condition of the patient, and notes the attitudes, and the character of the limp. The patient's clothing is then entirely removed, that one may observe the contour of the part and the general influence of the affection upon the mechanism of the body. The patient is then placed on his back upon a table, with the limbs parallel to one another, so that their relative length and size may be observed. If the pelvis is level when the limbs are parallel, there can be no persistent abduction or adduction, for when the two anterior superior spines are on the same plane such distortion is always evident. If the lumbar spine and the popliteal surfaces of the knees rest on the table simultaneously it shows, too, that persistent flexion is absent. One next tests the functions of the hip-joints, always beginning with the sound side for the purpose of comparison, and in order that the patient may become accustomed to the manipulation before the one suspected of disease is tested. Disease within a joint is accompanied by muscular spasm that limits motion in every direction, thus differing from other affections outside the joint that may limit its motion in one or more but not in all directions.

One compares the flexion, abduction, adduction, and rotation of the limbs while the child lies upon its back; it is then turned upon its face to test for extension by holding the pelvis flat upon the table with one hand while the thigh is gently elevated with

the other (Fig. 16). The normal range of extension in childhood is at least ten degrees backward from the line of the body, and limitation of this range is the earliest sign of approaching deformity of hip disease. It may precede the restriction of the extremes of motion in other directions, although this is unusual, and if this motion is unrestricted disease of the joint may be, practically speaking, excluded. The character of the reflex spasm that limits motion and the indications of discomfort when the limit has been reached have been described.

Measurements. The measurements of the limbs are then made. One first ascertains the actual length of the limbs by measuring from the anterior superior spines of the pelvis to the extremities of the internal malleoli, actual shortening being, of course, absent in the early stage of the disease. The second measurement is from the umbilicus to show the amount of apparent shortening or lengthening that may be present if the limb is distorted. The actual length of the limbs, as measured from the anterior superior spines, is not changed by tilting of the pelvis, but as the umbilicus is in the middle line of the body above the pelvis, measurement from this point simply shows the actual distance to the malleoli. Persistent adduction causes compensatory obliquity of the pelvis ; consequently the malleolus on the affected side is drawn upward or nearer to the umbilicus, while the other is carried downward to a corresponding distance (Fig. 191). If, then, the measurements from the umbilicus to the malleoli do not correspond relatively with those from the anterior superior spines, when the limbs are parallel and in the median line, it shows distortion ; adduction, if the limb is relatively shorter, abduction, if it is relatively longer than is shown by the measurement from the anterior superior spine. It has been stated that the measurement from the anterior superior spine is not changed by distortion. It is, however, shortened slightly by outward rotation, and more appreciably by abduction, and it is lengthened somewhat by adduction. This is explained as follows : When the limb is in the line of the body the trochanter is below the anterior superior spine from which the measurement is made. Abduction of the limb raises the trochanter toward the plane of the anterior superior spine, and consequently lessens the distance from this point to the extremity of the limb. Adduction, on the contrary, lowers the trochanter and increases the distance between these two points. In ordinary cases the variation from this source does not exceed half an inch. Flexion of one thigh causes a tilt-

ing forward of the pelvis that lessens the distance between the anterior superior spine and the malleolus on both sides, although not to an equal degree. It is customary, therefore, if the flexion is considerable, to raise the unaffected limb to the line of its fellow in making the comparative measurements, stating in the record that the limbs have been measured at the angle of the deformity.

Method of Estimating the Degree of Distortion of the Limb. As has been stated, when the pelvis is level, distortion of the limb is apparent, and the degree of distortion can be measured by the goniometer (Fig. 187); but it may be more easily ascertained by "Lovett's table."[1] This method is described by its author as follows:

Table I.—Distance between Anterior Superior Spines in Inches.

Difference in inches between real and apparent shortening.	3	3½	4	4½	5	5½	6	6½	7	7½	8	8½	9	9½	10	11	12	13
¼	5°	4°	4°	3°	3°	2°	2°	2°	2°	2°	2°	2°	2°	1°	1°	1°	1°	1°
½	10	8	7	6	5	5	4	4	4	4	4	4	4	3	3	3	3	2
¾	14	12	11	10	8	8	7	7	6	6	5	5	5	4	4	4	3	3
1	19	17	14	13	11	10	9	9	8	7	7	7	6	6	6	5	5	4
1¼	25	21	18	16	14	13	12	11	10	9	9	8	8	7	7	7	6	6
1½	30	25	22	19	17	15	14	13	12	12	11	10	10	9	9	8	7	7
1¾	36	30	26	23	20	18	17	15	14	13	13	12	11	10	10	9	8	8
2	42	35	30	26	23	21	19	18	16	15	14	14	13	12	12	10	10	9
2¼	...	40	34	30	26	24	21	20	19	17	16	15	14	14	13	12	11	10
2½	...	...	39	34	29	27	24	22	21	19	18	17	16	15	14	13	12	11
2¾	...	...	...	38	32	29	27	25	23	21	20	19	18	17	16	14	13	12
3	...	...	...	42	35	32	29	27	25	23	22	21	19	18	18	16	14	12
3¼	...	...	...	...	39	36	32	30	27	26	25	22	21	20	19	17	15	14
3½	...	...	...	...	...	40	35	33	30	28	26	24	23	22	21	19	17	16
3¾	...	...	...	...	...	...	38	35	32	30	28	26	25	23	22	20	18	17
4	...	...	...	...	...	...	42	38	35	32	30	28	26	25	23	21	19	18

"To measure by this method the patient is made to lie straight with the legs parallel. Real shortening is measured with the ordinary tape measure, and apparent shortening is obtained in the same way. It may be repeated that real or bony shortening is measured from the anterior superior iliac spines to each malleolus, and that practical shortening is found by a measurement taken from the umbilicus to each malleolus. The difference in inches between the two kinds of shortening is seen at a glance.

[1] R. W. Lovett. Boston Medical and Surgical Journal, March 8, 1888.

The only additional measurement necessary is the distance between the anterior superior spines, which is taken with the tape. Turning now to the table: if the line which represents the amount of difference in inches between the real and apparent shortening is followed until it intersects the line which represents the pelvic breadth, the angle of deformity will be found in degrees where they meet. *If the practical shortening is greater than the real shortening, the diseased leg is adducted; if less than real shortening, it is abducted.* Take an example: Length (from anterior superior spine) of right leg, 23; left leg, $22\frac{1}{2}$; length (from umbilicus) of right leg, 25; left leg, 23; real shortening, $\frac{1}{2}$ inch; apparent shortening, 2 inches; difference between real and practical shortening, $1\frac{1}{2}$ inches; pelvic measurement, 7 inches. If we follow the line for $1\frac{1}{2}$ inches until it

FIG. 194.

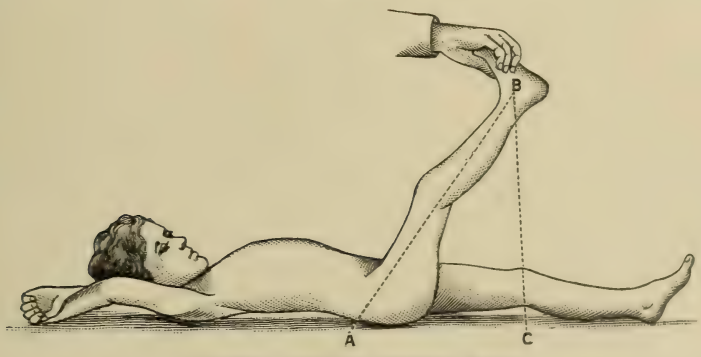

Kingsley's method of estimating flexion.

intersects the line for pelvic breadth of 7 inches, we find 12° to be the angular deformity, as the practical shortening is greater than the real, it is 12° of adduction of the left leg. If apparent lengthening is present its amount should be added to the amount of actual shortening."

If flexion is present the degree may be ascertained by raising the flexed limb until the lumbar spine touches the table, when the angle formed by the thigh with the body may be measured with the goniometer (Fig. 186), or its degree may be ascertained by Kingsley's table.

"The patient lies upon a table flat on his back and the surgeon flexes the diseased leg, raising it by the foot until the lumbar vertebræ touch the table, showing that the pelvis is in the correct position. The leg is then held for a minute at that angle, the

knee being extended, while the surgeon measures off two feet on the outside of the leg with a tape measure, one end of which is held on the table (so that the tape measure follows the line of the leg) (*A B*). From this point on the leg (*B*) where the two feet reaches by the tape measure one measures perpendicularly to the table (*B C*), and the number of inches in the line *B C* can be read as degrees of flexion of the thigh by consulting Table II. For instance, if the distance between the point on the leg and the table is 12½ inches it represents 31° of flexion deformity of the thigh.

TABLE II.[1]

0.5 inches.	1°	6.5 inches.	16°	12.5 inches.	31°	18.5 inches.	50°
1.0 "	2	7.0 "	17	13.0 "	33	19.0 "	52
1.5 "	3	7.5 "	19	13.5 "	34	19.5 "	54
2.0 "	4	8.0 "	20	14.0 "	36	20.0 "	56
2.5 "	6	8.5 "	21	14.5 "	37	20.5 "	58
3.0 "	7	9.0 "	22	15.0 "	39	21.0 "	60
3.5 "	9	9.5 "	24	15.5 "	40	21.5 "	63
4.0 "	10	10.0 "	25	16.0 "	42	22.0 "	67
4.5 "	11	10.5 "	27	16.5 "	43	22.5 "	70
5.0 "	12	11.0 "	28	17.0 "	45	23.0 "	75
5.5 "	14	11.5 "	29	17.5 "	47	23.5 "	80
6.0 "	15	12.0 "	30	18.0 "	48	24.0 "	90

"If the leg is so short that it is impracticable to measure off twenty-four inches one can measure twelve inches; ascertain from here the distance to the surface on which the patient is lying in a perpendicular line in the same way, then doubling this distance and looking in the table as before the amount of flexion is found."

ATROPHY. The circumference of the thighs, the knees, and the calves is then measured at corresponding points to test for atrophy or for other irregularities that may require explanation. The atrophy of joint disease affects the entire limb, and it is an unfailing symptom except in the earliest stage of the disease. It might be concealed in the thigh by a deep abscess, but it would still appear in the calf.

Local Signs of Disease. The hip-joint is so concealed by the overlying tissues that the local sensitiveness and swelling which usually accompany similar disease at the knee and ankle are often absent. Firm pressure, before or behind the trochanter, or over the head of the femur usually causes some discomfort, however. In many instances a peculiar resistance of the deeper parts, caused by infiltration of the tissues that cover the joint, is evident on palpation; and swelling about the joint and thigh, caused by

[1] G. L. Kingsley. Boston Medical and Surgical Journal, July 5, 1888.

effusion or by deep abscess, is not unusual when patients are first brought for treatment. Sensitiveness of the skin and local elevation of the temperature may be present if the disease is acute, particularly if an abscess is on the point of breaking through the skin.

The diagnosis of tuberculous disease of the hip, except, perhaps, in the stage of inception, is in most instances evident on a systematic examination, such as has been outlined, and it is probable that errors are due rather to a neglect of such examination than to any particular obscurity that the ordinary case may offer.

Diagnosis. **Local Irritation.** Strains of the muscles of the thigh, enlarged glands in the groin, irritation or disease of the genitals may, in infancy or early childhood, cause persistent flexion of the thigh and pain on motion. Simple muscular strains quickly recover, while the inflamed glands and other causes of local irritation are usually apparent on inspection.

"Growing Pains." So-called growing pain is probably due in many instances to strain of the muscles or to injury about the hip; in other cases it may be explained by rheumatism.

Local Injury. It would appear that injury, often of a trivial character, may cause congestion in the neighborhood of the epiphyseal cartilage of the head of the femur and that injury of this character in delicate children may be the predisposing cause of tuberculous disease. Such a sensitive condition causes a limp, pain, or discomfort on overuse and restriction of motion. These symptoms may last a few days or a few weeks; they may disappear and recur from time to time, and they can only be distinguished from those of incipient disease by continued observation.

Synovitis. In certain cases of injury synovial effusion may be present, although this is unusual.

In the cases in which the functional disturbance is caused by local irritation or by slight strain the symptoms are of sudden onset and are evidently of trivial importance, but if there is any doubt as to the diagnosis the hip should be bandaged and the patient should remain in bed or at rest until the complete subsidence of the symptoms or their persistence makes the diagnosis clear.

Anterior Poliomyelitis. Occasionally anterior poliomyelitis may be accompanied by pain on motion in the affected limb before paralysis is apparent, but in a few days at most the diagnosis is evident.

Rheumatism. Rheumatism is usually of sudden onset. It is almost always migratory in character and it is accompanied by fever. If it were confined to a single joint, as is sometimes the case in young children, and if the history were obscure, the diagnosis might be uncertain for a time. In such cases appropriate remedies should, of course, be employed.

Scurvy. This is also an affection whose symptoms are general in character. It is, therefore, more likely to be confounded with rheumatism than with a local disease. In rare instances one joint only appears to be involved, but this is, as a rule, the knee rather than the hip. Pain on motion of the limbs, in an infant artificially fed, always suggests scurvy.

Infectious Arthritis and Epiphysitis. Mild forms of infectious arthritis may follow scarlet fever, diphtheria, pneumonia, and, in a more severe and destructive form, typhoid fever. As a rule, however, several joints are involved, and, although the affection might be mistaken for rheumatism, it could hardly be confounded with local tuberculous disease.

Infectious arthritis or epiphysitis of the hip-joint is not uncommon in early infancy. It is of sudden onset, accompanied by high fever and by constitutiona disturbance. These symptoms, together with the local heat and swelling, caused by the rapid formation of pus, show the character of the affection and indicate the necessity for prompt surgical intervention.

Gonorrhœal arthritis is a form of joint infection that in adult age may resemble somewhat the subacute form of tuberculous disease. As a rule, however, it is of sudden onset and is evidently associated with the local disease.

Extra-articular Disease. Disease in the neighborhood of the joint, as of the trochanter or of the tuberosity of the ischium, may cause a limp and pain ; in most instances the local sensitiveness and local swelling indicate the seat of the disease, while motion of the joint is limited only in the directions that cause tension on the sensitive parts.

Osteoarthritis of the Hip. Osteoarthritis at the hip-joint may be mistaken for tuberculous disease, and at times the diagnosis may be obscure. This is, however, a disease of adult life, and it is in most instances accompanied by other evidences of a general affection. The general form of rheumatoid arthritis in childhood may begin in a single joint. The pain may be severe, and there may be muscular spasm and distortion of the limb. The diagnosis is usually made clear by the successive involvement of other joints.

Pott's Disease. Disease of the lumbar region of the spine before the stage of deformity, when the pain is referred to the lower extremities, and in which unilateral psoas contraction causes a limp, is often mistaken for hip disease, although the distinction between them is very clear. Psoas contraction limits extension only; all the other movements of the limb are unrestrained. The muscular spasm, of which the psoas contraction is a part, is a spasm of the muscles of the spine about the seat of disease, as is evident on examination. Other causes of psoas contraction have been mentioned in the consideration of Pott's disease. In exceptional cases active disease of the lower region of the spine in young children may set up spasm of the muscles about the hip, and *vice versa*, so that it may be impossible to decide at the first examination whether the irritation is in the hip or in the spine or in both.

Sacro-iliac Disease. Disease of the sacro-iliac junction is very uncommon in childhood. The symptoms and the attitude resemble sciatica rather than hip disease. There is local pain at the seat of disease upon lateral pressure on the pelvis, and if the pelvis be fixed the motion at the hip-joint will be found to be free and painless.

Disease of the Bursæ about the Joint. Inflammation of the bursæ about the hip may cause local swelling and sensitiveness, a limp and limitation of motion in certain directions, but the characteristic muscular spasm of hip disease is absent. Iliopsoas bursitis forms a fluctuating swelling in Scarpa's space, gluteal bursitis a localized swelling of the buttock.

Coxa Vara. Depression of the neck of the femur is a simple deformity in which disease is absent. It causes a limp and more or less discomfort, but the character of the deformity, shown by the actual shortening and by the elevation and prominence of the trochanter distinguishes it from hip disease, in which these are late symptoms. In coxa vara there is unequal limitation of motion, abduction, flexion, and inward rotation being somewhat restricted, while extension, the first motion limited in hip disease, is as a rule not affected.

Fracture of the Neck of the Femur in Childhood or Traumatic Coxa Vara. Fracture of the neck of the femur in childhood is often of what may be termed the green-stick variety, a depression of the neck of the femur without actual separation of the fragments; and in many instances the patients are able to walk about within a short time after the accident. In such cases the limp

and discomfort, attended during the stage of repair by a certain degree of muscular spasm, are often mistaken for the symptoms of disease. The history of the accident followed by immediate disability, the shortening and the elevation of the trochanter are usually sufficient to exclude disease. In doubtful cases the X-ray may be required to establish the diagnosis.

Congenital Dislocation of the Hip. Congenital dislocation of the hip causes a limp, but it is a limp that has existed since the child began to walk and that is unaccompanied by the symptoms of disease. The nature of the disability should be apparent on examination.

Hysterical Joint. In hysterical subjects a limp, apparent pain, and distortion of the limb, often following slight injury, may simulate disease. Hysteria is very uncommon at the period of life in which tuberculous disease is most frequent. Patients suffering from hysterical joints usually present other symptoms of hysteria; the characteristic signs of disease, muscular spasm and atrophy, are absent, while the apparent discomfort and the voluntary distortion are quite out of proportion to the physical evidences of injury.

The X-ray in Diagnosis. Roentgen pictures are of far more value in demonstrating deformity than in establishing early diagnosis of disease, especially at the hip in early childhood, when so large a part of the extremity of the femur is cartilaginous. The pictures are of value, however, in showing the destructive effect of the disease on the head of the femur or acetabulum, and thus giving one a clearer conception of the actual condition of the joint than would be possible otherwise (Fig. 192). In older subjects it may be possible to demonstrate the presence of disease in the interior of the bone by this means, but in any event Roentgen pictures are of value only when interpreted by knowledge of the physical signs.

Method of Recording a Case. The record should contain the general history of the patient together with an account of the more important symptoms, and of the treatment that may have been employed. The physical examination should include the weight and height for comparison with the normal standard, and as a basis on which to judge the future progress of the case. Then follows a brief description of the gait and attitude, of the character of the distortion, if it be present, and of the changes from the normal contour. If restriction of motion is present, its causes are stated if possible; whether, for example, it is due

to simple muscular spasm or in part to adhesions and contractions.

The presence or absence of heat and swelling, of abscesses, sinuses, and the like is indicated. If there is actual shortening of the limb its causes and distribution should be stated; whether it is the result of simple retardation of growth or of elevation of the trochanter, as may be ascertained by Nélaton's line and by Bryant's triangle.

If the elevation is due in great part to the enlargement of the acetabulum, while the upper extremity of the femur remains fairly normal in shape, the projection of the trochanter is more noticeable, and the distortion of the limb in adduction is greater, than when the elevation is the result of destruction of the head of the bone. In this class of cases Roentgen pictures are of service in showing the actual condition of the joint (Fig. 193).

A condensed account of the more important points in the physical examination may be presented by the formula used at the Hospital for Ruptured and Crippled, as follows: R.A.—R.U.—R.T.—R.K.—R.C.—A.G.E.—A.G.F.—A.S.P.—L.A.—L.U.—L.T.—L.K.—L.C.

"A" indicates the distance from the anterior superior spines to the internal malleoli.

"U," from the umbilicus to the same points.

"T," "K," and "C," the circumferences of the limb at the thighs, knees, and calves.

"A.G.E." indicates the angle of greatest extension.

"A.G.F.," the angle of greatest flexion. Thus the restriction of the range of anteroposterior motion at the hip is shown by these measurements.

"A.S.P." is the transverse diameter of the pelvis between the anterior superior spines, the measurement required in Lovett's table for ascertaining the degree of lateral distortion.

If, for example, the record read:

R.A. 18½—R.U. 20 —R.T.11 —R.K. 8¾—R.C. 7¾—A.G.E. 150—A.S.P. 7
L.A. 18½—L.U. 21¼—L.T.10¼—L.K. 8¼—L.C. 7¼—A.G.F. 90

it would show at a glance that there was no real shortening, that the limb was abducted because there is one and a quarter inches of apparent lengthening, according to the table, the equivalent of 10 degrees of abduction. It would show that there was permanent flexion of 30 degrees and a range of motion between

the limits of flexion and extension of 60 degrees, as compared with the normal of about 130 degrees.

The following details of the one thousand cases of hip disease investigated for me by Ashley are of interest as illustrating the character of the cases treated at the Hospital for Ruptured and Crippled:

The Duration of Disease when Treatment was Begun.

Three months or less	396	Four years	21
Three to six months	170	Five years	17
Six months to one year	80	From five to ten years	35
One year	124	From ten to forty years	16
Two years	75	Not stated	37
Three years	29		1000

The Degree of Deformity Present on First Examination.

No deformity	130	55 degrees of flexion	10
5 degrees of flexion	44	60 " " "	26
10 " " "	89	65 " " "	8
15 " " "	69	70 " " "	22
20 " " "	118	75 " " "	2
25 " " "	32	80 " " "	11
30 " " "	135	85 " " "	1
35 " " "	56	90 " " "	12
40 " " "	70	More than 90	1
45 " " "	41	Not stated	55
50 " " "	68		1000

Restriction of Motion at First Examination.

Normal motion	30
A range of motion through 105 degrees	14
" " " 90 "	65
" " " 75 "	49
" " " 60 "	95
" " " 45 "	67
" " " 30 "	112
" " " 15 "	95
" " " 5 "	157
No motion	147
Not stated	169
	1000

Attitude of the Limb at First Examination.

Flexion to a greater or less degree	814
No flexion	130
Not stated	56
	1000

Other Distortions Recorded.

Abduction	254
Adduction	167
External rotation	166
Internal "	58

ACTUAL SHORTENING WHEN TREATMENT WAS BEGUN.

¼ inch	129	2¼ inches	5
½ "	143	2½ "	5
¾ "	22	2¾ "	2
1 "	51	3 "	2
1¼ inches	9	3¼ "	2
1½ "	16	3½ "	2
1¾ "	6	9½ "	1
2 "	21		416

Shortening absent or not stated in	584
Abscess was present in	105

Treatment. The principles that should govern the treatment of a disease are best indicated by the study of cases that have received no treatment, and that show, therefore, the natural history of the affection.

A characteristic case of tuberculous disease of the hip-joint begins insidiously. It causes a slight limp and at times discomfort and pain. In the early stage of the disease there is slight flexion of the limb, usually combined with abduction, the instinctive assumption of the attitude of rest. As the disease progresses the limb becomes less capable of performing its proper function; the range of painless motion becomes more and more restricted, and the attitude changes to one of increased flexion and adduction, the attitude in which the limb is best protected from injury and in which it is least capable of performing its share of normal work. Pain is more constant, abscess is often present, and the constitutional effects of a depressing disease may be apparent. This progression of symptoms and attitudes is so fairly constant that hip disease was in former times often divided into stages corresponding to these early and later manifestations of its effects. When the limb has reached the position of greatest protection, when motion which at first was limited only by the involuntary spasm of the muscles that are now atrophied, is restricted by adhesions and contractions, pain often ceases to be a troublesome symptom, the general health improves, and effective repair begins. During the progressive stage erosion of the opposing surfaces of the joint has advanced, always more rapidly at the points of mutual pressure and friction, the upper and inner surface of the head of the femur and the upper margin of the acetabulum, and here the disease remains active while repair progresses at the points which have been relieved from irritation. Thus in many instances the upper margin of the acetabulum is destroyed and a subluxation of the femur takes place (Fig. 181), a displacement favored by

the attitude of flexion and adduction, and induced by muscular spasm and by pressure upon the limb. In some instances there is complete displacement, and when the diseased parts are thus separated from one another by this form of pathological dislocation relief of symptoms and practical recovery may quickly follow, although sinuses leading to areas of local disease or to fragments of necrosed bone may persist for many years.

Nature's cure of hip disease implies recovery with a shortened and distorted limb, a final result which is common enough even when treatment has been employed to explain the popular conception of what hip disease entails (Fig. 190).

As has been stated, it was customary in former years, when treatment was neglected or less efficient than at the present time, to speak of a first, second, and third stage of hip disease, corresponding to the character of the deformity, but early or later stage as used by the writer refers to the inception and progression of the local pathological process, not to the distortion of the limb.

There are many cases of hip disease in which the primary focus in the head of the bone is so limited in extent that perfect functional cure may result under any form of treatment, or non-treatment even. And there are others in which the disease is of such a destructive character that the result must be disastrous in spite of treatment. But there can be no doubt that by early diagnosis and by efficient protection a vast amount of suffering may be prevented, that useful function may be preserved, which would otherwise have been lost.

The object of treatment is to prevent the symptoms and the effects of the disease that have been outlined as characteristic of the untreated cases. To relieve the pain that depresses the vitality of the patient. To relieve the muscular spasm that induces distortion of the limb, and that stimulates the activity of the destructive process by increasing the pressure and friction of the diseased surfaces of the opposing bones. To correct and to prevent deformity and to prevent, as far as may be by lessening the pressure and by restraining motion, the upward displacement of the femur that causes irremediable distortion.

There are cases in which radical removal of the diseased parts may be indicated, and there are times when acute symptoms may require absolute rest of the patient. But in the management of a chronic tuberculous disease, throughout the period of years that may elapse before cure is accomplished, the primary requirements of the treatment that have been indicated must be met, as

far as may be, by appliances that allow exercise in the open air.

Mechanical Treatment. The most effective treatment of a diseased joint is that which assures it the most perfect rest and protection. If the disease is in the earliest stage and confined to the interior of the bone, rest offers the most favorable condition for repair and for preservation of the joint. If the disease is further advanced, complete relief of function affords an opportunity for nature to check its progress and to preserve, it may be, a part of the joint from invasion. If the joint is already involved, rest offers the best opportunity for repair by preventing friction that stimulates the progress of the disease and increases its destructive effects. Whatever checks or retards the progress of the disease correspondingly relieves its symptoms and prevents constitutional depression and thus preserves the vital resistance, both local and general, upon which the cure of the disease ultimately depends. Rest of a diseased joint of the lower extremity necessitates splinting, stilting, and traction.

Splinting naturally signifies the fixation that may be attained by the application of a splint, extending a sufficient distance on either side of the part to be fixed.

Stilting—the elevation of the foot from the ground so that jar and pressure on the diseased articulation may be removed.

Traction—a sufficient force exerted upon the limb to overcome and to control the spasmodic action of the muscles.

The knee-joint, the junction of two levers of similar size and function, may be easily controlled or placed at rest by means of apparatus. But the hip-joint is a ball-and-socket joint which allows free motion in many directions, and, being the junction of the body and the limb, two segments of different size and function, it is especially difficult to control. For this reason as much as any other, perhaps, the treatment of hip disease has been the subject of controversy for many years. And even at the present time one can hardly describe the treatment of hip disease adequately without contrasting the methods of treatment that are in common use.

Such an exposition should begin naturally with a description of what has long been known as the American treatment, in which traction has always occupied the most important place.

The Traction Hip Splint. The traction hip splint consists of a pelvic band and an upright. The pelvic band is made of sheet steel about an eighth of an inch in thickness and one and one-

eighth inches in width, sufficiently strong to support the weight of the body without yielding, bent into a U-shape to conform to the pelvis, but wide enough to cause no anteroposterior pressure. As Taylor puts it, there should be room enough for the pelvis to move freely in it. This band embraces about three-quarters of the pelvis at a point just above the trochanter. It is covered with leather, and is provided with a strap to complete the circumference. Upon the pelvic band four buckles are placed for the attachment of the perineal bands. The two buckles on the

FIG. 195. FIG. 196. FIG. 197.

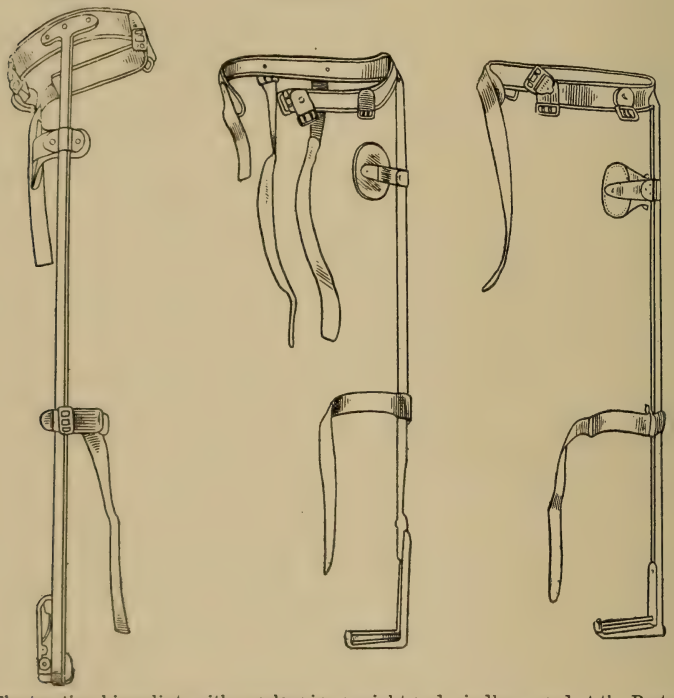

The traction hip splint, with overlapping upright and windlass, used at the Boston Children's Hospital. (Bradford and Lovett.)

front band are placed directly above the attachments of the adductor muscles, on either side of the genitals. Behind, the buckles are placed much farther apart, somewhat to the outer side of each ischial tuberosity, upon which, in great part, the weight of the body is to be supported. The pelvic band is bolted firmly to the upright at a slight inclination, corresponding to the inclination of the pelvis. The upright extends from the top of the trochanter to two or more inches below the sole of the foot. It may be made in one piece or in two sections over-

lapped and attached to one another by screws, to allow for adjustment (Fig. 196). It is turned inward at a right angle below the foot and is shod with leather or rubber. The foot-piece may be provided with a windlass (Fig. 195), or the traction may be made by simple straps attached on either side (Fig. 201). At about the middle of the upright is placed a support of light steel, which is provided with a broad leather strap for the purpose of fixing the thigh to the brace and supporting the knee. In some braces a second similar support is placed at the upper part of the stem; in others the knee is supported only by a broad leather pad which covers its inner surface and is attached to a cross-piece on the upright by straps, as in the Taylor brace. In the Taylor brace, which has served as a model for all similar appliances, the upright is a steel tube into which slides a rod, supporting the foot part of the brace, the two parts being joined with a rack-and-pinion attachment and lock, so that the brace may be lengthened or shortened by means of a key (Fig. 200).

Traction Straps. Traction upon the limb is made by adhesive plaster, preferably that known as moleskin (yellow) plaster, which is far less irritating to the skin than rubber plaster.

These plasters should be cut into a shape corresponding to the lateral aspect of the thigh and leg, thus: wide above and narrow below, reaching from the trochanter on the outer, and from the pubes on the inner side, to the malleoli (Fig. 221). The lower ends are reinforced by a second layer of plaster and to them buckles are attached. The plasters are then applied to the limb and are held in place by a bandage which is smoothly applied and then sewed, to prevent disarrangement. The object of the bandage is primarily to assure the adhesion of the plaster and secondarily to keep it clean. It can be replaced by a properly fitted covering of stockinette or by a stocking leg.

Another method of applying the plaster, designed to obtain a better hold upon the limb, is that devised by Taylor, and described by him as follows: "The first important object is to seize the leg in such a manner as to exert against it an unyielding force. This should be done in such a manner as will not interfere with the circulation, nor injure the knee, by unequal strain either below or above it. In other words, the whole leg should be grasped in such a manner that the knee will be supported. It may be done as follows: A strip of adhesive plaster, long enough to reach from the waist to the foot, and from three to five inches wide at the upper and about one-third

that width at the lower end, is taken and cut into five tails, as shown in the accompanying illustration (Fig. 198). A piece from four to six inches long is cut from the centre tail and added to the lower end to strengthen it; and, if the patient be strong, one or two more pieces are laid on the same place, where a buckle is attached. Two similar straps are prepared, one for the inside and one for the outside of the leg, and laid against the lateral

FIG. 198.



FIG. 199.

C. F. Taylor's method of applying adhesive plaster.

aspects of the leg, the ends with the buckles beginning about two inches above the internal and external malleoli, and the centre tails reaching the entire length of the leg and thigh, to the perineum inside and the trochanter on the outside. The lower strips or tails are then wound spirally around the leg to the pelvis and afterward the other two pairs of tails, which are cut down to just above the knee, are also wound about the thigh in the same manner. When completed the thigh is involved in a network of

strips of adhesive plaster, which act equally and without pressure on the whole surface. The leg has about one-fourth of the attachments, and the thigh three-fourths, which is found to be the right proportion to protect the knee equally from compression or strain. A few turns of the roller bandage are then made around the ankle just under the lower ends of the straps, which serves as a protection to the flesh under the buckles, and then it is continued over the straps on the whole leg. Thus prepared, the patient is ready for the splint" (Fig. 199).

FIG. 200.



The original traction hip brace provided with an abduction screw and a strap to regulate the inclination of the pelvic band on the upright.

At the Boston Children's Hospital the lower ends of the adhesive straps terminate in tapes that extend below the foot for attachment to the windlass, which is used with the cheaper form of brace.

Perineal Bands. Perineal bands are made by covering a firm, wide, unyielding band of webbing with several folds of blanket or similar material and then binding it smoothly with canton flannel. These are made in different lengths and sizes, as may be required.

The "High Shoe." The best and lightest material for raising the shoe worn on the sound foot to correspond with the brace is cork, and the ordinary thickness is two and a half inches. A good and cheap substitute may be made of light wood provided with a leather sole, and in certain cases a patten of metal may be used.

The Application of the Traction Hip Splint. The traction brace is applied in the following manner:

The patient lying upon his back, the pelvic band is first adjusted and is strapped about the body. The perineal supports are then drawn firmly into place so that pressure on the upright does not move the pelvic band from its proper position just above the trochanter. The brace is then pushed upward against the resistance of the perineal bands, while the limb is at the same

time drawn downward and is fixed by attaching the straps to the buckles at the ends of the adhesive plasters. If the brace is provided with a windlass or ratchet, further traction is applied to the point of tolerance by means of the key, care being taken in adjusting the brace that it does not project so far below the foot as to more than equal the extra length provided by the high

Fig. 201.

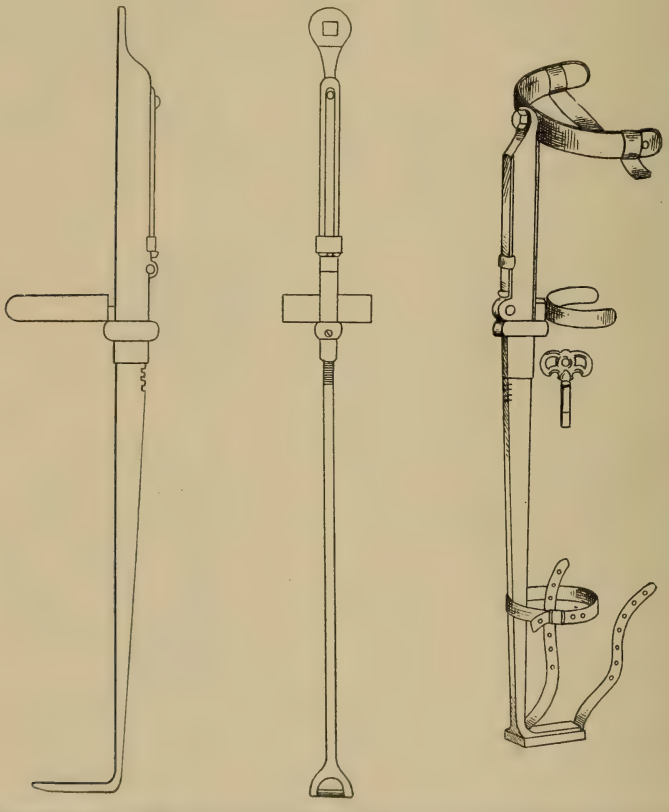

The Judson brace. This has but one perineal band, and the upright is bolted firmly to the pelvic band.

shoe on the sound side. The knee band is then adjusted and in many instances a strap is placed about the ankle and the brace to assure greater security. The shoe is then put on, the leg clothing is drawn over the brace, and the patient is allowed to stand. If in walking the patient is inclined to tilt the foot downward and to bear the weight on the toe, a strap is attached to the middle of the foot-piece and fastened to a buckle on the heel of

the shoe with sufficient tension to hold the foot in the horizontal position.

By means of this brace the weight is borne entirely upon the perineal bands; thus the joint is relieved from pressure and from jar. The perineal bands should be accurately adjusted to pass upward in front, parallel to one another on either side of the genitals, in order to avoid pressure on the inner borders of the thighs; while behind they turn diagonally outward in order to pass over the tuberosities, which are best adapted for weight bearing.

In the original Taylor hip brace the pelvic band is bolted to the upright in a manner to allow anteroposterior motion, and the inclination of the pelvic band is regulated by a strap attached to the upright for better adjustment (Fig. 200), when the limb

FIG. 202.

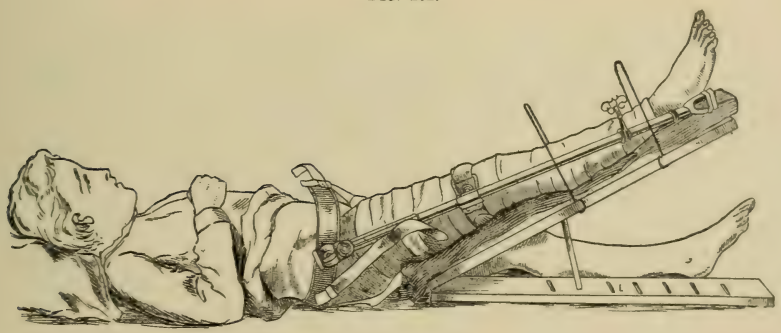

The reduction of flexion by means of the traction hip splint. (C. F. Taylor.)

is flexed to a marked degree. This brace has been modified by Taylor by shortening and changing the shape of the pelvic band for the use of but one perineal support (Fig. 231); and a similar form of brace is used by Judson. The shortened pelvic band lessens the restraint of the brace upon the motion of the limb, and seems to offer little compensating advantage.

Before the traction brace is used in ambulatory treatment, distortion of the limb, if it be present, should be reduced; or if the disease be particularly acute preliminary rest in bed until the subsidence of the symptoms is advisable.

The Reduction of Deformity by Means of the Traction Brace. The patient lies in bed upon a firm mattress; the distorted limb is then raised to slightly more than a sufficient angle to relax the contracted muscles and to straighten the lumbar lordosis; it is then abducted or adducted if necessary until the level of the

pelvis is restored. The pelvic band is made to conform to this greater relative inclination of the pelvis by lengthening the posterior strap; the brace is then applied, the limb being held in the attitude of deformity by a sling or support (Fig. 202), and as much traction as the patient can tolerate is exerted by lengthening the upright. The direct traction exerted by the brace may be reinforced by means of a cord running over a pulley at the foot of the bed, in the line of the brace, to which a weight of ten or more pounds (Fig. 203) is attached. Thus the pressure of the perineal bands is somewhat lessened. Efficient traction will quickly reduce recent deformity caused by muscular contraction, and as this is lessened the position of the limb is correspondingly changed until it lies extended and parallel with its fellow. If adduction be combined with flexion the perineal band on the side opposite to the disease is tightened from time to time, or a direct push against the opposite adductor region is exerted by means of a bar attached to the brace opposite the knee (Fig. 227). In ordinary cases the deformity may be reduced by this means in from two to six weeks.

The brace should be worn day and night. The perineal bands may be loosened at times to allow for bathing the skin with alcohol and for powdering, in order that the skin may be kept dry; but at such times, if the disease be acute, manual traction should be made until the brace has been readjusted. The adhesive plasters, if of moleskin, may often remain in position for three months or longer. When they are removed the limb is gently bathed with alcohol. Excoriations are unusual unless rubber plaster is used. If the skin is abraded the part should be powdered with boracic acid and protected from the plaster by a layer of gauze.

The Relative Efficiency of the Traction Hip Splint. In analyzing the action of this brace it is evident at once that it is thoroughly effective as a stilt. It is effective as a traction appliance, in the sense of relieving muscular tension, in direct proportion to the care that is exercised in its adjustment. Traction by this appliance may be made constant and effective, even to the point of practical fixation while the patient is in bed, or when crutches are used, in ambulatory treatment. But when the apparatus is used as a walking brace, as was designed by its inventor, constant traction is not exerted, for the traction straps alternately relax and tighten when the weight of the body falls upon and leaves the brace in walking. When the brace is off

the ground the joint is subjected to the traction that the brace exerts, plus its weight, as contrasted with cessation of traction and the relief from the weight when the brace supports the body at the alternate step. Thus the critics of the brace assert, in somewhat exaggerated language, that it exercises a pumping action on the joint. As a matter of fact, the observation of patients under treatment by this method will show that little actual traction is exerted in the ordinary cases; that the so-called traction really serves principally for the adjustment of the brace, which by its weight exercises a certain intermittent traction during locomotion. The hold of the encircling band upon the pelvis assures a considerable restriction of motion, but whatever splinting action it may have depends upon the degree of traction, which is never effective enough, however, to prevent a certain

FIG. 203.

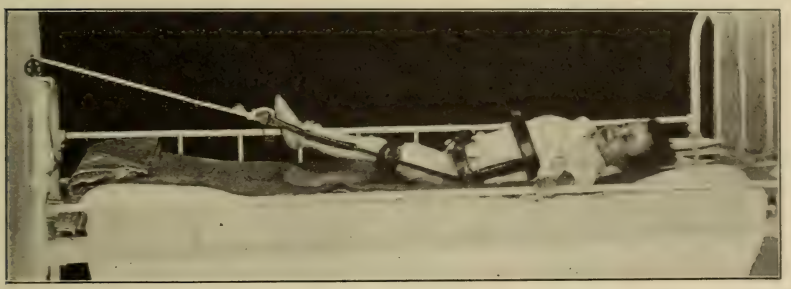

A method of reducing flexion in hip disease. The brace is adjusted to the angle of deformity, and in addition to the direct traction of the apparatus weights are attached to the brace itself. In the illustration counter-traction, by means of perineal bands attached to the head of the bed, is shown.

amount of motion. This point is illustrated by the experiments of Lovett,[1] which are described by him as follows:

"In these experiments a long traction splint was fitted with a self-registering pencil by means of which motion at the hip-joint was recorded upon the skin over the ilium. This was done simply by carrying the shaft up so that it held the pencil perpendicularly to the skin. A splint fitted with this register was applied to a boy with normal hip-joints, and traction was made up to the usual point, being about three pounds and a half, as registered by a spring balance inserted in the extension straps. With this splint on the boy was allowed to walk, and it was found that the hip described an arc of thirty-five degrees of joint

[1] R. W. Lovett. New York Medical Journal, August 8, 1891.

motion. In sitting down and rising an arc of similar extent was described. In another case with normal hip-joints the motion was found greater, and the register showed a motion of forty degrees. With a very severe amount of traction—so much so that it was almost unendurable—motion of fifteen degrees was recorded. This apparatus was first tested by being applied to a patient with anchylosis of the hip, when it was found that no motion was recorded, the register marking by a dot. These experiments certainly seem to show that to a healthy hip-joint the long traction splint affords very imperfect fixation, and it may be inferred that to a diseased joint equally poor support is afforded."

The fact must be borne in mind that the traction hip splint was not intended to be a fixation or splinting appliance. On the contrary, Davis, its inventor; Taylor, who changed it into a practicable form, and Sayre, who further modified it, each believed that motion, except when the joint was fixed by muscular spasm, was desirable.

"The first splint, as well as all my modifications, admits of free motion of the diseased joint, but rigidly excludes all friction of the diseased surfaces upon one another."[1] (Davis.)

"Motion without friction is not only not injurious, but it is highly beneficial."[2] (Taylor.)

"For the ligaments around a joint will become fibrocartilaginous or even osseous, if motion is denied them, particularly if a chronic inflammation is going on within the joint with which they are connected.

"As Dr. Davis is, I believe, the first person who constructed an instrument embracing these important advantages, extension with motion, I have given him full credit for the same," etc.[3] (Sayre.)

Motion without friction in this sense would seem to imply the actual separation of the femur from the acetabulum, or distraction as distinct from traction.

That actual distraction is possible at the hip-joint both in health and disease is proved by the experiments of Brackett[4] and by those of Bradford and Lovett. These experiments show that a traction force from ten to twenty pounds is required to cause

[1] Davis. Conservative Surgery, 1867, p. 214.
[2] Taylor. The Mechanical Treatment of Disease of the Hip-joint, 1873, p. 15.
[3] Sayre. Lectures on Orthopedic Surgery, 1879, p. 260.
[4] Brackett. Transactions American Orthopedic Association, vol. ii. Bradford and Lovett, New York Medical Journal, August 4, 1894.

one-eighth to one-quarter of an inch of actual lengthening of the limb, even in childhood. It is, therefore, to say the least, unlikely that the feeble and intermittent traction exerted by a hip splint, when used as an ambulatory support, can be sufficient to separate the bones from one another and thus to allow motion without friction as was originally claimed for this apparatus. In fact, it would appear that the claim that motion was of positive benefit to the diseased joint was afterward modified by the upholders of this method of treatment to a negative assertion of its harmlessness, for example:

"If the disease permits a certain amount of motion at the affected articulation, motion within the limits set by nature is not harmful."[1] (Shaffer.)

This statement would seem to imply that the motion permitted by the apparatus might be varied in accordance with the degree of restriction that a particular case presented, provided that this motion were restricted to the limit set by nature. In actual practice, however, the same form of brace is applied, and with the same adjustment, in every case; or as it is stated in a paper on the final results of the mechanical treatment by this apparatus in dispensary practice, under Shaffer's direction: "In each case reported a Taylor traction splint was applied soon after the first examination. . . . The patient, unless recumbency was necessary to overcome a malposition of the limb or unless the symptoms were so acute as to demand rest, was allowed almost unlimited exercise in the open air."[2] Yet it may be inferred from the report of the final results in these cases that in spite of the protection, which, in many instances, must have restricted motion within the limits present at the first examination, the range of motion became more and more restricted, for in 16 of 35 cases reported anchylosis resulted, and in 7 others the motion was less than ten degrees. Thus in 74 per cent. of the cases practical fixation of the joint was found on the final examination.

In criticising these statistics it must be borne in mind that the patients were treated under all the disadvantages of dispensary practice, and that the final usefulness of a limb is by no means in proportion to the freedom of motion that may be preserved; still with these reservations it can hardly be claimed that the proportion of absolute or partial anchylosis would have been

[1] Shaffer. Transactions American Orthopedic Association, vol. ii, p. 199.

[2] Shaffer and Lovett. On the Ultimate Results of the Mechanical Treatment of Hip-Joint Disease. New York Medical Journal, May 21, 1887.

greater than this had any other system of treatment been employed.

At the present time the theory that motion of a diseased joint is of benefit, or even that it is harmless, has few supporters even among those who use the traction brace exclusively. On the contrary, the motion that cannot be prevented is excused because of the practical efficiency of the brace and because it is believed that no more effective protection can be attained by any other method of ambulatory treatment.

In all acute cases a period of rest in bed with traction to the point of actual distraction is advised. When ambulation is resumed the braced limb is made pendent by means of the high shoe and crutches, so that uninterrupted traction may still be exerted, and the brace is only used as a supporting appliance when the symptoms indicate that the disease is quiescent.

Although this modification of treatment was not followed by Taylor, still in his later writings he states that motion is of advantage only in the stage of recovery. And it is evident that his success was due to the extreme care which he exercised in the supervision of the patients, and in adapting treatment to the varying phases of the disease rather than to any theory that he may have advocated.[1]

As has been stated, treatment by the long traction brace, by means of which motion without friction was at one time claimed to be possible, and in which traction is the distinctive feature, is sometimes called "The American Treatment of Hip Disease." In this sense the direct splinting of the joint without traction, by means of the Thomas brace, might be called in distinction "The English Treatment."

The Thomas Treatment of Hip Disease. H. O. Thomas,[2] of Liverpool, writing at a time when in America it was generally believed that motion was essential to the well-being of a diseased joint, and when fixation was supposed to predispose to, or to actually induce, anchylosis, states "that continuity of extension *per se* is not a remedy in hip-joint disease; in its application it involves unavoidably a fractional degree of fixation which is sufficient to mask the evil of this ridiculous malpractice."

The conclusions on which his treatment is founded are these: "The main obstacle to the cure of an inflamed joint is the friction

[1] Boston Medical and Surgical Journal, March 6, 1879.

[2] Diseases of the Hip, Knee, and Ankle-Joints, Treated by a New and Effective Method, 1875, p. 10.

and pressure of its surfaces; consequently the attainment of rest, that is of immobility of the articulation, ought to be the principle which should guide the treatment. Pressure and concussion are less to be feared than friction. Effectual rest can only be obtained by mechanical treatment, and for this purpose the appliances which I here recommend are effectual. The more an inflamed joint is moved the stiffer does it become; while the more effectually it is fixed, the sooner and the more completely is its capability of movement restored. To insure permanency of cure the control should be maintained for a period beyond the time when resolution has taken place. This prolonged arrest of

FIG. 204.

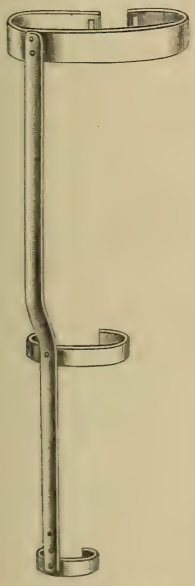

The splint in its simplest form, not yet padded or covered. (Ridlon.)

FIG. 205.

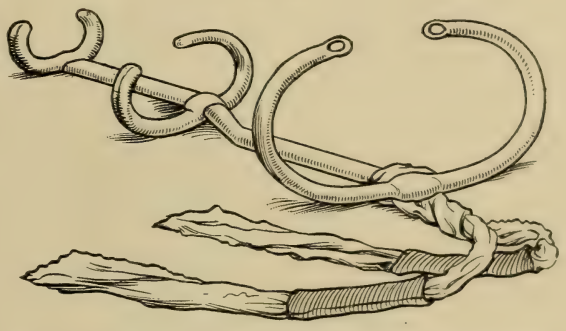

The Thomas hip splint, covered and fitted with shoulder straps. (Ridlon and Jones.)

a joint's movements, for even an unnecessarily long period, I have never found to do harm."

The splint used by Mr. Thomas to carry out these principles effectively is described by him substantially as follows:

A flat piece of malleable iron, three-quarters of an inch wide and three-sixteenths of an inch thick for children, and one inch by one-quarter inch for adults, long enough to extend from the lower angle of the scapula to the middle of the calf, forms the upright. This is fitted to the body of the patient, passing from the lower angle of the scapula, in a perpendicular line, downward, over the lumbar region, across the pelvis, slightly external, but close to the posterior spinous process of the ilium and the prominence of the buttock, along the course of the sciatic nerve to a point slightly external to the calf of the leg. It must be carefully modelled to this track. The lumbar portion of the

upright must be invariably almost a plane surface, but it must be twisted slightly on its long axis at the junction of the upper and middle third, so that the anterior surface of the lower part may look slightly outward to correspond to the contour of the buttock and thigh. A second and double bend is made in the upright at the point where it passes the buttock, so that the thigh part lies on a slightly higher plane than the body part, but parallel with it. The upright is then provided with chest, thigh, and leg bands (Fig. 204).

The chest band is of hoop iron one and a half inches in width by one-eighth of an inch in thickness. This is bent into an oval to correspond with the shape of the chest, being four inches less than the circumference at this point if the patient is an adult, and of a corresponding size for a child. It is riveted to the upper extremity of the brace, so that one-third of its length shall be on the side corresponding to the diseased joint and two-thirds on the other. The thigh band and leg band are of similar material, three-quarters by one-eighth of an inch in size. The thigh band, in length equal to two-thirds of the circumference of the thigh, is fastened to the upright at a point one to two inches below the buttock, and the calf band, equal in length to half the circumference of the leg at the calf, is riveted to the lower extremity of the brace. Both the thigh and leg bands are attached to the brace at points slightly to the inner side of the centre, so that the outer arm of each band is somewhat longer than the inner. The brace is padded with thin boiler felt and is covered smoothly with basil leather. In fitting the brace to the patient the long part of the chest band should be made to hug the body closely, while the short arm should be somewhat away from it. The anterior surface of the thigh part of the upright should have a perceptible outward twist and should be somewhat on the inner side of the popliteal space. Thus the instrument is prevented from rotating outward and becoming a side splint. The chest band is closed with a strap and buckle; it is suspended by shoulder straps, and the leg between the two bands is attached to the brace by means of a flannel bandage. Ridlon states that in practice this bandage is usually replaced by a strip of basil leather passed across the front of the limb close down to the upper border of the patella, thence backward and downward to the stem of the splint and pinned to the covering, so that the resistance to the downward working of the brace is borne by the quadriceps femoris muscle. The ordinary

shoulder straps may be replaced by a single bandage looped about the upper part of the stem (Fig. 206). This bandage is twisted for a length of about six inches, then separated, the ends being carried over the shoulders, are passed through holes in the corresponding ends of the chest band, where they are knotted, and finally the two ends are tied to one another, completing the circumference of the chest band.

This brace is fitted by the surgeon directly to the patient's body as he stands erect. If the limb be already flexed the foot is raised by blocks until the lumbar lordosis is straightened; the

FIG. 206.

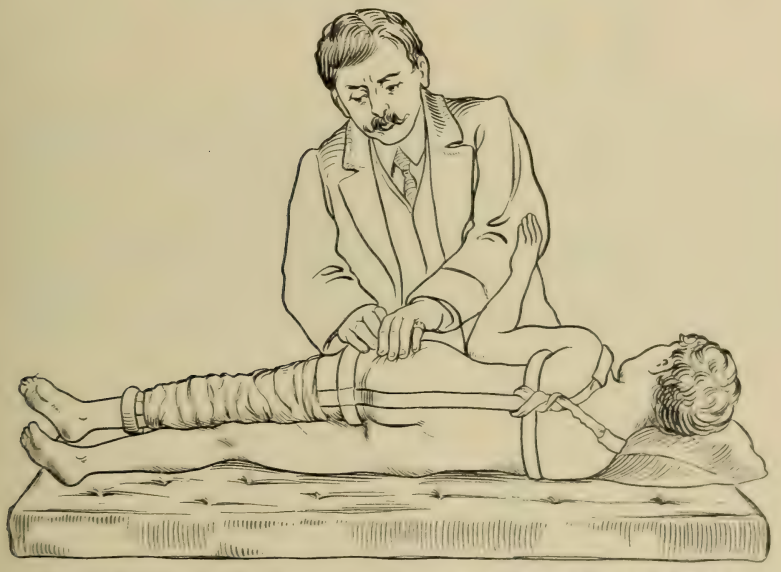

Method of changing the line of pressure on the skin from the Thomas hip splint by drawing the tissues to one side. (Ridlon and Jones.)

brace is then bent to fit the angle of deformity and is applied in the usual manner.

The brace is made of iron because it is less elastic than steel, and because it can be more easily twisted by wrenches. It must be heavy and strong in order to splint the part effectively, and it can only be an effective splint when it is fixed in its proper position and exercises direct pressure upon the hip-joint. In cases in which the brace has been properly employed a deep furrow should appear in the buttock directly over the neck of the femur. Once fitted to the patient it is changed only at infrequent

intervals and always by the surgeon, who is particularly careful not to move the limb during the active stage of the disease.

The double Thomas hip splint is made by joining two single splints. These are riveted to the chest band above and are connected at the lower ends by a crossbar, unless the brace is to be used in the reduction of deformity. Care must be taken that the uprights pass to the outer side and not directly over the posterior superior spines of the ilium.

FIG. 207.

Thomas splint applied with patten and crutches.

The Reduction of Deformity by the Thomas Method. Preferably in the treatment of children the double brace is applied, the sound limb being fixed in the extended position while the flexed limb is supported by the other arm of the brace, bent to the angle of deformity. The patient is confined to the bed and, as the muscular spasm relaxes under the influence of enforced rest, the brace is straightened slightly by wrenches from time to time, at a point opposite the joint, to conform to the improved position until symmetry is restored. In resistant cases this gradual relaxation is hastened by straightening the brace somewhat at intervals, to which the attached limb must conform—a gradual forcible reduction of deformity. According to Ridlon and Jones, the flexed limb is often forced to conform to the straight brace by a temporary exaggeration of the lumbar lordosis, which lessens as the spasm subsides under treatment.

The treatment is divided by Mr. Thomas into stages:

1. A preliminary stage of rest in bed for the reduction of deformity and to allow for subsidence of acute symptoms.

2. The patient is then allowed to go about on crutches wearing an iron patten at least four inches in height under the sound foot (Fig. 207).

3. When all symptoms of disease have subsided and when atrophy of the muscles is marked the brace may be removed at night.

4. The brace is finally discarded, but the patten and crutches are still used in walking.

According to Ridlon[1] the records of Mr. Thomas show the average time of confinement to the bed to be twenty-two weeks, and the average duration of treatment twenty-one months.

It is stated by Ridlon[2] that in actual practice these principles were not carried out, for nearly all the children treated under Thomas' direction at the time his observations were made were walking about without the high patten and crutches, even before the deformity had been overcome and while muscular spasm and pain persisted.

FIG. 208.

A form of Thomas brace employed in the treatment of infants. The pelvic band assures better fixation. The screws at the lower extremity are arranged to permit the addition of a foot-piece for traction.

This was, however, probably an exigency of practice among the poor, and at all events it is in line with Thomas' contention that pressure and concussions are less harmful than friction.

Modifications of the Thomas Brace. Although not so stated in his book, Thomas used at times a short brace extending only to the lower part of the thigh, thus permitting motion at the knee. This was apparently designed as a convalescent splint, although its use was not restricted to that class of cases. In certain cases a strip of iron, "the nurse," was screwed to the lower extremity of the long brace, prolonging it beyond the foot in order to prevent the patient from bearing weight upon the limb.

The Thomas brace, so effective in preventing and overcoming flexion deformity, does not prevent lateral distortion. In fact,

[1] Transactions American Orthopedic Association, vol. i. p. 17.

[2] A Report of Sixty-two Cases of Hip Disease Observed in the Practice of Hugh Owen Thomas. New York Medical Journal, October 4, 1890.

in twenty-four of the fifty-eight patients examined by Ridlon,[1] adduction was present; a larger proportion, it would appear, than would be found in a like number of cases under treatment with the traction brace. This tendency to lateral distortion may be guarded against by placing a half band of material similar to

FIG. 209.

The long plaster spica bandage. The dotted line indicates the position of the steel support.

the chest band about the side of the pelvis; on the same side for adduction, on the opposite side for abduction of the limb.

The Thomas brace has a great advantage over other appliances in its simplicity. It can be made by a blacksmith, but it must

[1] Loc. cit.

be fitted by the surgeon. This fitting requires great care. In the words of Mr. Thomas, "the fitting, although sometimes successful in one visit, may at other times occupy many days. The surgeon should mould, by reducing or increasing the various curves, until the instrument ceases to tend to rotate, and at none of its angles irritates the patient." He concludes in a general answer to the criticisms that have always been made on the difficulty of adjustment of the appliance as follows: "What I can invariably do must be possible to others."

Treatment by the Plaster Bandage. A third method of treatment is that by means of the plaster bandage without crutches or high shoe. This is simple splinting with whatever protection from concussion the support may assure.

This treatment might be called the German method if the traction hip splint and the Thomas brace are to be designated as American and English.

As used in the surgical clinic at Berlin, the plaster bandage is applied from the line of the nipples to include the foot, the limb being fixed in an attitude of slight flexion, abduction, and outward rotation. As a rule, the first bandage is applied under anæsthesia for the purpose of relaxing the muscular contraction and facilitating the application. If nutritive shortening of the muscles is present, sufficient force is employed to overcome the deformity. The spica is renewed at intervals of from two to four months. When the disease is cured and after the bandage is finally removed traction at night is employed for a time by means of a weight attached to the foot to prevent the tendency to distortion. In ambulatory treatment this method has little to recommend it except expediency, but as a temporary support to be used before the application of a suitable brace the plaster spica is most useful.

When properly applied it is an admirable support, often far more comfortable to the patient than any brace, and it is at times an indispensable form of dressing. It has the same defects as the plaster jacket, and it may receive the same defence that its most severe critics have had the least experience in its use.

Application of the Plaster Spica Bandage. A plaster bandage to assure support should fit perfectly, consequently it should be applied as closely as is possible. If it is available the trunk and the limb should be protected by a close-fitting covering of shirting, such as is used in the application of the plaster jacket. Those parts that are likely to be subjected to pressure

—the toes, the heel, the malleoli, the condyles of the femur, the sides of the pelvis, the anterior superior spines, and the thorax—should be suitably protected by cotton wadding, which may be held in place by a snugly applied canton-flannel bandage. The plaster bandage should cover the lower half of the thorax, and it should extend to the ends of the toes. It should be applied under slight extension very carefully around the adductor region and the buttock, which should be entirely covered and supported. At this point, in the line in which the bar of the Thomas hip splint runs, a piece of splint wood or a strip of malleable steel, long enough to reach from the middle of the back to the lower third of the thigh, should be incorporated in the plaster (Fig. 207). A similar piece is sometimes placed in front of the hip

FIG. 210.



A modification of the Lorenz hip rest used in the application of the plaster spica bandage. Another form is illustrated in the article on Congenital Dislocation of the Hip.

and another beneath the knee, the points at which the bandage is likely to break. The proper anteroposterior support of the buttock, consequently of the hip-joint, is almost invariably neglected in the ordinary application. The bandage may be applied in the upright posture by means of the swing, as used in the application of the plaster jacket, the weight being supported in part by the sound leg while the other is pendent. Or it may be applied with the patient in the reclining posture, the body being supported by a shoulder rest, and the pelvis by a sacral support. The arms are then drawn above the head to increase the capacity of the thorax, while the limbs are supported by an assistant (Fig. 213).

In the more recent cases deformity may be practically reduced at the second application of the bandage, because of the relaxation of the spasm assured by the rest and fixation; thus it is particu-

larly useful in the treatment of young children in the outdoor practice, for whom hospital care would otherwise be required.

THE SHORT OR LORENZ SPICA BANDAGE. The short spica bandage is used as routine treatment of hip disease in Lorenz's

FIG. 211.

The Lorenz spica, showing the adjustment to the pelvis. In this case it is extended below the knee, but in many instances motion at the knee-joint is permitted.

clinic in Vienna unless direct weight bearing causes pain. It is applied in the manner described under the treatment of congenital dislocation of the hip, the aim being to fix the affected limb in an attitude of slight flexion and abduction, the primary attitude of hip disease. A close-fitting covering of shirting is drawn over

the limb and pelvis, and a wide bandage is then introduced between the skin and shirting to serve as a "scratcher." The bony prominences are suitably protected by cotton or sheet wadding, and the bandages are then applied, being drawn closely about the pelvis and thigh, so that the movement joint may be controlled. The upper and lower extremities of the bandage are cut away as illustrated, and the shirting is then drawn over the margins of the plaster and sewed. This makes a smooth covering and holds the padding in position. If the bandage is extended below the knee it is more efficient. As an adjunct to mechanical support and during the stage of recovery, or even in the treatment of cases of a mild type, the bandage is very satisfactory, but as a routine treatment it is not a sufficient protection. It should be stated that in the treatment of the more acute cases by Lorenz the weight of the body is removed by a prolongation or stirrup of sheet steel which projects beyond the foot, the two extremities being incorporated in either side of the plaster bandage in the neighborhood of the knee (Fig. 212). In the better class of cases a leather support provided with a steel foot-plate extending slightly below the foot and a joint at the knee is used. The short spica bandage in combination with the traction hip brace (Fig. 220) answers the same purpose and is more efficient if somewhat more cumbersome.

Fig. 212.

The Lorenz stilt, sometimes used in the treatment of the more painful cases. This is incorporated in the plaster bandage above the knee and it extends below the foot.

Immediate Reduction of Deformity. In the more resistant cases an anæsthetic may be administered. If the deformity is due simply to muscular spasm the limb may be placed in the proper position without force, but if, as is often the case when the distortion is of long standing, it is caused in part by shortening of the muscles and fasciæ, a certain amount of force may be required.

The pelvis should be fixed and the force should be applied as far as possible by direct extension rather than by leverage. Subcutaneous division of the contracted tissues about the anterior superior spine and in the adductor region may be required. In very resistant cases the reduction of deformity by this method should be divided into several operations. Lorenz reduces the adduction deformity by means of a machine that exercises direct

traction on the adducted limb while the sound limb is pushed upward, so that practically no leverage is exerted on the joint.[1]

In cases in which the deformity is accompanied by abscess, or when the joint is surrounded by infiltrated tissues and by sinuses this treatment should not be employed. In fact, in certain cases of this class, especially when subluxation is present, it is often advisable to disregard the deformity that cannot be reduced by traction until the disease is cured, when it may be overcome by osteotomy of the femur.

FIG. 213.



The hip rest in use. The patient presents fixed flexion to 135 degrees, and fixed adduction of 35 degrees.

The immediate reduction of deformity, properly performed, is free from danger; and it has become almost the routine of practice in the indoor department of the Hospital for Ruptured and Crippled. The great advantage of placing the limb in the proper position and fixing it for weeks or months, instead of employing this time for the gradual reduction of the deformity, is, of course, self-evident.

[1] Lorenz. Sammlung klin. Vor., 206, Leipzig, March, 1898.

Three methods of reduction of deformity have been described:

1. By means of the traction brace.
2. By means of the Thomas brace.
3. By means of the plaster bandage, with or without anæsthesia.

A fourth method is that by means of the weight and pulley. This is in common use because it requires no special apparatus.

FIG. 214.

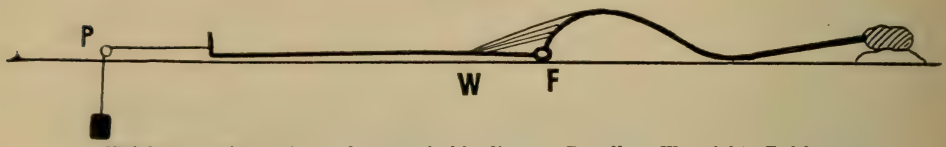

Weight extension acting as leverage in hip disease. P, pulley; W, weight; F, fulcrum. Marsh's diagrams, illustrating the advantage of traction in the line of deformity, in order to avoid leverage. (Howard Marsh.)

REDUCTION OF DEFORMITY BY THE WEIGHT AND PULLEY. The traction plasters are applied to the limb in the manner already described and the patient is placed on his back on a narrow, firm mattress. The limb is raised until the lumbar vertebræ rest upon the bed and it is then moved to one or the other side, if lateral distortion is present, until the level of the pelvis is restored. In this position the limb is supported on a pillow, or, better, on the adjustable triangle used with the traction hip splint (Fig. 202). A pulley is then attached to the foot of the bed in a prolongation of the line of the flexed limb. The wheel may be screwed to the top of a narrow board, which may be raised or lowered on the foot of the bed as required. To the buckles on the plaster traction straps a stirrup carrying the cord is attached. This stirrup is simply a spreader of narrow, thin wood, slightly wider than the foot, provided at either end with straps or tapes, its purpose being to prevent direct pressure on the malleoli (Fig. 219). By means of a

FIG. 215.

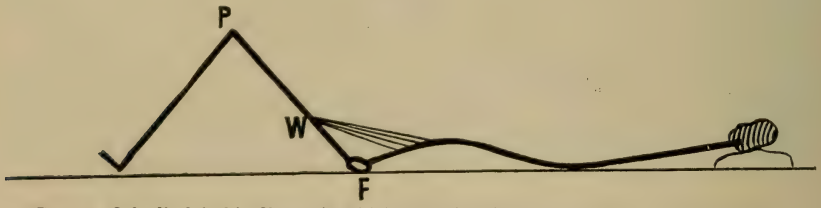

Posture of the limb in hip disease in which extension should be applied in order to avoid leverage. P, pulley; W, weight; F, fulcrum.

weight suspended at the foot of the bed traction is made upon the limb to the extent that the comfort of the patient will permit. As in Buck's system of extension, the foot of the bed is raised to increase the friction of the body and thus to counteract the traction force, but in the treatment of children this is inefficient and counter-traction must be provided. A simple method is to attach two perineal bands, as described in connection with the traction brace, to strong tapes that pass above and below the patient's body, to be fixed to the head of the bed at a suitable distance from one another; thus the pelvis is supported by prolonged perineal bands.

In order to assure efficient and constant traction the patient must be prevented from sitting up. For this purpose a swathe about the body or shoulder straps may be applied and attached to the bed.

FIG. 216.

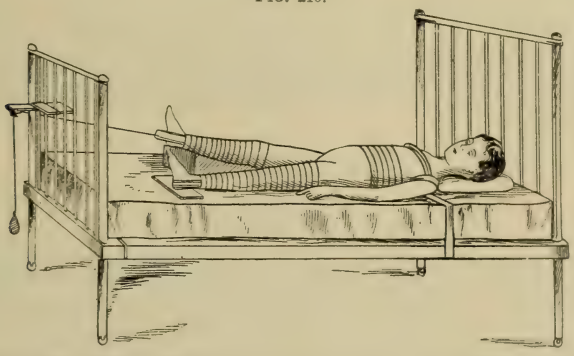

Extension in hip disease. Marsh's method of fixing the patient in bed with shoulder straps and a long T-splint on the sound side. (Howard Marsh.)

A convenient appliance is that of Marsh. "This consists of a piece of webbing, passing across the front of the chest and ending in two loops, through which the two arms are passed, and through which is threaded another piece of stout webbing, which runs transversely across the surface of the bed under the child's shoulders, and is fastened at its two ends to the sides of the bedstead. When this is in action the patient's shoulders are kept flat on the bed, so that he can neither sit up nor turn on his side. This chest band does not cause the slightest discomfort. It is not, of course, fixed tightly, and when the child finds that he cannot sit up he makes no further attempt to do so; and as he lies flat the band is loose."

It is often of advantage, particularly if the disease is active, to use some form of apparatus to fix the patient more thoroughly.

Marsh uses a long lateral splint of thin board reaching from the axilla to a crossbar below the sole of the foot. To this the patient's body and sound limb are bandaged (Fig. 216).

FIG. 217.

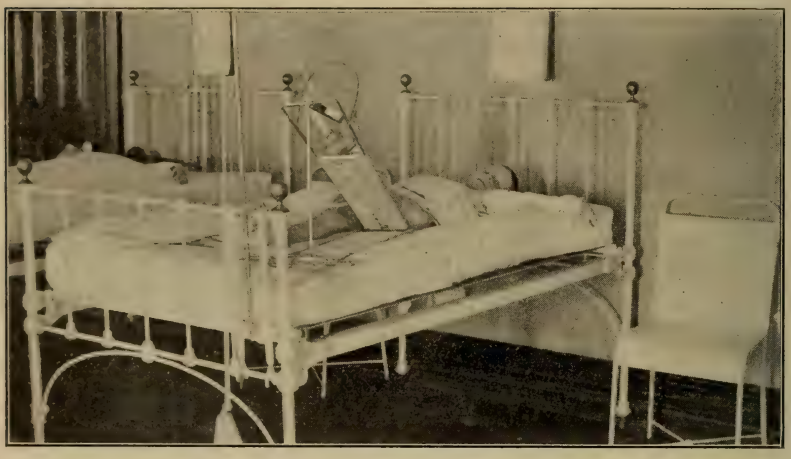

Traction by means of weight and pulley. (R. T. Taylor.)

FIG. 218.

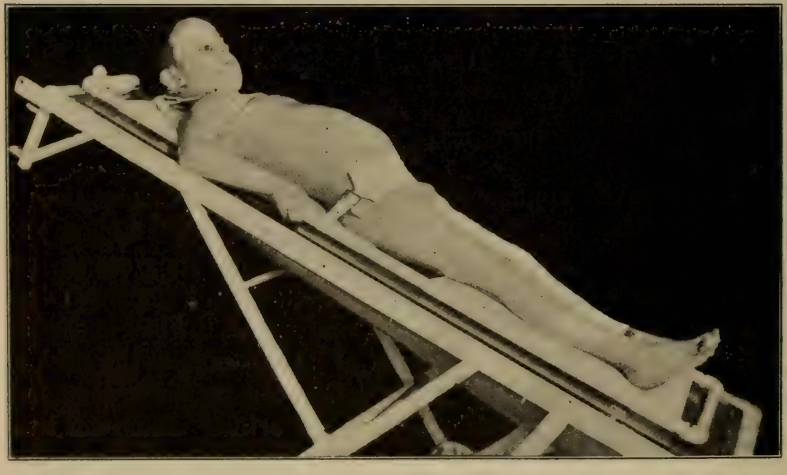

Method of fixing the patient to the Bradford frame for traction in hip disease. (R. T. Taylor.)

For the same purpose a plaster spica bandage or a Thomas splint may be applied on the sound side, but a more convenient appliance is the frame of gas-pipe covered with canvas that has

been described in the chapter on Pott's disease. Upon this frame the patient can be fixed, the limb being elevated by a support attached to the frame or independent of it (Figs. 217 and 218). It is perhaps needless to suggest that the bedclothes must be held from the elevated limb; in fact, that the patient must for a time be enclosed in a tent of bedclothes if the deformity is extreme. At first the traction weight must not be great, but as the perineum becomes accustomed to pressure as much weight as can be tolerated is used, from ten to twenty pounds being the average. This may be reduced at night and increased during the day. Great care must be taken to prevent painful pressure on the perineum by careful adjustment and frequent inspection of the perineal bands.

FIG. 219.

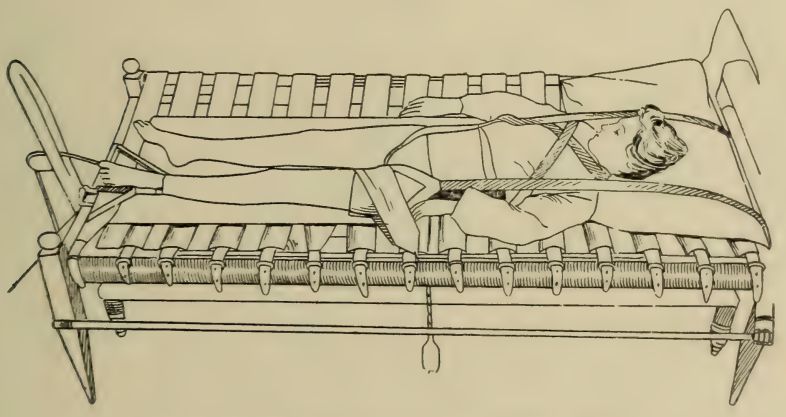

Lateral and longitudinal traction in hip disease. (Page.)

If the frame is used it may be provided with a windlass at the bottom for traction and with an arched band of metal across the pelvis for the attachment of the perineal bands, which behind are fastened to the side bars at a higher level. Thus the frame may be made an independent recumbent splint on which the patient may be moved about. If, however, one desires to exert traction to the point of distraction, the weight and pulley arrangement is more satisfactory; in this case the limb should be placed in an attitude of slight flexion and abduction, so that the femur may be drawn more directly from the acetabulum.

Lateral Traction. Thus far longitudinal traction has been considered, but lateral traction or traction in the line of the neck of the femur deserves some consideration.

Mr. Thomas, who condemned all forms of traction as deceptive and irrational, and especially longitudinal traction, speaks thus of lateral traction: "For surely if relief from pressure be required, the only direction in which this is possible is clearly in the axis of the neck of the femur. Any method of extension in the axis of the body merely transfers the pressure from the upper part of the acetabulum to the lower quarter."[1] This contention is purely theoretical, as there is no evidence to show that injurious pressure is ever exerted upon this part of the acetabulum. On the contrary, the specimens from subjects who have been treated by longitudinal traction in recumbency and by means of the traction hip splint almost invariably show the effect of pressure upon the upper part of the head of the femur and upon the upper adjoining margin of the acetabulum. Moreover, the neck of the femur is in childhood so short and is set upon the shaft at so great an angle that longitudinal traction, if the limb be slightly abducted, is, practically speaking, in the line of the neck; so that even from the theoretical standpoint the question of injurious pressure could only arise in the treatment of adults. The advantage of lateral traction in the treatment of hip disease has been urged with great persistency by A. M. Phelps[2] since 1889, and it has been applied as a routine practice in ambulatory treatment by Blanchard,[3] of Chicago, since 1872.

The effect of lateral traction in recumbency has been carefully investigated by C. G. Page.[4] His conclusions are that lateral traction alone is of no benefit, but if applied, together with longitudinal traction, it gives great relief in certain acute cases. The longitudinal traction should be twice as great as the lateral, ten and five pounds being the average weights employed in his experiments. The method is shown in the illustration (Fig. 219).

The Relative Efficiency of Traction and Splinting ("Fixation").

In considering the vexed question of the relative merits of splinting and traction in preventing muscular spasm and the consequent intra-articular pressure which causes pain and increases the destructive effects of the disease, these facts must be borne in mind.

[1] Loc. cit., p. 10.
[2] New York Medical Record, May 4, 1889.
[3] Transactions American Orthopedic Association, vol. vii.
[4] C. G. Page. Boston Medical and Surgical Journal, September 13, 1894.

The more acute the disease the less ability of the joint to carry out its proper function, which is motion. The greater the motion under these circumstances the more intense the muscular spasm, of which the object is the prevention of motion. If it were possible, therefore, to fix the joint absolutely there should be no muscular spasm, although the tension of acute disease within the bone, or of its products within the joint, might cause pain.

When the patient is fixed in the recumbent posture it is possible to apply a sufficient traction upon the muscles to prevent the spasmodic contraction that causes injurious pressure, and although no amount of traction will absolutely prevent motion, yet with the support that the bed provides, practically speaking, complete rest may be assured. Only in the exceptional cases in which tension upon congested tissues about an acutely inflamed joint is intolerable is this method of treatment inefficient.

The same statement is true of a properly applied spica bandage or Thomas brace, when the patient is recumbent, that it assures practical rest; thus it prevents muscular contraction, relieves the symptoms and promotes repair, although it cannot be claimed that the surfaces of the opposing bones are actually separated from one another.

But what is true when the patient is recumbent is not true in ambulatory treatment. The traction exerted by the hip splint even when the limb is pendent is far less effective than in recumbency, and when it is used as a walking appliance, for which it was designed and for which it is practically always employed, the traction is intermittent and of doubtful efficiency. The same loss in efficiency, although in far less degree, occurs in all forms of fixative apparatus when used in ambulation, but it may be stated without reserve that splinting is of far more importance in actual practice than is traction.

The Removal of Direct Pressure. "Stilting." Granting that the traction brace as a walking appliance is relatively inefficient in preventing motion, and that motion without friction, provided the joint surfaces are actually involved, is impossible, still the traction brace is, or may be, at all times an effective stilt in that it protects the joint from concussion and pressure by removing the foot from contact with the ground.

It is true that the removal of direct pressure may be assured by the use of axillary crutches, but in Thomas' practice they

were used in but few cases.[1] In fact, it is only by constant supervision that the use of crutches can be enforced upon children who no longer suffer pain; and as it is practically impossible to prevent the patient from bearing weight upon the limb, stilting by this means is relatively inefficient.

That direct pressure is one of the causes of upward displacement of the femur may be inferred from the statistics of Sasse and Bruns,[2] from the surgical clinics of Berlin and Tübingen, where the routine of treatment is the plaster bandage without the high shoe or crutches. In two-thirds of Sasse's and in four-fifths of Bruns' cases there was upward displacement of the trochanter. This is certainly a larger proportion than would be found in a corresponding class of patients treated by efficient stilting, although statistics on this point from American sources are lacking.

The Practical Combination of Traction. Splinting and Stilting. Thus far the methods of treatment by splinting and traction have been presented as if they were necessarily opposed to one another in principle, and as if the theory were still held that motion without friction is possible; and as if it were believed that anchylosis is caused by fixation and is prevented by the motion of a diseased joint. At the present time, however, it is generally recognized that the principle involved in both methods is the same, and that the actual merit of each must be decided by practical experience rather than by argument. The true test of the relative value of a routine of treatment is its efficacy in hospital practice, where its weak points cannot be supplemented by the careful supervision that may make almost any treatment effective that carries out in some degree the proper principle. This test is all the more necessary because the great majority of cases of this character are to be found among the poor.

From this point of view the writer's experience may be of interest. His early training was entirely in the traction method, but the observation of a large number of cases in which this treatment was used led to the following conclusions:

In one sense the treatment was successful, in that it in great degree relieved the symptoms throughout the course of the disease and enabled the patients to go about in the open air, to attend to school, and even to join in the games of their fellows. It was evident, however, from an inspection of the patients as

[1] Ridlon. Loc. cit.

[2] Sasse. Arbeit aus der klin. Chir., Berlin, 1896. Bruns, Archiv f. klin. Chir., Bd. xlviii. H. 1.

they returned for treatment, that the relief of symptoms was due to the protection insured by the stilting or crutch-like action of the brace and not by traction, which was usually simply traction in name, not in fact. But if the brace relieved the symptoms, it did not, in many instances, prevent deformity; and as the prevention of deformity is an object only secondary in importance to the relief of pain, the treatment was in so far unsatisfactory. This deformity was usually flexion, occasionally combined with adduction, a deformity often increasing slowly without pain, or other evidence of greater activity of disease. If the deformity were reduced by traction in recumbency, it reappeared when ambulatory treatment, by the brace, was resumed. This flexion seemed to be in many instances simply an adaptation to the prevailing

FIG. 220.

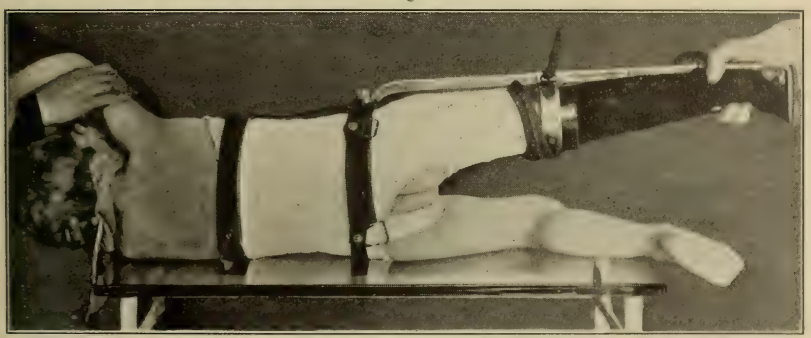

The short spica bandage reaching to the knee in combination with the brace. One perineal has been removed in order to show how the joint is supported by the bandage. The short spica of the Lorenz model may be used also for this purpose.

postures. When, for example, the patient assumed the sitting position, the limb was flexed in spite of the brace, and as much of the time was passed in this attitude, its influence on the production of deformity seemed to be obvious.

It was also apparent that the brace was not effective in relieving pain during the more acute exacerbations, even during recumbency with such traction as could be applied by the parents; nor when the children were brought in arms to the clinic.

Under these conditions it was found that acute symptoms might be relieved, or greatly modified, almost at once, by the application of a close-fitting short spica bandage extending from the middle of the thorax to the knee. Over this the brace was applied as before, making an apparatus which then combined splinting, traction, and stilting (Fig. 220). This treatment was

repeated in many instances, always with the same result. As the application of the plaster bandage was a somewhat tedious proceeding, it was often exchanged for a short Thomas splint worn beneath the pelvic band of the traction brace in the same manner. This fixation appliance not only relieved pain in the acute cases, but it also prevented the deformity, which was not checked by the traction brace alone.

FIG. 221.



The long, inexpensive brace, with solid upright, showing the perineal bands and the adhesive plaster, as used in hospital practice.

This combination of the short Thomas brace and the traction hip splint is effective as a means of relieving pain and preventing deformity. It has, however, the disadvantage of requiring careful adjustment, and it obliges the patient to wear shoulder straps; in other words, much care must be exercised to insure the comfortable adjustment of both appliances. Thus the next step was the combination of the two, even though the action was somewhat

less effective. To the pelvic band of the traction brace a lateral thoracic bar was attached, reaching upward in the axillary line to a point opposite the middle of the scapula, where it was joined to a metal band that encircled the chest, like that of the Phelps brace. When this was securely fastened about the chest, the body and the limb were held in line by a long lateral brace; the pelvis was supported by the pelvic band and the joint received the additional protection that was assured by traction and stilting (Figs. 221 and 222).

This brace and another form similar in principle, in which the upright of the thoracic attachment is fixed posteriorly to the pelvic band, are now in general use at the Hospital for Ruptured and Crippled. The efficiency of this brace may be still further increased by replacing the perineal bands by a metallic ring. This ring, which fits the upper extremity of the thigh closely, is

FIG. 222.



The long hip splint applied.

attached to the upright at an inclination corresponding to the line of the groin (Fig. 223). (The Thomas ring described fully in connection with his knee splint.) It is a better support because it prevents anteroposterior motion within the pelvic band, which the perineal straps allow. The ring may be used as the only support or it may be combined with a perineal band on the opposite side. This is of advantage if there is a tendency toward adduction.

The apparatus is most satisfactory when the hollow upright of the Taylor brace is used. This is light and strong, and is provided with an arrangement for effective traction, but in hospital practice the upright is made of solid metal, and the traction is made by simple straps. The metallic ring, besides providing better fixation, is a firm support that cannot be removed by the

patient. It is, of course, more difficult of adjustment, and it is not suited to the treatment of young children because of the difficulty in keeping it clean and dry.

The Thomas ring was first applied to a hip splint by Phelps (Fig. 225). He has always urged the advantages of fixation and

FIG. 223.

The long brace, with Thomas ring and extension upright, similar to Phelps' brace.

FIG. 224.

Rear view of brace.

traction, and his brace, of which that last described is simply a slight modification, is provided with an arrangement for lateral traction. Practically speaking, this is a tape by which the lower

third of the thigh is held in apposition to the upright. It hardly seems possible that appreciable lateral traction can be exerted on the joint by this means if the metallic ring is properly fitted to the thigh. The simple straps do not afford as effective traction as the rack and pinion, nor is the brace, as usually constructed, sufficiently strong to bear the weight of the body without bend-

FIG. 225.

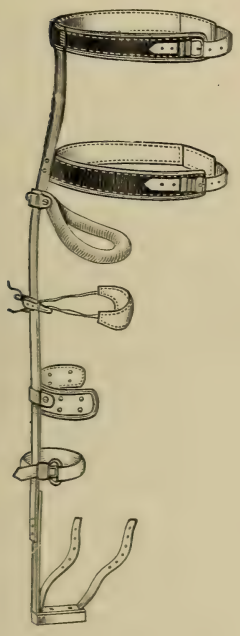

The Phelps hip splint.

FIG. 226.

A chair to be used with the long hip splint. The patient sits upon the sound side, while the splinted half of the body remains in the extended position, the brace resting on the floor.

ing. It should be stated, however, that this form of brace is intended to be used with crutches rather than as a walking appliance.

Many objections to this attempt to combine effective splinting without traction and stilting have been urged by those who believe in the efficiency of the ordinary traction brace. For example, it is said that the splinting is ineffective because the movements of the trunk are transmitted to the joint, while this is not true of braces that do not extend above the pelvis. In reply it may be stated that the traction part of the combined splint remains as effective

as before; thus it follows that this suggestion is an acknowledgment of the fact that the theory of motion without friction is no longer tenable. As a matter of experience, however, it will be found that motion of the upper part of the trunk is absorbed, as it were, in the flexible lumbar region of the spine before it reaches the joint. If, however, such motion or any motion causes discomfort or aggravates the symptoms, the patient should be confined in the recumbent posture until the acute phase of the disease is passed.

It is said that the brace is cumbersome, that the patient cannot sit with comfort, and that it prevents normal activity.

A long brace certainly weighs more than a short one, and if a brace prevents flexion of the hip and spine it is evident that the patient cannot sit with comfort in an ordinary chair.

As a matter of fact, the patients themselves make little complaint of the brace, even when it has been substituted for an ordinary traction splint; while the greater restraint of activity is a favorable element of treatment, since children who do not suffer pain are much more likely to be too active than to be harmfully restrained by any form of appliance. These objections are trivial, if one is convinced that the dangerous and deforming disease that is under treatment may be more easily controlled and that the final result is likely to be better and to be more rapidly attained by this means than by another.

It would be of advantage, of course, if a brace could be so adjusted to the pelvis and to the femur as to fix the joint without interfering with the motion of the spine. Satisfactory fixation can be attained, however, only by a close-fitting plaster bandage of the Lorenz model (Fig. 211). This should be applied over the traction plasters, and the traction hip brace is then adjusted. This method of treatment is the most effective that can be employed, but it must be renewed at frequent intervals if "ideal" fixation is desired.

This long brace is used exactly as is the ordinary traction brace. If deformity be present it is reduced by one or another of the methods that have been described. If the disease is acute, recumbency and traction are employed until this stage is passed.

When ambulation is resumed crutches may be employed for a time, but during the greater part of the treatment the brace is used as a walking appliance, as accurate splinting and as effective traction being employed during this period as circumstances will

permit. If the joint continues to be sensitive the short spica plaster should be applied in the manner described, to be worn beneath the brace. If one desires to exert lateral traction the upper part of the thigh may be drawn outward by means of a bandage attached to the junction of the pelvic band and the upright of the brace.

FIG. 227.

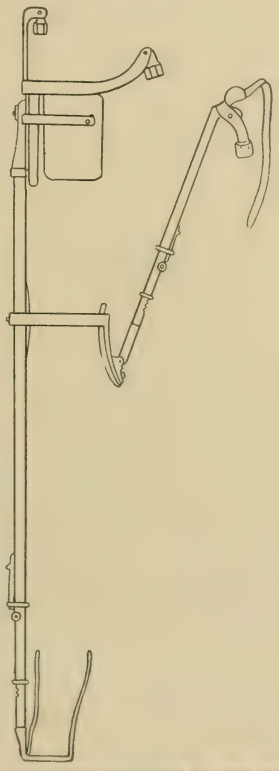

The Taylor hip splint as used by Taylor in the later years of his practice with but one perineal band.

The cut shows also an appliance for preventing or for correcting slight degrees of adduction, while the brace is in use as a walking appliance. The abduction bar is buckled about the upper extremity of the other thigh. (H. L. Taylor, *Medical News*, March 23, 1889.)

During the entire course of treatment supervision of the patient, with the aim of adapting activity to the local weakness, should be exercised, even though it may be less essential than when other apparatus is employed.

The impression that one might receive from descriptions of the treatment of hip disease is that most cases begin acutely, or that when the patients are brought for treatment the disease is in an acute stage, or that deformity is present, so that preliminary recumbency is required. But each year the proportion of early cases is greater, cases in which there is no deformity and in which acute symptoms are absent. In such instances the hip splint may be applied without preliminary recumbency, and if the joint is fixed in the normal attitude and protected a relatively rapid recovery without deformity and with a fair range of motion may be hoped for.

The Treatment of Hip Disease during the Stage of Recovery. It is much easier to assure one's self that the disease is still active than to decide when it is cured. For the symptoms may have been quiescent for months or years even, under the protective treatment, and yet they may recur on the slightest provocation when this treatment has been discontinued.

To judge of the probable duration of the disease in a given case, one must consider its area, its quality, and its complica-

tions. If, for example, the primary symptoms indicate that the focus of infection is of limited area and is contained within the bone, rapid recovery, possibly in a year, may be expected; but in the ordinary type of disease in which the joint has been

FIG. 228.

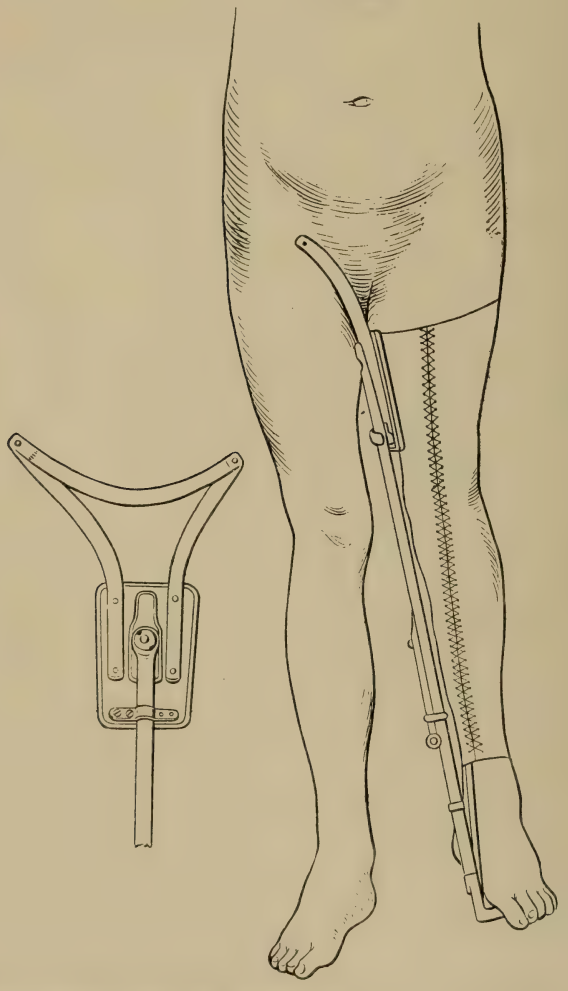

Taylor's median abduction brace used as a bed splint to overcome adduction by counter-pressure on the sound side.

invaded, repair can hardly be anticipated in less than three or four years. Supposing that sufficient time has elapsed to permit of natural cure, if there have been no symptoms of active disease for a year or more, and if muscular spasm is absent, one may test the joint by removing the brace at night to ascertain the

effect of simple motion without weight bearing. Such freedom will enable the patient to move the knee, which having been fixed in the extended position for so long usually remains stiff for a

FIG. 229.



Modified brace to be worn during convalescence. Same patient as in Fig. 224. The thoracic part has been removed and the lower end of the stem has been made into a caliper, passing through the heel of the shoe. The stem is extended by means of the key until the heel is lifted slightly from the shoe; thus the hip is relieved from shock.

FIG. 230.



Judson's perineal crutch. This support suspended from the shoulders may be employed as a substitute for axillary crutches. It is also used as a convalescent splint in the treatment of hip disease.

time; in fact, several months may elapse before the full range of motion is regained.

It is well, also, to remove the thoracic part of the brace to allow the patient more mobility at the hip. At a later time the traction may be discontinued and the brace may be suspended from the shoulders to serve as a perineal crutch (Fig. 230); or it may be attached to the shoe and so adjusted as to be slightly longer than the limb, in order that direct concussion and pressure may be lessened (Fig. 229). Or a brace jointed at the knee, after the Taylor pattern, may be employed.

This brace is so adjusted as to be slightly longer than the limb, so that the heel does not touch the bottom of the shoe (Fig. 232). Thus the weight is in great part supported on the perineal band. The weight of the brace may be in part supported and incidentally

FIG. 231. FIG. 232.

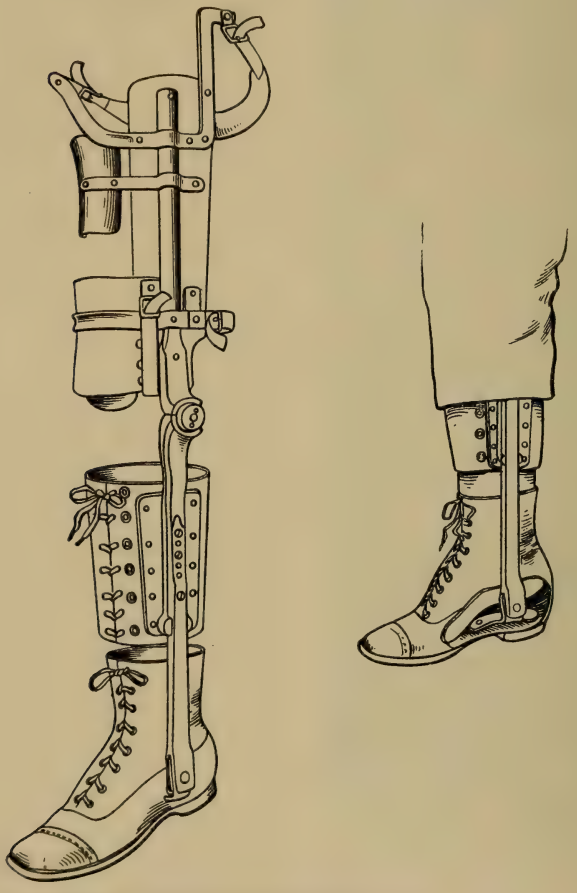

Convalescent hip splint, allowing motion at the knee. (Taylor.)

slight traction may be exerted by adhesive plaster applied above the knee (Fig. 233). The foot plate, to which the upright is attached, is shown in Figs. 232 and 234.

As the strain upon the part is increased, one watches carefully for the return of muscular spasm or for restriction of the range of motion. If the range of motion does not diminish, and if the deformity that may be present does not increase or does not

appear if it were absent, the brace may be removed at intervals and finally discarded.

As has been stated, the short spica after the Lorenz model is an admirable support during the period of recovery. It prevents motion at the joint, yet it permits the function of support, and thus a gradual rebuilding of the bony structure which has become atrophied during the course of the disease. By means of this

FIG. 233. FIG. 234. FIG. 235.

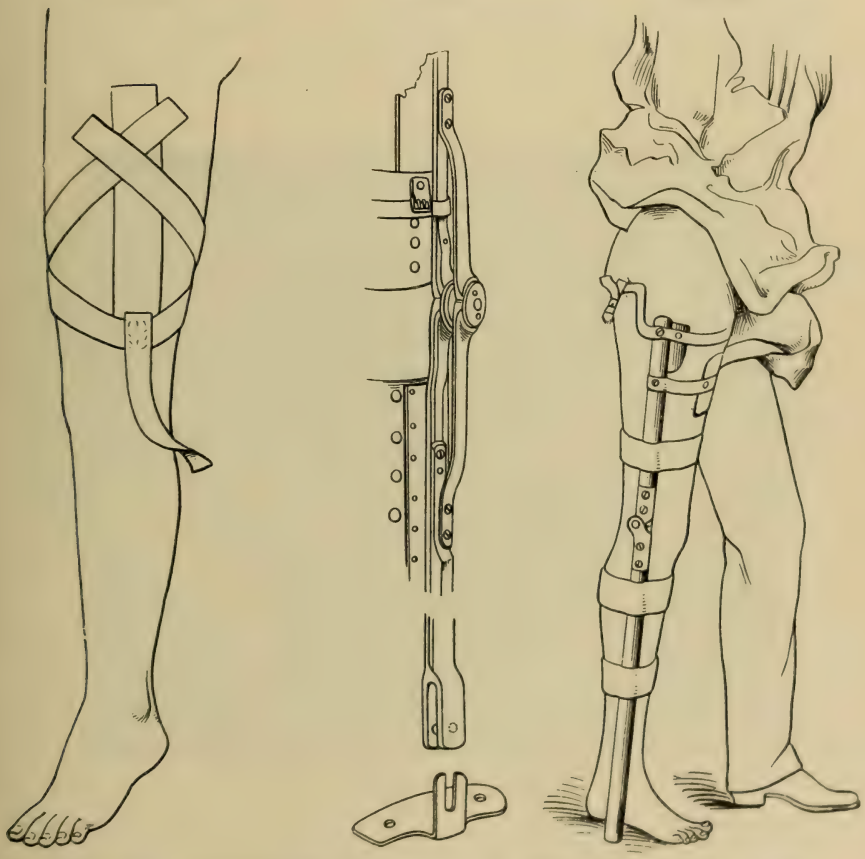

Details of the Taylor convalescent hip brace. Fig. 233, the adhesive plaster. Fig. 234, the foot plate showing the method of attachment.

The action of the Taylor convalescent hip brace in removing direct pressure illustrated by wooden model.

appliance the limb may be held in the desired position of slight abduction, and it is particularly effective when the limb, because of destructive changes in the joint, is inclined toward adduction. It should be stated that the long-continued fixation of the limb combined with traction may induce laxity of the ligaments and

hyperextension at the knee, unless it is properly supported by the posterior thigh band. In the cases in which the atrophy is extreme and in which this laxity is present the splint may be discarded in favor of the fixation bandage with advantage (Fig. 231).

This period of supervision even in favorable cases should be protracted, for no patient can be considered free from the danger of relapse for a long time after apparent cure. If there is firm bony anchylosis, as in exceptional cases, cure is assured; but if there is simple fibrous anchylosis, and particularly if there is upward displacement of the trochanter, there is a strong ten-

FIG. 236.

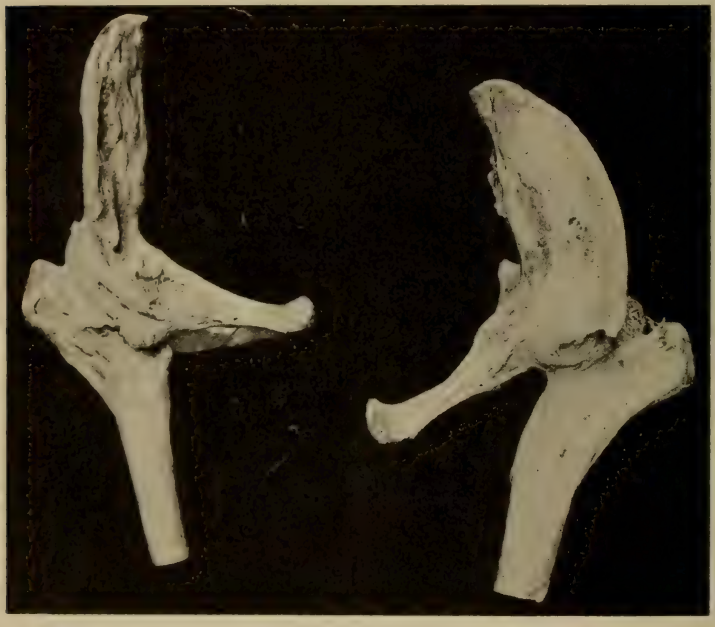

Double hip disease, terminating in bony anchylosis.

dency toward flexion and adduction, even though the disease is cured. In such cases it is often necessary to employ apparatus at intervals to reduce the deformity or to hold the limb in proper position until stability is assured. When the brace has been discarded, the patient should be trained to walk with equal steps, placing the limb, as far as possible, on an equality with its fellow and adapting in like manner the stronger to the weaker member.

This has an important influence in checking the tendency to

deformity and in modifying, or even concealing, the limp, a point to which Judson has repeatedly called attention.

Bilateral Hip Disease.

Ninety-five cases of bilateral hip disease were treated in the Hospital for Ruptured and Crippled during a period of ten years ending in 1899.

As a rule, the second hip is affected some time after the symptoms of disease of the first have been apparent, but occasionally both joints are involved simultaneously. In most instances the symptoms are rather subacute, owing, very likely, to the fact that the activity of the patient is so restricted.

FIG. 237.

Left hip disease, showing swelling caused by abscess, also the absence of flexion deformity.

Treatment. The treatment is similar in principle to that of the unilateral form. The patient during the greater part of the course of the disease must be confined in the recumbent position, although not necessarily in bed. The double Thomas hip splint is a convenient means of fixation. With this apparatus extension by means of the weight and pulley may be employed, or the brace may be so modified as to provide independent traction. If the disease of one hip is acute and is attended by abscess formation, excision for the purpose of lessening the strain upon the patient may be advisable.

If motion is greatly restricted in both joints locomotion unless crutches are used is very difficult, as motion at the knees can supply only in small part the function of the hip-joints. In such instances excision of one hip in the hope of obtaining a certain amount of motion may be considered.

Hip Disease Combined with Disease of Other Parts.

The most common combination is with Pott's disease. The two processes may be primarily distinct, but occasionally it would appear that the disease of the hip is caused by the infection of an abscess, which, coming from the spine, remains for a long time in contact with the capsule of the joint. In five of one hundred and fifty cases of disease of the hip-joint of which the final results were reported by Gibney, Waterman, and Reynolds (page 387), Pott's disease was a complication, in two instances preceding and in three following the disease at the hip. The combination of the two diseases makes the mechanical treatment difficult. Recumbency offers the best opportunity for the effective adjustment of apparatus when the disease of either part is acute. At a later period crutches may be employed, together with the necessary braces.

FIG. 238.

Untreated hip disease. Slight flexion and adduction (apparent shortening). The scar of a former abscess is seen on the outer aspect of the thigh.

Hip Disease in Infancy.

Hip disease in infancy is far less common than in early childhood. It presents nothing of special interest except that its effect upon the function of the joint and upon the development of the limb is usually more marked than in older subjects. Tuberculous disease of this joint must be differentiated from infectious epiphysitis, in which prompt operative treatment is indicated. A modified Thomas brace is most efficient in treatment (Fig. 208).

Hip Disease in the Adult.

Hip disease in the adult may present the typical symptoms of the ordinary form, but it is usually of the more subacute type. Not infrequently it is a complication of tuberculosis of the lungs.

The subacute form of tuberculous disease is often difficult to distinguish from osteoarthritis, if this is confined to the hip-joint. Gonorrhœal arthritis and impacted fracture of the neck of the femur may be mentioned also in differential diagnosis. The mechanical treatment is not difficult, but in many instances early excision may be advisable in order to bring about a rapid cure of the disease. This is far more important than in childhood, because few adults can afford the time required for the natural cure, and because in many instances the general condition of the patient may demand relief from the depressing effects of the local disease, especially if it be complicated by suppuration.

Abscess in Hip Disease.

It may be assumed that a limited collection of the fluid products of the tuberculous process is present in nearly every case of hip disease in which the joint surfaces are actually involved. In many instances it remains within the joint. In a larger proportion of the cases the capsule is perforated, the fluid escapes, and, if the quantity is sufficient to form an appreciable tumor, it is classed as an abscess. Such abscesses may be detected in about 50 per cent. of the cases that are treated under ordinary conditions.

In 1370 final results collected from various sources the percentage of abscess was as appears in the following table:

39	cases reported by Shaffer and Lovett[1]	. . . . .	69 per cent.
82	" " " Gibney[2]	. . . . .	60 "
390	" " " Bruns,[3] Tübingen	. . . . .	58.3 "
568	" " " Koenig,[4] Göttingen	. . . . .	56.5 "
125	" " " Sasse,[5] Berlin	. . . . .	50 "
82	" " " Prendlsburger,[6] Vienna	. . . . .	51 "
84	" in private practice, C. F. Taylor[7]	. . . .	25 "

Most often the abscess first appears upon the anterior and upper part of the thigh, in the space between the sartorius and

[1] New York Medical Journal, May 21, 1887.
[2] New York Medical Record, March 2, 1878.
[3] Beit. zur klin. Chir., 1895, Bd. xxx.
[4] Die Spec. Tuberculose der Knoch u. Gelenke, Berlin, 1992.
[5] Arbeit aus der Chir. klinik der K. Univ. Berlin (Bergmann's clinic), 1896.
[6] Behand. der Gelenktuberculose und ihre Endresultate aus der klinik Albert, Wien, 1896.
[7] Boston Medical and Surgical Journal, March 6, 1879.

tensor vaginæ femoris muscles. In other instances it may be detected first on the inner side of the thigh, or it may form a tumor beneath the gluteal muscles, its situation being influenced by the point at which the capsule is ruptured.

In rare instances the acetabulum may be perforated and a pelvic abscess may be formed, or the pus may find its way into the pelvis along the iliopsoas muscle; and occasionally a pelvic abscess may exist which appears to have no direct communication with the joint.

According to Koenig[1] the weakest point of the capsule is in the anterior wall, where it is covered by the iliopsoas muscle and by its bursa, which often communicate with the joint. A second weak place is in the posterior wall.

In a total of 321 abscesses in hip disease recorded by Koenig the situation was as follows:

On the inner side (inside the femoral artery)	26
Front of the joint (between artery and anterior superior spine)	126
Region of the trochanter	63
Posterior surface	49
In the pelvis	41
In other situations	16

The tuberculous abscess is a symptom and common accompaniment of hip disease, which, in cases treated under proper conditions, is not of great importance; and yet, on the other hand, it

FIG. 239.

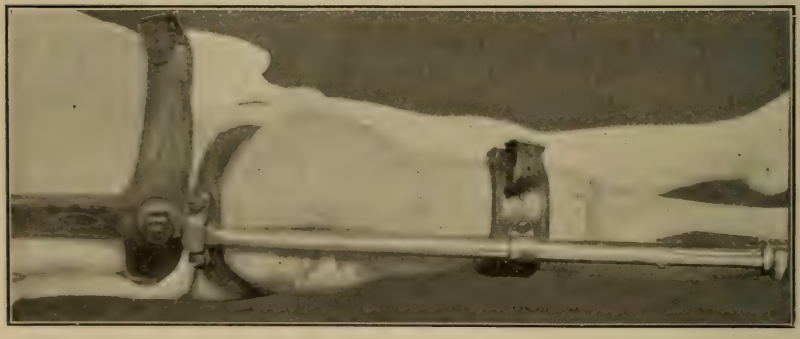

Abscess in hip disease. The brace is provided with the Thomas ring and with the ratchet extension.

is recognized as a dangerous complication. It is dangerous to life because of the profuse suppuration that may follow infection, and to function because of the adhesions and contractions that

[1] Loc. cit.

may result. This is evident in all statistics. It is clearly shown in those of Bruns. In this list the mortality in the non-suppurative cases was 23 per cent., and of the suppurative 52 per cent.

The Significance of Abscess. If abscess appears early in the course of the disease, it usually indicates that it is of a destructive character, and that the interior of the joint is involved; therefore, perfect function is less likely to be preserved than in those cases in which the disease has been confined to the interior of the bone.

Abscess formation is often preceded by an acute exacerbation of symptoms, by pain, by an increase of muscular spasm and consequent distortion, and often by an elevation of temperature. These acute symptoms subside and a fluctuating swelling appears. It may be inferred that the pain in such a case was due to the tension of the abscess within the capsule, and that the relief of pain followed perforation and the escape of the fluid.

In perhaps the larger proportion of cases, more especially those in which the joint has been protected, the formation of the abscess is not preceded by acute symptoms, such as have been described. Its appearance is long delayed, and but for the swelling its presence would not be suspected.

As the progress of the disease is influenced by the strain and injury to which the part is subjected, so abscess, a symptom of disease, is more common in those cases in which early and efficient treatment has been neglected; for the same reason its subsequent course is directly influenced by the protection that the diseased joint receives.

The danger from abscess is, of course, infection. Occasionally the abscess may become infected before an opening forms. Such infection may be inferred when the tissues about the abscess are hot and sensitive, and when fever is present; but, as a rule, the abscess is sterile until the skin is perforated. If the abscess sac is small and if drainage is efficient, and especially if communication with the joint has been occluded, infection is of slight consequence. But if before the opening has formed the abscess has perforated intermuscular fasciæ and has extended between the layers of muscles in various directions, infection is likely to cause severe local and constitutional symptoms. The thigh becomes the seat of an infectious cellulitis, pockets of pus form, which cannot be properly drained; hectic, emaciation, and loss of appetite follow, and if the profuse discharge of pus persists amyloid

degeneration of the internal organs may result. Such patients are said to die of exhaustion but the cause of exhaustion is an infected abscess.

Treatment. Admitting that abscess is a symptom whose importance stands in direct relation to the care that has been exercised in the treatment of the disease, and that in the better class of cases the danger from this source is slight, still it is also true that abscess is the chief cause of danger, and almost the only cause of death, in hip disease *per se*. One's views as to the treatment are likely to be influenced by the class of cases with which he is most familiar. Some surgeons have advocated absolute non-interference with the symptomatic abscess on the ground that in many instances it finally disappears by spontaneous absorption, while in other cases the long delay allows the communication with the joint to close, so that the danger of infection after an opening has formed is slight. Finally, that the results after non-interference are better than those reported after operative treatment. Others insist that all collections of fluid of this character should be evacuated as soon as they are discovered, because of the danger of infection before an opening forms and because of the advantage gained by preventing burrowing of pus. Little could be said against this latter course were it not that infection is as common after operative treatment as when a spontaneous opening forms; the only advantage in favor of the artificial opening being that the cavity with which it communicates should be smaller and more direct than when the fluid has undermined the tissues in various directions, but this is offset by the fact that at least 20 per cent. of abscesses disappear without treatment. In fact, as compared with indiscriminate incisions, the let-alone treatment should be preferred when proper after-treatment cannot be assured.

It would appear, however, that the middle course, between the extremes, is the safest, and especially so, as by far the larger number of patients must be treated under conditions that do not permit of proper care. In the outdoor department of the Hospital for Ruptured and Crippled abscesses are treated symptomatically. If a swelling appears but remains quiescent and causes no symptoms, it is not disturbed. If it enlarges, the tension of the fluid is relieved by aspiration, which may be repeated as required, compression, after the evacuation of the fluid, being applied by means of a pad and bandage. If the abscess is on the point of opening spontaneously, or if its contents are of such

a nature that aspiration is impossible, an incision is made and the proper dressings are applied; or, if the child lives at a distance from the hospital, the mother is instructed in the manner of dressing and as to the importance of cleanliness.

If the abscess is of large size, or if acute symptoms are present, the child is admitted to the hospital. Here the same general principle is followed, but at the present time the routine of treatment of non-infected abscess is free incision that will allow complete evacuation of its contents. The abscess membrane is removed by gently rubbing with iodoformized gauze. If the opening in the capsule of the joint is exposed, this may be enlarged to permit the evacuation of the products of disease within the joint; at the same time the character and extent of the disease may be ascertained, and foci may be removed if practicable; the wound is then closed with superficial and deep sutures, and a firm dressing is applied. This operation, if performed under aseptic precautions, causes no disturbance, and it relieves nature from the burden of necrotic material which must be an obstacle to spontaneous absorption. In many instances the abscess is permanently cured, although if the condition that induced it remains unchanged fluid will again accumulate, and if so a spontaneous opening will form in the line of the incision. This operation is not a radical cure of the abscess or of the disease; it is simply a means of thorough evacuation for the purpose primarily of accomplishing what the aspirator does only in part. If the abscess has become infected its contents are completely removed, the wound is then packed with gauze, and provision is made for efficient drainage.

In the treatment of abscesses the injection of iodoform emulsion, in connection with the aspiration or incision has been thoroughly tested. The results, as far as the disappearance of the abscess was concerned, were not as good as from simple aspiration; and as the procedure, being somewhat of the nature of an operation, caused the patients some discomfort and anxiety, it was discontinued. From the clinical standpoint there is little evidence that these injections exercise any particular influence upon the disease, but, theoretically, iodoform should lessen the infectiousness of the tuberculous fluid, and by local irritation stimulate the growth of granulation tissue. There appears to be no serious objection to its use.

The Treatment of Sinuses. When the disease is active the sinuses that serve as drains should not be interfered with. And

in the advanced cases when the disease is quiescent and when the tissues about the joint are of the peculiar, resistant, "porky" consistency, active measures, either for the purpose of closing sinuses or for the correction of deformity, should be deferred. In many instances, however, sinuses persist as tuberculous fistulæ, serving no useful purpose. In this class the complete removal of the infected tissue by excision or by thorough curetting is the most effective remedy. The various applications of pure carbolic acid, solution of salicylic acid, iodoform emulsion, balsam of Peru, and the like are of some service, but thorough removal of the disease is the only radical treatment.

Exploratory Operations. In certain instances exploratory operations may be indicated. If, for example, pain and swelling indicate tension within the capsule it may be relieved by an incision and the joint may be explored with the possibility of finding a localized focus of disease that may be removed.

The joint may be opened by an anterolateral incision, beginning one inch to the outer side of the anterior superior spine and extending downward about three inches. This exposes the line of junction between the tensor vaginæ femoris and the gluteus medius muscles. When these are separated from one another the anterior surface of the capsule of the joint is laid bare. If more room is required the tensor vaginæ femoris muscle may be divided. The capsule is then incised in the line of the neck and through the incision the head of the bone may be extruded by rotating the limb outward and extending it. By this means the character of the disease may be ascertained and in certain instances localized foci in the neck or in the head of the bone may be removed. The wound is then closed or drained as may seem advisable. By such intervention the course of the disease may be shortened, although cure by this means is unusual.

Temporary anterior dislocation of the head of the femur by means of the anterolateral incision may be of value in acute and painful disease. Posterior dislocation for this purpose has been performed by Bradford in several cases with satisfactory results, the bone being again replaced when the disease had become quiescent.[1] The object of this operation is to remove the opposing bones from direct contact, and to relieve the muscular spasm that accompanies acute disease.

Exploratory operations also may be of special value in the

[1] Transactions of the American Orthopedic Association, vol. xiii.

later stages of the disease, to ascertain the cause of long-continued suppuration, or of abnormal delay in repair, which may be due to detached or adherent fragments of necrosed bone within the joint. This point is illustrated by the statistics of 61 cases of hip disease treated by excision by Poor.[1] In 15 of these loose bone was found in the joint, and in 7 the head of the bone was detached.

In 98 cases investigated by Lehman[2] at the Würzburg Clinic sequestra were present in 20.4 per cent., and in 70 per cent. of 88 cases treated by Riedel.[3]

An exploration of the joint by one familiar with surgical technique should be free from danger, and it may be of much value.

Excision of the Hip. The operation of excision is now classed as a treatment of necessity in certain cases, usually those in which recovery under conservative treatment is considered very doubtful. For example, when there is progressive failure in health ; when it is impossible to drain the joint effectively after infection ; when there is evidence of extension of the disease to the shaft of the femur or to the pelvic cavity, or when other serious complications exist.

In certain instances the excision may follow an exploratory operation ; in such cases the anterolateral incision may be employed and the neck and head of the bone only may be removed. In this operation the diseased tissue is removed as thoroughly as possible with the sharp spoon, by scrubbing with iodoformized gauze, and by flushing with hot water. If the joint is not infected it is dried ; iodoform emulsion may be injected or the pure carbolic acid may be applied, and the various tissues are then sewed in layers ; pressure is applied, the aim being to secure immediate union. If this does not take place drainage is employed in the usual manner.

In typical cases the operation is performed because of extensive disease and infected abscess, and in such instances the entire upper extremity of the bone to the trochanter minor is removed.

A satisfactory method is that of Koenig.

An incision about five inches in length is made in a line joining the trochanter and the posterior inferior spine of the ilium. About two-thirds of the length is above and one-third over the trochanter. The incision is deepened to expose the capsule and the

[1] New York Medical Journal, April 23, 1892.
[2] Inaug. Diss., Würzburg, 1890.
[3] Centralbl. f. Chir., 1893, Bd. xx., Nos. 7 and 8.

surface of the trochanter, from which one removes the insertion of the gluteus maximus and the tendons of the medius and minimus. The muscles are separated in the line of the incision and the capsule is widely opened. With a thick, strong knife one separates all the muscular attachments to the anterior margin of the trochanter, while the limb is rotated outward, removing, if possible, a thin section of periosteum and bone. The same process is then repeated on the posterior surface, the limb being rotated inward. The trochanter is then removed.

The acetabular insertion of the capsule, together with the adjoining upper border of the acetabulum, is then cut away and the neck of the femur is separated from the shaft with a saw or chisel. All the diseased parts are then removed, including the acetabular wall and adjoining bone, if necessary. The wound is partly closed with drainage, and the extremity of the femur is placed within the acetabulum, where it should be retained for a time by a plaster bandage or Thomas brace provided with traction straps. When the patient begins to walk a hip splint or other support is used for a time to prevent deformity. One of the most efficient supports of this class is the short or Lorenz spica, the limb being fixed in an attitude of overextension and moderate abduction for many months.

The success or failure of excision of the hip as a life-saving operation, provided the diseased bone has been removed, is decided by the after-treatment, and in this, drainage is the great essential. The opening must be large and the shaft of the bone must be drawn down by efficient traction, so that it may not obstruct the opening, and the exuberant granulation must be removed from time to time. Phelps has introduced a valuable adjunct in the use of short, glass drainage tubes of large diameter, even up to one and one-half inches. Through such a tube or speculum the gauze is inserted, the opening permitting thorough inspection.

The importance of an open-air life after these operations can hardly be exaggerated. The lack of this, the inefficiency of the after-treatment in securing proper drainage, and the postponement of the operation until amyloid changes are advanced explain the unsatisfactory character of the results.

The functional results after excision in this class of cases are not as good as those that may be obtained when the operation has been performed at an earlier period. If motion continues free the joint is usually insecure. In many instances there is upward

displacement of the shaft of the femur upon the ilium with consequent flexion and adduction deformity, while in a third class of cases a movable joint of sufficient strength may be preserved. The ultimate shortening is considerably greater than after conservative treatment. This is accounted for by the upward displacement of the femur and by the removal of the two epiphyses of its upper extremity.

In a period of twelve years, 1888 to 1899, inclusive, 149 operations of excision were performed at the Hospital for Ruptured and Crippled. During this time 1283 cases of hip disease were treated in the wards and 1870 new cases were recorded in the out-patient department. Thus the operation was performed in 11.6 per cent. of those in the hospital, but the relative frequency of the operation in the entire number of patients under treatment was considerably less than this.

One hundred and twenty-one of these operations of excision, or those performed prior to 1897, have been carefully analyzed by Townsend.[1] The 121 operations were performed on 119 patients, in two instances both hips having been operated upon. In 113 abscesses or sinuses were present, in most instances infected. In 5 cases the spine was involved as well as the hip; in 2 instances the knee; in 2 the tarsus; in 3 the ilium. In 24 cases the anterior incision was employed, in 97 the posterior. In 18 instances the acetabulum was seriously diseased, and in 10 osteomyelitis of the shaft of the femur was present. This indicates the character of the disease in the cases operated upon.

In 99 of the 119 cases the later results of the operation were ascertained. Of these 52 were dead and 47 were living. Of the 52 deaths 9 were due directly to the operation, shock; 28 were caused by exhaustion (persistent suppuration); 9 by tuberculous meningitis; 7 by other causes. Thirty-seven deaths occurred within six months and 10 others within one year of the operation. Of the 47 patients living at the time of the investigation, 26 were cured. Of the remaining number about one-half were in poor condition, so that recovery could not be expected. It is evident that in a large proportion of the cases the operation was unsuccessful as a life-saving measure, since suppuration persisted.

The functional results in these cases are shown in the following table:

[1] Medical News, June 26, 1897.

TABLE SHOWING SHORTENING, MOTION, NUMBER OF SINUSES PRESENT, AND ANGLE OF GREATEST EXTENSION IN FORTY-SEVEN CASES OF EXCISION. (TOWNSEND.)

No.	Time since operation.	General condition.	Sinuses present.	Angle of greatest extension.	Motion in degrees.	Shortening in inches.
1	6¾ years	Good	3	150	0	2½
2	6¼ "	Fair	1	135	0	4
3	6 "	Good	0	180	100	3
4	5¾ "	"	0	180	35	3
5	5¼ "	Fair	0	145	10	4
6	5½ "	Good	1	165	0	1¼
7	5 "	"	0	155	5	2½
8	4¾ "	"	3	160	0	2½
9	4½ "	"	0	160	0	2¾
10	4¼ "	"	0	165	0	1¼
11	4 "	"	0	150	0	1½
12	4 "	Poor	4	...	0	1½
13	3½ "	Good	0	155	0	1½
14	3½ "	"	0	160	30	1
15	3 "	Poor	1	165	0	¾
16	2 "	Fair	2	145	30	¾
17	2 "	Good				
18	2 "	Fair	1	170	0	½
19	2 "	Good	0	150	0	3
20	1¾ "	"	0	175	..	½
21	1¾ "	"	0	165	30	½
22	1½ "	"	0	150	0	1
23	1½ "	"	0	150	0	1½
24	1¼ "	"	1	180	0	½
25	1¼ "	Fair	6	175	15	1
26	1 "	Poor	2	165	0	2½
27	1 "	Good	0	170	0	1½
28	1 "	"	0	155	0	1
29	1 "	"	0	175	0	½
30	1 "	Poor	0	180	10	1¼
31	11 months	"	3	170	0	¼
32	10 "	"	0	180	40	1¼
33	10 "	Good	3	165	0	½
34	10 "	"	0	160	0	½
35	10 "	"	1	165	0	1
36	10 "	Poor	1	160	0	¼
37	10 "	Good	3	155	10	1¼
38	9 "	"	1	...	0	½
39	9 "	"	0	...	...	½
40	9 "	Poor	1	170	0	½
41	9 "	Fair	3	...	...	1
42	8 "	Good	0	180	130	½
43	8 "	"	0	180	...	¼
44	8 "	Poor	1	165	10	¾
45	7 "	"				
46	7 "	Good	0	180	10	1¼
47	7 "	"	0	160	70	¼

Lovett[1] has reported the results of 50 excisions in a similar class of cases at the Boston Children's Hospital, 1877 to 1895. The number of patients actually treated in the wards of the hospital is not stated, but 1100 cases were recorded as having been under treatment during this time, a percentage of excisions of 4.5 of the total number. In 8 of the cases osteomyelitis of the femur was present, and in 15 the acetabulum was perforated. The ultimate mortality was about 50 per cent.

Poor[2] has reported the results in 65 cases operated upon at St.

[1] Transactions American Orthopedic Association, vol. x.
[2] New York Medical Journal, April 23, 1892.

Mary's Hospital, New York, with a final mortality of about 43 per cent. In 21 cases osteomyelitis of the shaft of the femur was present. In 11 cases there was perforation of the acetabulum, and in 9 of these the opening communicated with an intrapelvic abscess.

These statistics are quoted to illustrate the relative efficiency of late excision. The extent of the lesions in some of the cases shows that recovery would have been impossible without operation, and its failure to relieve the symptoms in so many instances is sufficient evidence that it was postponed too long. Under proper conditions for treatment excision of the hip is almost never required, but in hospital practice it should be performed oftener and earlier in the course of the disease.

Amputation. Amputation at the hip should follow excision when suppuration persists and when the condition of the patient does not improve, provided the internal organs are not hopelessly diseased. The operation of amputation after complete excision is a simple procedure and it should not be attended with great danger.

Reduction of Deformity in Resistant Cases. The various methods of reducing deformity during the active stages of the disease have been described, and the importance of preventing deformity throughout the entire course of treatment has been insisted on. At the present time, for one reason or another, deformity from this cause is very common, either because its importance is not appreciated or because it is considered as a necessary concomitant of the disease, treated by apparatus, as it is in the natural cure. At all events, in many instances it is allowed to persist until the accommodative changes about the diseased joint have so fixed the limb in the deformed position that greater correcting force is required than can be applied by the weight and pulley or by other method of traction.

In this class of cases, in which the muscles are structurally shortened and in part transformed to fibrous tissue, and in which the anterior wall of the capsule has become retracted and it may be adherent to the surrounding parts, forcible reduction under anæsthesia, or osteotomy, may be required. If the disease is quiescent or cured, if the head of the femur or what remains of it is in the normal position, and if a fair range of motion remains, gradual forcible reduction, after division of the bands of fascia or the muscles that hold the limb in the deformed position, is advisable.

In all cases in which the head of the articulation is destroyed

the aim should be to secure an anterior transposition of the upper extremity of the femur, and to secure this result one proceeds as in reducing or transposing the congenitally displaced hip—by longitudinal traction, by forcible abduction, combined with massage of the adductors, and, finally, by gradual extension—preceded usually by division of the resistant parts about the

FIG. 240.

Extreme deformity after hip disease, showing the attitude before operation. (See Figs. 241 and 242.)

anterior superior spine. The limb is then fixed by a Lorenz spica in an attitude of moderate abduction and overextension. Later the abduction is lessened by the overextended position ; this is maintained for many months, and is assured by passive movements after the support is removed. Forcible reduction in cured or quiescent cases is practically free from danger.

The Correction of Deformity by Femoral Osteotomy. If the deformity is fixed by bony anchylosis or by firm, fibrous adhesions within the joint ; or if it is feared that violence may stimulate

dormant disease; or if there is such a degree of upward displacement of the femur upon the pelvis that the deformity is likely to recur after replacement, it is better to correct the deformity by an osteotomy of the femur.

The patient having been prepared for operation, is turned upon the side and a sand-bag is placed between the thighs. A small osteotome, about the shape of a lead-pencil, of which one extremity is flattened to a cutting edge (Vance's instrument), is pushed directly through the soft parts to the femur at a point about two inches below the apex of the trochanter. It is turned until its cutting edge is at the right angle to the shaft and it is then driven through the cortical substance of the bone. When it has penetrated at one point it is withdrawn, and adjoining portions are cut until about half the circumference is divided, when with

FIG. 241.

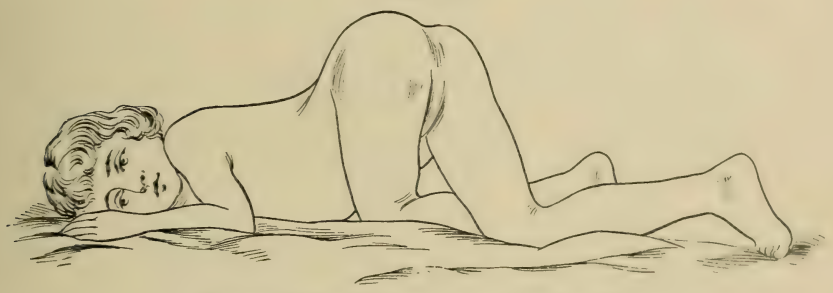

The favorite attitude in recumbency. (See Fig. 240.)

slight force the bone may be fractured. If the deformity is of long standing, division of the contracted tissues in the adductor region and below the anterior superior spine may be required.

The limb is then drawn down to complete extension and moderate abduction, and the body and limb are encased in a plaster-of-Paris spica bandage, which should remain in position for several months, although the patient may be allowed to bear weight on the limb in a few weeks after the operation. The long may be replaced by the short spica at the end of two months. This latter or some similar appliance should be used until tests show that there is no longer danger of recurrence of the deformity.

The advantages of the subcutaneous method are simplicity and freedom from danger. No dressings are required, except a pad of gauze over the minute opening, thus the limb may be firmly held by the plaster bandage. If there is anchylosis between the femur and the pelvis no support will be required after the bone

has united, but if there is motion in the joint some fixative appliance should be employed for a time to prevent recurrence of a part of the deformity.

Prognosis. Mortality. The direct mortality of hip disease is due almost entirely to the immediate or remote effects of abscess. This is illustrated by the statistics of Bruns, in which the mortality from all causes of the non-suppurative cases was 23 per cent. as compared with 52 per cent. in those in which suppuration was present.

FIG. 242.



After correction by osteotomy and division of the contracted tissues. (Gibney.) (See Figs. 240 and 241.)

The mortality among the patients treated at many of the German clinics is much higher than in the corresponding class in this country.

At Tübingen, according to Wagner,[1] it was 40 per cent.

At Kiel, according to Mummelthy, it was 48.59 per cent. in non-operative cases and 53.96 per cent. in operative cases.

At Marburg, according to Marsch, it was 35 per cent. in non-operative cases and 40.4 per cent. in operative cases.

At Heidelberg, according to Huismans,[2] it was 46.6 per cent. in non-operative cases and 58 per cent. in operative cases.

At Zurich, according to Pedolin,[3] it was 37.7 per cent. in non-operative cases and 54 per cent. in operative cases.

At Vienna, according to Prendlsburger,[4] it was 17 per cent. in all classes.

At Göttingen, according to Koenig,[5] 40.3 per cent.

In a total of 636 cases treated by conservative methods by Rabl, 1859 to 1894, definite results were ascertained in 519;[6]

[1] Beit. z. klin. Chir., 1895, Bd. xiii.
[2] Quoted by Binder, Zeits. f. Orthop. Chir., 1889, Bd. vii. H. 2 and 3.
[3] Centralbl f. Chir., July 25, 1896, No. 30.
[4] Loc. cit.
[5] Koenig. Das Hoeftgelenk, Berlin, 1902.
[6] Zur Conserv. Behand. der tuberculosen Knochen und Gelenksleiden, J. Rabl, Leipzig und Wien, 1895.

335 were hospital cases. Of these 216 were cured, 64.4 per cent.; 70 died, 20.8 per cent., and 49, 14.4 per cent., were still under treatment; 184 were treated as out-patients. Of these, 132 were cured, 71.5 per cent.; 35 died, 19.2 per cent., and 17, 92 per cent., remained under treatment.

In 288 cases treated at the Hospital for Ruptured and Crippled, New York, reported by Gibney,[1] the death-rate was 12.5 per cent.

In private practice the statistical reports of final results show the death-rate to be extremely small. C. F. Taylor,[2] 94 cases, including 24 in which suppuration was presented, 3 deaths. L. A. Sayre,[3] 212 cases, 5 deaths. Lorenz,[4] 60 cases, with 3 deaths.

In the clinics of this country the death-rate has been estimated to be from 10 to 15 per cent., a rate of mortality much lower than that reported from those abroad. This is accounted for in part by the fact that patients are of a better class and in part because they receive earlier and more efficient mechanical protection.

The causes of death, according to Wagner's statistics of 124 cases, were as follows:

Hip disease	35
General tuberculosis	37
Tuberculous meningitis	13
Tuberculosis of the lungs	11
Acute miliary tuberculosis	5
Amyloid degeneration	8
Septic infection	12
Intercurrent disease	3
	124

Thirty per cent. of the deaths occurred in the first year of the disease, 26 per cent. in the second year, and 20.4 per cent. in the third year.

The percentage of recovery was 65 per cent. of those in the first decade of life, 56 per cent. of those in the second, and but 28 per cent. of those in the third decade.

The causes of death in 50 cases among 778 patients treated at the New York Orthopedic Dispensary and Hospital during the years 1877 to 1882 were:[5]

[1] New York Medical Journal, July and August, 1877.
[2] Boston Medical and Surgical Journal, March 6, 1879.
[3] New York Medical Journal, April 30, 1892.
[4] Wiener Klinik, 1892, 10 and 11.
[5] Shaffer and Lovett. New York Medical Journal, May 21, 1887.

Tuberculous meningitis	20
Amyloid degeneration	5
Exhaustion	3
Tuberculosis of the lungs	3
Tuberculous peritonitis	1
Septicæmia	1
Convulsions	1
Unknown	16
	50

Of 96 deaths recorded at the Alexandra Hospital, London (a mortality of about 26 per cent. of the cases treated), the causes were

Tuberculous meningitis	16.1 per ct.
Albuminuria and dropsy	20.8 "
Tuberculosis of the lungs	8.3 "
Exhaustion	9.4 "
Erysipelas and pyæmia	3.1 "
After operation	9.4 "
Intercurrent diseases	7.3 "
Unknown	25.0 "
	100.0 "

The direct mortality of hip disease should include all deaths due to operation, those caused by exhaustion and amyloid degeneration, which is almost always the result of profuse suppuration secondary to pyogenic infection. Tuberculous meningitis, a common and apparently an unavoidable cause of death, is not necessarily a complication of the local disease, except in so far as a lowered vitality may predispose the patient to it, since it may have been due to new infection or induced by the primary focus which preceded the tuberculosis of the hip.

It is believed that operative interference is sometimes the direct cause of tuberculous meningitis, and it is of interest in this connection to note that 20 of 50 deaths, or, rather of 34, in which the cause of death was known, 58 per cent. were due to this complication among the cases treated at the New York Orthopedic Dispensary and Hospital, where no operations were performed.[1] While of 52 deaths in a total of 99 cases treated at the Hospital for Ruptured and Crippled, in which excision was performed, but 9 were caused by tuberculous meningitis.[2]

The normal death-rate among cases under fair hygienic conditions is illustrated by statistics from the Hospital for Ruptured and Crippled at a time when no operative or mechanical treatment was employed.[3] This was 12.5 per cent.; 4.5 per cent. from exhaustion, 4.5 per cent. from amyloid degeneration, 1.75

[1] Shaffer and Lovett. New York Medical Journal, May 21, 1887.
[2] Townsend. Medical News, June 26, 1896.
[3] Gibney. New York Medical Record, March 2, 1878.

per cent. from tuberculous meningitis, 1.75 per cent. from intercurrent diseases.

Thus nearly 75 per cent. of the deaths were due more or less directly to suppuration.

Functional Results. In a certain proportion of cases perfect function may be retained, the proportion depending upon the extent of the disease, and upon the timeliness and efficiency of the treatment.

In a total of 280 cases from the private practice of Dr. L. A. Sayre,[1] in which the final results were known, 73, or 26 per cent., recovered with perfect motion, and 120, or 42 per cent., retained good motion. These results are extraordinarily good, very much better than any others that have been reported, and, of course, far better than may be expected in the ordinary class of cases.

The effect of mechanical treatment and of the various measures employed for the correction of deformity is well illustrated in two series of ultimate results in cases treated at the Hospital for Ruptured and Crippled, reported by Gibney.[2] In the first series of 80 cases no mechanical or operative measures were employed, the treatment being simply hygienic and symptomatic; the results, therefore, represent natural cure under proper supervision. The duration of the disease was three years in 23; three to six years in 28; six to ten years in 16, and fifteen years in one case.

In 35 cases the shortening was two inches or more, and in nearly every case there was more or less deformity, viz.:

In	2	there was flexion to	. . . . .	90°
"	3	" " "	. . . . .	110
"	3	" " "	. . . . .	120
"	19	" " "	. . . . .	135
"	19	" " "	. . . . .	145
"	18	" " "	. . . . .	150
"	11	" " "	. . . . .	160-170

In 4 no estimate was made. Distortions other than flexion are not specified.

In 12 instances motion was retained of from 15 to 90 degrees.

In the second series[3] of 107 cured cases mechanical and operative treatment was employed, although the protection assured was in many instances far from efficient. In many of these cases the disease was in an advanced stage, and deformity was present

[1] New York Medical Journal, April 30, 1892.

[2] Gibney, Waterman, and Reynolds. Trans. Amer. Orth. Assoc., 1895, vol. x.

[3] Loc. cit.

in more than half of the number when treatment was begun, and yet all of them recovered without marked flexion and presumably without adduction, as this deformity is not mentioned.

No flexion	47
Flexion of 10°	30
" of 10–20°	20
" of 20–30°	10
Perfect motion was retained in	13
Good " " " "	22
Limited " " " "	41
There was anchylosis in	31

In 69 cases the shortening was one inch or less, 35 having no shortening. In 38 it was more than one inch.

As has been stated, the mechanical treatment in these cases was not sufficiently effective to prevent deformity, and to attain these results osteotomy with or without division of contracted tissues was performed in 19 cases, forcible correction with or without tenotomy in 30 cases, and in 4 cases the joint was excised.

If the joint has been actually invaded by disease so that a part of its articulating surface has been destroyed, motion must be impeded both in area and quality. In such cases the joint is somewhat weakened, and it is often sensitive, although in many instances not to the extent of interfering seriously with the ability of the patient. In this class discomfort in damp weather or pain on overexertion is experienced, symptoms similar to those complained of by rheumatic subjects.

Simple shortening, due to retardation of growth, unaccompanied by deformity, is of comparatively little importance. Firm anchylosis in a symmetrical position insures a strong and useful limb, the flexibility of the lumbar region compensating for the loss of motion at the joint. In such cases the disability may be very slight, and the effect of the loss of motion may be more apparent in the sitting than in the erect posture, for the patient must, as it were, sit upon his back, an attitude which perceptibly reduces the sitting height.

Flexion, if it be slight, does not cause disability, but flexion of more than 30 degrees increases the lumbar lordosis and makes the buttock prominent, the deformity so characteristic of the natural cure (Fig. 190). Great flexion, for example, of 60 or 90 degrees, causes an exaggerated lordosis which is almost always a source of pain or discomfort to a patient who is obliged to stand much of the time.

Abduction is of no importance unless it be considerable. It

serves in most instances as a compensation for actual shortening of the limb.

Adduction, on the other hand, which necessitates an upward tilting of the pelvis in order to restore the parallelism of the limbs, is the most disastrous of all the distortions since it causes a practical shortening often greater than that due to the destructive effects of the disease.

The motion that is retained after recovery from hip disease is usually considered as the test of successful treatment. This is by no means the fact, for in many instances motion is preserved because the joint is destroyed and because what remains of the upper extremity of the femur is supported by the tissues on the dorsum of the ilium—a form of pathological dislocation.

In such cases deformity is almost always present, and the support is insecure.

Deformity is far more disabling than loss of motion, and the best safeguard against final deformity is to prevent it during treatment, and to retain as far as may be the joint surfaces in proper relation to one another. Whatever motion is preserved will then be of service to the patient, and if anchylosis follows the result may still be classed as good.

Deformities of Other Parts Caused by Hip Disease. Deformities of other parts are sometimes observed as secondary results of hip disease, most often in cases that have not received proper treatment. In the spine an exaggerated *lordosis* as a compensation for flexion is not uncommon, and *lateral curvature* may follow distortion of the pelvis caused by adduction. In the limb *knock-knee* may follow persistent adduction of the thigh, or it may be an effect of laxity of the ligaments without such distortion. Another deformity is *genu recurvatum*. This is apparently caused by long-continued disuse of the limb, and by the use of apparatus in which the knee has not been properly supported. It is supposed to be one of the effects of traction, but it is also observed in cases in which traction has never been employed. In cases in which the muscular atrophy that follows limited motion and long-continued disuse is great, *laxity of the ligaments* of the knee-joint is common, and not infrequently subluxation of the tibia also. A slight degree of *equinus* with accompanying exaggeration of the arch is not uncommon among patients who have been treated by the traction apparatus, in which the foot is pendent and in which the toes are often inclined downward to guide the brace in walking. Practically speaking, all these secondary deformities may

be avoided by proper supervision of the patient during the period of treatment.

As a rule, patients who have recovered from hip disease finally discard all apparatus, or at most use only a cane as a support, and many prefer to walk habitually on the toe rather than to equalize the length of the limbs by a high shoe.

By far the larger number of this class, having accommodated themselves to whatever weakness and distortion may be present, are able to undertake the ordinary occupations of life. Of the patients cured at the New York Orthopedic Dispensary and Hospital in the report already referred to, in whom the final results as regards motion and symmetry were certainly not above the average, it is stated that there was not a single individual who was incapacitated from doing a full day's work at his or her trade or occupation. None used crutches and but one used a cane.

CHAPTER VIII.

NON-TUBERCULOUS AFFECTIONS OF THE HIP-JOINT.

THE relative frequency and importance of the various affections of the hip-joint that cause disability are indicated by the following statistics of Koenig's[1] clinic at Göttingen :

Tuberculous disease	568	= 75 per ct.
Infectious diseases after typhoid fever:		
Scarlatina and the like	110	= + 25 per ct.
Gonorrhœal arthritis	30	
Arthritis deformans	22	
Injuries	11	
Contractions, cause unknown	6	
Coxa vara	5	
Tumors	2	
Pyæmic suppuration	3	
	757	

Several of the affections enumerated are very uncommon in childhood, while injury and coxa vara are relatively more important. Coxa vara and fracture of the neck of the femur in early life are considered in Chapter XV.

Traumatisms at the Hip-joint.

It is probable that injury at the hip-joint, caused by falls or strains, may induce congestion about the epiphyseal cartilage of the head of the femur. In this class of cases there is usually discomfort at night after overexertion, "growing pain," and there may be a limp and restriction of motion. These symptoms may disappear in a few days or they may recur from time to time. If the injury is more severe there may be local sensitiveness and even swelling—synovitis. This congestion, with the lessened local resistance induced by it, may be a predisposing cause of tuberculous disease. It is probable, also, that cases of this type are sometimes mistaken for hip disease and go to swell the number of perfect functional results that are attained by one or another system of treatment.

Treatment. All cases of this class require careful treatment and supervision. Strains or other injuries in young children are

[1] Das Hoeftgelenk, Berlin, 1902.

best treated by a supporting bandage and by rest in bed until the symptoms disappear. If the sensitive condition persists, protective treatment by a brace, preferably the ordinary traction hip splint, or by a short plaster bandage, should be employed, the diagnosis being reserved until it is made clear by the progress of the case. Chronic synovitis of the hip-joint, especially in the adolescent or adult, unless it be a result of severe injury, is usually tuberculous in character.

Fracture of the neck of the femur, epiphyseal separation, and coxa vara are considered in another section.

Acute Infectious Arthritis—Acute Epiphysitis at the Hip-joint.

Acute epiphysitis, caused by infection with pyogenic germs, is not uncommon in infancy and early childhood, and it often passes as a form of acute tuberculous disease. Of fifty-two cases in which but a single joint was involved the hip was affected in twenty-six.[1] In some instances it is induced or favored by injury, in others it is secondary to an infected wound, and it may follow pneumonia or one of the exanthemata. (See page 270.)

Symptoms. The symptoms are of sudden onset, accompanied usually by high fever and prostration. The hip becomes swollen, hot, and sensitive both to motion and pressure.

Treatment. The treatment is early and free incision and efficient drainage, the limb being afterward supported by some form of splint. The suppuration ordinarily persists for several months ; the epiphysis is usually destroyed in whole or in part, and in consequence the joint becomes somewhat loose and flail-like (Fig. 243). Many of these cases seen in later years, but for the history and the scars about the joint, might be mistaken for congenital dislocation. In certain instances the symptoms are less acute and the diagnosis from tuberculous disease can be made positively only after a bacteriological examination of the fluid that may be removed from the joint by aspiration.

In the class of cases in which the disease is confined to one joint and in which the shaft of the bone is not involved, the prognosis is good if the pus is thoroughly evacuated. In twelve cases treated at the Hospital for Ruptured and Crippled there were three deaths.[2] The prognosis as to function under these conditions is much better than in tuberculous disease.

[1] Townsend. American Journal of the Medical Sciences, January, 1890.
[2] Townsend. Loc. cit.

After recovery the joint should be supported for a time to prevent upward displacement. If the head of the femur has been destroyed there is usually upward and backward displacement. This induces flexion and adduction of the limb and great disability. In such cases one should, under anæsthesia, force the femur forward to the neighborhood of the anterior superior spine and to fix it there for a long period by the application of a Lorenz spica bandage applied with the limb in an attitude of abduction and hyperextension. The operation is in detail similar to the Lorenz method for replacing the congenital dislocation. (See Congenital Dislocation of the Hip.)

Subacute Arthritis.

In the forms of arthritis that may complicate infectious diseases several joints are usually involved, and the affection is often subacute in character.

Undoubtedly there are mild cases of infection at the hip-joint terminating in partial or complete recovery without operation. In such cases, which are usually classed as rheumatism, there is usually some infiltration about the hip, flexion deformity, limitation of motion, and pain or discomfort referred to the affected joint. A satisfactory treatment is the application of ichthyol ointment in a strength of about 25 per cent., the joint being fixed by a posterior wire splint or light Thomas hip brace.

Spontaneous Dislocation of the Hip-joint.

If the hip-joint becomes distended with fluid the capsule may be ruptured and sudden displacement may occur.

Degez[1] has collected from literature seventy-nine cases of this character. The displacement occurred in the course of the following diseases :

Typhoid fever	32
Rheumatism	24
Scarlatina	13
Variola	3
Gonorrhœal arthritis	3
Grippe	2
Erysipelas	1
Eruptive fever	1

Such accidents[2] may be guarded against by preventing flexion and adduction of the limb and by evacuation of the fluid that

[1] Revue d'Orthopédie, January 1, 1890.

[2] Graff. Deutsche Zeits. f. Chir., February, 1902.

distends the joint. The femur should be replaced as soon as possible before it has become fixed by adhesions and contractions. Even in this class of cases, in which treatment has been delayed for months, by means of preliminary traction and by the use of manual force, as in the reduction of congenital dislocation, one may succeed in replacing the femur. In cases of long standing the acetabulum is filled with new material, which must be removed by the open method before replacement is possible. As an alternative operation one may force the head of the femur into the anterior position and fix the limb, for several months, in the attitude of extension and abduction. If the outward rotation of the foot is excessive, or if a tendency toward adduction persists, a secondary osteotomy of the shaft below the trochanter minor may be performed. However early, reduction is accomplished, limitation of motion is to be expected, and in many instances absolute anchylosis. On this account the limb should be supported for a time in proper position in order to prevent deformity.

FIG. 243.

The later effect of acute epiphysitis of the right hip at three months of age. The scar is shown.

Gonorrhœal Arthritis.

Gonorrhœal arthritis of this joint is an affection not uncommon in adult life, and in its symptoms and effects it may resemble tuberculous disease or perhaps more closely osteo-arthritis. The treatment of infectious arthritis in general is discussed elsewhere. Deformity should be corrected by rest in bed with traction, and protective treatment should be employed while the sensitiveness persists. The short spica plaster bandage, if properly applied, is a satisfactory support.

Extra-articular Disease.

Occasionally tuberculous disease, or other form of destructive ostitis, may begin in the neighborhood of the trochanter major. The symptoms are local pain, sensitiveness, and swelling of the soft parts. Later thickening and irregularity of the underlying bone become evident.

The symptoms are limp and discomfort. If the disease involves the capsule or is sufficiently acute to cause sympathetic congestion of the joint, there may be limitation of motion ; but, as a rule, this is slight or absent. In many instances the focus in the bone may be shown by an X-ray negative. When the disease is tuberculous or of the subacute type, abscess in the trochanteric or gluteal region may be the first indication of disease.

The treatment is prompt removal of the focus of disease before the joint or the shaft of the femur has become involved.

Disease of the pelvic bones in the neighborhood of the joint may simulate hip disease. The diagnosis is made by the local swelling and sensitiveness, and by the freedom of motion in the directions not restrained by sensitive tissues that are involved in the disease.

Gluteal Bursitis. An enlargement of one of the bursæ lying beneath the gluteal muscles may cause a rounded, fluctuating swelling in the buttock. It may be painful to pressure and it usually causes a limp and some discomfort on motion, dependent upon the degree of inflammation that may be present. Occasionally the bursitis may be caused by injury, but in most instances it is the result of tuberculous infection. The bursa may communicate with a diseased hip-joint, but usually it is a distinct and primary affection.

Iliopsoas Bursitis. The iliopsoas bursa lies in front of the capsule of the hip-joint, extending from the trochanter minor to and sometimes over the brim of the pelvis. Not infrequently it communicates with the joint. If the bursa is enlarged it forms a swelling in Scarpa's space of a somewhat quadrilateral form. Sometimes a central indentation indicates the position of the iliopsoas tendon.

This causes a distinct enlargement of the upper and inner aspect of the thigh. It is usually accompanied by slight flexion, abduction, and outward rotation of the limb, an attitude that relieves the tension on the sensitive part. Zuelzer has collected from litera-

ture forty-five cases of gluteal and fifteen of iliopsoas bursitis. This illustrates the relative frequency of the two affections.[1]

Simple bursitis may be distinguished from disease of the joint by the absence of characteristic muscular spasm and general limitation of motion. Acute inflammation may simulate local abscess.

Treatment. Chronic disease of bursæ is usually tuberculous in character. Aspiration and injection of carbolic acid or iodoform emulsion may be employed as primary measures. As a rule, however, incision, drainage, or, if possible, removal of the sac is indicated. According to Lund,[2] iliopsoas bursa may be reached easily by a vertical incision between the femoral artery and the crural nerve.

Malignant Disease about the Hip-joint.

Carcinoma of the upper extremity of the femur is almost always secondary to a primary tumor of another part of the body. Sarcoma is far less frequent in this situation than at the knee. The character of the disease soon becomes evident in the general enlargement of the upper extremity of the thigh, but in the early stage diagnosis can be made only by means of the X-ray or by exploratory incision.

Cysts of the Femur.

In extremely rare instances cysts, caused apparently by inclusion of a displaced portion of epiphyseal cartilage, may cause enlargement, weakening, and deformity of the upper extremity of the femur. One case, in a boy thirteen years of age, was treated at the Hospital for Ruptured and Crippled. The symptoms were discomfort, limp, and outward bowing of the upper third of the femur. Cure followed its removal. Cysts may be caused also by localized osteomyelitis of a mild character.

Arthritis Deformans.

Osteoarthritis of the Hip-joint. Osteoarthritis is not infrequently confined to the hip-joint. In this form it is an affection of adult life or old age (malum coxæ senile). It is characterized in its later stages by disappearance of the cartilage covering the head of the femur and by an eburnation and progressive destruction, or wearing away, of the underlying bone. At the same time

[1] Deutsche Zeits. f. Chir., Bd. l. H. 1 and 2.

[2] Boston Medical and Surgical Journal, September 25, 1902.

there is formation of ecchondroses about the junction of the femur with the acetabulum, which become ossified into irregular masses of bone. In the early stage of the affection the fluid within the joint may be increased in amount, but later it is diminished in quantity and changed in quality as the synovial membrane becomes transformed in part to fibrous tissue. The etiology of the affection is discussed elsewhere. (See page 274.)

Symptoms. The early symptoms are usually subacute in character. They are neuralgic pain in the limb, "sciatic rheumatism," stiffness on changing from rest to activity, and sensitiveness to direct pressure on the joint, so that the patient often lies habitually on the other side. The movements of the joint become somewhat restricted, and in certain instances creaking sounds are apparent to the patient. In the advanced stages of the disease there is marked thickening about the trochanter which is usually displaced upward, owing to the progressive changes in the head and neck of the femur. The limb is shortened and it is often distorted, usually in an attitude of flexion and adduction, and marked atrophy is apparent. These symptoms, but for the history, might be mistaken for the results of fracture of the neck of the femur, and in the earlier period of the disease the limp, the pain, and restriction of motion with the attendant atrophy may simulate very closely tuberculous disease of a subacute type.

The progress of the disease may be slow or it may be rapid. It depends in great degree upon the strain to which the part is subjected. In this it resembles tuberculous disease.

Treatment. In the class of cases in which the disease is confined to a single joint one may hope to check the progress of the destructive process by lessening the strain upon the joint by regulation of the patient's habits and occupation, and to improve the nutrition of the part by massage and local stimulants. Passive motion in the directions of abduction and extension for the purpose of preventing secondary contraction of the muscles, is of service also.

If deformity be present it should be reduced by traction and rest in bed. Afterward the symptoms may be relieved by the use of a hip brace (Fig. 231) that will remove the weight and limit the range of motion, or a support of the character of a Lorenz spica of plaster, leather, or other material may be used. In extreme cases resection of the upper extremity of the femur might be advisable. Lorenz states that he has treated

cases satisfactorily by inducing anterior transposition of the head of the femur and fixing the limb for a time in an attitude of extension and abduction. In most cases neither the operative nor the brace treatment is feasible, but the use of a firm flannel spica bandage or similar support, combined with the application of cautery, from time to time, adds to the comfort of the patient.

CHAPTER IX.

TUBERCULOUS DISEASE OF THE KNEE-JOINT.

Synonyms. White swelling, tumor albus.

Tuberculous disease of the knee-joint is next in frequency and importance to that of the hip. It is, however, far less dangerous to life, and the prognosis, as regards function, is much better than in the former affection. This is explained by the simplicity of the joint and by its situation at a distance from the trunk, at the junction of two levers of nearly equal length and size. As the problem of protection by mechanical means is comparatively simple it is more often applied, and in proportion to its efficiency the injury of functional use is lessened and the tendency to deformity is checked.

FIG. 244.

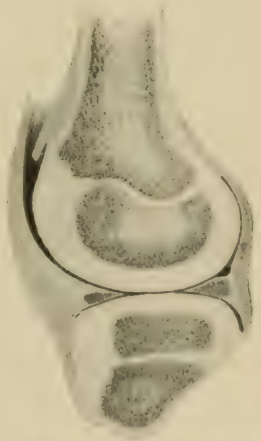

Section of knee-joint at the age of eight years, showing the epiphyses of the femur and tibia and their relation to the capsule. (Krause.) The centres of ossification in the epiphyses of the femur and tibia are present at birth. Ossification is completed in each at about the twentieth year.

Pathology. The disease may begin in the epiphysis of the femur or in that of the tibia, occasionally in the patella or in the head of the fibula, or primarily in the synovial membrane.

In 547 cases,[1] about two-thirds of which were in adults, treated at Koenig's clinic at Göttingen by operative procedures which permitted inspection of the joint, 281 (51.4 per cent.) were apparently examples of primary osteal disease; 266 (48.6 per cent.) were primarily synovial. The focus was in the femur in 93 instances (33.1 per cent.), in the tibia in 107 (38.1 per cent.), in the patella in 33 (11.7 per cent.), and in more than bone in 48 (17.1 per cent.).

The examination of a joint permitted by arthrectomy or excision cannot be sufficiently thorough to exclude disease of the bone and to establish the diagnosis of primary disease of the synovial mem-

[1] Die Specielle Tuberculose der Knochen und Gelenke, Berlin, 1-90.

brane, but in 92 instances the opportunity was offered by amputation at the thigh, 80 of the patients being adults. This examination, presumably thorough, showed the primary disease to be of the bone in 50 cases, while in 35 the synovial membrane was apparently the seat of the primary affection.

In 17 of the 50 cases in which the disease was osteal, the focus was in the femur; in 7 it was in the internal condyle, in 6 in the external condyle, and it was in other situations in 4 cases. In 17 the primary disease was of the tibia; in 5 of the internal tuberosity; in 5 of the external tuberosity; in other situations 7. In 5 instances the primary disease was of the patella, and more than one bone was involved in 11 cases. Nichols[1] states that he has examined 120 tuberculous joints of adults and children, after excision or amputation, or at autopsy, and in every instance primary foci in the bone were discovered. He believes primary disease of the synovial membrane to be very uncommon, and asserts that examinations are of no particular value as establishing the absence of primary osteal disease unless the bones are sawed into thin sections. This is the view generally held in this country, that in the great majority of cases the disease of the bone precedes the disease in the interior of the joint. From the clinical standpoint, however, one recognizes two distinct types of tuberculous disease: one, beginning as a chronic synovitis of which the early symptoms are subacute, a type more often seen in adults (Fig. 248); and the more common class, in which the symptoms of pain, muscular spasm, and deformity seem to indicate clearly primary disease of the bone.

The proximity of the active disease in the neighborhood of the joint sets up a sympathetic hyperæmia within it, and an accompanying synovitis. If the disease is progressive the synovial membrane becomes thickened and adhesions form between its folds that gradually lessen the capacity of the joint and diminish its mobility. When perforation takes place the granulation tissue spreads over the surface of the cartilages, destroying them in its progress and eroding the underlying bone; or if the joint is filled with tuberculous fluid the cartilage may be macerated and separated in necrotic shreds. The direct destructive effects of the disease are increased by pressure and friction if the joint is not protected by mechanical means. The hypertrophied synovial membrane and the thickened and diseased capsule explain the peculiar

[1] Transactions American Orthopedic Association, vol. xi.

elastic resistance on palpation called pseudofluctuation. In more advanced cases there is also a reactive inflammation in the overlying tissues, accompanied by a formation of fibrous tissue that involves the tendons and muscles. These changes within and without the joint cause the firm, resistant tumor characteristic of "white swelling."

FIG. 245.

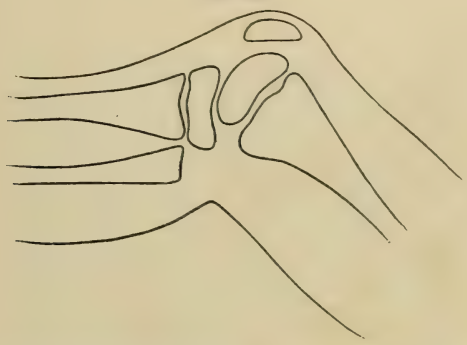

Flexion deformity at the knee-joint, with slight subluxation of the tibia.

Etiology. The etiology of tuberculous disease has been discussed in Chapters V. and VII.

Statistics. Tuberculosis of the knee-joint is essentially a disease of early life, although it is less strictly confined to childhood than is disease of the spine or hip. Sex exercises but little

FIG. 246.

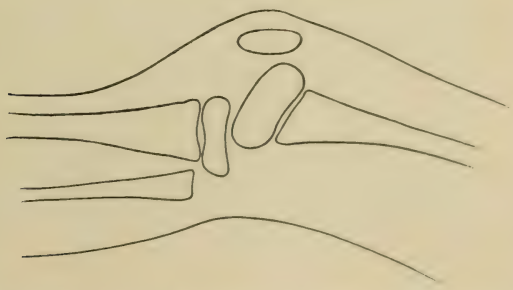

After forcible correction, showing the increase of the posterior displacement. Drawings from the X-ray photographs of an actual case.

influence, and the two sides are affected in nearly equal numbers. These points are illustrated by the following table of 1000 consecutive cases treated at the Hospital for Ruptured and Crippled.[1]

[1] These statistics, together with those of tuberculous disease of the joints, other than of the hip, were collected for me by Drs. F. C. Bradner, S. E. Sprague, E. L. Barnett, and S. W. Stone, house officers at the hospital, 1900–1901.

AGE AT INCIPIENCY OF KNEE-JOINT DISEASE.

1 year or less	25	23 years old	12
2 years old	45	24 " "	8
3 " "	91	25 " "	3
4 " "	164	26 " "	2
5 " "	84	27 " "	4
6 " "	75	28 " "	5
7 " "	66	29 " "	7
8 " "	74	30 " "	1
9 " "	65	31 " "	1
10 " "	60	32 " "	2
11 " "	46	33 " "	1
12 " "	20	34 " "	1
13 " "	19	35 " "	4
14 " "	17	36 " "	0
15 " "	12	37 " "	2
16 " "	10	38 " "	1
17 " "	20	39 " "	1
18 " "	8	40 " "	1
19 " "	8	41 " "	1
20 " "	8	50 " "	1
21 " "	12		
22 " "	13		1000
Males	512	Right	485
Females	488	Left	515

Symptoms. The general characteristics of tuberculosis have been described in the chapters on Pott's disease and hip disease. In the description of these affections, however, but little stress was laid on local sensitiveness and local swelling, because the diseased parts lie at a distance from the surface and are concealed by the muscles and other tissues. At the knee, on the other hand, the joint is superficial, and even slight effusion changes, to a perceptible degree, its contour. If the disease is progressive sensitiveness to pressure, elevation of the local temperature, and infiltration or thickening of the tissues are usually present.

Even when the patients are seen at a comparatively early stage in the course of the disease the history of the affection will almost always show that it is chronic and progressive in character. The importance of establishing this fact has been mentioned in the consideration of hip disease, and it may be stated again that a chronic painful disease of a single joint, accompanied by a tendency to deformity, is, in childhood, almost always tuberculous in character.

The symptoms of tuberculous disease may be classified as *limp, pain, local heat, sensitiveness and swelling, muscular spasm and limitation of motion, distortion and atrophy.*

On physical examination one will note the character of the limp and the slight flexion of the limb that usually accompanies it. The joint is, as a rule, somewhat enlarged, and the normal

depressions about the patella and the projection of the component bones are less accentuated than on the opposite side. There is usually slight local elevation of temperature and sensitiveness to pressure, varying in degree with the character of the disease. In certain cases a degree of effusion is present, sufficient to be classed as synovitis, but in most instances the swelling is due, in great part, to the hyperæmia and thickening of the synovial

FIG. 247.

Acute tuberculous arthritis of the knee.

membrane and the capsule, which gives the sensation of elastic resistance rather than of actual fluctuation.

The most important diagnostic sign is limitation of the range of motion caused by muscular spasm. The normal range is from complete extension, 180 degrees, to a degree of flexion, limited by the apposition of the calf and the posterior surface of the thigh. Even in the early stage of disease slight limitation of complete

extension is present, due to reflex muscular spasm, and usually a corresponding limitation of the complete flexion. On sudden movements the characteristic reflex contraction of the muscles is apparent. In most cases this limitation of motion and consequent flexion deformity is well marked on the first examination. Atrophy of the muscles of the thigh and calf, dependent upon the duration of the disease and upon the interference with function, is present, and this atrophy is more noticeable because of the enlargement of the knee.

In certain cases, more often seen in infancy and early childhood, the symptoms are more acute and the progress of the disease is so rapid that it may simulate an infectious epiphysitis (Fig. 247).

In another type, apparently a primary disease of the synovial membrane, more common in adults, the early symptoms are very similar to those of simple chronic synovitis. The joint is swollen by a distention of the capsule, pain is not troublesome except on jars or sudden twists of the limb, and muscular spasm and limitation of motion are evident only after a careful examination. In this class, months or years may pass before the symptoms become as disabling as in the osteal type of the disease.

Primary and Secondary Distortions of Knee-joint Disease. At the hip-joint, in which the range of motion is extensive, the deformities resulting from disease are somewhat complex, causing, for example, apparent shortening or lengthening, according as the limb is adducted or abducted. But the movements that the knee-joint permits are much simpler, and the primary distortion is simply flexion. Complete extension of the limb, the limit of normal motion in that direction, brings the joint surfaces into close apposition ; the ligaments are then tense and no lateral motion is permitted. This is the attitude in which the greatest efficiency of the limb for weight bearing is assured. When the ability of the knee for carrying out its normal weight-bearing function is lessened by disease which makes the parts sensitive to pressure and strain, the range of extension is lessened and the limb is persistently flexed to a greater or less degree, corresponding to the sensitiveness of the joint. The agents that adapt the limb to the habitual attitudes are the muscles under the control of the nervous system. In this sense the primary distortions are due to muscular action, but it is certainly not true that these muscles antagonize one another, and that the stronger overcoming the weaker cause the deformity, since the extensors at

this joint are stronger than the flexors, and since flexion is the primary deformity at every joint which is diseased without regard to the relative strength of the opposing muscular groups.

In disease at the knee-joint, as at other joints, the extremes of motion in every direction that the joint permits are limited by muscular spasm, but limitation of extension, which is so essential to normal use, is at once evident, while limitation of flexion, the extreme of which is unessential, is only apparent on examination, and it may be absent even. Flexion is, then, the primary distortion at the knee, and other deformities may be classed as secondary.

FIG. 248.

Tuberculous disease of the knee in an adult. The synovial type.

Secondary Deformities. Of these the most common is outward rotation of the tibia upon the femur. When the limb is fully extended there is no lateral motion at the knee, but when it is flexed lateral motion is possible, and in the attitude of flexion the traction of the biceps upon the head of the fibula tends to rotate it upon the femur. This deformity is also favored by the use of the limb in the attitude of outward rotation, which is always assumed when the weakness or stiffness of the knee-joint is present, and by the secondary knock-knee that often accompanies the disease.

Subluxation or backward displacement of the tibia upon the femur is another secondary deformity. When the leg is flexed upon the thigh the articulating surface of the tibia glides backward upon the condyles of the femur. Here it becomes fixed by muscular contraction, and later by the secondary changes within the joint. If muscular spasm be extreme this alone might cause the subluxation, but there are other factors; one is the destructive action of the disease, which is usually most marked at the point at which the bones are in contact, and the other is the leverage exerted upon the joint. This is exemplified by the

increase of the displacement that is often observed when an attempt is made to straighten the limb by force, against the resistance offered by the contracted tissues on the flexor aspect. The same leverage, in slighter degree, is exerted when the weight

FIG. 249.

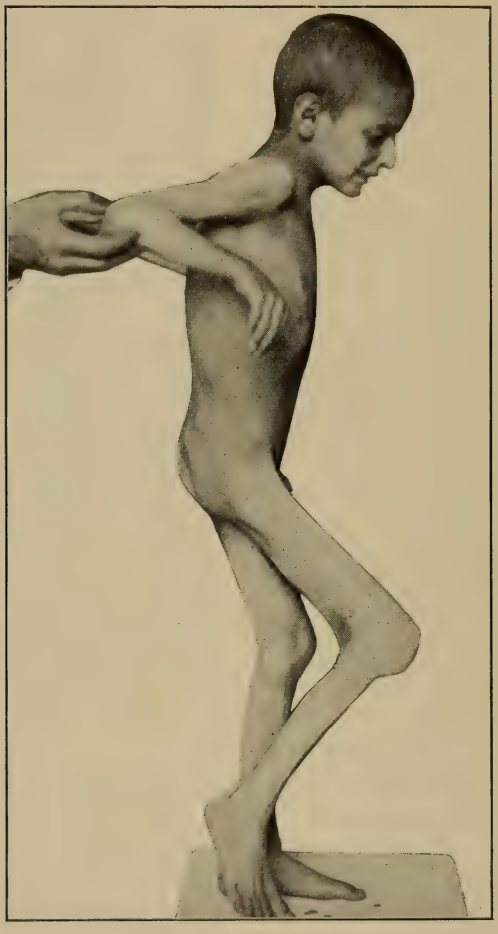

Untreated disease of the knee-joint involving the shaft of the femur, illustrating the hypertrophy of the condyles of the femur, the subluxation and outward rotation of the tibia, the atrophy and the characteristic deformity.

of the distorted limb is supported on the heel in the recumbent posture, or when the limb is extended in the act of walking, or if the upper extremity of the tibia is not supported during the period of treatment by apparatus (Fig. 246).

Knock-knee (genu valgum) is another secondary deformity. This is explained in certain instances by the hypertrophy of the internal condyle caused by disease, but it is induced more directly by the use of the flexed and somewhat disabled limb in the passive attitude of outward rotation. Genu varum is uncommon, and it is usually the result of the destruction of a part of the internal condyle of the femur or of the tibia, or of irregular epiphyseal growth.

The character and the relative frequency of the deformities are indicated by the statistics of Koenig's[1] clinic, of 150 cases of knee-joint disease treated by arthrectomy, 128 of these being in children. In 94 cases flexion was present; in 50, from a slight degree to 135 degrees; in 16, from 135 degrees to 90; in 28, to a right angle or less. Together with the flexion were combined other deformities as follows: Genu valgum in 60 cases; moderate in 42; extreme in 18. Genu varum in 1 case. Subluxation of the tibia in 20 cases. Outward rotation of the tibia in 10 cases.

As has been stated, the primary deformity of knee disease is simple flexion. If the disease is of an acute type this flexion increases rapidly. If it is subacute in character, and especially if the clinical signs indicate that the disease is primarily of the synovial membrane, the progress of the deformity is slow. In ordinary cases secondary deformities appear at a later time and especially when the disease has reached the destructive stage; and they are most marked in patients who have persistently used the deformed limb without protection.

Actual Shortening and Actual Lengthening. Retardation of growth is, of course, not an early symptom of disease; in fact, actual lengthening of the limb, due to the irritative effect of the disease upon the epiphyseal cartilage of the femur or of the tibia, is common. This lengthening, sometimes to the extent of an inch or even more, may persist throughout the entire course of treatment, but after the cure of the disease a corresponding retardation of growth that will more than equalize the length of the limbs, may be expected. When the disease is of the destructive type the ultimate shortening may be considerable; two or more inches is not unusual.

Leusden,[2] in 33 cases under treatment in the clinic at Göttingen, 1896–1898, found slight shortening in 2, equality of length in 18, lengthening of the femur on the diseased side in 13.

[1] Loc. cit.

[2] Deutsche Zeits. f. Chir., Bd. li. H. 3 and 4.

In one hundred and sixteen cases of tuberculous disease of the knee the limbs were measured by Berry and Gibney[1] with reference to this point. In 72 of these there was actual lengthening of the femur, from which in may be inferred that in at least 62 per cent. of the cases examined the primary disease was of the femur.

In	17	¼ inch.
"	34	½ "
"	15	¾ "
"	6	1 "
	72 = 62 per cent.	

H. L. Taylor,[2] from an examination of 40 cases of tuberculous disease of the knee, concludes that the limb is almost always longer in the first two years of the disease, usually longer during the second two years, but usually shorter when the period of growth is completed. The lengthening is in most instances of the femur.

Diagnosis. Tuberculous disease is a local destructive process that is, as a rule, confined to a single joint. This is an important point in the differential diagnosis from general or constitutional affections like rheumatism, rheumatoid arthritis, and the like, in which several joints are involved. The following affections may be considered in differential diagnosis.

Injury of the Knee. Strains of the knee in childhood are often followed by limp and persistent flexion and pain on motion. In such cases the onset is sudden and the symptoms usually disappear quickly under treatment. Synovitis of traumatic origin is usually indicative of a more severe injury. When synovitis persists the diagnosis may be doubtful because tuberculous infection may have followed the original injury. This emphasizes the importance of the careful treatment and continued observation of injuries of this class, especially in weakly children.

Synovitis. Chronic synovitis of doubtful origin, which shows no tendency toward recovery, is usually tuberculous in character.

Hæmophilia. Effusion of blood into the knee-joint may cause inflammatory symptoms during the stage of absorption and organization of the clot that resemble those of disease. The sudden onset and the personal history of the patient, who may be known as a bleeder, will explain the symptoms. (See page 283.)

[1] American Journal of the Medical Sciences, October, 1893.
[2] Transactions American Orthopedic Association, 1901, vol. xiv.

Infectious Arthritis—Acute Epiphysitis. This is of sudden onset, attended by the constitutional and local symptoms of acute infection.

Rheumatism. This, in early childhood, may be confined to a single joint, but it is of sudden onset, it is usually accompanied by constitutional disturbance, and after a time other joints become involved.

Rheumatoid Arthritis—Osteoarthritis. Diseases of this character, of the monarticular form, are more common in adult life. The symptoms are rather of the rheumatic than of the tuberculous type.

Charcot's Disease. Charcot's disease of the knee-joint is characterized by sudden effusion, by rapid destruction of the joint, and consequently by weakness and deformity ; but pain is usually very slight and muscular spasm is absent. The diagnosis of disease of the spinal cord will explain the condition of the joint. (See page 284.)

Sarcoma. Sarcoma, beginning in or near the epiphysis of the femur or of the tibia, may simulate tuberculous disease very closely. If the tumor is of the periosteal type, it usually forms a more localized and irregular swelling than could be accounted for by tuberculous disease. Central sarcoma may simulate tuberculous disease also, but the progress of the tumor is more rapid. The clinical distinction between the two is that tuberculous disease is very amenable to treatment as far as its symptoms are concerned, while the progress of sarcoma is but little influenced by treatment. It may be stated, however, that the X-ray is the only means of early diagnosis, the destruction of the substance of the bone about the tumor being much greater than that caused by the tuberculous process.

Hysterical Joint. Some of the symptoms of disease may be simulated by hysterical subjects, but there is always an absence of the positive physical signs that invariably accompany a destructive disease. These and other affections are described at length in the following chapters.

Treatment. The treatment of tuberculous disease of the knee in childhood is conservative, operative intervention being simply incidental to protective treatment. In adult life, on the other hand, the radical removal of the disease may be indicated as the primary measure. The reasons for this distinction are obvious. In childhood the duration of treatment is of no particular importance as compared with the final functional result, but in adult

life the shortening of the period of disability and the definite assurance of cure may be of far greater moment than the preservation of motion.

In childhood, under favorable conditions, ultimate recovery, with fair functional use of the joint, may be anticipated; while a radical operation, although it may cure the patient in a shorter time, takes away the possibility of a cure with motion. In adult life a rigid limb is a strong, useful, if somewhat awkward support, but in childhood the removal of portions of the epiphyses and of the epiphyseal cartilages entails a progressive inequality in the limbs, due to loss of growth, and unless the limb is protected by mechanical means deformity is the rule, even though the disease has been thoroughly removed. Thus the treatment of routine is, in childhood, at least, protection; protection from the traumatism of

FIG. 250.

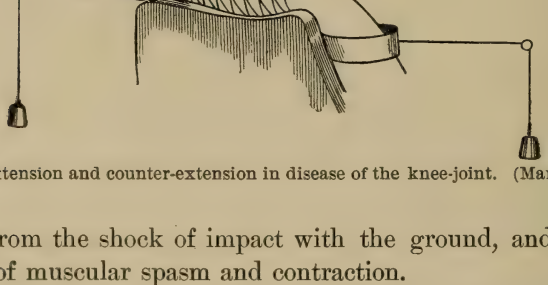

Extension and counter-extension in disease of the knee-joint. (Marsh.)

motion, from the shock of impact with the ground, and from the pressure of muscular spasm and contraction.

Mechanical treatment, which is so difficult at the hip, is comparatively easy at the knee, and, as has been stated, the results are correspondingly better. At the hip-joint one of the most common causes of shortening and deformity is upward displacement of the femur upon the pelvis, but at the knee, if the limb is supported in the attitude of extension, the apposition of the broad surfaces of the femur and the tibia prevents displacement, while muscular spasm, a symptom whose intensity is in proportion to the degree of harmful motion that is permitted, is easily controlled by efficient splinting.

Reduction of Deformity. The first step in treatment is the reduction of deformity that may be present, in order that the limb, at the beginning as well as throughout the entire course of treatment, may be in absolute normal position; and as the chief function of the leg is to support weight the proper attitude is

complete extension. Whatever motion the patient retains will then be about the point of greatest usefulness. In the cases in which an opportunity for reasonably early treatment is offered the only deformity is flexion, induced by muscular contraction, although if it has persisted for some time secondary retraction of the muscles may be present. In this class of cases the spasm, and consequently the deformity, may be readily overcome by placing the joint at rest.

FIG. 251.

Tuberculous disease of the knee in an adult, with the form of Billroth splint used at the Hospital for Ruptured and Crippled.

The Plaster Bandage. The most efficient splint for this purpose is a close-fitting plaster bandage, applied from the groin to the ankle, or, better, to include the foot, in order to prevent œdema of the unsupported part, which is common after the first dressing and until the circulation of the limb has become adapted to the new conditions. In the application of the bandage the bony prominences of the knee and ankle are protected by cotton. A canton-flannel bandage is then applied smoothly, and directly upon this the light plaster bandage. At the second application,

at the end of a week, the subsidence of the spasm will permit the straightening of the limb. In cases of longer standing several successive applications of the bandage may be required, together with manual extension during the application; or an anæsthetic may be administered. Under anæsthesia the muscular spasm relaxes and deformity, even of some standing, may be reduced by traction and by slight leverage, the head of the tibia being supported and drawn forward by the hands as the deformity is gently reduced.

Traction. Deformity may be reduced also by traction with the weight and pulley, the leg being supported so that no direct leverage is exerted at the seat of the disease (Fig. 250).

Forcible Correction by Reverse Leverage. In the more resistant cases, especially if accompanied by subluxation, the following method may be employed: The patient is anæsthetized and is placed face downward on a table, the feet projecting over its end.

FIG. 252.

Illustrating the method of supporting the body and fixing the tibia before straightening the limb. The folded sheet indicates the degree of subluxation present. In resistant cases of this type an assistant applies the pressure on the thigh.

The body of the patient is then elevated by means of pillows to conform to the deformity—that is, the thigh of the affected limb is raised sufficiently to allow the tibia to lie evenly upon its anterior border on the table. The operator with one hand holds the head of the tibia firmly against the table and with the other massages the contracted tissues of the popliteal region, gradually exerting more downward pressure on the thigh, but never to the extent to lift the tibia from the table; thus, further subluxation is impossible. As the contraction gives way the pillows are removed. Usually the deformity may be reduced at one sitting, but if it is very resistant complete correction is not attempted. At the conclusion of the operation adhesive plaster straps for traction and a close-fitting plaster bandage are applied (Fig. 252).

Rest in bed with traction is enforced for a time, and the ordinary brace is then employed. This is, in the author's experience, the most effective and satisfactory method for reducing deformity. If the contraction is of long standing preliminary division of the flexor tendons may be advisable, but this is not usually necessary.[1]

The Billroth Splint. The Billroth splint, as modified by Stillman, is an effective appliance for overcoming resistant deformity. A thick pad of felt is placed over the upper surface of the condyles of the femur and a thinner pad in the popliteal region over the upper border of the tibia. Other points that may be subjected to pressure are similarly protected, especially the dorsum of the foot and the perineum. A plaster bandage is then applied from the groin to the toes, made especially thick and strong in the popliteal region. On either side of the knee two curved, slotted steel bars attached to expanded tin splints and joined to one another by an adjustable bolt are incorporated in it (Fig. 251). When the bandage hardens it is completely divided into two parts by a circular cut about the knee, and the bolts in the slots are so adjusted as to form a hinged splint, the centre of motion being somewhat above and in front of the knee-joint. When the limb is slightly extended the position of the hinges has a tendency to lift the tibia and to separate it from the femur. This straightening opens the cut in the popliteal region, which is held open by a wedge of cork. In this manner, by the insertion of larger wedges, the limb is gradually straightened from day to day until the deformity is overcome, or until a new bandage is required. If the pressure on the front of the femur, when the leverage is exerted, becomes painful, a part of the padding is removed.

FIG. 253.

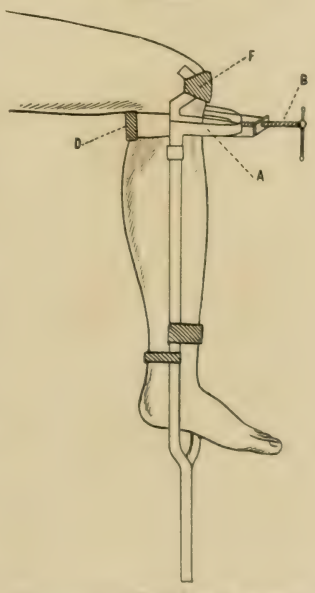

The Bradford-Goldthwait genuclast for the correction of flexion deformity and subluxation at the knee. Counter-pressure is applied over the lower extremity of the femur. Subluxation is prevented during the forcible correction by means of the screw and strap beneath the head of the tibia, by which it is drawn forward.

[1] Whitman. American Journal of the Medical Sciences, May, 1905.

In the treatment of older subjects greater force may be employed by means of osteoclasts. One of the best machines of this type is the Bradford-Goldthwait genuclast (Fig. 253). The more violent methods should not be employed during the active stages of the disease; and whenever considerable force is required in young subjects the possibility of separating the epiphysis of the femur, forcing it backward, and thus pressing upon the popliteal vessels, should be borne in mind.

Mechanical Treatment. The most efficient mechanical appliance for the treatment of tuberculous disease at the knee is the *Thomas*

Fig. 254.

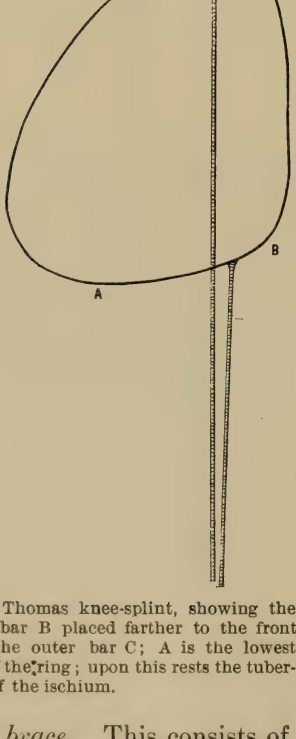

The Thomas knee-splint, showing the inner bar B placed farther to the front than the outer bar C; A is the lowest part of the ring; upon this rests the tuberosity of the ischium.

Fig. 255.

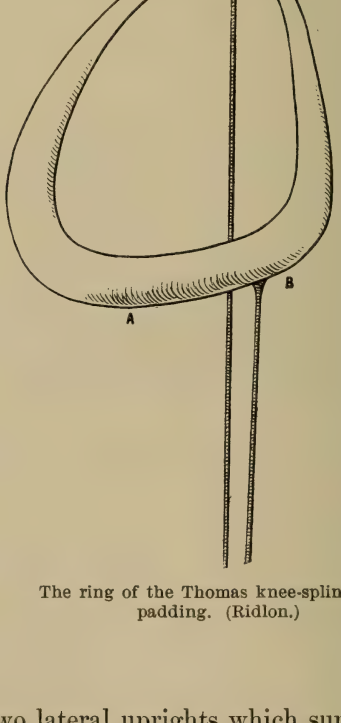

The ring of the Thomas knee-splint after padding. (Ridlon.)

knee brace. This consists of two lateral uprights which support the limb on either side, terminating below the foot in a crossbar shod with leather or rubber, which serves as a stilt, and above in a ring that fits the upper extremity of the thigh, and supports the weight of the body. The brace is made of iron wire from three-sixteenths to three-eighths of an inch in thickness. The ring is of an irregular ovoid shape, flattened in front, expanded

behind, and wider on the inner than on the outer side (Fig. 254). This ring is welded to the uprights at a lateral and anteroposterior inclination. The lateral inclination forms an angle with the inner bar of 135 degrees (Fig. 256), the anteroposterior inclination forms an anterior angle of 145 degrees (Fig. 255) with the same upright, which is set upon the ring at a point slightly in advance of its fellow. The objects of the shape of the ring and of its inclination are these: its anterior part is flat, because the surface of the groin is flat; its posterior segment is expanded to accommodate the thickness of the buttock; the

FIG. 256.



Showing the front of the ring of the Thomas knee-splint.

FIG. 257.

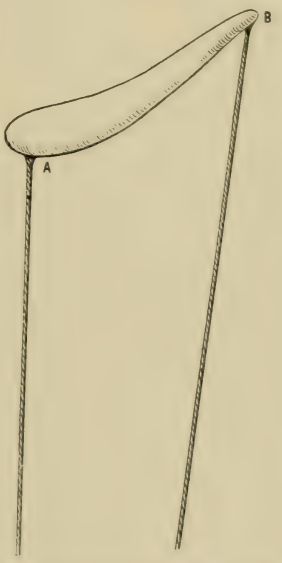

Showing the back of the ring of the Thomas knee-splint. (Ridlon.)

anteroposterior inclination allows the ring to rest comfortably beneath the tuberosity of the ischium. The lateral inclination which follows the line of Poupart's ligament is made necessary by the greater length of the outer bar, which, in order to assure better support and less pressure, rises above the level of the trochanter major.

The ring is made somewhat larger than the thigh to allow for padding with felt. This should be thicker on the inner and posterior surface, where the weight is borne, than on the anterior and outer part. The padded ring is then smoothly covered with basil leather. As used at the Hospital for Ruptured and

Crippled, the brace is made from two to three inches longer than the leg, to serve as a stilt like the hip splint. To the foot-piece two straps are attached on either side to provide for traction on the limb and to hold the brace securely in its place. A band of leather is drawn between the bars at the upper third and another at the lower third of the brace to serve as supports for the thigh and calf. Adhesive plasters, reaching from the knee to the ankle, provided with buckles above the malleoli, having been applied, the ring is pushed firmly against the perineum and is held in position by buckling the straps to the traction plasters with as much tension as the comfort of the patient will permit. The thigh and leg supports should fit the parts perfectly; the knee is then fixed in its place by a bandage drawn tightly about it and the lateral bars. Ankle and heel straps complete the adjustment (Fig. 258).

FIG. 258.

The Thomas knee-brace.

In cases in which the joint is sensitive and in which there is a tendency to deformity the entire limb is in addition enclosed in a light plaster bandage, so-called "skin fitting," applied directly upon a flannel bandage.

If the brace is attached by means of the adhesive plaster straps, a certain amount of traction is assured, together with additional accuracy of adjustment; and by the traction and by the direct pressure on the knee the slighter degrees of deformity may be reduced without discomfort. In acute cases preliminary rest in bed is advisable, and crutches may be employed in the early stages of ambulatory treatment. But during the greater part of the disease the splint serves as a perineal crutch, and by the use of slight corrective force when the plaster bandages are applied, or by traction at times toward one or the other upright, lateral dis-

tortion of the limb may be corrected during the course of treatment. This brace may be used in the treatment of very young children if it is carefully fitted and if the parts are kept clean and dry, and it is an effective brace for all ages, and for all conditions of disease.

The Caliper Brace. The traction may be discarded and the brace may be held in position by a shoulder band, or it may be used as a so-called caliper splint. In this form it was almost exclusively employed by Mr. Thomas in his later practice and at the present time by Ridlon,[1] the long brace being used simply for a bed splint. As a caliper brace the two bars are cut off, turned directly inward at a right angle, and are inserted into a steel tube, which is passed through the heel of the shoe. The bars are made slightly longer than the limb, so that the patient's heel is lifted nearly an inch from the inside of the shoe when walking; thus, the jar of impact with the ground is prevented. The brace is fixed in position by a leather band beneath the knee and another beneath the calf, and the limb is held extended by pressure pads applied to the thigh and leg, as illustrated (Fig. 259). Ridlon uses the brace to reduce deformity by direct pressure backward on the knee by means of bandages, opiates being given to relieve pain.

Other braces may be employed, for example, the traction hip splint, but as the Thomas brace answers every requirement it seems unnecessary to describe others in this connection.

Accessory Treatment. The accessories to protective treatment, which, of course, includes the proper attention of the general condition of the patient, are local applications, injections, and venous stasis. They are classed as accessories because none of them is essential to successful treatment.

The local application of cautery, applied at intervals of a week or less, may add to the comfort of the patient and stimulate the reparative processes. The X-ray appears to act in a somewhat similar manner; it relieves pain, and in most instances the infiltration of the tissues becomes less marked.

Ichthyol ointment of a strength of about 40 per cent. certainly relieves pain and local congestion in certain instances. Firm compression by means of a flannel bandage and by the adhesive plaster strapping is of value, especially in the infiltrating, "boggy" type of disease.

[1] Transactions American Orthopedic Association, vol. vi.

The knee is the joint into which injections of iodoform emulsion may be made most easily. Such injections are more likely to be of service in the synovial than in the osteal type of disease. About 10 c.c. of a 10 per cent. emulsion of iodoform in sweet oil may be injected through a trocar into the distended capsule at intervals of several weeks. It is then distributed by gentle massage. It may aid the reparative processes by an irritative stimulation, but it apparently exerts no very direct influence on the tuberculous process.

FIG. 259.

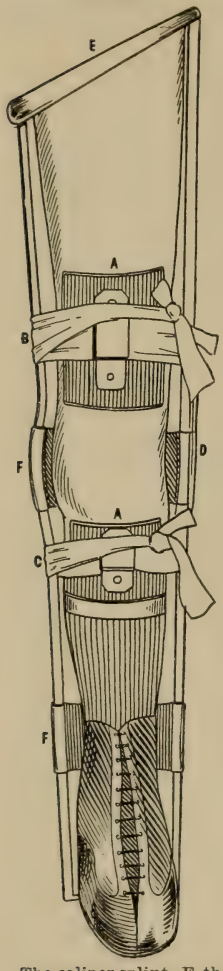

The caliper splint. E, the ring around the upper part of the thigh. A, pad for backward pressure. B, bandage. C, bandage. F, leather sling for support at the back of the limb. D, a strip of bandage fastening together the pressure pads to prevent slipping and consequent loss of pressure. (Ridlon and Jones.)

Bier's treatment by passive congestion may be easily applied to the joint. The limb up to the joint is firmly bandaged by a flannel bandage. A rubber band is then applied immediately above the joint with sufficient tension to retard the return of the venous blood. The joint then becomes swollen and congested. The congestion is at first used for an hour or more at a time once or twice daily. Later it may be applied continuously. Passive congestion apparently increases the stability of the granulation tissue and its further transformation to fibrous tissue. The method should not be employed during the acute phases of the disease. (See page 259.)

Treatment during Convalescence. During the active stage of the disease the brace must be worn day and night; during the stage of recovery it may be removed at night to allow for motion at the knee, and later a form of walking brace (Fig. 176) that will allow a limited motion at the knee may be of service; but this is not an essential in treatment. If slight knock-knee remains after recovery, it may be overcome by the use of a Thomas knock-knee brace, which will also serve as a protection to the weak joint.

The indications of cure have been discussed under hip disease. In brief, when sufficient time has elapsed to permit of natural

cure ; when there have been no symptoms of active disease for months ; when muscular spasm has disappeared, one may tentatively remove the brace in the manner described. But any symptom of disease, and particularly increasing limitation of the range of motion, or a tendency toward deformity, indicates the necessity for continued protection.

If anchylosis is present supervision and occasional treatment will be required during the period of growth in order to prevent deformity.

Extra-articular Disease and Operative Intervention. In certain cases, especially in young children, the disease about the epiphyseal cartilage of the femur or of the tibia may find its way to the exterior of the bone before it invades the joint. This fortunate course is indicated by local sensitiveness and swelling over one of the condyles of the femur or about the head of the tibia. In such instances the thorough removal of the disease is indicated, or if a Roentgen picture shows that the disease is accessible, even though it is not immediately below the surface, an exploratory operation may be advisable. An incision is made, usually over the internal condyle of the femur. The periosteum is raised and a portion of the cortex is removed in order to expose the spongy bone on either side of the epiphyseal cartilage.

In many instances an area of softening will be found. This must be thoroughly removed. The cavity may be treated with pure carbolic acid or the cautery, or filled with iodoform emulsion or paraffin, and the wound is then closed. In favorable cases prompt operative intervention may cut short the course of the disease.

Abscess. Abscess is present as a complication in about one-third of the cases that have received efficient protection, and in a larger percentage of those in which treatment has been neglected.

It was present in 51 per cent. of Koenig's cases[1] and in 47 per cent. of three hundred final results reported by Gibney.[2] At the knee, as at other joints, the infected abscess is the most dangerous complication of the disease, as is illustrated by Koenig's statistics :

Death-rate in cases without abscess	25 per cent.
" " with abscess	46 "

Although in many instances abscess indicates an extensive and destructive disease of the bone, yet the exhausting suppuration that is an indirect cause of death is suppuration from infected

[1] Loc. cit. [2] American Journal of the Medical Sciences, October, 1893.

areas in the thigh and leg, which may have little direct relation to the extent of the original disease. It should be the aim in treatment to prevent this burrowing of fluid after the capsule has been perforated, and to prevent overdistention of the capsule even in order to lessen the macerating effect of the tuberculous fluid upon the cartilages. When the fluid within the joint is of considerable amount, and when it is increasing in quantity, it may be removed by aspiration, or a better procedure is to incise the capsule. This will allow a thorough removal of its fluid and solid contents, after which the opening may be closed with sutures.

Tuberculous abscess which has perforated the capsule may be treated in the same manner, or it may be drained subsequently, according to the indications. Unless the abscess is infected careful bandaging of the thigh and leg should prevent burrowing.

Synovial Tuberculosis. In the forms of synovial tuberculosis that resemble chronic synovitis the fluid, if the quantity is large, may be evacuated by an incision in the capsule which will allow for exploration and for removal of the fibrinous masses that are often present. Afterward the interior of the joint may be treated with an application of a strong solution of chloride of zinc or pure carbolic acid. This sets up an active reaction which causes adhesions within the capsule, and exerts a favorable influence on the course of the disease. A protective brace should be worn to guard the joint from sudden twists and strains and to limit the range of motion within the painless arc. The adhesive plaster strapping may be employed in cases of this type with great advantage. Such a brace is shown in Fig. 176. The injection of iodoform emulsion should be of particular advantage in the treatment of this form of disease. Theoretically, its use should modify the infectious quality of the tuberculous fluid and lessen the danger of infection with pyogenic germs, and on this ground, rather than because it actually shortens the course of the disease, it may be recommended.

Arthrectomy. When, as in exceptional cases, the disease is progressive and shows no tendency toward recovery, and particularly if an infected abscess communicating with the joint makes efficient drainage difficult, the operation of arthrectomy may be indicated.

An Esmarch bandage having been applied, the joint is thoroughly exposed by a curved anterior incision passing above or below or through the patella, and all the diseased tissue is re-

moved; that in the soft parts is cut away, and foci in the bone are excavated with the chisel and scoop. If infection be present the joint may be packed with gauze, the leg being fixed in the position of flexion; but in other instances the wound is closed with or without drainage as may seem advisable. In a large proportion of cases primary healing may be obtained. By the procedure one may hope to cure the disease, but in all but exceptional cases the functional result will be anchylosis. The operation has the advantage over excision in that less bone is removed, and that the epiphyseal cartilages, in part, at least, remain; thus, the immediate as well as the ultimate shortening is less than after excision.

Results of Arthrectomy. The direct death-rate of the operation is small. In 150 cases reported by Koenig but 3 deaths were attributable to the operation itself. The final results in 114 of these cases, in which the operation was performed in childhood, were as follows:

Patients cured and living	90	
Cured of the local disease, but not living at the time of the investigation	10	
Practically cured, insignificant fistulæ remaining	2	
	102	= 89.5 per ct.
Living, not cured	5	
Deaths before the cure of the local disease	7	
	12	= 10.5 per ct.

Thus in 89 per cent. of the cases the operation was successful as far as the cure of the local disease was concerned. In 75 per cent. of the successful cases immediate cure was attained; in 25 per cent. fistulæ persisted for a longer or shorter time. In 10 cases some motion was retained, but in the others anchylosis followed the operation. In about 70 per cent. of the cases the limb was practically straight; in 30 per cent. it was distorted. This shows the necessity of continued supervision and in many instances of protective treatment during the growing period in all cases in which anchylosis is present from whatever cause.

In forty-eight cases in which the operation had been performed before the tenth year, and in which the limbs were straight, the influence of the operation on the growth was investigated.

Number of cases.	*Years elapsed since operation.*	*Average shortening in cm.*
6	2	1
5	3	1.6
4	4	1
3	5	2
19	6–7	2
11	8–13	2.5

These measurements indicate that the shortening is not likely to be very great as a result of the operation, certainly very much less than after complete or even partial excision performed at the same age.

Excision. Excision of the joint in childhood has been practically abandoned, because of the great shortening that follows complete removal of the epiphyses, and because so-called partial excision—that is, the removal of the thin sections of bone from the surfaces of the femur and tibia, leaving the cartilages—is usually an unnecessary operation, in the sense that disease that might be cured by this procedure might have been cured by conservative methods.

FIG. 260.

Deformity and shortening resulting from excision of the knee in childhood.

Early excision in adult cases is often indicated because it will assure a cure of the disease in a short time, whereas mechanical treatment will require years of disability with no certain prospect of absolute cure at the end of the period. If, therefore, the disease has progressed sufficiently to indicate that the natural cure would result in anchylosis, or if the time required for natural cure is of importance to the patient, early excision may be advised in the case of the adult or adolescent whose growth is nearly completed.

The operation is performed under the Esmarch bandage, and the joint is exposed by the anterior incision, as in the operation of arthrectomy. All the diseased tissues are cut away and sections of the bones, parallel to the articular surfaces, are removed, sufficient in depth to include all the diseased area. If the sections are so made as to allow the bones to be brought into close apposition, sutures through the periosteum will hold them in position, without nails or wiring. The vessels having been

ligated, the wound may be closed with or without drainage, as may be indicated by the character of the disease, a plaster-of-Paris dressing is applied, and the limb is elevated. Mechanical support is of service in the after-treatment in lessening the discomfort and hastening the cure.

Results of Excision. In Koenig's statistics of 300 excisions, 6 deaths were due directly to the operation, and 23 others occurred during the course of the after-treatment—a total of 29 (9.6 per cent.).

In 23 instances amputation was afterward performed because of failure of the operation. The good results are classed by Koenig as 75 per cent., the bad as 25 per cent. In 193 cases the position of the limb in after years was investigated. It was straight in 175, distorted in 18, all but 1 of this latter group being in children.

Amputation. This operation is indicated as a life-saving measure. When the disease is so extensive as to require complete removal of the epiphyses in early childhood, amputation is the preferable operation, as the limb, aside from requiring constant protection to prevent deformity, will be so short as to be of little practical use.

Operations for the Relief of Final Deformity. In the majority of the cases deformity can be rectified by one of the methods already described. If, however, there is bony anchylosis in an attitude of marked flexion the limb may be straightened by the removal of a sufficient wedge of bone from the joint. The deformity may be remedied almost equally well by linear osteotomy of the femur just above the joint, and this operation is to be preferred in young subjects, as no bone is removed.

Genu valgum may be corrected by a similar operation. (See Osteotomy for Knock-knee.)

Prognosis. The most important statistical evidence on the course and the outcome of tuberculous disease of the knee-joint in childhood has been presented by Gibney. The statistics completed in 1892 were the result of an investigation of 499 cases treated during a period of twenty years, 1868–1887. In but 300 of these could definite information be obtained.[1]

Eighty-seven per cent. of the cases were in children, and 51 per cent. of the patients were less than five years of age at the inception of the disease.

[1] American Journal of the Medical Sciences, October, 1893.

The cases were divided into three classes, according to the treatment that had been followed :

1. The expectant treatment. In this class no apparatus was employed, or, if employed, it was inefficiently used.

2. The fixation treatment. In this class the joint was more or less efficiently splinted, but not protected from impact with the ground.

3. The protective treatment. In this class the joint was both splinted and protected from jar, and the mechanical treatment was efficient.

The results were classified as follows:

	Total.	Excisions.	Amputations.	Deaths.	Under treatment.	Cured.
Expectant	71	5	3	3	9	51
Fixation	190	9	1	35	31	114
Protection	39	0	0	2	11	26
	300	14	4	40	51	191

Mortality. The total deaths in the 300 cases were 40 (13.3 per cent.); 26 of these were from causes directly or indirectly connected with the disease (8.6 per cent.), viz.:

Operative shock	1
Prolonged suppuration	16
Tuberculous meningitis	6
Phthisis	3
	26
Intercurrent diseases	14
	40

Function. The functional results as regards motion in the cases in which conservative treatment was continued to the end, including the cases still under observation, 242 of 300, were as follows :

	Total.	Motion retained.	Anchylosed.
Expectant	60	44 or 7 per ct.	16
Fixation	145	113 " 77 "	32
Protection	37	34 " 95 "	3
	242	191 or 79 per ct.	51

Of the 191 patients who retained a movable joint, 74 had had abscesses, 3 or more cicatrices being present in 39.

As to the range of motion, in 74 it was from 45 degrees to

normal and in 41 more than 90 degrees; thus 30 per cent. of the patients retained a fair range of motion.

Deformity. In 51 cases anchylosis was present; in 16 of these the limb was practically straight, in 35 it was flexed more than 30 degrees (69 per cent.).

These statistics again illustrate the great tendency toward deformity, when during the growing period there is anchylosis at the knee from whatever cause.

In the 191 cases in which motion was retained the limb was practically straight in 125 (65 per cent.). In 49 others the flexion was less than 25 degrees, and in but 16 could the deformity be classed as bad (8 per cent.).

In 10 cases only did relapse occur after apparent cure.

In but 16 of the 449 cases was there involvement of other joints while the patients were under observation (3.2 per cent.). In 8 of these the spine was involved, in 2 the hip, and in 6 other joints.

The influence of age upon the death-rate and the ultimate causes of death are illustrated by Koenig's statistics, the death-rate being much higher, at least in the cases in early childhood, than in this country.

According to Koenig's statistics, the death-rate, direct and indirect, from disease of the knee-joint, was as follows:

323 children	(1 to 15 years of age),	deaths . .	65 = 20 per cent.
225 patients	(16 " 30 " "),	" . .	61 = 24 "
68 "	(31 " 40 " "),	" . .	30 = 44 "
74 "	more than 40 years of age	" . .	45 = 60 "

Causes of Death.

Deaths from causes not connected with the disease . 14 = 2 per cent.
" following operations . . . . . 18 = 2.5 "
" caused by tuberculosis, 141 = 22.5 per cent. of all cases and 80 per cent. of all the deaths.

Tuberculosis of the knee	1
" " lungs	94
General tuberculosis	30
Tuberculous meningitis	7
Acute miliary tuberculosis	3
Tuberculosis of other parts	6
	141

It may be noted that 16 of the 40 deaths in Gibney's cases were due to prolonged suppuration, and that of 51 cases still under observation 26 had been treated for ten years or longer, and were still uncured. This indicates that in a larger proportion of the cases conservative methods should have been supple-

mented by more radical treatment. Still, taken as a whole, the results, although the mechanical treatment was, in many instances, far from efficient, are much better than any others that have been presented.

General Conclusions. On this evidence the following conclusions seem to be justified. The death-rate in childhood from all causes should be less than 10 per cent. The duration of treatment is from two to five years. Recovery with a useful range of motion, when the diagnosis has been made at an early stage and when efficient mechanical treatment has been employed, may be predicted in 50 per cent. of the cases.

Deformity can always be prevented by treatment and by supervision. Under favorable conditions radical operations are not often indicated, but when indicated they should not be delayed too long. Amputation of the limb should prevent death from prolonged suppuration. In a certain proportion of cases the disease may be cut short by early exploratory operations, for the removal of foci of disease in the bone before the joint has become involved.

Although the benefits of protective treatment are as evident in disease of the adult as in childhood, yet early operation is often indicated in this class, because of the necessity for shortening the period of disability, and because excision assures a straight and useful limb.

CHAPTER X.

NON-TUBERCULOUS AFFECTIONS AND DEFORMITIES OF THE KNEE-JOINT.

Strains and Injuries of the Knee in Childhood.

Injury of the knee in childhood may cause local discomfort and persistent flexion of the leg, even when but little synovial effusion is present. In this class of cases the application of a plaster bandage, under sufficient traction to overcome the deformity, is of service in placing the part at rest and preventing further injury. The importance of treating promptly slight injuries of the joints in childhood, especially in the class of patients predisposed to tuberculous infection, has been mentioned already in the consideration of hip disease.

Muscular "cramp," a form of tetanic contraction, induced possibly by injury, which fixes the limb in a flexed or extended position, is sometimes seen in children of a susceptible or nervous temperament. The treatment is similar to that of strains.

Synovitis.

Acute traumatic synovitis is properly treated, immediately after the injury, by splints, by elevation of the limb, by the application of ice-bags and the like ; but after the acute symptoms have subsided the absorption of the effused fluid is aided by functional use of the limb, if the joint is properly protected. One of the most efficient methods of treatment is that by means of the adhesive plaster strapping advocated by Cottrell and Gibney. The entire surface of the knee, except a narrow space in the popliteal region, is firmly strapped with overlapping layers of adhesive plaster, extending from the upper third of the leg to the middle third of the thigh ; and over this a flannel bandage is applied ; or if the leg is swollen, the entire limb should be firmly bandaged with elastic stockinette bandage, from the toes to the upper third of the thigh in addition (Fig. 267). The adhesive plaster serves as a support which allows a certain degree of motion, sufficient to stimulate the circulation, and thus to hasten the restoration of

the normal condition. If greater compression is desired, the entire joint may be covered with the adhesive plaster as suggested by Hoffmann.[1] A pad of cotton is placed in the popliteal space, a close-fitting stocking leg is drawn over the knee, and about this circular bands of plaster are drawn as tightly as the comfort of the patient will permit. The adhesive plaster strapping is renewed from time to time, as the swelling diminishes, and its use is continued until the symptoms have entirely disappeared.

Chronic synovitis may be treated in a similar manner, although if the effusion is persistent the fluid may be removed by aspiration. If the ligaments are lax, a supporting brace may be required for a time (Fig. 176). Massage and exercises and static electricity are of service in the stage of recovery to restore the strength and activity of the supporting muscles.

Infectious Arthritis.

Suppurative arthritis of this as of other joints should be treated by free incisions, and efficient drainage should be assured. If this cannot be attained by ordinary methods the capsule should be widely opened and the patella divided by means of a transverse anterior incision. The interior of the joint may then be completely exposed by flexing the leg to an acute angle, as suggested by Mayo. Mechanical protection is usually required after the immediate symptoms are relieved. The subject is considered more at length elsewhere. (See Chapter VI.)

Osteoarthritis.

In this disease several joints are usually involved, but occasionally the affection may be confined to the knee. The early symptoms are stiffness, discomfort, and pain more noticeable in damp weather, and often creaking sensations in the joint are appreciable to the patient. At intervals the symptoms may be more acute and the joint becomes hot and swollen; as a rule, however, they are subacute in character. The progress of the affection is slow, the joint becomes somewhat enlarged and irregular in outline, the range of motion becomes more restricted, and flexion of the limb after a time persists. (See Rheumatoid Arthritis, page 274.)

Treatment. The general and constitutional treatment does not require especial consideration here. Locally massage and

[1] New York Medical Journal, January 27, 1900.

the hot-air bath may add to the comfort of the patient and increase the mobility of the joint, in the early stage of the affection at least. Static electricity has been employed with advantage in certain cases. The application of the cautery and stimulating liniments are useful in relieving pain, and the support of a flannel bandage adds much to the comfort of the patient. In many instances a brace (Fig. 176) may be employed with advantage to lessen the strain upon the part. Operative removal of the hypertrophied synovial membrane, loose bodies or irregular projections of bone that may interfere directly with movement, is sometimes of service. Excision is a final remedy in extreme cases.

Prepatellar Bursitis.

Synonym. Housemaid's knee.

A chronic enlargement of the bursa lying over the patella and its ligament is common among those who have to kneel much of the time; hence the popular name. Occasionally cases of acute bursitis, in which there is considerable effusion into the sac, are seen, and these are sometimes mistaken for synovitis of the knee.

Treatment. In acute cases strapping the front of the knee with strips of adhesive plaster which will limit motion and provide compression is an effective treatment. If the effusion is considerable it may be relieved by aspiration. In chronic cases cure can be attained only by the removal of the thickened sac.

Pretibial Bursitis.

Beneath the ligamentum patellæ, occupying the space between the tendon and the periosteum of the tibia, is the deep pretibial bursa. It is, according to the investigations of Lovett,[1] as wide or somewhat wider than the tendon; its upper border is on a level with the joint, its lower border reaches to the tubercle of the tibia, and, being slightly longer on the outer than on the inner border, it is somewhat triangular in shape. It does not communicate with the knee-joint.

Enlargement of this bursa is, as a rule, the result of injury, but, as bursitis elsewhere, it may be a complication of infectious diseases, rheumatism and the like.

Symptoms. The symptoms are stiffness at the knee and pain on sudden movement, especially when strain is exerted on the

[1] Boston City Hospital Reports, 8th series, 1897.

tendon by complete flexion or extension of the leg as in active use. The tubercle of the tibia seems enlarged and is sensitive to pressure, and a swelling on either side of the ligament is usually evident.

Treatment. The affection, if at all acute, may be treated by relieving the strain and pressure on the tendon, by fixation of the limb for a time in a plaster bandage or other form of splint. Later the adhesive plaster strapping will provide sufficient fixation and pressure. The absorption of the fluid may be hastened by the application of the cautery. If the swelling is persistent, the fluid may be removed by aspiration or incision or removal of the sac.

Enlargement of the Superficial Pretibial Bursa.

A small bursa, lying upon the insertion of the ligamentum patellæ, may become enlarged, causing an apparent hypertrophy of the tubercle of the tibia. It may be treated by strapping with adhesive plaster, and the prominent tubercle should be protected by some form of bunion plaster.

Injury of the Tibial Tubercle.

Osgood[1] has called attention to the fact that symptoms resembling those described may be caused by partial separation of the tubercle of the tibia. The treatment is primarily rest in the extended posture.

Bursæ and Cysts in the Popliteal Region.

Simple inflammation of the bursa lying between the inner head of the gastrocnemius and the semimembranosus muscle may cause a fluctuating swelling on the inner side of the popliteal region. It may be treated by compression or by incision as may seem advisable. Cysts in the popliteal region usually communicate with the knee-joint and are complications of rheumatic or tuberculous disease. They are of interest principally from the diagnostic standpoint.

Internal Derangement of the Knee-joint. (Hey.)

The term internal derangement signifies sudden interference with the function of the joint which may be due to (*a*) loose

[1] Boston Medical and Surgical Journal, January 29, 1903.

bodies in the joint ; (*b*) displacement or fracture of a semilunar cartilage ; (*c*) other injury.[1]

Loose Bodies in the Knee-joint. Loose bodies in the knee-joint may be composed of portions of fibrin, fragments of synovial membrane, or bits of cartilage or bone, and the like. In certain forms of synovial tuberculosis and osteoarthritis these loose bodies may be present in large numbers, but from the therapeutical standpoint the important cases are those in which the joint is otherwise normal. In this class the foreign body is sometimes detected by the patient as a smooth, movable object on one or the other side of the patella ; but in many instances the first sign of its presence is interference with the function of the joint. After a sudden movement or when the knee has been flexed, as in the kneeling position, or without appreciable cause, severe pain in the knee is felt and the joint may be fixed in the position of flexion. By massage, manipulation, or spontaneously the foreign body is dislodged from between the surfaces of the bones and movement becomes free and painless, but discomfort remains for a time and in most instances synovial effusion follows. These symptoms recur at intervals, and the disappearance of the movable body from its accustomed place at such times demonstrates its relation to the disability.

Displacement of a Semilunar Cartilage. Displacement of a semilunar cartilage is usually of traumatic origin. The internal cartilage is usually affected, and it appears to be caused most often by an outward twist of the tibia upon the femur. The patient's limb is fixed in the attitude of flexion, and in certain instances an irregularity may be detected at the inner and upper border of the tibia.

To replace the cartilage the leg should be flexed, then suddenly extended and rotated inward. In some instances an anæsthetic may be required. The displacement is followed by discomfort and synovial effusion. The accident having once occurred, is likely to recur ; the patient recognizing the character of the movements that are likely to cause the displacement, also the proper manipulation for its replacement.

Injury. In other instances somewhat similar symptoms may follow injury at the knee, pinching of the synovial membrane, bruising or fracture of the cartilage, or a strain of one of the ligaments within the joint, being assigned as causes. In cases of

[1] W. H. Bennett. Lancet, January 6, 1900.

this character, in which symptoms recur from time to time, the joint becomes weak and insecure, partly because of the repeated synovial effusion and partly because of the muscular relaxation.

Treatment. If the patient is seen immediately after the displacement or injury the limb should be fixed in a plaster bandage for four weeks or more to allow for reattachment of the displaced part. Afterward it may be protected by the adhesive plaster strapping, and when the effusion has been absorbed massage and exercises for strengthening the muscles should be employed.

In the more chronic cases in which the ligaments are lax, a brace which will permit anteroposterior motion, but prevent lateral mobility, may be required. The Campbell brace (Fig. 176) used by Shaffer, is a light and effective support that interferes little, if at all, with the use of the limb.

If the diagnosis of displaced or fractured cartilage can be verified, and if it is the cause of persistent disability, it should be removed. And the same may be said of isolated foreign bodies, which are known to be the cause of the symptoms.

Under the Esmarch bandage the joint is opened by an incision about three inches in length on the anterolateral aspect of the joint. After the capsule is opened the leg is flexed to bring the cartilage into view. If loose it is then separated from its attachments with a tenotomy knife and is removed. The capsule is then united with a fine catgut, the wound is closed, and a plaster bandage is applied. At the end of a week or more the patient may walk about. At the end of a month the adhesive plaster strapping may replace the bandage. Perfect functional recovery is the rule. The treatment of hypertrophied and congested synovial membrane, or loose bodies, is conducted in a similar manner.

Acquired Genu Recurvatum.

Synonym. Back knee.

Genu recurvatum, as the name implies, is a deformity in which the knee is habitually overextended.

Etiology. Acquired genu recurvatum may be a simple local deformity, or it may be secondary to weakness or distortion of other parts. Local or primary genu recurvatum may be an effect of rhachitis, or of disease or injury of the femur or tibia. In this form the femur may be curved sharply forward above the joint, or the upper extremity of the tibia may be bent backward

at the epiphyseal junction, and flexion may be limited by the obliquity of the articulating surfaces.

More often the deformity is secondary. It may be, for example, an effect of equinus, either congenital or acquired, in which the knee is strained by the effort of the patient to place the heel upon the ground. It may be caused by the use of a brace in the treatment of hip disease, if the knee-joint is not properly supported, and it is often seen also as a result of disease at this joint, for which no apparatus has been employed. It even appears in some instances on the sound side, apparently as a form of compensation for the shorter limb (Fig. 189). It is one of the comparatively infrequent complications of disease at the knee-joint, in which the leg has been supported by the brace in an extended or overextended position, or in which the growth at the epiphyseal cartilages of the femur or tibia has been irregular. In rare instances it is the direct result of traumatism, as when the limb has been suddenly forced into an overextended position, and the posterior ligaments, and possibly the crucial ligaments also, have been ruptured or weakened. It is most often, however, an accompaniment of paralysis of the posterior thigh muscles or of the gastrocnemius muscle, or both. A slight degree of overextension at the knees is not uncommon in children who have the so-called loose joints.

In many cases genu recurvatum is combined with a varying degree of knock-knee, and there is often an abnormal mobility at the joint that allows a certain amount of posterior displacement of the tibia. In extreme cases of this class there may be well-marked subluxation.

Symptoms. The symptoms, aside from the deformity, are weakness and insecurity caused by the hyperextension when weight is borne. If the deformity is extreme, the strain upon the weakened parts usually causes discomfort. Flexion is rendered difficult because of the abnormal relation of the joint surfaces and of the accommodative changes in the ligaments and muscles, so that in extreme cases the patient swings the leg along in the extended or overextended position.

Treatment. If the recurvation is caused by deformity of the bones, the normal relations may be restored by osteotomy of the tibia or femur, as may be indicated. Deformity secondary to distortions elsewhere may be treated by remedying the primary cause.

Traumatic genu recurvatum may be treated by fixation in the flexed position until the repair is complete, afterward by massage

and support if necessary. The ordinary form of overextended knee, combined with lateral mobility, must be supported by a brace which permits only anteroposterior motion to the normal limit or slightly less. Whenever possible massage and exercises should be employed.

Congenital Genu Recurvatum.

Synonym. Anterior displacement of the tibia.

The most common of the congenital deformities at the knee is the so-called genu recurvatum, in which the knee is bent somewhat backward ; or, in other words, the leg is hyperextended on

FIG. 261.

Congenital genu recurvatum. (Hoffa.)

the thigh. The condition is often spoken of as an anterior dislocation, but there is no actual displacement, except in the extreme cases in which the tibia may be turned directly forward on the femur, even to a right angle or less. In the ordinary cases the range of extension is merely exaggerated, while flexion is limited or checked, principally by adaptive shortening of the quadriceps extensor muscle (Fig. 261). In some cases there may be changes in the direction of the articulating surfaces in adaptation to the deformity of the femur and tibia.[1]

The appearance in well-marked genu recurvatum is very peculiar ; it is as if the patient's leg were reversed, for the popliteal

[1] Delanglade. Revue d'Orthopédie, May, 1903.

depression has become a prominence and the range of overextension seems to represent normal flexion. In such cases the leg may be brought to the straight line, but greater flexion is resisted by the retracted tissues, and when the pressure of the hand is removed the leg is drawn back to the deformed position by the contraction of the quadriceps extensor muscle.

Other Deformities and Malformations. Genu recurvatum is not infrequently accompanied by varus or valgus deformity at the knee, more often by the latter, and by laxity of the ligaments. In many instances the patella is absent or is rudimentary, and not infrequently the deformity is accompanied by malformations or defective development of other parts.

Seventy-eight cases were collected by Potel.[1] In 37 instances the deformity was limited to one side; in the others both limbs were affected. In 50 cases the condition of the patella was noted; in 26 of these it was absent or rudimentary. Twenty of the cases were accompanied by talipes.

Etiology. The deformity in cases of simple recurvatum may be explained by an abnormal and fixed position *in utero*, and in cases seen soon after birth the mechanism is clearly shown by the habitual attitude. The thighs are sharply flexed on the body; the dorsal surfaces of the hyperextended knees are in relation to the abdomen, while the feet may be brought into contact with the face or trunk, according to the degree of deformity. The retarded development of the quadriceps extensor muscle explains the rudimentary patella which is often an accompaniment of the deformity.

Treatment. The treatment of the hyperextended knee is very simple. It consists in massage of the atrophied and contracted muscles, combined with more or less forcible manipulation in the direction of flexion. If, as is often the case, the leg seems to be drawn forward by spasmodic muscular action, the methodical massage should be combined with the use of a simple posterior splint.

In the more extreme cases manual force may be applied under anæsthesia, and the deformity may be overcome at one or several sittings, according to the resistance of the contracted parts. The leg is then fixed in a flexed position until the tendency to recurrence has been overcome. When the child begins to walk a light lateral brace may be necessary to insure perfect functional use of

[1] Étude sur les Malformations Congénitale du Genou. Lille, 1897, Imp. L. Danel.

the joint, as in many instances laxity of ligaments and muscular weakness may persist for a long time.

Rudimentary or Absent Patella.

As has been stated, a rudimentary patella is a frequent complication of genu recurvatum or of any congenital defect or deformity of the knee or limb that involves imperfect development of the quadriceps extensor muscle. In many cases of this type it is impossible to distinguish the patella during the early months of infancy, but later a minute patella appears that slowly increases to an approximately normal size.

Absence of patella under the same conditions is less frequent, although Potel collected one hundred cases from literature.

Treatment. The treatment of rudimentary patella is included in the massage and stimulation of the atrophied or rudimentary muscle with which it is usually associated, and the support that the weak or deformed knee may require.

Congenital Displacement of the Patella.

The patella may be displaced upward as a result of extreme genu recurvatum, and in rare instances it may be displaced inward or downward, but far more often the displacement is outward. Fifty cases of this form are recorded, in most of which it was a complication of congenital genu valgum.

Slipping Patella.

This term is applied to an abnormal laxity of the supporting tissues that allows occasional displacement of the patella upon or to the outer side of the external condyle.

Etiology. This disability is more common among females than males, and is more often unilateral than bilateral. The abnormal mobility may be an inherited peculiarity; it may be due to weakness of the quadriceps extensor muscle, or to imperfect development of the patella or of the external condyle; or the original displacement may have been due to injury. In many instances, however, the predisposing cause is genu valgum, as a consequence of which the patella is carried toward the external condyle.

Weimuth[1] has collected 66 cases. Of these 32 were of con-

[1] Deutsche Zeits. f. Chir., Bd. lxi. Bade, Zeits. f. Orthop. Chir., 1903, Bd. xi. p. 3.

genital, 14 of traumatic (rupture of internal ligaments), and 20 of pathological origin (knock-knee).

Symptoms. If the slipping of the patella is a frequent occurrence it causes comparatively little pain, but when the parts are less relaxed the displacement is likely to be followed by a certain amount of effusion into the joint and by the symptoms of a sprain. It is usually the result of a misstep or sudden movement when the thigh muscle is relaxed or of extreme flexion of the leg. As a rule, there is a sense of insecurity and weakness at the knee in those who are subject to the accident.

Treatment. The treatment varies according to the condition of the parts about the joint. If the displacement is the direct result of violence the leg should be fixed for a time in a plaster bandage, which may be replaced by the adhesive plaster strapping or a knee-cap. Later massage and muscle training should be employed. In cases in which the slipping has become habitual and particularly when the ligaments of the joint are much relaxed, a light brace should be employed to prevent lateral motion and to limit the range of flexion at the joint, if this predisposes to the displacement (Fig. 176).

Operative Treatment. If the position of the patella that predisposes to the further displacement is a consequence of genu valgum the rectification of the deformity will, as a rule, remedy the secondary disability. If the displacement appears to be caused by laxity of the capsular ligament, as well as by the abnormal position of the patella, an operation for the purpose of limiting the mobility and restoring the proper relation of parts may be conducted in the following manner: A long, curved incision is made about the inner side of the knee, the lower extremity of which crosses the ligamentum patellæ. The skin flap having been reflected, the contracted capsule may be divided on the outer side without disturbing the synovial membrane. The patella is then forced inward and the redundant tissue on the inner side is folded and sutured, or a section of the capsule may be removed, sufficient in size to hold the patella in its proper position. In extreme cases the tubercle of the tibia, with the attached tendon, may be removed and reimplanted on the inner aspect of the tibia, as performed by Wolff and Walsham.

The limb should be held in the extended position for a time, and it should afterward be supported by a brace or knee-cap for several months. Subsequently massage and exercise for restoring the tone of the weakened muscle should be employed.

The operation for the dislocated patella has been performed in childhood by Pollard,[1] and in early infancy by Bajardi.[2]

The method described is that of Bradford.[3]

Elongation of the Ligamentum Patellæ.

In certain cases the ligamentum patellæ may be abnormally long, so that the patella lies habitually above its proper position. This elongation may be one of the evidences of general relaxation of the ligaments of the knee, and thus a predisposing cause of the slipping patella or of abnormal mobility at the knee-joint.

Etiology. The elongation of the tendon may be a congenital peculiarity or it may be acquired. It is most often observed as an effect of anterior poliomyelitis or of hemiplegia or paraplegia.

Symptoms. The symptoms of elongation of the ligamentum patellæ, as distinct from those of the general laxity of the ligaments that is often present, are weakness and disability, usually noticeable on walking up or down stairs, or after overexertion. Shaffer, who first called attention to the disability from this cause, thinks that it may be a predisposing cause of displacement of the semilunar cartilages.[4]

Treatment. In this, as in other forms of insecurity or of abnormal mobility at the knee, a brace that allows only antero-posterior motion will, as a rule, relieve the symptoms. If the ligament is of such a length as to require it, it may be shortened, or the tubercle of the tibia may be removed and implanted at a lower point, as suggested by Walsham.[5]

Other Congenital Deformities at the Knee.

Congenital displacements are uncommon. As a rule, they are incomplete and are caused by laxity of the ligaments and by defective formation of the bones or other parts.[6]

Snapping Knee.

A very slight form of partial recurrent displacement is the snapping or clicking knee not uncommon in early infancy, in which the tibia on sudden extension of the limb springs forward or rotates outward on the femur with an audible snapping sound.

[1] Lancet, 1891, vol. i. p. 988.
[2] Archiv di Ortoped., 1894, p. 209.
[3] Transactions American Orthopedic Association, vol. viii. p. 228.
[4] Ibid., vol. xi.
[5] Medical Week, February 17, 1893.
[6] Drehmann. Die Cong. Lux. des Kniegelenks. Zeits. f. Orth. Chir., 1900, Bd. vii. H. 4.

This movement appears to be the result of voluntary muscular contraction combined with laxity of ligaments. In some instances the subluxation appears to cause pain or discomfort. The ability to displace the tibia on the femur by muscular action is sometimes found in older subjects. Occasionally the snapping may be caused by slipping of the biceps tendon.

Treatment. The treatment of congenital dislocations or subluxations of the knee consists in reposition, support, and massage of the weak part. The snapping knee may be supported by a flannel bandage, or, in the more marked type of laxity of ligaments, it may be fixed for a time in a brace. Complete recovery is the rule.

Congenital Contraction at the Knee.

Slight limitation of the range of extension of one or both knees is not infrequent. As a rule, it is easily overcome by massage and manipulation. In the more extreme cases there may be an accommodative forward bending of the lower extremity of the femur, as in certain cases in which flexion follows anchylosis.

General Contractions.

Congenital contraction at the knees of a more marked and resistant form may be combined with flexion contraction at the hips, or it may be one of a series of contractions at other joints. In the latter instance other congenital deformities, such as club-hand or foot, or evidences of defective development are usually present. For example, certain joints may be fixed in flexion or fixed in extension. In some instances the contraction or the partial anchylosis appears to be due simply to long-continued fixation *in utero*, and to consequent non-development of the muscles. In others it appears to be a complication of so-called fœtal rhachitis.

Treatment. The treatment consists in regular massage and manipulation, with the aim of increasing the range of motion. Deformity, if present, may be rectified in the usual manner.

Prognosis. The prognosis depends upon the cause of the contraction or fixation. In most instances, under careful and continued treatment, the range of motion may be in great degree restored.

CHAPTER XI.

DISEASES AND INJURIES OF THE ANKLE-JOINT.

Tuberculous Disease of the Ankle-joint.

Disease of the ankle-joint is the third in the order of importance, although it is far less common than is disease at the knee.

In five consecutive years 1788 cases of tuberculous disease of the joints of the lower extremity were treated at the out-patient department of the Hospital for Ruptured and Crippled. In 54.1 per cent. of these the hip-joint was affected; in 36.2 per cent. the knee-joint, and in but 9.7 per cent. the ankle-joint.

Fig. 262.

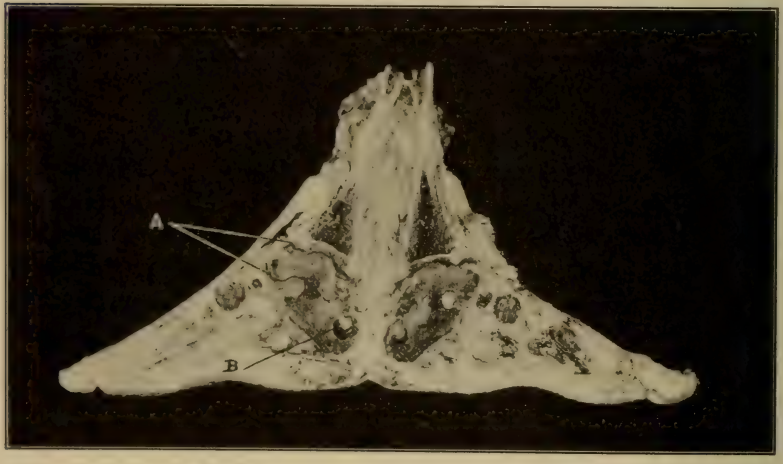

Tuberculous disease of the ankle and tarsus. A, disease of the ankle and subastragaloid joints. B, cavity in the os calcis containing sequestrum.

Pathology. The pathology of tuberculous disease at the ankle differs in no essential particular from that of disease of the hip and knee. It does not, therefore, call for special consideration. It is of interest to note, however, that abscess is a more common complication at this than at the other joints.

In 30 final results of disease at the ankle reported by Gibney,[1]

[1] American Journal of Obstetrics, April, 1880.

abscess was present in 25 (83 per cent.). In 78 final results reported by Prendlsburger[1] abscess was present in 68 (87 per cent.), as contrasted with a percentage of 69 and 51 at the knee and hip, respectively. This greater liability to abscess is very possibly apparent rather than actual, since the ankle-joint is so superficial that fluctuation may be detected here that would be overlooked at the hip. And because the tissues about the joint readily allow spontaneous opening at an early period, before sufficient time has elapsed to permit of spontaneous absorption.

Situation of the Disease. Otto Hahn[2] has recently investigated the cases of tuberculous disease of the ankle and foot treated at Tübingen during the past fifteen years. These cases were 704 in number in 685 patients, in 19 both feet having been involved.

In 309 of the cases the disease was of the ankle-joint. Of these 51 per cent. were osteal in origin. The primary focus was in the internal malleolus in 11, the external in 7, in both in 5. It was in the astragalus in 116 cases.

In 16 instances the disease of the ankle was secondary to primary infection of the os calcis, and in 5 cases both the astragalus and the os calcis were diseased.

Etiology. The etiology of tuberculous joint disease does not require further comment. It may be noted, however, that tuberculous disease at the ankle is relatively more common in later childhood and adult life than is the same affection at the knee and hip.

Of 1000 cases of disease of the hip-joint, 12 per cent. were in patients more than ten years of age.

Of 1000 cases of disease of the knee-joint, 25 per cent. were in patients more than ten years of age.

Of 339 cases of disease of the ankle-joint, 30 per cent. were in patients more than ten years of age.[3]

Of the 339 patients 177 were males (52.2 per cent.); 162 were females (47.8 per cent.). The disease was of the right ankle in 173 cases; of the left in 166.

[1] Loc. cit.

[2] Beiträge zur klin. Chir., 1900, Bd. xxvi. H. 2.

[3] Statistics from Hospital for Ruptured and Crippled.

AGE AT INCIPIENCY OF ANKLE-JOINT DISEASE IN 339 CONSECUTIVE CASES TREATED AT THE HOSPITAL FOR RUPTURED AND CRIPPLED.

1 year or less	5	24 years old	2
2 years old	42	25 " "	3
3 " "	43	26 " "	3
4 " "	44	27 " "	4
5 " "	34	28 " "	4
6 " "	24	29 " "	2
7 " "	19	30 " "	2
8 " "	8	31 " "	0
9 " "	9	32 " "	1
10 " "	9	33 " "	2
11 " "	11	34 " "	1
12 " "	8	35 " "	0
13 " "	4	36 " "	2
14 " "	4	37 " "	2
15 " "	4	40 " "	4
16 " "	6	43 " "	1
17 " "	2	44 " "	1
18 " "	4	45 " "	4
19 " "	3	46 " "	2
20 " "	3	48 " "	1
21 " "	4	50 " "	1
22 " "	5		
23 " "	2		339

Of 658 patients 412 were males (62 per cent.); 246 were females (38 per cent.). In 27 the sex was not stated.

AGE OF THE PATIENTS TREATED FOR ANKLE-JOINT AND TARSAL DISEASE AT TÜBINGEN. (HAHN.)

	Males.	*Females.*	*Total.*
1 to 10 years	45	28	73
11 " 20 "	149	91	240
21 " 30 "	89	34	123
31 " 40 "	32	28	60
41 " 50 "	37	27	64
51 " 60 "	35	26	61
61 " 70 "	18	11	29
71 " 80 "	6	1	7
81 "	1	0	1
	412	246	658

Symptoms. The symptoms are usually subacute in character, and are often mistaken for sprain or rheumatism. In some instances they appear to follow an injury, but in the majority of cases in childhood no cause can be assigned. The ankle becomes sensitive to sudden movements; the patient limps, and discomfort after overuse and pain at night become noticeable. The limp differs in character from that caused by hip or knee disease. The patient walks with the foot rotated outward, bearing the weight upon the heel and upon the inner border, active leverage "spring" being avoided.

Deformity. The primary deformity of ankle-joint disease in the subacute cases is valgus, induced apparently by the continued use of the limb in the passive attitude. In more advanced cases it becomes equinovalgus, and when the limb is no longer capable of supporting weight, but is held pendent, the equinus deformity predominates, due partly to the force of gravity and partly to the muscular spasm.

FIG. 263.

Tuberculous disease of the ankle.

As has been stated, in the early stage the symptoms are those of a persistent, somewhat painful disability at the ankle, causing *stiffness*, *limp*, and at times *pain;* later *swelling* and *deformity* appear.

Physical Examination. The joint is usually somewhat enlarged. In some instances the swelling is uniform; in others it is localized in front or behind one of the malleoli. This swelling is not, as a rule, like that of simple effusion into the joint, but the tissues have the peculiar elastic characteristic of thickening and infiltration. There is usually a perceptible increase in the local temperature, and pressure directly upon the malleoli causes discomfort. The voluntary movements of the joint are restricted,

and passive movements show the characteristic reflex muscular spasm, limiting both dorsal and plantar flexion.

Subastragaloid Disease. If the astragalus is primarily diseased, the symptoms are usually first apparent in the ankle-joint, but in certain cases the joint between the astragalus and the os calcis is first involved, the primary focus being in the os calcis. Disease at the subastragaloid joint is usually classed as ankle-joint disease, although the swelling is most marked at a point somewhat below the malleoli (Fig. 264).

FIG. 264.

Tuberculous disease of the subastragaloid joint.

In this form forced lateral motion of the os calcis causes discomfort, and the range of adduction and abduction of the foot is restricted, while dorsal and plantar flexion may remain completely free.

Diagnosis. The principles of differential diagnosis of tuberculous disease from other affections have been considered in detail in the description of disease of the spine and of the larger joints.

In childhood a chronic, painful disease confined to a single joint in which motion is limited by muscular spasm, and in

Fig. 265.

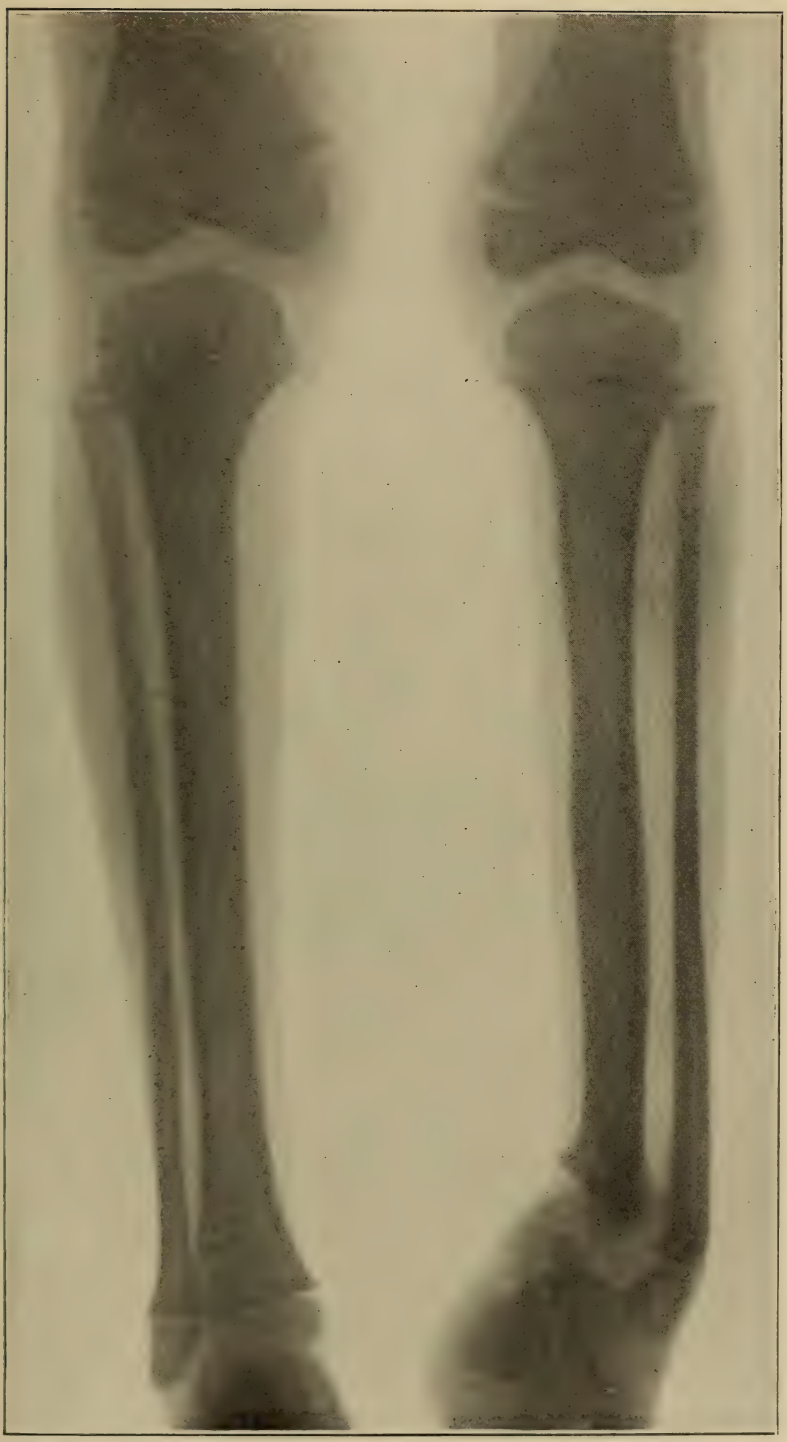

The epiphyses of the lower extremities at the age of six years, showing the effect of operative removal of bone at the ankle-joint for tuberculous disease at the age of three years, in causing subsequent deformity of the foot and shortening of the limb. Ossification is present at birth in the lower epiphysis of the tibia. It begins at the second year in the lower epiphysis of the fibula, but not until the fifth year in its upper epiphysis.

which there is a tendency to deformity, is almost certainly tuberculous in character.

In adult life also the same statement applies, and distinguishes tuberculous disease from *rheumatism*, *rheumatoid arthritis*, or other general affections. Forms of *infectious arthritis* may be differentiated by the history. *Sprains* or other injury may be distinguished by the history of the onset and by the absence of local signs of serious disease. In rigid *flat-foot* the symptoms are localized at the mediotarsal joint. It should be borne in mind, also, that the pain from a weak or injured foot is experienced, as a rule, only when it is in use; whereas, in tuberculous disease of the bone, pain is common when the part is not in use, and it may be particularly troublesome at night.

Treatment. In disease of this, as of other joints, functional rest is indicated. This necessitates fixation of the joint and stilting of the limb, efficient traction being manifestly impossible. The foot should be fixed in a light plaster bandage, extending from the extremities of the toes to the calf, at a right angle with the leg and in an attitude of slight supination, in order to guard against the tendency toward valgus. This deformity is very common after the cure of the disease, and it often subjects the patient to the additional discomfort of progressive flat-foot.

Reduction of Deformity. If the foot has become distorted before the patient is brought for treatment, the plaster bandage may be applied in the attitude of deformity, and at the subsequent applications of the dressing, when the muscular spasm is lessened, gentle manipulation will gradually overcome the malposition. In resistant cases immediate reduction of the deformity under anæsthesia may be advisable. Throughout the entire course of treatment the greatest attention must be paid to the attitude. Deformity is easily prevented, but is often very difficult to correct, especially during the later stages of the disease, when the tissues are infiltrated and sensitive, and especially if discharging sinuses are present.

Other retentive appliances may be employed, but they are inferior to a properly applied bandage, which holds its place by accuracy of adjustment, which most effectively prevents motion, and which exercises a certain degree of compression upon and general support of the swollen joint. The bandage is usually renewed at intervals of a month, but it may be retained indefinitely if it is properly protected by a light shoe or slipper. The Bier method of passive congestion may be applied at the ankle

by means of a bandage above the upper border of the plaster support. And the adhesive plaster strapping may be used beneath the plaster bandage if local compression and more comprehensive support is desired.

The most satisfactory brace to serve as a stilt in connection with the local support is the Thomas brace, which has been described in the section on disease of the knee-joint (Fig. 258).

When patients are treated efficiently the discomfort or inconvenience attending the disease is slight. As a rule, the swelling of the joint becomes more localized and finally an abscess appears beneath the skin. It is then advisable to remove the fluid and other contents by means of a simple incision. In most instances a sinus persists for a time. If the discharge is slight, the part may be dressed with ichthyol, balsam of Peru or other application, and the whole inclosed again in the plaster bandage; or, if it be more profuse, an opening may be made and the dressing applied outside the plaster bandage.

Operative Treatment. Early operation, especially of a gouging character, should be avoided. An effective operation of this class often involves the sacrifice of bone that would be spared in the natural cure, and it entails an irregularity in the growth and causes deformity in after-life that may be irremediable (Fig. 265).

Similar operations in the treatment of fistulæ, or abscess, while the tissues are thickened and œdematous, and while the disease within the joint is active, should be postponed until the process of repair is more advanced. During the stage of convalescence, however, cure may be hastened by the removal of persistent foci of disease, or sequestra in the bone, or tuberculous tracts in the overlying soft parts.

In the adult or adolescent, and in exceptional cases in childhood, operative removal of the disease may be indicated. If it is confined to the ankle-joint, the removal of the astragalus, which is usually the primary seat of infection, is the operation of choice.

The operation is performed under the Esmarch bandage; a curved lateral incision is made passing beneath the external malleolus from the neighborhood of the tendo Achillis to the anterior aspect of the joint. The lateral and capsular ligaments are divided, after which the foot may be displaced inward. The astragalus is exposed and it may be removed easily by dividing

the ligaments about its head and its attachment to the os calcis. All the diseased tissue in the soft parts and in the bone must be removed thoroughly. If the disease has not extended to the tarsus, and if it seems to have been completely removed, the wound may be closed, but in most cases it should be packed for a time with gauze. The after-treatment is conducted as if the operation had not been performed, support and fixation being continued until it is evident that the disease is cured.

Removal of the astragalus does not interfere to a marked extent with the function of the foot, nor does it cause noticeable deformity. As a primary operation, permitting inspection and the opportunity for thorough removal of all disease in the neighboring parts, it should always be performed in preference to extensive gouging, which is, as a rule, of little avail.

Prognosis. Disease at the ankle is not only less common, but it is less dangerous than that of the larger joints, because it is remote from important structures, and because there is less opportunity for the burrowing of infected abscesses. The duration of the disease here is, as a rule, shorter than at the knee or hip, and the final results in childhood are almost always excellent. Often free motion is retained at the ankle, and even if the astragalus be fixed by disease the mobility in the other joints of the foot is sufficient to compensate very effectively for the anchylosis. Shortening of the limb is of comparatively little consequence. It is not often more than an inch, and it may be absent. The growth of the foot is often considerably retarded, partly from disuse and partly because of the destructive effect of the disease upon the tarsal bones.

In the 30 cases reported by Gibney, treated expectantly, in which the mechanical treatment was far from effective, 6 patients recovered with normal motion; 11 with practically normal function. In 7 there was good motion. In 6 there was anchylosis, and in 3 persistent valgus. In all the limb was efficient. In 20 instances there was no limp, and in but 1 case was it marked. In no instance was a crutch, cane, or other support used. The average duration of the disease was three years and three months, a minimum of one year, a maximum of six years. There were 2 deaths, of which but 1 was dependent upon the disease, septicæmia being the cause assigned, though it is stated that practically all the bones of the tarsus were involved. In this case amputation was evidently indicated.

Tuberculous Disease of the Tarsus.

Tuberculous disease of the joints of the foot, not involving the ankle, is not uncommon.

In 386 of the 704 cases reported by Hahn, the disease was limited to the foot. In 141 cases the mediotarsal joint was involved; in 51 of these the disease was confined to this joint; in 46 the ankle was involved; in 29 the disease extended forward to the tarsometatarsal articulation, and in 16 the three joints were diseased. In 78 cases the tarsometatarsal joint was involved, in 33 of which the disease did not extend beyond this articulation.

Disease of Individual Bones. In these cases the distribution was as follows:

The astragalus	170;	disease confined to the single bone in	8
The calcaneum	200;	" " " " "	87
The cuboid	116;	" " " " "	18
The scaphoid	82;	" " " " "	2
The cuneiform bones	86;	" " " " "	8
Metatarsal bones	45;	in one-half of these the disease was of the first metatarsal, either alone or in connection with the adjoining cuneiform bone or phalanx.	

In a total of 1231 cases, including these and others reported by Audry,[1] Koenig,[2] Mondan,[3] Münch,[4] Spengler,[5] Vallas,[6] Czerny,[7] and Dumont,[8] the relative frequency of the disease in the bones of the foot and ankle appeared to be as follows:

Malleoli	96, 7.7 per cent.	Scaphoid	110, 8.9 per cent.
Astragalus	291, 23.6 "	Cuneiform bones	109, 8.8 "
Calcaneus	339, 25.9 "	Metatarsus	110, 8.9 "
Cuboid	154, 12.5 "	Phalanges	22, 1.7 "

Primary Disease of the Astragaloscaphoid Joint. In disease at this point the swelling is localized in front of the ankle on the inner side of the foot. Adduction is restricted, and the foot is often fixed in an attitude of persistent abduction.

Disease of other bones of the tarsus is indicated by the local swelling and sensitiveness. The disease sometimes involves the shaft of a metatarsal bone, or one of the phalanges, causing expansion and destruction, "spina ventosa."

Treatment of Tarsal Disease. Disease of the tarsus shows a marked tendency to extend from one bone to another until the entire foot is involved. Consequently if an early diagnosis is

[1] Revue de Chir., 1891.
[2] Schmidt's Jahrb., 1884, Bd. cciv.
[3] Deutsche Chir., l. 66.
[4] Deutsche Zeits. f. Chir., 1879, Bd. xi.
[5] Ibid., 1897, Bd. xliv.
[6] Deutsche Chir., l., 66.
[7] Volk. S. klin., v., No. 76.
[8] Deutsche Zeits. f. Chir., 1882, Bd. xvii.

made of a distinctly localized process prompt removal of the diseased bone is indicated; but in most instances the disease is too extensive to permit of its radical removal. In such cases operative intervention is contraindicated, and the treatment by protection, similar to that employed in disease of the ankle, is indicated. In childhood the prognosis is very good even when the disease is extensive, but in adult life amputation of the foot may be advisable because of the time required to assure a natural cure and because an artificial leg provides a better support than a stiff and sensitive extremity. Amputation is almost always indicated, if there is co-existent disease of the lungs.

Sprain of the Ankle.

The ankle is, from its position, especially liable to injury; in fact, the term "sprain" is popularly associated with this joint.

A sprain is most often caused by an unguarded movement, by which the foot is turned suddenly inward or outward, with sufficient force to injure the synovial membrane, to rupture some of the fibres of the muscles, to strain tendons and tendon sheaths, and even to rupture ligaments. If the foot is twisted inward the injury is most marked on the outer side of the joint; if outward, on the inner side of the ankle. In the slighter degrees of sprain the injury may be confined to the tissues about the joint, but in most instances there is effusion within the capsule, even hemorrhage when the injury has been severe.

Symptoms. The immediate symptoms of sprain are pain, often intense, of a throbbing character, swelling, heat, and in many instances discoloration of the surrounding parts, even extending over the leg and foot.

Treatment. If an opportunity for immediate treatment is offered, the swelling and the effusion of blood may be restrained by the application of elastic stockinette bandages from the toes to the knee. As much compression is exercised as the comfort of the patient will allow, and the bandage should be made sufficiently thick to prevent painful motion. If the injury has been severe and if the part is very sensitive to motion or jar, the joint, having been protected with cotton, may be fixed in a light plaster bandage. This may be cut down the front to allow for daily massage of the foot, ankle, and leg which is of great service in hastening the absorption of the effusion.

The use of hot air, hot and cold water, and static electricity, and the like are of service also in relieving the discomfort and

especially in stimulating the circulation of the blood, upon which repair depends.

By far the most effective treatment during the stage of recovery and as an immediate application for sprains of slighter degree, is the adhesive plaster strapping which has been popularized by Gibney. His method is as follows : Strips of adhesive plaster about three-quarters of an inch in width and from nine to eighteen inches in length are prepared. A long strip is placed with its centre beneath the heel, and the two ends are carried upward over the malleoli, to a point at the junction of the middle and lower thirds of the leg. A second strip is placed at the posterior extremity of the heel, and the two ends are carried forward somewhat beyond the tarsometatarsal junction on either

FIG. 266.

A method of applying adhesive plaster strapping for sprain of the ankle.

side. Another strip is then placed by the side of the first, and the fourth by the side of the second, until the entire ankle is smoothly covered, except for a space about two inches in width directly on the front of the ankle. One takes particular care to make the plaster fit well about the malleoli and reinforces it at the points of greatest sensitiveness. A light bandage is then applied and the patient is encouraged to use the foot in walking. The plaster may be applied in a variety of ways ; a satisfactory method is as follows, after the preliminary massage for the purpose of reducing the swelling :

One end of a strip of adhesive plaster about three feet long and three inches wide is applied to the lateral aspect of the leg just below the knee-joint ; it is carried down the side of the leg

over the malleolus, beneath the heel and arch, and up the other side to a point opposite the beginning, where it is fixed by a circular band about the calf. If the sprain is of the outer side of the ankle, sufficient tension is made upon the outer half of the plaster to hold the foot slightly abducted. If, as is more common, the sprain is of the inner side, the inner half is drawn firmly beneath the arch, carrying the foot toward inversion so that all strain may be removed from the sensitive part. This band of plaster is reinforced by one or more so that the lateral aspect of the ankle is completely covered. And in addition the entire ankle is then inclosed with narrow, overlapping strips which cover all the tissues well beyond the sensitive area. The foot and leg

FIG. 267.

The stockinette bandage.

are then bandaged to assure the adhesion of the plaster. When the joint is firmly held by the supporting plaster the patient can, as a rule, walk with comfort; and he is encouraged to do so, for functional use, provided it does not cause additional injury, is the most effective stimulant of the circulation; thus the patient applying, as it were, an automatic massage, cures himself.

As the swelling subsides the plaster strapping wrinkles, and it must be renewed, about three applications being required, as a rule, the last of which is allowed to remain until all of the symptoms have disappeared. Vigorous massage before applying the new dressing is of service in hastening the cure. It is perhaps needless to state that a preliminary shaving of the part will add somewhat to the comfort of the patient.

Chronic Sprain.

A chronic sprain may be the result of an inefficiently treated acute injury, in which an improper attitude originally assumed to spare the sensitive part finally becomes habitual. In other instances persistent disability may be the result of fixation of the joint for too long a time in splints. Such disuse causes atrophy of the muscles and of the bones as well (see Atrophy, page 241), while the effused material within and without the joint remains because of the imperfect circulation. The same disability may follow simple disuse of the injured part. It is more often observed in nervous individuals who exaggerate the importance of the injury and the discomfort that it causes. In such cases the limb may be discolored by venous congestion, the foot may be œdematous, and the movements may be limited by adhesions or by muscular adaptation to the habitual attitude.

In other instances the original injury may have caused a slight subluxation of the astragalus, sufficient to throw the foot into an attitude of abduction, in which it has become fixed by the secondary changes in the muscles and ligaments. In some cases of this class the original sprain was at the mediotarsal or at the subastragaloid joint, and its effect has been traumatic weak foot. It may be stated, also, that many of the so-called sprains of the ankle are simply injuries of a weak foot, a disability to which the treatment should be directed. (See the Weak Foot.)

Treatment. Treatment must be conducted with the aim of restoring the normal range of motion and so supporting the part that normal functional use may be permitted. If adhesions have formed and if the foot is persistently held in an abnormal attitude, forcible manipulation under anæsthesia may be required as a preliminary treatment, followed by fixation for a time in a plaster bandage, in the attitude directly opposed to that which has been habitual. In this class of cases the habitual attitude is usually one of equinovalgus; the foot should be fixed for a time, therefore, in a plaster bandage in a position of extreme varus, at a right angle with the leg, and upon it the patient is encouraged to bear his weight both in standing and walking. When all discomfort has disappeared, a support, usually a light leg brace to prevent lateral motion, and if the arch is depressed a foot plate also, should be worn for a time. The most effective curative agent is functional use, but massage, hot air, passive manipulation, and exercises are valuable accessories.

Injuries of this class are very amenable to treatment, conducted with the aim of restoring normal function, if proper support is provided during the period of pain and weakness.

Tenosynovitis.

The sheaths of the tendons about the ankle-joint, if involved in a sprain of the ankle, may cause persistent interference with

FIG. 268.

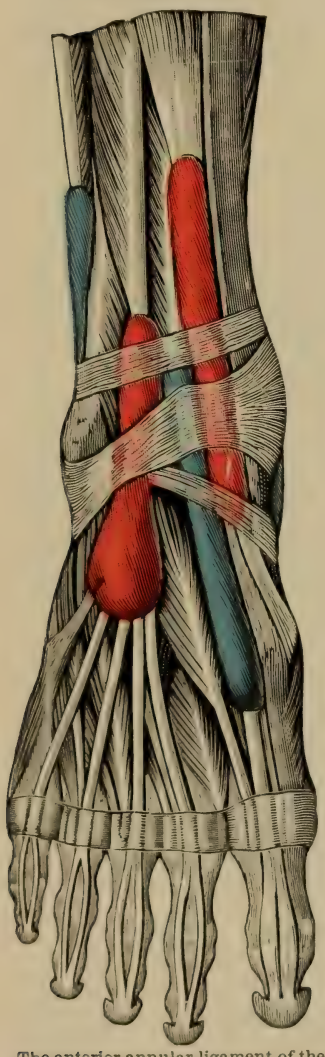

The anterior annular ligament of the ankle and the synovial membranes of the tendons beneath it artificially distended. (Testut, from Gerrish's *Anatomy*.)

FIG. 269.

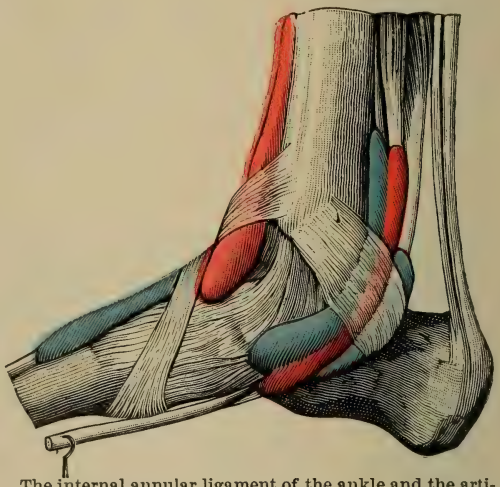

The internal annular ligament of the ankle and the artificially distended synovial membranes of the tendons which it confines. (Testut, from Gerrish's *Anatomy*.)

FIG. 270.

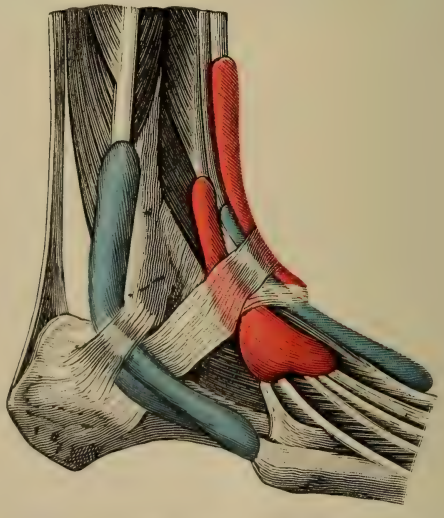

The external annular ligament of the ankle and the artificially distended synovial membranes of the tendons which it confines. (Testut, from Gerrish's *Anatomy*.)

function; or strain of a tendon and of its sheath may cause symptoms of disability when the joint is uninjured. The symptoms of acute tenosynovitis are discomfort on motion of the affected tendon, and this motion may be accompanied by a peculiar creaking which is apparent on palpation. In many instances there is slight local swelling and sensitiveness to pressure about the affected part, and the general movements of the foot that call the muscle into action are painful.

The arrangement of the tendon sheaths should be borne in mind. At the ankle-joint all the tendons are provided with sheaths; on the front of the foot are three—the sheath of the tibialis anticus, which extends from a point about two inches above the extremity of the malleolus to the scaphoid bone (Fig. 268); that of the extensor longus hallucis, from the annular ligament to the head of the first metatarsal, and the common sheath for the extensor communis digitorum, extending from a point about half an inch above the malleoli to about one inch below the annular ligament. Behind the internal malleolus are the common sheaths of the tibialis posticus and flexor longus digitorum, beginning about an inch above the extremity of the malleolus and extending to the astragaloscaphoid junction, and that of the flexor longus hallucis of about the same extent (Fig. 269). Behind the outer malleolus is the sheath of the two peronei, beginning one inch above the malleolus, dividing into two portions for the two tendons and ending just behind the tuberosity of the fifth metatarsal bone (Fig. 270).

Treatment. Simple traumatic tenosynovitis should be treated by rest and by compression. An effective treatment is strapping with adhesive plaster, so applied as to prevent the movements of the foot that cause discomfort. In more painful and persistent cases the use of a plaster bandage to assure absolute rest may be necessary. Cautery applied over the affected part is of service. Chronic tenosynovitis may follow injury or it may be the result of gonorrhœa or other infectious disease. In chronic cases when the palliative treatment is ineffective, thorough removal of the affected sheath is indicated. (See Achillobursitis.)

Tuberculous Tenosynovitis. A persistent and increasing swelling of a tendon sheath always suggests tuberculous disease. In such instances the sac is thickened and often contains the so-called rice bodies. Prompt and complete removal of the diseased sheath is indicated, and by this means a permanent cure may be attained in most instances.

Other Affections of the Ankle-joint.

The ankle-joint may be the seat of an infectious arthritis; it may be involved in an osteomyelitis of the tibia. It may be one of the joints affected in chronic rheumatism or rheumatoid arthritis, and occasionally Charcot's disease may appear in this situation. The principles of the treatment of these affections have been indicated elsewhere.

CHAPTER XII.

DISEASES AND INJURIES OF THE ARTICULATIONS OF THE UPPER EXTREMITY.

Tuberculous Disease of the Shoulder-joint.

Disease at the shoulder is very uncommon in childhood. In a total of 453 cases of tuberculous disease treated at the Vanderbilt clinic 210 were cases of Pott's disease. In 6 of the remaining 243 cases the disease was of the shoulder-joint (2.5 per cent.).

In 1883 consecutive cases of joint disease—Pott's disease being excluded—treated in the out-patient department of the Hospital for Ruptured and Crippled during the past five years, the

Fig. 271.

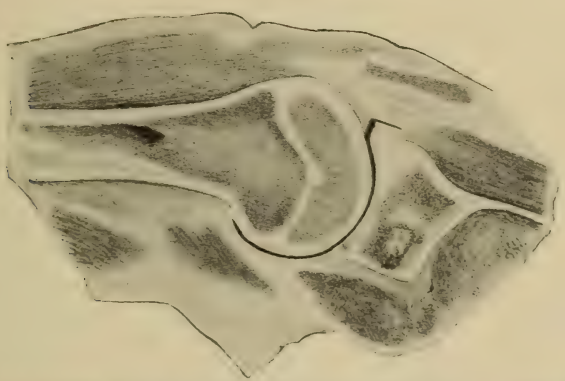

Section of the shoulder-joint at the age of eight years. (Schuchardt.) Ossification appears in the epiphysis of the head of the humerus at the end of the first year; a second point appears in the greater tuberosity during the second year. These unite between the fourth and sixth years. Ossification is complete between the eighteenth and twentieth years.

shoulder-joint was involved in 38 instances (2 per cent.). In 1900 cases of joint disease treated at Billroth's clinic, the shoulder was involved in 14, or less than 1 per cent.

Pathology. The disease usually begins in the head of the humerus. In 32 observations on adults recorded by Mondan and Andry,[1] the primary disease was of the head of the humerus in 23 cases, of the humerus and scapula in 4, of the scapula alone in 1, and in 3 instances it appeared to be primarily synovial.

[1] Revue de Chir., 1892.

In the majority of cases abscess forms and comes to the surface near the insertion of the deltoid muscle. In advanced cases the tissues of the axilla and of the adjoining thorax may be infiltrated and perforated by numerous sinuses. Not infrequently the disease is of the form called caries sicca, in which there is no swelling, but progressive destruction of the head of the humerus by granulation tissue. This form is characterized by extreme muscular atrophy and by practical anchylosis.

Statistics.

AGE AT INCIPIENCY OF DISEASE AT THE SHOULDER-JOINT IN SIXTY-TWO CONSECUTIVE CASES TREATED AT THE HOSPITAL FOR RUPTURED AND CRIPPLED.

1 year or less	1	13 years old	3
2 years old	6	15 "	2
3 "	1	18 "	3
4 "	3	19 "	5
5 "	3	20 "	4
6 "	1	23 "	1
7 "	3	26 "	2
8 "	4	27 "	1
9 "	6	34 "	1
10 "	1	48 "	1
11 "	5	56 "	1
12 "	4		
		Total	62

Males, 38; females, 24; right, 35; left, 27.

Townsend[1] made a detailed report on 21 cases treated at the Hospital for Ruptured and Crippled during the years 1889 to 1893. Ten of these were less than ten years of age; 7 were between ten and twenty, and 4 were more than twenty. The youngest patient was three and a half and the age of the oldest was thirty-five years. In 5 cases the disease was secondary to disease of other parts; in 1 case to Pott's disease; in 2 to hip disease, and in 2 to disease of the knee-joint.

Symptoms. The history of the case will show the persistent and progressive character of the disability, but the symptoms characteristic of tuberculous disease are far less marked at the shoulder than at other joints. This is explained by the fact that the upper extremity is not subjected to weight bearing and because the mobility of the scapula upon the thorax lessens the injury caused by unguarded movements of the arm. This double joint at the shoulder masks the interference with the function of the joint, and the strain caused by overuse may be lessened by the unconscious restraint that the patient can exercise upon

[1] Transactions of the American Orthopedic Association, vol. vii.

motion at this joint. In fact, even when absolute anchylosis is present the patient may think that motion is but moderately restricted.

The symptoms of the disease may be classified as *pain, sensitiveness, restriction of motion, atrophy.*

There is usually a dull ache about the joint, with occasional neuralgic pain referred to the elbow and arm. The discomfort is increased by movements that pass beyond the limits allowed by the mobility of the scapula, especially on attempting to rotate the humerus, as in clothing one's self or brushing the hair. The joint is sensitive to pressure; thus the patient finds that he cannot lie on the affected side at night.

The normal range of motion between adduction and abduction is about 90 degrees, and between flexion and extension somewhat less.

On examination the limitation of motion caused by muscular spasm will be evident when the scapula is fixed, so that movement of the joint can be tested.

Pressure upon the head of the humerus usually causes pain, and in many instances local heat and swelling are present. The atrophy of the shoulder muscles is often extreme and that of the other muscles of the limb is well marked.

As has been stated, abscess is a common accompaniment of the disease, and in such cases the tissues about the joint are swollen and infiltrated. In other instances there is progressive destruction of the head of the humerus without abscess formation (caries sicca). In cases of this type the flattening of the shoulder may be so extreme as to be mistaken for subcoracoid dislocation.

Treatment. The treatment of the disease here as elsewhere is rest. To assure absolute functional rest the wrist should be attached to the neck by a sling, the elbow being flexed to an acute angle; the arm is then fixed to the thorax by a bandage, and all the clothing, including the shirt, is placed outside the affected part. Local rest and compression may be still further assured by strips of adhesive plaster applied over the shoulder and extending to the back and chest; or a shoulder cap of leather or plaster may be employed. This method of fixing the arm is the only one that assures continuous rest, as a change of the clothing necessitates movement of the joint. During the acute phases of the disease the arm may be supported in the attitude of extreme abduction by means of a triangular splint or pad. This position is often that of greatest comfort to the patient. Direct

traction is not often employed, as support of the pendent limb is usually preferred by the patient.

Operative Treatment. If the focus of disease seems to be localized, an exploratory operation for its early removal may be indicated. Excision of the joint in the adult cases, or arthrectomy in younger subjects, may be advisable when suppuration is persistent or when for other reasons it may seem best to attempt to remove the diseased area.

Prognosis. The duration of the disease appears to be from two to five years. The death-rate is higher than in disease of the joints of the lower extremity, because a larger proportion of the patients are adults, and in this class tuberculosis of the lungs is not an infrequent complication.

It is impossible to speak positively of the results of the conservative treatment of disease of the shoulder. The disease is uncommon, and protection is almost never applied in the incipient stage, nor efficiently and persistently employed to the end. The ordinary result is, therefore, anchylosis, usually of the fibrous rather than of the bony variety.

If the disease appears in early life the growth of the limb may be seriously interfered with; an inch or more of shortening from this cause is not uncommon.

Tuberculous Disease of the Elbow-joint.

Tuberculous disease of the elbow-joint is the fourth in order of frequency, preceding the shoulder and the wrist. Of 1883 consecutive cases of joint disease treated at the Hospital for Ruptured and Crippled 56 were of the elbow.

Pathology. The primary disease is in most instances osteal, as in 92.8 per cent. of the cases investigated by Scheimpflug, 44 in number.[1] The original focus of infection is somewhat more often of the ulna than of the humerus. Of the ulna the olecranon process, and of the humerus the external condyle, appear to be the points of election. Disease of the head of the radius is comparatively infrequent. In 119 cases reported by Ollier the olecranon was involved in 73, the humerus in 33, and the radius in 12 instances.[2] And in the cases investigated by Kummer,[3] and Middledorpt,[4] the ulna was more often the seat of the primary disease than was the humerus, but in 81 cases treated in Koenig's

[1] Festschrift für Billroth, 1892.
[2] Karewski. Chir. Krank. des Kindersalters, p. 268.
[3] Deutsche Zeits. f. Chir., Bd. xxvii.
[4] Archiv f. klin. Chir., Bd. xxxiii.

clinic the primary disease was of the humerus in 43, of the olecranon in 36, and of the radius in 2 instances.[1]

Statistics.

AGE AT INCIPIENCY OF DISEASE AT THE ELBOW-JOINT IN FIFTY-NINE CONSECUTIVE CASES TREATED AT THE HOSPITAL FOR RUPTURED AND CRIPPLED.

1 year or less	2	13 years old	3
2 years old	5	14 "	2
3 "	8	15 "	1
4 "	5	17 "	1
5 "	5	19 "	1
6 "	4	21 "	1
7 "	8	23 "	1
8 "	1	25 "	2
9 "	2	29 "	1
10 "	5		—
11 "	1	Total	59

Males, 28; females, 31; right, 27; left, 32.

Symptoms. The symptoms are those of a chronic, persistent, destructive disease. *Pain, local sensitiveness and swelling, stiffness, deformity, atrophy.*

The pain is usually localized at the elbow. It is increased by sudden movements, and as the bones are so superficial there is usually local sensitiveness to pressure, most marked over the seat of the disease. In the early stage the swelling is slight, and it is of the peculiar elastic character due to thickening of the tissue rather than to effusion within the capsule, but as the disease progresses the joint assumes the peculiar spindle shape characteristic of white swelling. The degree of elevation of the local temperature depends upon the activity of the disease. The most important physical sign is the restriction of motion due to the characteristic muscular spasm which becomes evident when the limit of painless motion is passed. The limitation of extension and flexion gradually increases, and finally the limb becomes fixed in an attitude midway between flexion and extension, with the forearm in an attitude between pronation and supination. This is the characteristic deformity of the disease.

Atrophy of the muscles of the arm and forearm is present, corresponding to the intensity and duration of the disease and to the functional disability of the joint.

Treatment. The treatment here as elsewhere consists essentially in placing the joint at rest in the attitude at which anchylosis or limitation of motion will least inconvenience the patient,

[1] Koenig. Lehrbuch Spec. Chir., Berlin, 1900.

and at the elbow-joint this is practically at right angular flexion (Fig. 273).

In the treatment of young children the wrist may be attached closely to the neck by means of a sling, with the elbow at an acute angle (the Thomas method) within the clothing. Or a light plaster bandage may be used to fix the joint, the wrist being supported by a sling. This enables the patient to dress himself without moving the part, and it protects the joint from injury. Other forms of splints may be employed, but the plaster bandage

FIG. 272.

Tuberculous disease of the elbow-joint.

answers every purpose. It should, of course, extend from the axilla to the hand, and in sensitive cases it may include the hand also.

Reduction of Deformity. In many instances the arm is fixed in the semi-extended attitude when the patient is brought for treatment. In this class of cases a simple and effective means of reducing deformity is that suggested by Thomas. When it is impossible to bring the wrist to the neck, one bends the neck

toward the wrist and attaches the two by a bandage that the patient is unable to remove. From this uncomfortable attitude the patient can free himself only by drawing the arm toward the neck and thus reducing the deformity. At the next visit the same procedure is repeated, until finally the elbow is flexed to the required degree. A permanent sling may be constructed of a leather wrist-band and a tube of leather to pass about the neck, through which the bandage may be drawn ; thus the pressure on the wrist and neck may be lessened. In the very resistant cases

FIG. 273.

Tuberculous disease of the elbow-joint ; the stage of recovery.

reduction of deformity under anæsthesia may be required, but this is not often necessary.

Prognosis. If the case is treated at an early stage the prognosis in childhood is good. The duration of treatment may be estimated at two years or more, and retention of a fair range of motion may be expected. Anchylosis in the right-angled position does not, however, seriously inconvenience the patient, provided the cure is absolute. The loss of growth is usually less than when the upper epiphysis of the humerus has been destroyed, the

final disproportion depending, of course, upon the age of the patient and upon the degree of function that is preserved.

Operative Treatment. In some instances it is possible to remove small foci of disease from the humerus, or from the ulna, before the joint is involved. The position of the disease may be indicated by sensitiveness or swelling, and in older subjects a Roentgen picture may demonstrate its position accurately.

Excision of the Elbow. Excision is often advisable in adolescent or adult life, because by this procedure, in most instances, the disease may be cured in a definite time and because a movable joint may be assured.

Oschman has recently investigated the final results of the operation performed on this class at Kocher's[1] clinic at Berne, 1872–1897. In 40 of 45 cases the operation was performed for tuberculous disease. There were no deaths referable to the operation. Of the entire number of cases 15 were dead, but 11 of these survived the operation for from five to twenty years. Eight of the deaths were due to tuberculosis, 2 to other causes, and in 5 the cause of death was unknown. In 96 per cent. of the cases the local disease was cured. In 68 per cent. of the cases the patients were able to use the limb at hard labor, and in the others it was efficient for light work. In 6 cases there was subluxation or luxation ; in 5 the joint was not firm. In 59 per cent. the motions were practically normal. In 11 per cent. the joint was anchylosed.

Tuberculous Disease of the Wrist-joint.

Disease of the wrist-joint is very uncommon in childhood. In a total of 3105 cases of tuberculous disease treated in the out-patient department of the Hospital for Ruptured and Crippled during the past five years, 98 were of the upper extremity, and in but 4 of these was the wrist-joint involved. Of 43 cases in which the joint was resected by Ollier, the youngest patient was thirteen years of age.

Of 990 cases of disease of the joints in childhood, reported by Karewski, the wrist was involved in 31.[2]

Disease of the wrist in older subjects is less infrequent, although at all ages it is rare as compared with disease in other joints. Tuberculous disease of the metacarpus and phalanges (spina ventosa) is, however, far more common.

[1] Archiv f. klin. Chir., 1900, Bd. lx. H. 2.
[2] Chir. Krank. des Kindersalters, Berlin, 1894.

AGE AT INCIPIENCY OF DISEASE AT THE WRIST-JOINT IN EIGHTEEN CONSECUTIVE CASES TREATED AT THE HOSPITAL FOR RUPTURED AND CRIPPLED.

2 years old	1	19 years old	2
6 "	1	20 "	2
9 "	1	25 "	2
12 "	2	26 "	2
14 "	1	27 "	1
16 "	2		—
17 "	1	Total	18

Males, 11; females, 7; right, 12; left, 6.

Symptoms. The symptoms of tuberculous disease of the wrist are, as in other situations, *pain*, *local swelling* and *sensitiveness*, *limitation of motion*, caused by muscular spasm, and *atrophy*. In advanced cases the hand is usually flexed somewhat upon the arm.

FIG. 274.

Tuberculous disease of the wrist and knee-joints, showing the characteristic deformities in neglected cases of a severe type.

Treatment. The treatment of this, as of other joints, is functional rest, with support in the attitude in which anchylosis or limitation of motion will cause the least inconvenience. A light plaster bandage extending from the elbow to the tips of the fingers, applied over a flannel bandage drawn as tight as the comfort of the patient will permit, is a satisfactory support; or a leather splint or other form of appliance may be used. The hand

should be held in an attitude of moderate dorsal flexion, which will permit the flexor muscles to close the fingers easily if the wrist becomes fixed by the disease. If flexion deformity is present it should be corrected by degrees, with each application of the bandage, until the desired attitude is attained (Fig. 275). The flannel bandage exercises a certain amount of compression upon the wrist which seems to be of benefit, and in certain instances this compression and fixation may be still further increased by the application of adhesive plaster. When the disease of the joint is quiescent, or in the stage of recovery, the bandage or splint may be shortened to allow the patient to use the fingers.

Prognosis. The prognosis as regards function in cases treated promptly in childhood should be good. In the adult cases wrist-joint disease seems to be very often complicated by disease of the lungs; thus the prognosis as to life is often bad. In this class of cases early excision is usually recommended, with amputation as a final resort.

Spina Ventosa.

Central disease of the long bones of the foot and hand is the most common form of diaphyseal tuberculosis. While the

FIG. 275.

Treatment of tuberculosis of the wrist-joint by plaster of Paris, showing the proper attitude.

cortical substance is destroyed from within it is often replaced in part by a formation of periosteal bone from without, which in turn may be destroyed by the advancing disease. In the early cases the affected bone is enlarged, spindle-shaped, and is somewhat sensitive to pressure. At this stage repair may take place with but little ultimate change from the normal, but in many instances the bone is perforated and in part destroyed, the

neighboring joint is involved, and the finger becomes stunted and distorted.

FIG. 276.

Tuberculous disease of the carpus.

FIG. 277.

Tuberculous disease of the left wrist-joint. The irregularity and the diminished size of the carpal bones indicate the extent of the destructive process. The patient, the mother of the child (Figs. 10 and 11) with Pott's disease, died within a year, of tuberculosis of the lungs.

In 159 cases tabulated by Karewski,[1] the metacarpal bones were diseased in 65 instances; the phalanges in 57; the metatarsal bones in 29; the phalanges of the toes in 8. In a number

[1] Chir. Krank. des Kindersalters, Berlin, 1894.

of instances several of the bones and larger joints were involved (159 cases in 135 patients).

The disease is more common in the early years of life, 84 of the 135 patients being four years of age or less, 38 of these being less than two.

Spina ventosa of the phalanges may be treated by rest and compression, and both splinting and compression may be exercised by adhesive plaster strapping. If the joint is involved amputation of the finger may be indicated, because of the distortion and loss of growth that may be expected. Tuberculous disease, limited to a single bone of the carpus or metacarpus, may be treated by operative removal of the disease.

Periarthritis of the Shoulder.

Under the title of scapulohumeral periarthritis, Duplay[1] in 1872 described a painful affection of the shoulder induced by traumatism, dependent upon an inflammation of the bursa lying between the deltoid and supraspinatus and infraspinatus muscles and the coracoacromial ligament. But under this title are now included a number of affections that cause similar symptoms in which it would appear that the interior of the joint is not involved.

Symptoms. In a typical case of so-called periarthritis the patient complains of a dull pain about the joint and sensitiveness to pressure just below the acromion process or over the bicipital groove. The pain is increased by motion, particularly by abduction or by rotation of the arm. In mild cases only extensive motion causes pain, but in most instances there is a constant sensation of discomfort which is increased to acute pain by sudden movements or jars. The part becomes sensitive to pressure, so that the patient avoids lying on the shoulder at night. In certain instances the pain may radiate down the arm, and there may be weakness and numbness of the fingers. Gradually the passive movements of the joints are diminished in range, and atrophy of the shoulder muscles appears.

These symptoms usually pass as rheumatism, but there is no fever, no involvement of other joints, no swelling, and, as a rule, no general sensitiveness to pressure, as is usual when the synovial membrane of the joint is affected. In certain instances these symptoms follow injury, or exposure to cold, or they appear

[1] Archiv. générale de Méd., Paris, 1872.

without apparent cause. In one class of cases the symptoms may be due to an inflammation of the subdeltoid bursa, as in the cases originally described by Duplay ; in others to a *tenosynovitis* of the biceps tendon that may extend to the surrounding parts. This is suggested by local sensitiveness at the bicipital groove, and by the creaking sensation at this point when the muscle is in use. Or the symptoms may be due to neuritis affecting the circumflex nerves, as suggested by Amidon.[1] It is probable also that the nerves in the neighborhood of the joint may be secondarily implicated in an inflammation of bursæ, or directly injured by the original traumatism, if such preceded the symptoms. It is also possible that the bursitis may have been a sequel of gonorrhœa or of other infectious disease.

Treatment. During the acute and painful stage the part should be kept at rest. Cautery may be applied and the joint should be inclosed in adhesive plaster strapping, and if the weight of the limb causes discomfort it should be supported. In certain instances tension on the sensitive part may be relaxed by supporting the arm in an attitude of abduction. When the acute symptoms have subsided passive movements, massage, and static electricity are of service. Voluntary exercises should be employed when they no longer aggravate the symptoms. In the cases of long standing in which motion is very much restricted, apparently by adhesions without the joint, passive movements under anæsthesia may be of benefit. In such cases it may be well to support the limb for a time in the abducted attitude to prevent the formation of the adhesions. Afterward passive motion, massage, and exercises may be employed. If these cases are treated carefully in the early stage, recovery is usually rapid, but if neglected the symptoms may persist indefinitely

Chronic Bursitis.

Chronic bursitis at the shoulder-joint is comparatively infrequent. The bursæ most often involved are the coracoid, the subscapular, and the deltoid. Of these the last is the most often affected. Sixteen cases have been reported by Blauvelt,[2] and three others by Ehrhardt.[3] The enlarged bursa forms a fluctuating swelling most evident on the anterior and outer aspect of the shoulder, the symptoms being discomfort, weakness, and limita-

[1] American Medico-Surgical Bulletin, March 21, 1896.
[2] Beiträge zur klin. Chir., Bd. xxii. [3] Archiv f. klin. Chir., 1900, Bd. lx.

tion of motion of the arm. The disease is usually tuberculous in character, and it should be treated by incision or by complete removal of the sac if possible.

Sprain of the Wrist.

This is a very common accident. The most effective treatment is the adhesive plaster strapping applied about the metacarpus, wrist, and lower half of the forearm. If the pain on motion is severe sufficient plaster is applied to splint the part and to limit movement to the point of comfort. If the injury is of a slighter grade the compression and support of a single layer of plaster is usually sufficient. This dressing prevents injury and yet it allows a certain degree of functional use, which is the most effective means of restoring a joint to its normal condition by hastening the absorption of the effused material within and without the joint.

Chronic Sprain. Persistent weakness and stiffness may follow treatment of a sprain by splints, or when for any reason disuse of function has been long continued. In many instances, however, the sprain was in reality a fracture or displacement. All chronic sprains, therefore, should be examined by means of the X-ray in order that the presence or absence of more extensive injury may be determined.

The treatment is similar to that of the acute sprain : protection from injury, and functional use to the extent of which the part is capable. With this, massage, hot air, and electricity or other form of local stimulation may be employed with advantage. The same treatment is indicated when the joint is stiff and painful as the result of rheumatism or other inflammation, provided the stage of recovery has been reached.

Acute Tenosynovitis.

Tenosynovitis is common at the wrist-joint. It is usually induced by strain or overuse of a muscle or muscular group. Movements of the muscles that are involved cause discomfort, and there is usually local sensitiveness and a creaking sensation on palpation over the affected tendon sheath. The adhesive plaster strapping, so applied as to exert compression and to prevent the motion that causes discomfort, is the most effective treatment.

Chronic tenosynovitis, causing progressive enlargement of a tendon sheath with accompanying symptoms of weakness and discomfort, is usually tuberculous in character. In such cases the diseased part should be promptly removed. If the disease is of long standing, extending into the palm of the hand, it may be advisable to simply evacuate the contents, including the rice bodies, through an incision. An astringent solution may be injected, and after its removal the incision may be closed. Pressure is then applied, with the aim of securing partial adhesions of the apposed surfaces.

CHAPTER XIII.

DEFORMITIES OF THE UPPER EXTREMITY.

Congenital Dislocation of the Shoulder.

This may occur in two forms, one in which there is actual misplacement before birth, and the other in which a dislocation is caused by violence at birth. In either case the displacement is almost always backward upon the dorsum of the scapula (subspinous). Thus the arm is abducted and rotated inward, and the head of the displaced bone may be felt in its abnormal position. Cases of congenital displacement in other directions are recorded, but these are so unusual as to be of little practical importance.[1]

True primary displacement of either variety is uncommon. Many of the reported cases were apparently subluxations secondary to the relaxation of the capsule of the joint and to the muscular atrophy caused by anterior poliomyelitis, or more often to the habitual malposition due to obstetrical paralysis (Fig. 278). According to Porter,[2] twenty-nine cases are recorded in literature, in at least half of which the diagnosis is doubtful. It is, of course, apparent that both displacement and paralysis may be coincident and caused by injury at birth.

Treatment. The only treatment of a dislocation is replacement of the displaced bone if it be possible. If the displacement were discovered in infancy it should be possible to reduce it by manipulation, especially if it were of traumatic origin. As a rule, however, the cases are not seen until later childhood, when the accommodative changes are so great as to make reposition difficult.

Phelps, of New York, has reported several cases of congenital dislocation of the shoulder, caused apparently by injury at birth, as most of them were accompanied by paralysis. In the first case (a boy eight years of age) the joint was opened by a posterior incision along the border of the deltoid muscle. The head of

[1] Scudder. American Journal of the Medical Sciences, February, 1898.
[2] Transactions of the American Orthopedic Association, 1900, vol. xiii.

the scapula was found to be atrophied, and the posterior margin of the glenoid cavity broken away. This, together with the contraction of the tissues on the anterior aspect of the joint, made it necessary to cut away a part of the head of the bone in order to replace it. The secondary articulating surface on the scapula was excised and the redundant capsule was removed. The immediate result of the operation was very favorable. Phelps states that he has operated on two similar cases, but a final report of the results has not been presented.[1] In all cases of this character limitation of motion or even anchylosis is to be expected.

It would seem, however, that, as in a posterior displacement the contracted tissues must be those in front of the joint, an anterior rather than a posterior incision would be preferable. In any event prolonged forcible manual stretching of the contracted parts, in the manner described in the treatment of congenital dislocation of the hip with the aim of securing bloodless reposition, should precede the open operation. By this means the writer has reduced the displacement easily in several cases in early childhood. After reduction the limb should be fixed for months in the attitude of extension on the scapula, so that the head of the humerus may be forced forward, and it should be rotated outward in order to overcome the tendency to inward rotation that is almost always present. When the parts have become adapted to one another the support is removed, and manipulation and exercises are then employed, as in the after-treatment of congenital dislocation of the hip. If the bone cannot be retained in proper position, and especially in those cases in which the paralysis is extensive, the joint may be opened by an anterior incision, and the cartilage may be removed from the humerus and scapula, with the aim of obtaining bony anchylosis. (See Arthrodesis.)

Obstetrical Paralysis.

Partial or complete paralysis of the muscles of the arm may be a result of difficult or protracted labor. It may be caused by direct injury of the brachial plexus, but most often it is caused by traction on the body or the head, and by violent twists of the neck during delivery. The muscles most often paralyzed are those supplied principally by the fifth and sixth cervical roots of the plexus, the deltoid, the biceps, and the

[1] Transactions of the American Orthopedic Association, vol. viii.

supinators of the forearm.[1] Thus in most instances the arm hangs in an attitude of slight abduction and exaggerated pronation (Fig. 278). If the attitude is allowed to persist and if the paralysis is permanent, the head of the humerus, rotated backward beneath the atrophied deltoid muscle and held in the abnormal attitude by accommodative changes in the capsule and surrounding parts, simulates very closely in later years the true congenital dislocation of the shoulder (Fig. 279).

FIG. 278.

Obstetrical paralysis. Characteristic attitude.

Whether cases reported as congenital displacement of the shoulder are secondary to paralysis or not, it is evident that all cases of obstetrical paralysis should be carefully examined with regard to a complicating dislocation, and that the secondary deformity induced by paralysis should be prevented.

Treatment. During the first month after birth the shoulder of the paralyzed arm is often somewhat swollen, and motion may cause pain. In such cases rest is indicated. The arm should be placed against the side, and the hand, with the fingers extended, should be supported on the chest beneath the clothing. When the primary sensitiveness has subsided, each of the joints of the extremity should be moved systematically to the limits of the normal range of motion several times in a day. Particular care should be exercised in supinating the forearm and extending the wrist and fingers, if they are involved in the paralysis. The muscles should be massaged, and the arm should be supported by a sling, or otherwise, in proper position. Recovery may be complete, although it is often delayed for many months. As a rule, traces of the injury are evident in

[1] Thomas. Johns Hopkins Hospital Bulletin, November, 1900.

atrophy of certain muscles, particularly of the deltoid, and a certain weakness of the arm persists, even though no paralysis remains.

In many instances recovery is but partial, the arm is weak, certain muscles are paralyzed, and there is much restriction of movement at the shoulder. The growth of the member is retarded, and the attitude simulates that of posterior dislocation, as

FIG. 279.

Obstetrical paralysis in adolescence.

has been stated. Even in such cases massage, exercises and training will often improve the functional ability of the disabled part. If from neglect of treatment subluxation of the humerus is present, it should be reduced by manipulation in the manner described. In certain cases of this character function may be greatly improved, if the operation is supplemented by massage and appropriate training.

Recurrent Dislocation of the Shoulder.

Recurrent dislocation of the shoulder is in most instances a sequel to traumatic dislocation. The cause of the instability is usually laxity of the capsular ligament and weakness of the supporting muscles, the result, it may be, of too early use of the arm after the accident. In rare instances greater derangement of the joint, caused by fracture of one or other of the articulating surfaces, rupture or displacement of ligaments or muscles, or permanent paralysis of the deltoid muscle, may be present.

The displacement, which may be partial or complete, recurs at intervals and is a very serious disability.

Treatment. If the patient is seen immediately after a displacement and if the dislocation has recurred but a few times and at long intervals, it may be inferred that the disability is the result of simple laxity of the capsule and of muscular weakness. In such cases a period of fixation followed by massage and exercise of the atrophied muscles may result in cure. The patient should be carefully questioned as to the particular movements of the arm that are likely to cause the displacement, which is, as a rule, forward beneath the coracoid process. Most often elevation and abduction seem to be the predisposing movements that should be restrained. A simple and often an effective means of treatment is the application of a shoulder cap of canvas that fits closely about the shoulder and upper arm. This is held in place by bands crossing the body and buckled beneath the other arm ; from the lower border of the cap one or more bands pass downward and are attached with the braces to the trousers, so that elevation of the arm is restrained, before the point of instability is reached.

Operative Treatment. If these milder measures are ineffective, an operation to reduce the size of the lax capsule may be performed according to the method employed by Burrell. The arm being slightly abducted, an incision is made from the coracoid process downward and outward along the line of the cephalic vein to a point below the upper border of the tendinous insertion of the pectoralis major. The deltoid and the pectoralis major are separated, exposing in the upper border of the wound the coracobrachialis, and in the lower angle the upper part of the insertion of the pectoralis major muscles. The upper three-fourths of this insertion is divided in order to expose the head and neck of the bone. The humerus is then rotated outward

and a portion of the insertion of the subscapularis muscle, stretched over the head of the humerus, is divided. The capsule is thus laid bare.

In Burrell's second case a portion of the anterior wall of the capsule three-eighths of an inch wide and three-fourths of an inch long was excised, and the wound was closed with sutures. The incised muscles fell into apposition when the arm was fixed to the side. Burrell has operated on two patients by this method with perfect success.

Similar operations in which the lax capsule was overlapped and sutured without opening it have been performed, by Ricard in 1892 and by Steinthal in 1895.[1]

Congenital Deformities of the Elbow.

Congenital displacement of the ulna is one of the rarest of deformities. The displacement is usually incomplete, and it is associated with laxity of the ligaments.

Congenital displacement of the radius is much more common. Thirty cases collected from the literature have been reported by Bonnenburg.[2] The symptoms are similar to those of traumatic dislocation. The deformity is often overlooked in childhood, and as it causes no great disability, treatment is not usually desired. In several instances the head of the radius has been removed with a favorable effect in increasing the range of supination.

Cubitus Valgus, Cubitus Varus.

Cubitus valgus, in which the forearm is abducted at the elbow, and cubitus varus, in which it is inclined in the other direction, are occasionally seen as congenital deformities. They are, in most instances, associated with laxity of the ligaments.

Similar deformities are not uncommon during the progressive stage of rhachitis, but they usually disappear when the erect attitude is assumed and when the arms are relieved of the strain of supporting the body in the sitting posture.

The forearm forms an angle with the upper arm, opening outward when the limb is extended at about 173 degrees in males and 167 degrees in females.[3] This is sometimes called the "carrying" angle, because the hand is held at some distance

[1] Burrell and Lovett. American Journal of the Medical Sciences, August, 1897.
[2] Zeits. f. Orth. Chir., Bd. ii.
[3] Potter. Journal of Anatomy and Physiology, vol. xxix, p. 498.

from the body while the arm is in contact with the trunk. What may be called normal cubitus valgus is common among women, and in certain instances it may be exaggerated to deformity. Acquired cubitus varus is usually the result of direct injury. Both deformities may be treated by osteotomy of the humerus just above the articulation after the method used to correct similar deformity at the knee.

Subluxation of the Wrist.

A peculiar displacement of the hand forward and usually toward the radial side, described by Madelung[1] as "spontaneous subluxation," is sometimes seen in young subjects whose occupation may require constant use of the flexors of the hand and fingers. In these cases the lower extremity of the ulnar is displaced toward

FIG. 280.



Spontaneous subluxation of the wrist.

the dorsum of the hand; there is abnormal separation of the two bones of the forearm from one another at the wrist, and in many instances the lower extremity of the radius is bent forward. As a consequence the wrist is enlarged, the ligaments are relaxed, and dorsal flexion of the hand is restricted. The symptoms, aside from the deformity, are weakness and sensations of discomfort about the dorsum of the wrist.

Etiology. The predisposing causes of the affection are, apparently, relaxation of the ligaments, and, possibly, slight pre-existing rhachitic deformity of the same character. The exciting causes are occupation or injury. The slight forward bending of the lower extremity of the radius is due, apparently, to irregularity in growth at the epiphyseal junction.

[1] Archiv f. klin. Chir., Bd. xxiii.

Treatment. The treatment is rest, massage, forcible manipulation in the direction of extension, and a support of leather or other material to hold the hand in the extended position. In more extreme cases the deformity of the radius may be overcome by osteotomy.

Congenital Deformities at the Wrist.

Simple congenital dislocation of the wrist is extremely rare. Displacement of the wrist and hand is usually associated with defective development of the bones of the arm, and the deformity is usually classed as club-hand.

Club-hand.

Congenital distortions of the hand may be divided into four primary varieties, according to the direction in which the hand is turned, viz.:

1. Forward or palmar.
2. Backward or dorsal.
3. Lateral to the radial side—radial.
4. Lateral to the ulnar side—ulnar.

Lateral and anteroposterior distortions occur also in combination.

Etiology. There are two distinct varieties of club-hand:

1. In which there is simple distortion caused apparently by abnormal restraint and pressure *in utero*. In certain cases of this class there may be limited motion at both the shoulder-joint and elbow-joint and defective muscular development apparently dependent upon long-continued fixation.

2. In which the deformity is associated with defective development of the radius or ulna and often with congenital abnormalities of other parts.

In the palmar and dorsal distortions the bones of the arm are usually normal. The lateral deviations of the hand are often complicated by defective formation of the radius or ulna, and thus they correspond to talipes due to absence of the tibia or fibula.

According to Hoffa,[1] 39 cases of the former and but 6 of the latter are recorded; in but 1 case was there entire absence of the ulna. Of the 39 cases of radial club-hand 19 were of both sides.

[1] Lehrb. der Orth. Chir., p. 481.

These statistics, however, by no means represent the relative frequency of the deformity. From the writer's observation it would appear that radial club-hand is nearly as common as the deformity of the foot caused by absence of the fibula, of which, according to Potel, there are 200 recorded cases. The ulnar form of club-hand is less frequent even than the deformity due to defective formation of the tibia.

The most important form of club-hand is, then, that due to absence or to defective formation of the radius. As in talipes valgus due to absence of the fibula, the tibia is short and often

FIG. 281.

Club-hands and club-feet.

bent sharply forward, so in this form of club-hand the ulna is usually short and bent inward. The hand may be perfect in formation, but, as a rule, the thumb is absent or rudimentary, and other adjoining bones, together with the corresponding ligaments and muscles, may be absent also (Fig. 282).

The hand occupies practically a right-angled relation to the ulna, and as this bone is usually bent inward as well the direction of the hand is often reversed and is parallel to the forearm. As a rule, the hand is also somewhat bent forward, so that the deformity might be described as radiopalmar (Fig. 283).

Treatment. In those forms of club-hand in which the structure is normal the deformity may be overcome, as a rule, by manipulation, and support by the plaster bandage or otherwise, as described in the treatment of talipes. Massage and muscle training are required in the after-treatment. If the deformity is complicated by defective muscular development and limited joint motion massage and passive manipulation may be required for years. Complete recovery is unusual.

In slighter cases of radial club-hand, due to defective development, it may be possible by manipulation and tenotomy to replace

FIG. 282.

Congenital absence of radius and the bones of the thumb. (Weigel.)

the hand in its normal position, but this is unusual. As a rule, an operation on the ulna will be necessary, together with division of the contracted tissues. Sayre[1] removed a portion of the carpus and implanted the head of the ulna at the point of resection. McCurdy[2] sawed through the ulna, leaving the extremity in relation to the carpus and sutured the proximal fragment and the semilunar bone to one another. Thomson[3] replaced the hand by subcutaneous tenotomy and by the removal of a cuneiform section of bone from the lower end of the ulna.

[1] Transactions of the American Orthopedic Association, vol. vi.
[2] Ibid., vol. viii. [3] Ibid., vol. ix.

The operation of splitting the ulna into an ulnar and radial portion and implanting the carpus between the two has been performed by Bardenhauer.[1] The immediate effect of the various operative procedures was favorable, but no final results have been reported.

Fig. 283.

Congenital club-hands, showing the short and deformed forearms, also bow-legs. (Gibney.)

In any event some form of apparatus must be used during childhood at least, to support the hand, whether the operation has been successful or not; and at best the arm will be short and the thumbless hand weak as compared with its fellow.

Congenital Contraction of the Fingers.

The most common form of congenital contraction is that of the little finger (hammer finger) of one or both hands. This is semiflexed and extension is checked by what appears to be a congenital shortening of all the soft parts on the flexor side. In other instances several fingers may be similarly affected.

Treatment. If treatment by manipulation and splinting is begun early the deformity may be overcome by lengthening the contracted tissues. In later life the prospect of perfect cure by any method of treatment is slight, because of the strong tendency to recontraction after the finger has been straightened.

Webbed Fingers.

In the most common form of this deformity two or more fingers are joined by skin and fibrous tissue to the first phalangeal joints, but sometimes throughout the entire length of the fingers.

[1] Verhand. der deutsch. Gesells. f. Chir., 23 Kong., 1894.

In other instances the web may be thicker, containing muscular fibres from the apposed parts, and, occasionally, the bones of the two fingers may be joined to one another, even to the finger-nails.

Etiology. The cause of the deformity is arrest of development before the fingers have been separated from one another; thus the thumb, which is differentiated from the other parts of the hand as early as the seventy-fifth day of intra-uterine life, is rarely involved, as compared with the fingers, which are separated from one another at a later period.

Treatment. In all but the extreme grades of deformity the fingers may be separated from one another; operative treatment being conducted according to the rules of plastic surgery.

Congenital Displacements of the Phalanges and Distortions of the Fingers.

These deformities are not particularly uncommon. They should be treated by manipulation and by splinting at as early a period as is practicable. Other congenital deformities and malformations of the hand do not call for extended comment.

Trigger Finger.

Synonyms. Jerking finger, snapping finger.

This affection was first described by Nélaton under the title "Doigt à Ressort." On extending the closed hand one finger remains flexed. If the flexion is overcome by greater muscular effort or by passive force the finger flies back to complete extension with a sudden snap or jerk; hence the name. In well-marked cases the same difficulty and the subsequent snap is experienced in flexing the finger. The middle and ring fingers are more often affected, but sometimes the thumb or the fifth finger may be involved.

The patient usually complains somewhat of stiffness and pain in the finger, but the interference with its function is the principal symptom.

Etiology. The usual explanation of the disability is interference with the motion of the tendon in its fibrous sheath, either because of a reduction of its calibre due to injury or inflammation, or to an enlargement or irregularity of the tendon itself. In most instances the obstruction appears to be in the neighborhood of the metatarsophalangeal joint.

The duration of the affection is indefinite.

Treatment. If the obstruction appears to be of inflammatory or traumatic origin it may be treated by splinting and later by massage. In confirmed cases the tendon and the sheath may be explored in the hope of finding and removing the obstruction.[1]

Mallet Finger.

Synonym. Drop-finger.

This is caused usually by a blow upon the terminal phalanx, which ruptures or weakens the attachment of the extensor tendon at the base of the phalanx so that it is habitually flexed sometimes nearly to a right angle.

The treatment must be by incision and reattachment of the tendon to the periosteum.

"Baseball finger" is the reverse displacement of the terminal phalanx which is dislocated backward, forming a bayonet-like deformity. There is often, in addition, injury of the base of the phalanx that causes subsequent irregular hypertrophy.

If reposition is impossible open incision may be employed to correct the deformity.

Dupuytren's Contraction.

Dupuytren's contraction is a deformity of the hand caused by contraction of a part of the palmar fascia and of its prolongations to one or more of the fingers. The fingers are flexed as a consequence to a greater or less degree, and in advanced cases they may be drawn to close contact with the palm. The ring finger is most often primarily affected, but, as a rule, two or more fingers are somewhat involved in the contraction.

In a large proportion of the cases both hands are affected, but not as a rule simultaneously, the contraction beginning in the second hand several years after the deformity in the first.

Pathology. The characteristics of the deformity are explained by the anatomy of the palmar fascia. This consists of a strong central portion, and two thinner lateral parts that cover the muscles of the thumb and little finger. It is made up of longitudinal fibres continuous with the tendon of the palmaris longus, and the annular ligament. It divides into four processes that are attached to the digital sheaths, to the integument at the clefts of the fingers, and to the superficial transverse ligament. Pro-

[1] The bibliography is large. More recent articles are those of Jamin, Cent. f. Chir., June 6, 1896, who reports thirty-one cases, and A. Necker, Beiträge zur klin. Chir., B. x. p. 469.

longations of the fascia pass along the lateral aspect of the fingers and are attached to the periosteum and to the tendon sheaths of the first and second phalanges.

The cause of the contraction appears to be a chronic plastic inflammation of a part of the fascia, which becomes hypertrophied and finally contracts, drawing the finger toward the palm in the manner described.

Etiology. The etiology is uncertain.

The contraction is much more common in men than in women, and it is practically confined to middle and later life. It is claimed that the deformity is more common among those who are subject to gout or rheumatism. It appears, also, to be an hereditary affection in certain instances. Injury or irritation of the palmar tissues, incident to certain occupations, would seem to explain the disproportionate liability of the sexes to the affection.

Symptoms. The first symptom is usually the deformity; the patient finds it impossible to completely extend one or more of the fingers; the tissues about the base of the finger seem stiff, and when it is forcibly extended a hard, elevated cord may be felt extending from about the centre of the palm to the second phalanx, most prominent at the metacarpophalangeal articulation.

To this the skin is adherent, and as the contraction increases it is thrown into elevated ridges. Later other bands appear if the contraction affects, as it usually does, other portions of the fascia. In many instances no pain is experienced unless the contracted fascia is forcibly stretched or is pressed upon. In other cases complaint is made of neuralgic pain in the hand and even in the arm and back. Occasionally the first symptom to attract attention may be a sensitive nodule in the skin at the base of the finger.

The contraction usually increases slowly until the finger that is most affected is drawn to the palm.

Treatment. The deformity may be overcome in part by multiple division of the contracted bands from the finger to the palm, but complete removal of the contracted fascia is preferable if it be possible. The finger is then supported in an attitude of slight flexion until the circulation is adjusted to the new position.

CHAPTER XIV.

CONGENITAL AND ACQUIRED AFFECTIONS LEADING TO GENERAL DISTORTIONS.

Rhachitis.

Synonym. Rickets.

Rhachitis is a constitutional disease of infancy caused by defective nutrition, of which the most marked effect is distortion of the bones.

Etiology. The predisposing cause is constitutional weakness. This may be inherited or it may be the direct effect of illness, but most often it is the result of improper hygienic surroundings, particularly lack of sunlight, damp rooms, overcrowding, and defective ventilation. The direct cause of the disease is improper nourishment. In most instances this is due to the substitution of artificial food for the mother's milk, in others to improper diet after the infant is weaned; in rare cases it may be the result of prolonged lactation, or it may be caused by the defective quality of the mother's milk. The disease, therefore, begins usually between the ages of six and eighteen months, although it is by no means confined to these limits. In most instances improper surroundings and improper nourishment are combined in the causation of the disease; thus rhachitis is relatively common in large cities. At the Hospital for Ruptured and Crippled the most extreme cases are observed among the Italian and the colored children. The former are usually nursed, but are improperly fed after weaning, while the latter, if nursed at all, are usually allowed a mixed diet even during the early months of life.

Pathology. The manifestations of a disease dependent upon impaired nutrition are, of course, general in character. In rhachitis there is a mild degree of anæmia, and a general weakness and relaxation of the voluntary and involuntary muscles. As a result the circulation is impaired and the power of assimilation is diminished; thus congestion and enlargement of the internal organs, intestinal catarrh, bronchitis, and the like are common accompaniments of the disease. The most marked and characteristic changes are found in the bones; these consist in

a diminution of the earthy substances and in overgrowth of osteoid tissue.

"The essential features of the morbid processes are, first, an exaggeration of the processes immediately preparatory to the development of true bone; secondly, an imperfect conversion of this preparatory tissue into true bone; and, thirdly, a great irregularity of the whole process." (Erichsen.)

On section of rhachitic bone it will be noted that the periosteum is increased in thickness, and is more or less adherent to the underlying softened and spongy tissue. The medullary canal is enlarged, and its contents are abnormally vascular. The epiphyseal cartilage, normally a thin, bluish line, is much increased in thickness. It appears to be swollen and infiltrated, and it has lost its former translucency. Microscopic examination at this point, where growth is most active, shows marked irregularity in size and shape of the columns of cartilage cells; the zone of calcification is lacking or is ill-defined, and masses of cartilage cells are found unchanged in what should be the area of true bone. The same irregularity of line and shape is observed in the medullary spaces of the newly-formed osteoid tissue.

As a direct result of the changes that have been described, the epiphyseal junctions are enlarged and the shafts of the bones are thickened by the formation of osteoid tissue beneath the periosteum. The indirect effects of the disease, and of the weakness that it causes, are deformities, the nature of which will be indicated under the heading of symptoms. The stage of weakness is followed by that of repair, which sometimes goes on with great rapidity; the softened bones become abnormally hard, "eburnated," and premature solidification at the epiphyseal junctions may be one of the remote results of the disease that accounts in part for the dwarfing of the stature, observed as one of the final results of severe rhachitis.

Symptoms. As the disease is the effect of imperfect assimilation its more pronounced symptoms are preceded by those of indigestion, such as flatulence, constipation, and the like. Profuse perspiration, especially about the head, and restlessness at night are common symptoms. Teething is often delayed or is irregular. The infant is slow in its movements, and makes little effort to stand or to walk at the usual time, and if the disease is active the affected parts may be sensitive to pressure.

Deformities. The deformities are in part due to the direct effect of the disease. One of the earliest and most constant evidences

of rhachitis is the enlargement about the epiphyses, an enlargement caused in part by the direct hypertrophy and in part by pressure upon the softened tissues. The enlargements at the junctions of the ribs and the costal cartilages, the *rhachitic rosary*, and at the wrists and ankles, *double joints*, are almost invariably present in well-marked cases. The more general distortions are in part the effect of atmospheric pressure, in part the effect of the force of gravity and habitual postures, and in some instances muscular action or injury may deform the softened bones. These deformities differ greatly according to the time of onset of the disease, and with its duration and severity. The head may be long and oblong in shape, or rectangular, *caput quadratum*, and it sometimes presents prominences in the frontal and parietal regions due to thickening of the bone, and on the posterior aspect depressed and softened areas, *craniotabes*. The fontanelles are abnormally large, and they may remain open long after the usual time of closure.

The thorax is compressed from side to side, the compression being most marked in the middle region, where the ribs have the longest cartilages and the least direct support. As secondary results the back of the thorax is flattened and the sternum is thrust forward, forming the *pigeon breast*. The lower ribs are everted to accommodate the distended abdomen, *potbelly*. In well-marked cases the rhachitic chest presents two distinct grooves, one transverse in the axillary line, *Harrison's groove*, and the other passing upward by the side of the rhachitic rosary. These deformities are in great degree caused by atmospheric pressure, but they are increased if the child assumes the sitting posture habitually. In this attitude the body is inclined forward, the clavicles are distorted, and the spine is bent into a more or less rigid posterior curve, most marked in the lower dorsal and lumbar regions, the *rhachitic kyphosis*. Less often there may be a lateral deviation or *scoliosis*.

The arms may be distorted by the efforts of the child to support the body in the sitting posture, or by active exertion, as in creeping (Fig. 284). Occasionally the deformities may be localized at the elbows, and sufficiently marked to merit the name *cubitus varus* or *valgus*, corresponding to genu valgum or varum ; or the principal distortion may be a dorsal convexity of the lower extremity of the radius.

The bones of the lower extremities are often distorted, primarily by the habitual postures assumed in sitting or creeping, and these

deformities are usually exaggerated when the erect attitude is assumed. In some instances it would appear that the femoral necks are twisted backward somewhat; this distortion may explain in part the limitation of inward rotation that is sometimes observed in rhachitic children. Depression of the femoral neck (coxa vara) may be present also, although this deformity does not, as a rule, attract attention until a much later period of life. The changes in the pelvis are of special interest to the obstetrician. These are essentially an increase in the sacrover-

FIG. 284.

General rhachitic deformities, showing distortions of the arms and legs induced by posture.

tebral prominence, due to the forward and downward displacement of the sacrum, an abnormal expansion of the ilia, caused by pressure of the abdominal contents, and, in some instances, a decrease of the lateral diameter, an effect of the pressure of the femora upon the yielding bone.

In the milder type of rhachitis in older children who walk, the deformities are often confined to the trunk and lower extremities. In such cases, in addition to the changes in the bones, there is usually a prominent abdomen and increased lordosis, combined

with slight habitual flexion of the thighs and lower legs, the *rhachitic attitude*.

If the disease is of sudden onset and is severe and general in its manifestations, it may be accompanied by pain, by sensitiveness of the affected bones, and by such weakness of the lower extremities as may simulate paralysis, *rhachitic pseudoparalysis*. It is probable, however, that the cases in which the pain is extreme, "acute rhachitis," are, in reality, scurvy or scurvy and rhachitis combined, scurvy rickets so-called.

Rhachitis, as described, is the type ordinarily seen in hospital practice, and its manifestations are unmistakable. In its milder form it is not particularly uncommon among the children of the well-to-do, whose hygienic surroundings are good. In such cases the most marked symptom is weakness. The child is often fat and well developed, although, as a rule, pale. The abdomen is somewhat enlarged and slight prominences at the epiphyseal junctions, particularly at the wrists, may be made out. The legs appear small in proportion to the body, and the ligaments are lax, so that if the child stands the feet are flat and assume the attitude of valgus. In this class, in which the child is said to have weak ankles, knock-knee is common.

The most common symptom of rhachitis of the mild type is the failure of the child to attempt to walk at the usual time, about sixteen months. If a child who is not ill and who has not suffered from exhausting disease does not walk at two years of age it is probably rhachitic.

Prognosis. The duration of the progressive stage of rhachitis depends, of course, upon the age of the patient and upon the treatment. In cases that are untreated and in which the predisposing causes continue, the period of repair may be delayed for several years or longer, as shown by the fact that the child makes little effort to stand. But, in most instances, the rhachitic child begins to walk at some time during the third year, and at this time the deformities of the lower extremity, knock-knee, bow-leg, flat-foot, and the like usually develop or become aggravated, while those of the upper extremity may become less noticeable.

The deformities of rhachitis tend to disappear or to become less marked with growth ; the concavities of the distorted shafts are filled by accretions of periosteal bone, which is again absorbed from the interior as the medullary canal straightens itself. The thickened diaphyses and enlarged epiphyses become more symmetrical under the influences of rapid growth and increased func-

tional activity, but traces of severe rhachitis always remain, and many of the more noticeable and permanent distortions of the trunk and of the lower extremities are due to this cause.

The prognosis as to the outgrowth of rhachitic deformities depends upon the duration and the severity of the disease and upon the function of the deformed part. Rhachitic distortions of the arms almost always disappear. The rhachitic chest is rarely seen in the adolescent or adult. The rhachitic kyphosis is corrected or modified when the erect posture is assumed, but rhachitic scoliosis, on the other hand, usually increases with the growth. Distortions of the lower extremities may occasionally entirely disappear, and in most cases they are less marked in the adult than in the child. Stunting of the growth is a constant effect of severe and prolonged rhachitis ; it depends in part upon the arrest of development during the active stage of disease and in part upon the changes in the bones that cause premature consolidation at the epiphyses.

Treatment. The treatment of rhachitis consists essentially in a reversal of the conditions under which it developed. It is, therefore, dietetic, hygienic, and medicinal. Deformity, the effect of the disease, may be prevented by guarding the weakened bones from overstrain, and it may be remedied, if it be present, by manipulation or by mechanical or by operative treatment.

The more detailed treatment of rhachitis may be found in works on Pediatrics. In general, the diet in the cases developing in early infancy should be of milk, especially modified according to the need of the patient. At a later time, corresponding to the normal period of weaning, the diet should be largely animal, to the exclusion of starchy food, cream and fresh butter being especially valuable.

The patient, protected by proper woollen underclothing, should pass as much time as possible in the open air, and should sleep in a well-ventilated room. Daily salt baths are recommended for older children, and regular massage of the extremities and of the abdomen should be employed. Medicinal treatment is of secondary importance. The bowels should be regulated and digestion should be aided by proper remedies. For anæmia, which is usually present, the syrup of the iodide of iron is of value ; cod-liver oil serves both as a food and medicine, when it is readily assimilated. It is unlikely that any drug has a very direct influence on the disease. Phosphorus in doses of $\frac{1}{200}$ to $\frac{1}{100}$ of a grain is often given, and is supposed to lessen the

abnormal congestion of the bones, while the deficiency of lime salts may be supplied possibly by the administration of lime in some form, the syrup of the lactophosphate of lime being a favorite prescription.

The prevention of deformity, other than by the means already enumerated, consists in preventing habitual postures that predispose to deformity, and in daily massage and manipulative correction of incipient distortions. Young infants and those whose bones are especially vulnerable should spend much of the time in the reclining posture. The Bradford frame or similar appliance is especially useful in the treatment of this class of cases. The treatment of the more advanced deformities, by support or by operation, is described elsewhere.

"Late Rickets."

Late rickets is, as the name implies, an affection presenting all the characteristics of the common infantile form. This, in rare instances, appears in later childhood or even in adolescence; in some cases the affection appears to be a continuation or recrudescence of the infantile form; in others no history of a preceding affection can be obtained.[1]

By many writers the term late rickets is improperly used to explain the deformities of adolescence, genu valgum, coxa vara, and the like, although none of the distinctive signs of the affection may be present. Local rickets is less objectionable as applied to the same class of cases.

Chondrodystrophia.

Synonyms. Fœtal rhachitis, achondroplasia.

Cases that present the signs of what appears to be severe general rhachitis at birth are not especially uncommon. The trunk is disproportionately long as compared to the stunted limbs; the head is large, the chest presents a pigeon-like distortion, and the epiphyses appear to be generally enlarged. In some instances the back is curved into a rigid kyphosis, or scoliosis and restricted motion or apparent fixation of many of the joints may be present.

Etiology and Pathology. These cases were formerly supposed to be instances of intra-uterine rhachitis; chondrodystrophia

[1] Drewitt. Transactions of the London Pathological Society, 1881, vol. xxxii. Clutton, St. Thomas' Hospital Reports, 1884, vol. xiv.

is not, however, the result of a disturbance of nutrition; it is due apparently to a congenital defect in the bones themselves or rather of the original cartilage. Rhachitis is characterized by hypertrophy of the epiphyseal cartilages and by delayed ossification. In chondrodystrophia, on the contrary, there is atrophy of the epiphyseal cartilages and abnormal rapidity of ossification. On section of a bone the shaft is seen to be thickened and stunted,

FIG. 285.

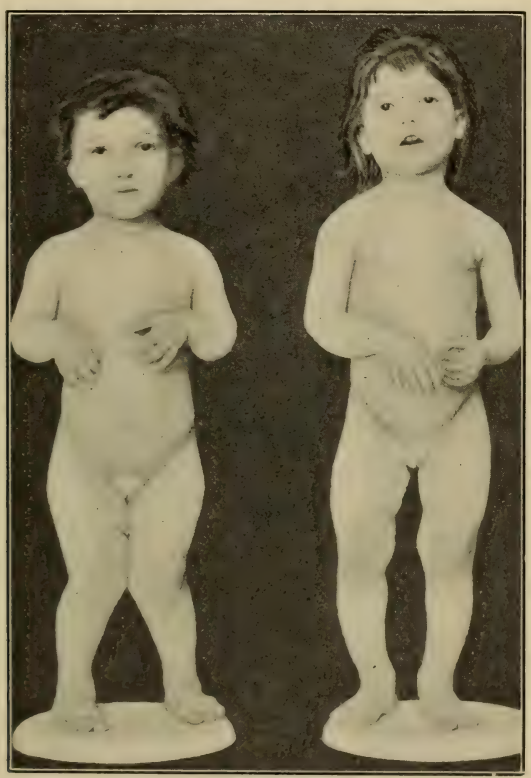

Chondrodystrophia of slight degree, contrasted with ordinary rhachitis, in sisters. 1. Chondrodystrophia. Broad, short, very flexible hands; trunk disproportionately long; knock-knees. Age, five and a half years; height, 30½ inches; normal height, 40 inches. 2. Rhachitis, bow-legs; age, four years; height, 32½ inches; normal height, 36 inches.

the epiphyses are enlarged also, and these hypertrophied and prematurely ossified segments may overhang the diminutive cartilage that intervenes.

Chondrodystrophia, or an affection resembling it, is sometimes seen (Fig. 285) in a very mild form; the appearance of the child

suggests rhachitis, but the stunting of the growth is greater than is ever the result of rhachitis of corresponding severity.

Cretinism. Cretinism may cause a similar dwarfing of the stature, and cretinism may be combined with chondrodystrophia, but in most instances the symptoms of mental deficiency that accompany cretinism are lacking in this affection.

Treatment. The treatment of so-called fœtal rhachitis consists in regular massage and manipulation of the distorted parts and of the anchylosed joints. This treatment may extend over several years, during which the limbs and back must be protected.

Rest on the Bradford frame during the period of active treatment is advisable. If congenital cretinism is suspected the administration of thyroid extract would be indicated.

Prognosis. By persistent treatment the range of motion in the stiffened joints may be regained, but the prognosis as to growth is bad. The patients present in later years the abnormally long trunk and stunted extremities that were present at birth.

Infantile Scorbutus.

Synonyms. Scurvy, scurvy rickets.

Scurvy in infancy, as at other periods of life, is a constitutional disease dependent upon impaired nutrition, caused apparently by the deprivation of proper food. The disease was originally described by Smith and Barlow as scurvy rickets, but it may, and often does, occur independently of the latter affection.

Pathology. The pathological changes most often found in cases of the advanced type are hemorrhages beneath the mucous membranes and the periosteum. Separation of the epiphyses may occur.

Symptoms. The disease is most often observed in bottle-fed infants from six to eighteen months of age. In some instances the patients are evidently ill-nourished, but in others they may appear to be in good condition. The early symptoms resemble rheumatism. The child shows evidences of discomfort when certain joints, usually of the lower extremity, are moved, and as the disease progresses it may scream whenever it is turned or lifted. The painful joints are sensitive to pressure and they may be somewhat enlarged, but local heat and redness, as well as fever, are, as a rule, absent. After dentition the gums may be swollen and spongy, and hemorrhages into the skin or beneath the mucous membranes may occur. In extreme cases the swelling about a

joint due to effusion of blood and accompanied, it may be, by separation of the epiphysis may be mistaken for the symptoms of infectious epiphysitis or even for sarcoma.

Treatment. The treatment consists primarily in the regulation of the diet, particularly in the substitution of fresh milk, properly modified, for the patent food or sterilized milk that may have been employed. This should be supplemented by orange juice, or that of other fresh fruit. The change of diet usually relieves the symptoms. During the painful stage of the disease complete rest in the horizontal position on a pillow or frame may be indicated; later, massage of the limbs and back may be of service in improving the nutrition, and remedying slight deformity.

Fragilitas Ossium.

Synonym. Idiopathic osteopsathyrosis.

Idiopathic fragility or osteopsathyrosis is of congenital origin. The bones appear to be weak simply because of a failure in the formation of periosteal bone. In such cases there may be distortions at birth, apparently caused by intra-uterine fractures, and in after-life fracture may follow the slightest accident or even sudden motion. Blanchard[1] has reported a case in which there were seventy distinct fractures between the ages of two months and twenty-seven years. A similar case was for many years under treatment in the Hospital for Ruptured and Crippled. For a part of the time the trunk and legs were inclosed in a plaster-of-Paris casing to prevent the fractures that followed even ordinary movements. At the age of fourteen the strength of the bones had increased sufficiently to enable the patient to walk about with the support of braces, but he was, in stature, about the size of a child of seven years.

Fractures in this class of cases are attended with but little pain. They unite slowly with but a small callus. It is practically impossible to prevent a certain amount of deformity. With advancing years the liability to fracture may diminish, but, as a rule, the patient is disabled and dwarfed in stature.

The treatment is protective. Massage is of some service in improving local nutrition. Medication is of little avail.[2]

There are many other conditions that cause local or general

[1] Transactions American Orthopedic Association, vol vi.

[2] Porak. Bull. et Mém. de la Soc. Obst. et Gyn. de Paris, 1840. Salvetti, Beitr. zur Path. Anat. und Allg. Path., 1894, Bd. xvi.

fragility of the bones and thus an increased liability to fracture. For example, the weakness of old age, sometimes called senile rickets; the atrophy caused by disuse incidental to chronic joint disease, or the weakness that may be caused by certain diseases of the nervous system. In other instances the weakening may be the direct result of disease, as, for example, osteomalacia or rhachitis. (See Atrophy of Bone, page 241.)

Osteomalacia.

Synonym. Mollitis ossium.

Osteomalacia is a disease of an inflammatory nature, characterized by an absorption of the earthy substances (decalcification) of the bones and by deformity. The disease is one of adult life.

FIG. 286.

Osteomalacia in a child.

It is far more common among females than males, and pregnancy, in about half of the cases that have been reported, seemed to be the exciting cause. The disease usually begins insidiously. The symptoms are pain on motion, referred to the pelvis and to the

thighs. This is supposed to be of rheumatic origin until the character of the affection is made evident by the weakness of the limbs and by the deformities. These deformities are of greater interest to the obstetrician than to the surgeon, for when the affection complicates pregnancy the distortion of the pelvis may be so great as to prevent normal delivery.

Osteomalacia in Childhood. Three cases of osteomalacia in childhood have been reported by Siegert,[1] and one case has come under my observation. The patient, one of twelve living children of healthy parents, was nursed by his mother for the usual period, and until the age of four years he appeared to be perfectly healthy. At this time, without known cause, general weakness became apparent, and at the same time deformities of the lower

FIG. 287.

Osteitis deformans in a female seventy-three years of age. (Lunn.[2])

extremities developed. At the age of six years he was unable to stand. At the present time the condition of the patient, now nine years of age, is shown in Fig. 286. There is no evidence of rhachitis or of paralysis. The patient has never suffered from pain or discomfort. The lower extremities are somewhat atrophied from disuse, the bones are abnormally flexible and are distorted to a moderate degree. The epiphyses are not enlarged (Fig. 282).

Treatment. As the etiology of the affection is unknown, the treatment is therefore experimental or symptomatic and palliative.

Local Osteomalacia. When deformity of a bone appears and increases without apparent cause it is often assumed that a local disease—"local rickets or local osteomalacia"—is present.

[1] Münch. med. Wochenschr., November 1, 1898.
[2] Prince. American Journal of the Medical Sciences, November, 1902.

Local weakness and deformity may be caused by injury or by subacute osteomyelitis and the like. If there is a distinct local disease that deserves the name of local osteomalacia, its cause has not been determined.

Osteitis Deformans.

This disease was first described by Paget[1] in 1877. It is a chronic inflammatory affection of the bones, characterized by hypertrophy and softening. "The bones enlarge, soften, and those bearing weight become unnaturally curved and misshapen."

FIG. 288.

Normal tibia and foot.

FIG. 289.

Osteitis deformans. Hyperostosis and decalcification. (Fitz.) Contrast with Fig. 289.

Section of an affected bone shows it to be markedly increased in size, and somewhat in length, by a combination of rarefying and formative osteitis. The inner layers become porous, and at the same time new bone is deposited beneath the periosteum.

The disease appears to be confined to adult life, and it is apparently more common among males than females. Of 67 cases collected by Packard, Steele, and Kirkbride,[2] 61 per cent. were in males. Occasionally but a single bone is affected. Such

[1] Med. Chir. Trans., 1882, vols. xl. and lxv.
[2] American Journal of the Medical Sciences, November, 1901.

are, in all probability, early cases, for, as a rule, the lesions are symmetrical and general in distribution, the bones of the lower extremity, the skull, and the spine being more often involved. Thus the head progressively increases in size, and the legs become bowed. If the spine is affected it bends forward, forming a long, more or less rigid kyphosis.

Aside from the deformities and the characteristic enlargement of the bones, the symptoms are not marked. At times complaint is made of pain usually supposed to be rheumatic until the characteristic changes in the bones appear. The disease is extremely chronic in its course, and, as a rule, the general health is not seriously affected. In several instances sarcoma of bone finally caused death many years after the onset of the disease. Its etiology is unknown, and its treatment is palliative.

Secondary Hypertrophic Osteo-arthropathy.[1]

Osteo-arthropathy is an inflammatory disease of the bone characterized by hypertrophy, clubbing of the fingers, and effusion into certain of the joints. The hypertrophy is caused by a deposition of layers of bone beneath the periosteum of the metacarpal and metatarsal bones, the phalanges and the distal extremities of the adjoining bones of the arms and legs. Less often the area of the disease is more extensive, involving the femora, the humeri, and the spine even.

Osteo-arthropathy is usually a complication of pre-existing chronic disease, most often of the lungs. The patient first notices clubbing of the terminal phalanges and hypertrophy of the finger-nails, later an increasing enlargement of the wrists and ankles and of the hands and feet, accompanied by discomfort, sensitiveness to pressure, and often by effusion into the neighboring joints, symptoms that would be classed as rheumatic were it not for the evident hypertrophy.

The clubbing of the fingers is due, in part at least, to impairment of the circulation, and the connection of the disease of the bones with that of the lungs has suggested the theory that it is caused by the absorption of toxins, and that its etiology is similar to the amyloid hypertrophy of the internal organs that sometimes follows chronic disease of bones and joints attended by suppuration.

The treatment is symptomatic, and as the affection is almost

[1] Marie. Revue Médicale, Paris, 1890, x. p. 1. Bamburger, Wiener klin. Woch., 1889, No. 11; Deutsche Chir., 1899, L. 28.

always secondary to a graver disease but little is known of its outcome. It is certain, however, that the secondary osteo-arthropathic symptoms become less marked or may even disappear as the patient recovers from the original disease of the lungs or other organs. The affection is very uncommon in childhood. In one characteristic case observed by the writer complete recovery followed the cure of Pott's disease and chronic bronchitis, the hypertrophied phalanges alone remaining.[1]

Acromegalia.

This affection is also characterized by progressive enlargement of the hands and feet, but it differs from osteo-arthropathy in that all the tissues are involved in the hypertrophy. The hypertrophy of the bone is limited to the epiphyseal extremities, and is slight compared with that of the soft parts. The face is often involved, the tissues of the nose, lips, and ears being enlarged and thickened, together with the underlying bones, so that the expression is very markedly changed.

Acromegalia is common among those of gigantic stature, the local hypertrophy and the gigantism both being due, it is supposed, to disease of the pituitary gland.

Diagnosis. The three affections that have been described—osteitis deformans, osteo-arthropathy, and acromegalia—are rare diseases, and they are of little practical interest to the surgeon other than from the standpoint of diagnosis. This might be somewhat difficult if the pathological process were confined to a single bone or limb, as is sometimes the case in osteitis deformans.

The essential characteristics of the three diseases may be summarized as follows: In osteitis deformans the entire bone is increased in size and length, and because of the coincident weakening of its structure it becomes distorted; the skull is usually involved, but the hands and feet are not often affected. It is a disease of middle or later life, and there are, as a rule, no symptoms other than those due to the local changes in the bones.

In osteo-arthropathy the process is an hypertrophy of a slight degree, caused by deposition of periosteal bone, especially about the distal extremities of the shafts of the bones adjoining the hands and feet. It is not often accompanied by the weakness or the deformity that is characteristic of the preceding affection; the skull is not usually involved, but the long bones of the hand

[1] Whitman. Pediatrics, February 15, 1899.

and feet are thickened, so that these members are markedly increased in size. There is often coincident discomfort and swelling of the neighboring joints. As a rule, the local affection of the bones is secondary to chronic disease of the lungs.

In acromegalia the marked changes are hypertrophic enlargements of the hands and feet in which all the tissues are involved ; the hypertrophy of the bones is most marked about the epiphyses, the diaphyses remaining unaffected ; thus it differs from the preceding disease, in which similar enlargement of the extremities occurs. The head is often involved, but the hypertrophy is of all the structures of the face, not of the skull, as in osteitis deformans.

The disease appears to be confined to early adult life, and it is often preceded or accompanied by symptoms of a general nature, headache, mental impairment, and the like.

The changes in the bones characterizing the affections may be easily demonstrated by means of the Roentgen pictures.

CHAPTER XV.

CONGENITAL DISLOCATION OF THE HIP AND COXA VARA.

Congenital Dislocation at the Hip-joint.

Of all the congenital dislocations, or, perhaps, more properly, misplacements, that of the hip-joint is by far the most common and the most important.

Statistics. Congenital dislocation of the hip is much more common in females than in males. In 671 cases collected from

Fig. 290.

Congenital dislocation of the hip, showing the elongated capsule and the right-angled relation of the neck to the shaft of the femur. (William Adams.)

different sources by Lorenz, 589 (87.8 per cent.) were in females and 82 (12.2 per cent.) in males. Of 1039 cases seen at the Polyclinic in Milan, 867 (83.4 per cent.) were in females, 172

(16.6 per cent.) in males.[1] In 500 cases from the records of the Hospital for Ruptured and Crippled, investigated for me by Dr. C. P. Flint, 413 (82.6 per cent.) were in females and 87 (17.4 per cent.) in males.

The dislocation is more often unilateral than bilateral. In Lorenz's series of 671 cases 421 (64.4 per cent.) were single; 225 of the right, 196 of the left side. In 245 cases (36.6 per cent.) the displacement was bilateral.

STATISTICS OF FIVE HUNDRED CASES OF CONGENITAL DISLOCATION OF HIP, RECORDED AT THE HOSPITAL FOR RUPTURED AND CRIPPLED.

		Per cent.
Males	87	17.40
Females	413	82.60
	500	100.00
Right hip	135	27.66
Left hip	218	44.47
Both	136	27.87
	489	100.00
Not specified	11	
	500	
Males.		
Right hip	25	30 48
Left hip	32	39.04
Both	25	30.48
	82	100.00
Not specified	5	
	87	
Females.		
Right hip	110	27.04
Left hip	186	55.69
Both	111	27.27
	407	100.00
Not specified	6	
	413	

The dislocation at the time when the patients are brought for treatment is usually posterior, upon the dorsum of the ilium; in other instances it is anterior, and the head of the bone may be felt beneath the anterior superior spine. It is probable, however, that the primary displacement is often directly upward, for in those cases discovered in infancy this position is common.

Pathology. The pathological anatomy of the dislocation was first clearly demonstrated by Dupuytren in 1826, and since 1890, when the open operation was first performed, the exact relation and the appearances of the different components of the joint have been described in detail by Hoffa, Lorenz, and other operators.

[1] Bernacchi. Zeits. Orth. Chir., vol. ii. p. 275.

The condition of the joint varies with the age of the patient and the strain and friction to which the displaced parts have been subjected. In early infancy it may be assumed that the head of the bone lies in close proximity to what is, in some instances, a practically normal acetabulum; in others to one that is somewhat rudimentary, often shallow and small, sometimes of an oval or of a somewhat triangular shape. The *acetabulum* is covered with normal hyaline cartilage, the ligamentum teres is present, and the capsule is of nearly normal structure. At a later time, when the joint is exposed at operation at the age of five or more years, the capacity of the rudimentary acetabulum may be lessened by a deposit of fat and fibrous tissue. As a rule, however, it appears to be of fair size and depth. The *capsule* is elongated to accommodate the upward displacement of the femur. It is hypertrophied, especially where it covers the upper part of the head of the bone, and it may be drawn into a shape like an hour-glass; the upper part contains the head of the bone; the anterior wall is drawn tightly across the acetabulum, forming at its upper border a narrow slit-like communication, through which the ligamentum teres passes if it be present (Fig. 286). The interior of the capsule is in part lined with synovial membrane, and it often contains more synovial fluid than is found in the normal joint.

FIG. 291.

Congenital dislocation of the hip, showing the original and the acquired acetabula. (Lorenz.)

The *ligamentum teres*, although probably present at birth in a large proportion of the cases, becomes attenuated and ribbon-like with the increasing elongation of the capsule, and after the age of five years, or at the time when the open operation is performed, it is usually absent, and far more often in the bilateral than in unilateral cases. According to Lorenz, in 52 cases between two and a half and five years it was present in 17; in 48 cases beyond the age of five years it was present in but 4. In rare instances it may be

hypertrophied. In my own experience the ligament is present in a very much larger proportion of the cases, although it is often so rudimentary that it might easily be overlooked.

A shallow *secondary acetabulum*, formed in part by the direct pressure of the head of the bone through the adherent capsule, and in part the result of irritation of the periosteum, is usually found upon the ilium (Fig. 292), but it is not often of sufficient depth to assure a secure support for the head of the femur ; thus

FIG. 292.

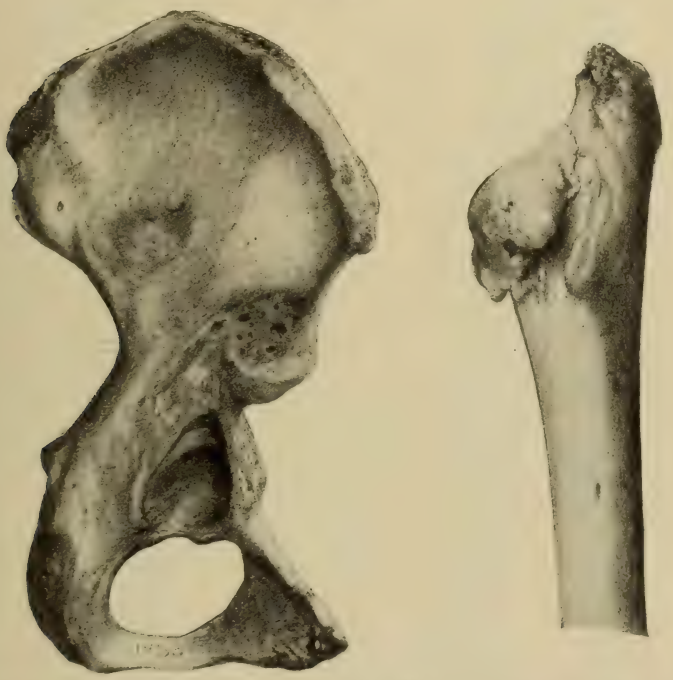

Congenital dislocation of the hip in adult age, showing the abnormal shape of the acetabulum, the depressions in the ilium caused by the pressure and friction of the head of the femur, and the destructive effect of this pressure and friction upon the femur. (Adams.)

its upper margin gradually recedes or two distinct depressions may be formed, one above the other. The upper extremity of the *femur* is usually somewhat atrophied. The neck is often shorter than normal, and its angle may be lessened, and in many instances its forward inclination is increased. The head of the bone may be nearly normal, although usually it is somewhat flattened on its inner and under surface, or it may be somewhat conical, acorn-like in shape, or again compressed from side to side to an almond shape or otherwise distorted. The abnormal-

ities, in part congenital, become more marked with age, and in adult specimens the head and neck of the femur may be so atrophied and worn away that it has little semblance of normal contour (Fig. 292).

There are also secondary changes in the bones of the *pelvis*. In unilateral dislocation the pelvis is usually somewhat atrophied

FIG. 293.

Unilateral dislocation, showing the inclination of the body toward the shorter leg.

FIG. 294.

The same patient before operation, showing the abnormal lordosis and rotation of the pelvis. (See Figs. 320 and 321.)

on the affected side, and a lateral inclination of the spine may be present. The final changes in the pelvis caused by the bilateral dislocation are more important; its inclination is increased, the lumbar lordosis is exaggerated, the sacrum is forced forward and downward so that the anteroposterior diameter is lessened; the tuberosities of the ischia are everted and the transverse diameter of the pelvic outlet is increased.

The long *muscles* of the thigh are shortened, while those attached about the trochanter are changed in direction and are usually lengthened. There is also a slight general muscular atrophy that is particularly marked in the gluteal group.

The changes that have been described are in great degree secondary to the displacement. They are in part congenital, in part accommodative, and in part due to the influences of attrition and injury, to which the abnormal mobility predisposes. Thus, as a rule, they become more marked with increasing age, and in some of the adult specimens but little resemblance to the normal parts remains.

As a rule, congenital dislocation of the hip is not accompanied by defective development or deformity elsewhere, although cases are sometimes seen in which a general laxity of ligaments is present or in which the dislocation may be one of a series of deformities and malformations.

Etiology. Nothing positive is known of the etiology of the dislocation. In a small proportion of the unilateral cases it may be due to violence at birth, but the fact that nearly 85 per cent. of the patients are females makes it evident that the primary cause can be neither injury nor disease.

Hereditary influence can be established in a few instances. The writer has examined three female children in a family of nine, in each of whom there was dislocation of the left hip, the order being the third, eighth, and ninth child. Also twins in another family, one having single and the other double dislocation. And in four instances congenital displacement was present in the mothers of patients.

Of the various theories that have been advanced to account for the condition, the most reasonable seems to be defective development. This defective development may affect the entire acetabulum, or it may involve only its posterior margin, or the cause of the displacement may be an abnormal laxity of the capsule that predisposes to displacement when the thigh is flexed and adducted.

It is evident that the defective development may be the cause of the luxation, or it may be an effect of displacement or malposition which in turn may be due to an abnormal or constrained attitude of the fœtus.

The predisposing attitude is doubtless flexion and adduction of the thigh, and dislocation at this joint is relatively frequent because the acetabulum is shallow in fœtal life. According to

Sainton's observations, in newborn children it covers but one-third of the femur, but at the age of five years it is sufficiently deep to contain one-half of it.

Heusner[1] and Marcwald, from an examination of eighty-five fœtuses, conclude that the greater liability of females to the dislocation is explained by the disproportionate laxity of the capsule as compared with males.

Fig. 295.

Congenital dislocation of both hips, illustrating the separation of the thighs, the abnormal breadth of the pelvic region, and the prominent trochanters.

It is probable that the dislocation, in some cases at least, is at birth a subluxation only, that becomes complete through muscular action and by the use of the limb in standing and walking.

Symptoms. The displacement does not, as a rule, attract attention until the child begins to walk, although in some cases the mother may have noticed a peculiar breadth of pelvis, or a "lump" on the buttock, or a "snapping" about the hip-joint, or a peculiar attitude of the limb before this time.

Unilateral Dislocation. If the displacement is of one side, a *limp* is immediately apparent, which becomes more noticeable as the child grows older. The limp is peculiar, and its character is explained by its cause; for the shortened limb, owing to the elasticity of the capsule, becomes still shorter when the weight falls upon it; thus in walking there is a peculiar lunge of the body toward the short side, that has been likened to the motion in walking down stairs. In the ordinary form the head of the

[1] Zeits. f. Orth. Chir., 1902, Bd. x. H. 4.

femur is displaced upward and backward, and in compensation the pelvis is tilted toward the short limb and its inclination is increased ; it is thus twisted downward and forward so that the anterior superior spine lies at a lower level and in advance of that of the opposite side (Figs. 293 and 294).

FIG. 296.

Bilateral congenital dislocation of the hip, showing the exaggerated lordosis.

At an early age the *shortening* of the limb, due to the elevation of the trochanter, is from one-half to three-quarters of an inch. In later childhood the elevation is from one and one-half to two inches, and in adult life it may be considerably more.

The effect of the displacement is also shown by a flattening of the *buttock*, and usually the elevated and prominent *trochanter*

may be seen as an abnormal lateral projection, on a level with the anterior superior spine, which is, as has been stated, somewhat tilted downward.

In childhood *motion* in the false joint is more free than normal, and the abnormal mobility can be demonstrated by alternate traction and upward pressure on the limb, but as the femur becomes larger and the upward displacement increases, the mobility is restricted. The range of abduction is much diminished, and in extreme cases the limb may become permanently adducted and flexed, thus adding the apparent shortening of adduction to that caused by the dislocation (Fig. 297).

Bilateral Dislocation. When the dislocation is bilateral the shortening of the limbs is, as a rule, equal or nearly so, and if, as

FIG. 297.

Congenital dislocation in an adolescent, illustrating the flexion contraction in a well-marked case.

is usual, both femora are displaced backward, the pelvis is tilted forward; thus in compensation "the hollow" of the back is increased, the abdomen protrudes, the buttocks are flattened, the pelvis appears to be abnormally wide, and the thighs are separated by a considerable interval (Figs. 295 and 296). The limp characteristic of the single displacement is replaced by an exaggerated *waddle*, a "sailor gait."

General Symptoms. In early childhood there are no special symptoms other than the limp or the waddle, but as the child becomes more active it usually complains of *discomfort* after exertion. It is easily fatigued, and at times it may suffer actual pain. These symptoms are, of course, more marked in the double than in the single displacement, because in the latter case the normal limb is capable of bearing more than its share of the strain.

The symptoms often increase during adolescence, but they may become less troublesome in adult life, when the head of the bone may have found a permanent resting place on the pelvis; a security which is often assured by a corresponding limitation of the range of motion. The shortening and the secondary effects of the displacement, of course, persist, so that the individual is, as compared with the normal standard, more or less disabled and deformed.

The great majority of the patients are females, and, because of the less laborious occupations and the distinctive dress, the disability and its effects are less serious than if the displacement were more equally divided between the sexes.

Anterior Dislocation. The symptoms of the unilateral anterior dislocation, in which the head of the bone lies beneath the anterior superior spine, are much less marked than in the ordinary form because the relation of the pelvis to the femur is nearly normal; so that secondary deformity is slight. The shortening is less and the limp is less noticeable because the resistance of the tissues attached to the anterior superior spine is sufficient to assure a relatively secure support.

In bilateral anterior dislocation the entire body is swayed slightly backward, but the lumbar lordosis is not increased; in fact, the back is often peculiarly flat. Otherwise the symptoms do not differ, except in degree, from those of the posterior displacement (Fig. 298).

FIG. 298.

Bilateral anterior congenital dislocation. The lordosis is far less marked than in the ordinary form.

Supracotyloid Displacement. As has been stated, in early cases the displacement may be a form of subluxation in which the head lies but slightly above the normal position. The same upward displacement is occasionally found in older subjects. The physical signs are similar to those of the anterior displacement.

Diagnosis. The diagnosis offers no difficulty. The history of the limp or waddle noticed when the child began to walk and yet unaccompanied by pain or preceded by injury or disease is in itself sufficiently distinctive. If the displacement is of one side,

measurement demonstrates the shortening as compared with the other limb, a shortening that is explained by the prominence and the elevation of the trochanter above Nélaton's line. Traction and upward pressure on the leg will demonstrate the abnormal mobility of the displaced head; and finally, if the thigh be flexed and adducted to its extreme limit, the neck and head of the femur can be easily distinguished moving under the gluteal muscles when the limb is rotated. Thus it may be differentiated from

FIG. 299.

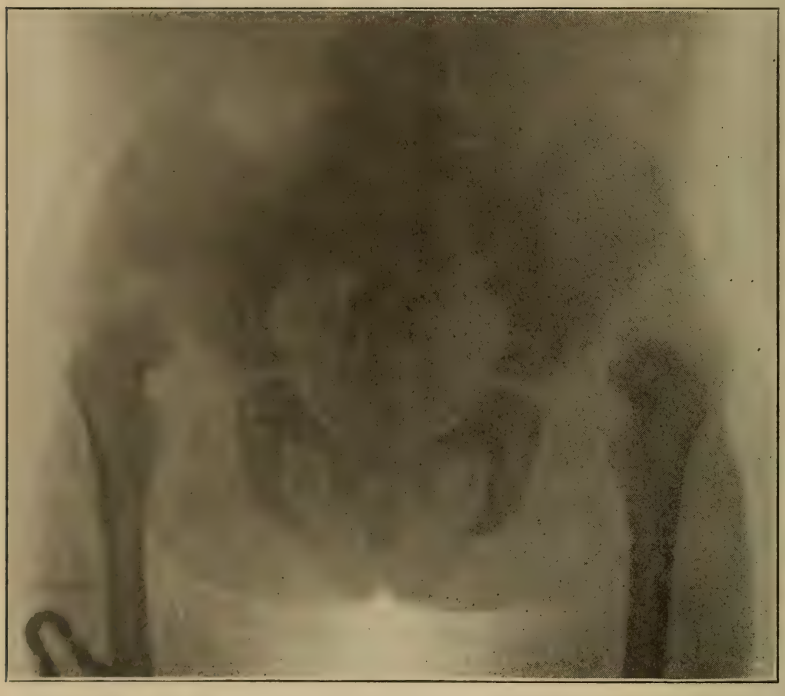

Bilateral congenital dislocation of the hip.

depression of the neck of the femur (*coxa vara*), in which, although the trochanter is elevated, the neck and head of the bone cannot be felt, and in which the abnormal mobility, characteristic of the dislocation, is absent. Again, coxa vara is almost never a congenital affection; therefore, the history itself would practically exclude it.

Upward displacement of the femur not infrequently follows *infectious epiphysitis* or *arthritis* of infancy or early childhood. In such cases a part of the upper extremity of the bone is usually

destroyed, so that the head cannot be distinguished on palpation. Although the other physical signs are similar to those of the congenital displacement, the scars about the joint show the evidence of former disease, and the history is almost always available for diagnosis. Thus, as a rule, such disabilities, as well as traumatic dislocations or other results of injury or disease, are readily excluded.

FIG. 300.

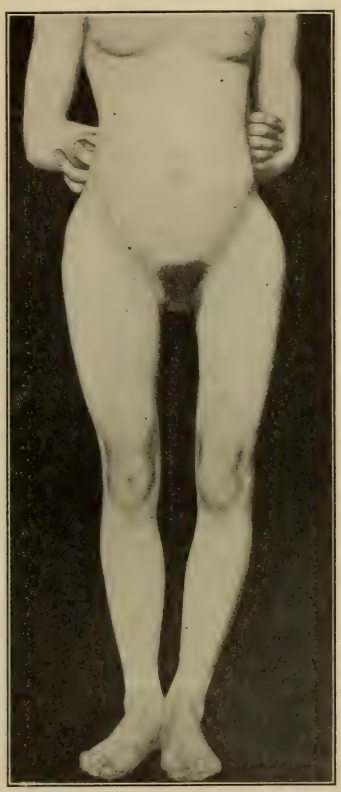

Bilateral dislocation in adolescence. This patient was practically disabled by pain and weakness.

The bilateral dislocation presents, of course, the same physical signs as the single form ; it is even more easily recognized by the peculiar appearance and distinctive gait of the patient.

The waddling gait may be simulated by that of extreme *bow-legs*, but the hip-joints are, in this deformity, normal in appearance and function. The waddling of *lumbar Pott's disease* is also somewhat similar, but this is an acquired painful disease of the spine, in which the hip-joints are normal in appearance and usually so in function.

Pseudohypertrophic paralysis may be mentioned as causing a somewhat similar gait and attitude, but here the resemblance ceases.

As has been stated, the diagnosis of congenital dislocation can be easily made by physical examination ; the only real difficulty is experienced in certain dislocations or subluxations of the anterior type in which a secure secondary acetabular support has formed, and in cases seen in early infancy in which the dislocation may be incomplete, but opportunity for such early diagnosis is rarely offered. In doubtful cases a Roentgen picture will demonstrate the character of the disability (Fig. 299).

Treatment. Dupuytren, in 1829, after a careful study of the anatomy of the deformity, came to the conclusion that it was not

only incurable but that palliation of its effects even was hardly attainable ; and for sixty years the statement was generally accepted, although cures were attained in all probability by Pravaz, of Lyons, 1847, and at a much later time by Paci, of Pisa, 1887.

The term dislocation naturally suggests that cure implies replacement and retention of the displaced bone in its proper place, and in 1890 Hoffa, now of Berlin, first performed this operation with success by opening the joint from behind and enlarging the rudimentary acetabulum to a size sufficient to contain the head of the bone. The details of the operation were afterward modified by Lorenz, of Vienna,[1] and at the present time the original operation has been to a great extent abandoned for bloodless reposition, but to Hoffa belongs the credit for the introduction of the modern treatment of this disability.

The Lorenz Operation of Bloodless Reduction, Retention, and Weight Bearing.

This treatment is based on the experience obtained by the open treatment that an acetabulum of fair size is practically always present. This acetabulum is not of sufficient capacity to retain the head of the femur when the limb is in the normal attitude, but it is sufficiently deep to permit of retention when the limb is fixed in abduction.

It has been proved, also, that by traction and leverage the head of the femur in most instances can be forced into direct contact with the rudimentary acetabulum. Once this contact or reposition is attained, the limb must be fixed to prevent displacement, and as soon as possible the patient must stand and walk in order that the weight of the body and functional use may deepen the rudimentary acetabulum. Meanwhile the distended capsule and other tissues contract about the new joint, and the muscles become accustomed to their new functions. That the acetabulum may be actually enlarged by the presence of the head of the femur is proved by the fact that secondary depressions of sufficient size to form joints of fair stability are often found upon the pelvis in anatomical specimens from older subjects.

The first step in the operation is to overcome the resistance of the tissues, namely, of the capsule and of the long muscles that

[1] Pathologie und Therapie der Angebornen Hoeft Verrenkung, Wien, 1895 ; Ueber heilung der Angebornen Hoeftgelenk Verrenkung, Leipzig u. Wien, 1900.

have become structurally shortened in accommodation to the upward displacement of the head of the femur. The second step is to reduce the dislocation, or, rather, to force the head of the femur over the posterior or upper border of the acetabulum. The third is to increase the security of the articulation by stretching the anterior border of the capsule. The fourth is to fix the parts securely in a plaster bandage.

The Lorenz Operation. The patient is placed upon a table with a thick folded sheet beneath the buttocks. The assistant, standing opposite the operator, fixes the pelvis with his hands (Fig. 301). In some instances better control is assured by pressing

FIG. 301.

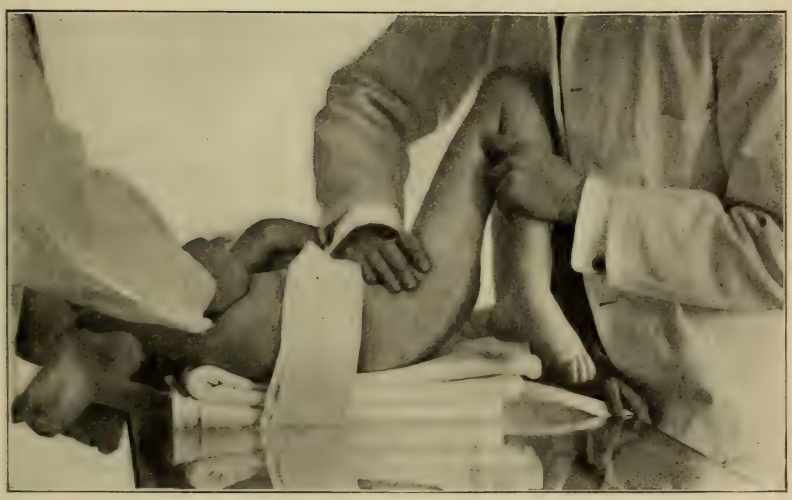

Reduction of dislocation of the right hip. First step. The operator breaks down the resistance offered by the adductors by forcible massage.

the flexed thigh of the sound side downward against the abdomen, as in the Thomas test for flexion in hip disease.

The operator first flexes the thigh to a right angle with the body, then forcibly abducts it, at the same time kneading the tense muscles with the ulnar border of the hand, stretching and rupturing the fibres until the normal prominence has entirely disappeared. The stretching is continued until the limb can be forced down to the plane of the body. One next overcomes the shortening of the tissues on the posterior aspect by flexing the limb, extended at the knee, upon the trunk, gradually forcing it downward until the toes may be placed against the patient's face

FIG. 302.

Forcible flexion of the extended limb on the abdomen. Second step in the operation.

FIG. 303.

Forcible extension of the thigh. Third step in the operation.

(Fig. 302). During this manœuvre the assistant fixes the pelvis by holding the extended thigh of the sound side firmly against the table. The next step is to overcome the resistance of the tissues on the front of the joint. The pelvis is fixed by the assistant. The leg is then flexed upon the thigh, and the thigh is forced downward behind the plane of the body, or the patient may be turned upon the side, as in Fig. 303. After this preliminary stretching traction is made upon the limb, and if with slight effort the trochanter can be drawn down to Nélaton's line reduction is attempted.

Reduction. The pelvis having been fixed as in the first position, the limb is slowly and forcibly abducted over a wedge of wood suitably padded, the apex of which is placed between the trochanter and the pelvis (Fig. 304). As the limb is gradually

FIG. 304.

Reposition. The thigh is forcibly abducted over the padded wedge. Fourth step in the operation. The wedge is of hard wood of the following dimensions: length, 9½ inches; height, 3½ inches; base, 3 inches.

forced downward to and behind the plane of the body, the head of the femur is forced upward until it finally snaps over the posterior border of the acetabulum. Reduction is usually accompanied by a distinct jar, and often by an audible thud. It is also indicated by tension upon the posterior muscles of the thigh which causes fixed flexion of the leg. An effort is now made to increase the capacity of the joint. The patient is turned upon the sound side and the pelvis, having been fixed by the assistant, the operator draws the thigh over and over again behind the plane of the body, and at the same time rotates it from side to side. The security of the reposition is then determined. One tests successively the stability or depth of the superior margin of the acetabulum by reducing the abduction; of the posterior margin by lifting the thigh ventralward, and in a similar manner the inferior border. Upon this examination the prognosis is made; if the

stability allows an approximation to the normal position before displacement occurs the prognosis is good. If, on the other hand, the margins of the acetabulum are so ill-formed that displacement occurs very easily the prognosis is bad.

The operation is varied somewhat in certain instances. If after the stretching, the trochanter still remains above Nélaton's line, one attempts to overcome the remaining resistance by direct traction in the line of the body. Counter-resistance is furnished by a folded sheet passed between the thighs about the perineum, the two ends of which are tied about a corner of the table. Traction on the limb is made by one or two assistants while the

FIG. 305.

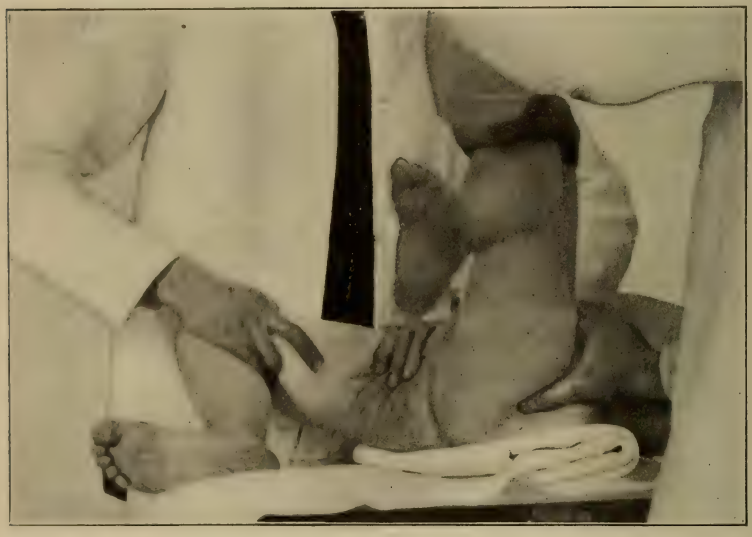

Reposition in young subjects, the thumb being used as the fulcrum to reduce the left hip.

operator supports the pelvis and presses downward and inward upon the trochanter. Occasionally reposition is effected during this manœuvre—that is, the head is drawn over the superior instead of the posterior border of the acetabulum.

Preliminary Traction. In the treatment of older patients or of more resistant cases preliminary traction in bed is advisable. The traction must be considerable, and heavy weights, if possible up to forty pounds or more, should be employed for two or more weeks. This is of great advantage.

Reduction in Young Subjects. In younger subjects the wedge is not necessary, but the thumb of the operator may be used as a

fulcrum beneath the trochanter to lift and push the head upward while the limb is abducted. In this class of cases much less force is required in the preliminary stretching (Fig. 305).

After reposition has been accomplished and when the greatest possible stability is assured by abducting the thigh again and again and forcibly rotating it from side to side to stretch the contracted anterior wall of the capsule and by extending the leg upon the thigh, to thoroughly overcome the resistance of the hamstring muscles the plaster bandage is applied. A close-fitting stockinette shirt, of which one-half has been cut and sewed to cover the limb, as a drawer, is drawn on over the limb, threaded as it were, with a long bandage, the "scratcher." The patient is then placed upon the pelvic rest and the limb is held in the

FIG. 306.



The position in which the limb is held when the plaster bandage is applied.

position of greatest stability at a right angle with the trunk and lying behind the plane of the body. The pelvis and thigh are thoroughly and thickly covered with layers of sheet-wadding or cotton. This is bandaged firmly with cotton flannel, to assure a slight elastic compression (Fig. 306).

The plaster spica is then applied. This should be thick and firm, at least a dozen and oftentimes many more of the ordinary size being used by Lorenz. These bandages are drawn snugly around the pelvis and thigh by a series of reverses and figure-of-eight turns, clasping the iliac crests and thoroughly covering in the buttock. The support is cut away, to allow motion at the knee-joint and the ends of the shirting are then drawn smoothly over the bandage and are sewed to one another (Figs. 307 and 308).

The operation is usually followed by swelling and discoloration in the adductor region and more or less pain, especially when the leg is moved. This soon passes away, usually during the first or second week, and the child is then encouraged to stand. As it is only with extreme difficulty that the foot on the operated side can be brought to the floor, a cork-soled shoe from one and a half to three inches in height is usually worn to facilitate walking.

As has been stated, walking is encouraged on the theory that weight bearing and the stimulation of functional activity will increase the stability of the joint by deepening the acetabulum and accentuating its boundaries. In most instances the range

FIG. 307.

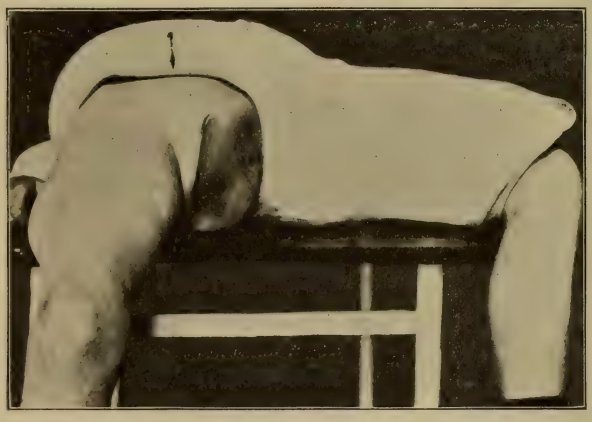

The plaster bandage as applied by Lorenz, illustrating the extreme thickness of the pelvic portion and discoloration of the adductor region.

of extension at the knee is for a time somewhat restricted. This restriction is overcome by passive force and by the voluntary effort of the patient. The first bandage is allowed to remain in place for from six to eight months, the skin being kept in good condition by daily vigorous rubbing with the band beneath the supporting bandage. In very young children the bandage must be changed when it becomes offensive.

In this time (from six to eight months) it may be supposed that the accommodative contraction of the muscles about the joint and of the capsule will lessen the danger of redisplacement. The limb is then let down somewhat so that the patient is able to walk about without the aid of a high shoe. The second

bandage is retained for three months or more, and it is then removed, the period of retention being from eight to fourteen months, according to the stability of the joint at the time of reduction. In the treatment of very young children, when in testing the stability after reduction the femur is not displaced, even when the normal position is approached, the limb may be

FIG. 308.

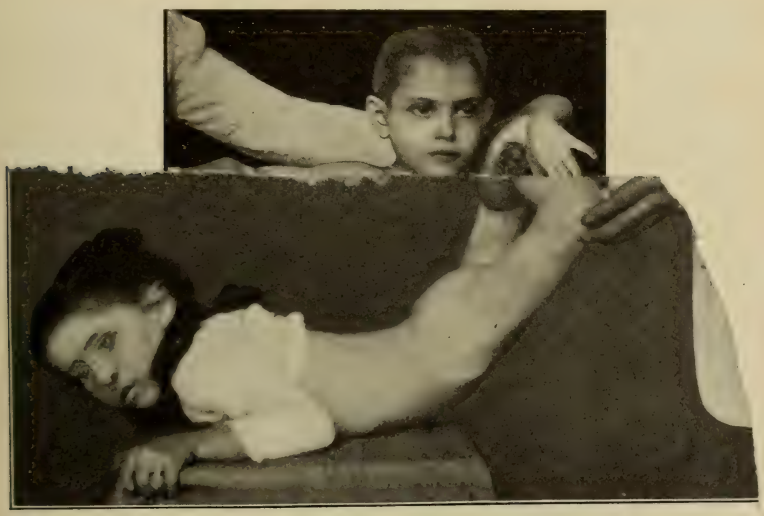

The after-treatment following the removal of the bandage in a case of bilateral dislocation, illustrating hyperextension of the thighs.

In 450 operations reported by Lorenz, the following accid-
-med :



Unilateral congenital dislocation, showing the fixation bandage. A shoe with a cork sole about two inches in height should be worn on the operated side, while the attitude of exaggerated abduction is maintained.

fixed by the plaster in a less distorted attitude—what Lorenz calls the indifferent position of flexion, abduction, and outward rotation.

So, also, when the tests at the operation show fair stability a second bandage need not be applied after a preliminary retention of from six to nine months, but it is better to err on the side of safety in the matter of fixation.

When the retention bandage is finally removed the attitude of moderate abduction and outward rotation persists for a time, in some instances for several months. This being an indication of stability, is considered a favorable sign, and no attempt is made to correct it. In the after-treatment the limb is massaged, particularly the posterior and lateral muscles of the hip, and the child is encouraged to abduct and to extend the thigh. Passive movements are made, also, in the direction of abduction and extension, the ability to reproduce the first or operation position during the early treatment being considered essential. In certain instances the child for a time should sleep in this position, the attitude being assured by a triangular cushion placed between the limbs and strapped to the thigh and pelvis.

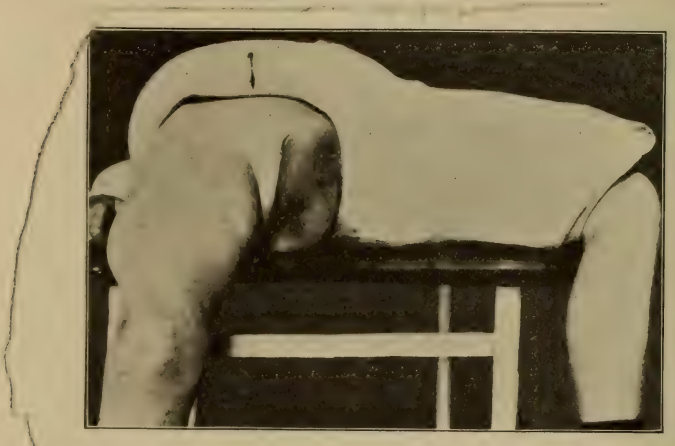

Plaster bandage as applied by Lorenz, illustrating the extreme thickness of the ... and the right angular flexion in bilateral dislocation. Compare with Fig. 311.

Bilateral congenital dislocation is treated in exactly the same way as the unilateral. Both hips are operated upon at one sitting, and are fixed in the typical attitude (Fig. 304). Walking is, of course, difficult, but the child is usually able to stand, and after several months it is often able to get about on its feet after a fashion (Fig. 312).

When the second bandage is applied the limbs are let down somewhat, but the degree depends, of course, on the initial stability. The after-treatment is the same as for the single dislocation, except, of course, that the subsequent period of awkwardness is much longer. Massage and exercises (Fig. 310) are far more important than in single dislocation, as the weakness

is greater. The primary position during sleep may be assured by a cushion or roll placed between the thighs.

Prognosis. The Lorenz operation is not without danger. The death-rate attributed to anæsthesia is disproportionately large in the cases reported, and in this the violence of the manipulations may be an important factor.

FIG. 310.

The after-treatment following the removal of the bandage in a case of bilateral dislocation, illustrating hyperextension of the thighs.

In 450 operations reported by Lorenz, the following accidents occurred :

Fracture of the neck of the femur in	11 cases.
Fracture of the pelvis in	3 "
Peroneal paralysis in	3 "
Crural paralysis in	5 "
Sciatic paralysis in	3 "

In the last cases the paralysis persisted ; in the others it was temporary. In 1 case the femoral artery was ruptured, the patient recovering without ill-effect. In 1 case gangrene of the extremity necessitated amputation at the hip-joint.

It may be stated, however, that in the younger class of cases the operation, if conducted with reasonable regard to the resistance of the tissues and to the susceptibility of the patient, is practically free from danger.

In cases treated at the proper age—that is, under six years for bilateral and under eight for unilateral cases—nearly 50 per cent.

of the unilateral and 25 per cent. (50 per cent. for each side) of the bilateral cases can be anatomically and functionally cured.

FIG. 311.

Illustrating the range of normal abduction of the thighs, from the attitude of right angular flexion.

FIG. 312.

The bandage applied after the reduction of bilateral dislocation, showing a favorite method of progression on a chair.

Nearly all the others can be greatly improved, in that the posterior displacement may be converted into an anterior one. In

such cases, in which the head of the femur is forced forward below the anterior superior spine, the static conditions become approximately normal, and further displacement is to a great extent prevented by the firm tissues attached at this point. A stable articulation is assured by long retention of the limb in the position of abduction and extension by means of the plaster bandage and by exercises and passive movements after its removal.

FIG. 313.

The cure of congenital dislocation. The same patient is shown in Fig. 308.

As has been stated, in successful cases the head of the femur can always be palpated directly beneath the femoral artery. The first indication of failure is a slight lateral displacement of the head to the outer side of the artery. This may appear even during the period of fixation, but often not until the plaster bandage is removed. At first there is no shortening, but slowly, as the displacement increases and as the head of the bone ascends from the neighborhood of the acetabulum to that beside or above the anterior inferior pelvic spine, this becomes evident. At first it is half an inch, later an inch, but it is not often more than this, at least during childhood.

It has been stated that this outcome may be expected in about half of the favorable cases as to age in which all the details of the operation have been properly carried out, and it is the usual result in the unfavorable class. This result, which is not classed by Lorenz as a failure, but rather as an improvement, may be explained in certain instances by interposition of a fold of capsule between the head of the bone and the acetabulum, or by failure of the process of reformation of the acetabulum. In most

cases, however, it is accounted for by an anterior twist of the upper extremity of the femur, so that the neck instead of pointing inward and slightly forward from the shaft is turned forward and slightly inward. Thus, in order to replace the head in the acetabulum, the limb must be rotated inward until the foot points inward rather than forward.

Occasionally the presence of this deformity may be ascertained before operation. It may be suspected, for example, in nearly all the anterior and supracotyloid displacements in older subjects, and it could be demonstrated, doubtless, by a series of Roentgen pictures. In most cases, however, the failure of treatment calls attention to the probable existence of the deformity. It is, of course, apparent that the only remedy is a cutting operation. Lorenz is content in these cases with anterior apposition, but if it is probable that a twist in the upper extremity of the femur is alone responsible for failure, it seems more reasonable to remove this by osteotomy. This operation will be described in connection with the open operation.

The Treatment of Older Subjects. It has been stated that the final result in a very large proportion of the operations was anterior transposition or apposition, as Lorenz calls it, and that in cases beyond the age of eight years this result is to be expected. In this class of cases—from ten to twenty-one years of age—it is the primary aim of the operation. After preliminary traction in bed and after subcutaneous division of the more resistant tendons if this is necessary, the limb is forced into moderate abduction and extreme extension, so that the head of the bone is displaced forward to the neighborhood of the anterior inferior spinous process. In this attitude the limb is retained for many months by means of the plaster bandage, and it is assured in the after-treatment by the manipulation and exercises already described. Although even in the most successful cases a limp persists, yet it is far less noticeable than in untreated cases, the discomfort is relieved, the limb is lengthened, and the danger of future disability is much lessened.

In those unusual cases in which the adduction and flexion deformity is extreme, osteotomy of the femur may be required, and if the pain is persistent excision of the hip may be necessary.

The Treatment of Congenital Dislocation in Infancy. Occasionally one has an opportunity to treat congenital dislocation in early infancy. The details of treatment do not differ essentially from those already described, except, of course, that

reduction is easily effected (Fig. 305) and that walking or weighting (functional use in other words) cannot be utilized at once in the after-treatment. In this class of cases, provided the test of the stability of the joint is satisfactory, one need not fix the limb in the extreme position. It is well, however, to carry the bandage below the knee in order to assure for a time more complete fixation. The support must be renewed whenever sanitary reasons indicate the necessity. In many instances cure is practically assured in a few months.

Variations in the Treatment. It has been stated that the first indication of failure was ordinarily a slight lateral displacement of the head to the outer side of the femoral artery, and that this displacement was favored by the anteversion of the neck of the femur. As is well-known, anteversion of moderate degree is not unusual in the femora of apparently normal joints. In such instances subluxation is prevented by the cotyloid cartilage, and by the normal capsule which are wanting in the congenital dislocation. When, therefore, anteversion is suspected or is known to exist it is well to rotate the thigh inward, so that the head of the femur is slightly to the inner side of the artery, and to fix it in this attitude by extending the plaster bandage below the knee, the leg being slightly flexed upon the thigh. This attitude should be retained until it may be assumed that the capsule is sufficiently contracted to restrain the femur from reluxation. As has been stated, the writer considers the additional security attained by carrying the bandage below the knee of some importance in treatment of infants and young children.

Arthrotomy. If the Lorenz operation has failed when all the details have been thoroughly carried out, the advisability of an exploratory operation suggests itself. Under proper aseptic precautions this should entail no danger, nor should it compromise the functional ability of the joint. One can then assure one's self that the head of the bone is actually replaced within the acetabulum. Arthrotomy is indicated also if the resistance to reposition by the ordinary method is so great that dangerous force must be exerted to overcome it.

The joint is exposed by a lateral incision about three inches in length, extending downward from a point about three-quarters of an inch to the outer side of the anterior superior spine of the ilium, the fascia is divided, and the line of junction between the tensor vaginæ femoris and the gluteus medius muscles is found. These muscles are then separated and are drawn to either side by

retractors, thus exposing the capsule of the joint. This is opened by an incision parallel to the neck of the bone. The finger is then passed through the opening, down upon the rudimentary acetabulum. A strong cervix dilator is next inserted and the contracted capsule is thoroughly stretched. If the ligamentum teres is present it is removed.

FIG. 314.

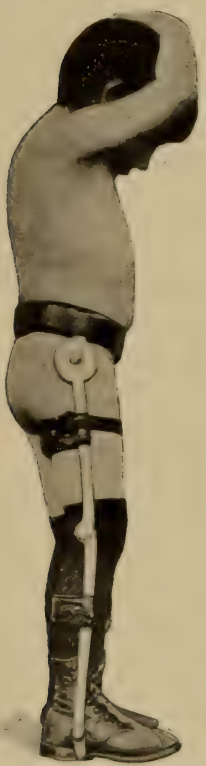

A successful result after the open operation, illustrating a useful form of brace to be used in the after-treatment to hold the limb in proper position, if it has a tendency to rotate outward.

FIG. 315.



Bilateral dislocation six months after replacement by the open method in 1897, illustrating the change in the contour of the trunk.

The head is then replaced ; the capsule and overlying tissues are united with catgut sutures. The limb is then fixed in the typical position by the Lorenz spica. In the majority of cases the cause of the failure of the primary operation is an anteversion of the neck of the femur. In this event after replacement the limb must be rotated inward to the required degree and fixed

by a plaster bandage extending below the knee as a preliminary to osteotomy.

Osteotomy.

When the limb has been fixed for several, preferably six, months, in the attitude of inward rotation so that stability is in some degree assured, the operation for correcting the anterior twist of the upper extremity of the femur should be performed.

The plaster bandage having been removed, a long drill should be inserted through the trochanter and into the neck of the bone. This indicates the position of the neck and fixes the upper frag-

FIG. 316.

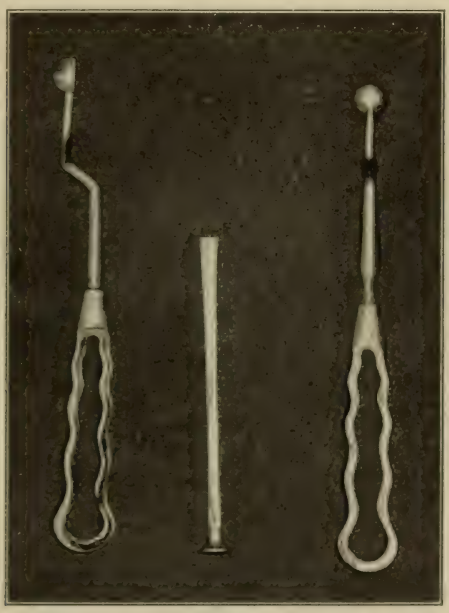

Scoops used in the treatment of congenital dislocation, also the subcutaneous osteotome.

ment. A subcutaneous osteotome is then inserted at a point just below the trochanter minor or at the lower third of the femur, and a thorough division of the bone is made. The lower osteotomy is perhaps to be preferred, because one has better control of the fragments at this point. When the division is complete, the upper fragment being fixed by the drill, the limb is rotated outward until the normal relation between the shaft and the neck is restored. A plaster spica including the foot is then applied, by which the drill and the upper fragment are

fixed in proper relation to the shaft. Two weeks later, when the improved position is assured, this is withdrawn. The after-treatment is the same as in the uncomplicated cases.

FIG. 317.

Unsuccessful treatment by forcible correction (Lorenz operation). The posterior has been changed to an anterior displacement. Rear view.

The Open Operation with Enlargement of the Acetabulum. The original Hoffa-Lorenz operation, once the treatment of routine,

is now reserved for a restricted class of cases in which the bloodless operation has failed, and in which on opening the joint the acetabulum is found to be notably deficient.

Supposing the shortening of the limb to have been overcome by previous treatment, the joint and capsule are opened in the manner already described. One finger is then inserted to the acetabulum and by its side a strong, sharp, bayonet-shaped spoon (Fig. 316) is passed, and with it the shallow acetabulum is enlarged to a sufficient size, care being taken to accentuate its superior and posterior border. The head is then placed within it, and the wound is closed or packed according to the custom of the operator. A long plaster spica is then applied with the limb in an attitude of moderate abduction and extension. In a month, or when repair is complete, a short Lorenz spica is applied and the patient is encouraged to walk about. This support should be worn for from six months to a year in order to prevent the contractions that almost inevitably follow operations of this character. Exercise and forcible manipulation within a few weeks after the operation, as recommended by many writers, are not only of no service, but in the author's experience harmful.

When the spica is removed and the patient is allowed to run about, motion usually returns. At this time massage should be employed and passive movements always in extension and abduction. Later gymnastic training is of great value. After this operation, provided there is true anatomical cure, motion is usually restricted to a greater or less degree, and in older subjects there is often fibrous anchylosis. For this reason it should be limited to unilateral cases, or, at all events, one should never operate on the second hip until the result of the operation in the first is known. In unilateral cases anchylosis without deformity is not a serious functional disability, as there is solid support without shortening, while if fair motion is obtained, as in many instances, the functional result is far better than after simple transposition. It should be stated that even after the open operation this transposition is often the outcome. In such cases motion is, of course, free, and the stability is somewhat greater than after the bloodless operation. If after this operation motion is extremely limited, one must expect flexion and adduction deformity unless it be prevented by careful treatment. In certain instances the range of motion may be increased by breaking up adhesions and stretching the contracted parts under anæsthesia.

The danger of the operation is slight, and the deaths, with but few exceptions, have been due to infection. Lorenz and Hoffa lost several of their earlier patients from this cause, but with improved technique the danger is slight.[1] The bad results of the operation may, as a rule, be accounted for by its improper

FIG. 318.

Unilateral dislocation. Two years after operation in 1897 by the Lorenz method. A complete cure.

FIG. 319.

Unilateral dislocation. Eighteen months after operation by the Lorenz method in 1897. A complete cure.

performance, particularly the failure to replace the femur securely, or by failure to insure asepsis, or by inefficient supervision and after-treatment.

[1] Hoffa has performed the operation 248 times, with 10 deaths, 8 due to the operation, the last 132 operations without a death. Lorenz, in 260 operations, lost 4 patients from septicæmia.—Report of the Thirteenth International Congress, Paris, August, 1900.

It is perhaps unnecessary to state that operations of this character should not be performed unless asepsis can be assured, unless the operator is familiar with the anatomy of the parts, and unless the essential after-treatment can be provided.

Review of the Treatment of Congenital Dislocation of the Hip. The prospect of success in treatment stands in direct relation to the age of the patient, since the extent of the pathological

FIG. 320.

Unilateral dislocation, after operation by the Lorenz method in 1897. A complete cure. Compare with Fig. 296.

FIG. 321.

Unilateral dislocation, two years after operation. Compare with Fig. 294.

changes that make cure difficult or impossible depends in great degree, as in acquired dislocations, upon the duration of the disability. Consequently treatment should be applied as soon as the displacement is discovered, and, as has been stated, there is little excuse for not making the correct diagnosis when the child begins to walk. The treatment of selection is the functional weighting method of Lorenz. By this means a larger proportion

of the cases may be cured, and in all instances the posterior may be changed into an anterior displacement, which is a great improvement.

If one is not content with such partial success the treatment may be supplemented by arthrotomy, and if anteversion of the upper extremity of the femur prevents success it may be remedied by osteotomy.

Excavation of the acetabulum will often assure anatomical success.

Anatomical reposition with fair or even very limited motion assures better function in unilateral cases than transposition, but anchylosis with deformity is certainly no improvement on the original condition. It may be suggested, also, that the danger of open operation even if slight must be considered.

In the treatment of adolescent cases one should attempt to obtain anterior transposition and to assure it by fixing the limb for a sufficient time in the improved position.

As has been stated, the operation of bloodless reduction had been attempted and probably successfully performed long before the time of Lorenz. Its first advocate was Pravaz, of Lyons, in 1847; and Paci, of Pisa, in 1887, described a method of reduction resembling in some respects that of Lorenz, but far less definite and effective, in that primary reduction was not assured nor was the weight of the body utilized in the after-treatment.[1]

Palliative Treatment. Palliative treatment does not require extended comment. In brief in unilateral cases a cork sole may be worn to equalize the length of the limbs, and in bilateral cases a corset suitably strengthened with steel supports may be adjusted if the lordosis is extreme. Exercise and passive manipulation with the aim of retaining, as far as possible, the ability to abduct and to extend the thighs may be of service in preventing secondary contractions. Overexertion that causes discomfort or pain should be avoided.

Congenital Subluxation of the Hip.

As has been stated, there are cases of congenital displacement of the hip which are in reality subluxations. In such cases there is a slight limp and slight shortening, and an X-ray picture shows a secure acetabulum somewhat above the plane of the opposite side. These subluxations are always of the anterior

[1] Archiv. di Ortop., 1892. p. 420.

variety. No treatment other than care to preserve the range of abduction is required as a rule.

Snapping Hip.

Some individuals possess the power of slightly displacing the hip, usually upon the superior or upper border of the acetabulum. This is sometimes seen in infancy, the child's thigh snapping with a jar or even audible sound upward and downward. This is usually accomplished when the child is seated in the mother's lap, the thigh being flexed and adducted, and in this class of cases it is, according to the mothers, an evidence of temper. As the displacement may be increased by habit, it is well to restrain it by applying a bandage about the hip and to prevent flexion of the limb, which is apparently preliminary to its accomplishment. (See Snapping Knee.)

Coxa Vara.

Synonyms. Depression or incurvation of the neck of the femur ; bending of the neck of the femur.

The character of this deformity is indicated by the synonyms. The term coxa vara signifies that its causes and effects are similar to those of genu valgum and varum, the more common distortions of the lower extremities.

Genu valgum and varum are common in childhood, but rarely develop in adolescence. Coxa vara is, in comparison, an infrequent deformity, and it is peculiar in that it more often appears in later childhood or adolescence than at the earlier period, doubtless because the neck of the femur is, at the age when rhachitic distortions are common, very short, and, therefore, relatively stronger than the shaft, while in adolescence the conditions may be reversed.

The distortions at the knee are self-evident, but the neck of the femur is concealed from view ; thus the diagnosis of coxa vara may be somewhat difficult ; and, in fact, it is only in very recent years that its symptoms have been recognized. Fiorani[1] first described the deformity as it had been observed by him in children, but E. Müller[2] first called attention to the affection as one of the deformities of adolescence, which, until that time, had been mistaken for hip disease.

[1] Gazetta degli Ospitale, 1881, Nos. 16, 17.
[2] Beiträge zur klin. Chir., 1889, Bd. iv.

Pathology. The term coxa vara should not be applied to depression of the neck of the femur that may be secondary to destructive disease; for example, to osteomyelitis, arthritis deformans, osteomalacia, and the like, but it should be reserved for cases of simple local deformity. In most instances the deformity affects the neck as a whole (cervical coxa vara); in others it is most marked at the epiphyseal junction (epiphyseal coxa vara). Epiphyseal coxa vara is more often found in the adolescent class, and particularly in those cases in which the symptoms have been induced or aggravated by injury or strain.

FIG. 322.

Section of the upper extremity of a normal femur at eight years of age; angle formed by the neck with the shaft 140 degrees. In the normal subject the neck of the femur projects slightly forward (12 degrees) and upward to form an angle with the shaft of about 125 degrees. In childhood this angle is usually somewhat greater, and in later years it may be somewhat less than 125 degrees; in fact, a variation between 110 and 140 degrees may be within the normal limit.[1]

Whether the injury caused primarily a partial epiphyseal separation which afterward slowly increased under the strain of functional use or suddenly increased a pre-existing distortion of the weakened part is sometimes difficult to decide. A number of specimens of coxa vara have been examined, but no changes, other than such as might be caused by the deformity itself, have been found. These are, in brief, congestion and softening of the bone, and evidences of irritation within the joint during the progressive stage of the deformity, and the general adaptive changes

[1] Humphrey. Journ. Anat. Phys., vol. xxiii. p. 236.

in all the components of the joint that always accompany displacement or distortion. These may be considerable, including, in advanced cases, a change in the acetabulum, whose upper border is less sharply defined than normal.

Etiology. Some writers assume that the weakness of the neck of the femur that predisposes to deformity is the result of local disease, such as so-called local rickets or local osteomalacia. This is, however, simply a convenient hypothesis. Others believe the deformity to be symptomatic of late rickets, although evidence of general rhachitis is almost never present in the ordinary type as it appears in later childhood and adolescence.

Coxa vara may be classed as one of the group of static deformities of the lower extremity caused by a disproportion between the strength of the supporting structure and the burden that is put upon it. The support may be disproportionately weak, because of inherited delicacy of structure; it may be weakened by injury or by disease; it may be overburdened by weight or strain.

Mechanical Predisposition to Deformity. In many cases the predisposition to deformity is the result of a lessened angle of the femoral neck. This slight and predisposing depression, which appears to be, in many instances, the effect of early rhachitis, becomes exaggerated to deformity during later childhood or adolescence. In this sense—that of a remote result—coxa vara might be classed as one of the rhachitic deformities. The importance of this mechanical factor in the etiology was demonstrated to me by the investigation of a number of cases of simple fracture of the neck of the femur in childhood. In these cases the neck of the femur was, by the original injury, somewhat depressed, and although complete functional recovery followed, yet in a number of the cases progressive deformity, attended by the symptoms of typical coxa vara, resulted. This could be explained only on the theory that the lessened angle, subjecting the part to greater strain, was the predisposing cause of the later disability. Other factors in the etiology may be general weakness, incident to rapid growth, direct injury, and the strain of occupation.[1]

In this connection it may be stated that fracture of the neck of the femur in childhood may cause a deformity which in the absence of a history could not be distinguished from the ordinary form of coxa vara, of which, in fact, it is the traumatic form.

[1] One case of congenital coxa vara has been reported by Kredel (Central. für Chir., 1896, No. 42). Depression of the neck of the femur in congenital dislocation of the hip has been mentioned in the section on that affection.

(See Fracture of the Neck of the Femur and Epiphyseal Separation.)

Statistics. The deformity is far more often unilateral than bilateral, and more than three-fourths of the cases are in males. In a total of 109 cases collected from the literature, 83 were in males and 26 in females; 85 were unilateral and 24 were bilateral. The more important details in the 54 cases that have come under my own observation are presented in the accompanying table.

No.	Name.	Date.	Sex	Side affected.	Age.	Duration.	Direction of the distortion forward or backward.	Actual shortening in inches.	Apparent shortening.	History or evidence of former rhachitis.
1	Nelson	Oct. 1896	F.	Right	2½	6 mos.	Posterior	½	½	Yes
2	Van Orden	June, 1896	M.	"	4	1 year	"	¾	¾	No
3	Clayton	April, 1891	F.	Left	6	4 mos.	"	½	½	"
4	Zeltermann	Jan. 1898	M.	Right	7	6 mos.	"	½	½	Yes
5	Vitt	Mar. 1897	"	Left	7	6 "	"	1	1	"
6	Brunjes	Dec. 1901	M.	"	7	5 yrs.	"	1	1¼	Yes
7	Weneck	May, 1902	"	"	7	2 "	"	½	½	"
8	Tuit	July, 1899	F.	"	7½	6 mos.	"	½	¾	"
9	Seeger	Mar. 1897	"	"	8	2 yrs.	"	1	1	No
10	Rose	Jan. 1888	"	D.	8	3 "	"	...	...	"
11	Cohen	June, 1898	M.	Right	8	6 mos.	"	½	½	Yes
12	Kebesky	Aug. 1900	"	Left	8	6 "	Downw'd	½	½	"
13	Dengher	July, 1900	"	Right	8	1 year	"	½	½	"
14	Hirsch	Mar. 1897	"	Both	9	2 yrs.	Anterior	...	...	"
15	Sussman	Aug. 1902	F.	Left	10	1 year	Posterior	¾	¾	"
16	Reardon	Mar. 1898	M.	Both	11	6 "	Anterior	..	...	"
17	Beckmyer	Mar. 1895	"	"	11	8 "	Posterior	...	...	"
18	Brill	Mar. 1894	"	Right	11	1 year	"	1	1	No
19	Greer	Jan. 1896	"	Left	12	8 yrs.	"	1	1	Yes
20	Thomas	Mar. 1898	F.	Both	12	1 year	Anterior	R.¾	¾	"
21	Buechler	Nov. 1902	M	"	12	10 yrs.	Downw'd	...	...	Yes
22	Abrams	Mar. 1898	F.	Right	13	10 yrs.	Posterior	2	2¼	No
23	Rutschmann	July, 1896	M.	"	13	6 mos.	"	½	½	"
24	Fraad	Nov. 1894	"	"	13	1 year	"	¼	¼	"
25	Shandley	Dec. 1898	F.	"	13	1 "	"	½	1½	
26	Skidmore	Nov. 1899	M.	Left	13	3 yrs.	"	½	1½	
27	Cords	May, 1900	"	Right	14	3 mos.	"	½	1½	Yes
28	Cunningham	May, 1897	F.	Left	14	1 year	"	½	1½	No
29	O'Neil	Jan. 1902	"	"	14	1 year	"	¾	1½	No
30	Herbert	April, 1897	M.	Right	14	6 mos.	"	1	1	"
31	Bruning	Oct. 1897	"	"	15	2 "	"	½	1	"
32	Betz	June, 1892	"	"	15	1 year	"	¾	3	"
33	Lawson	Oct. 1897	"	"	15	1 "	"	½	1¼	"
34	Jensen	Jan. 1902	F.	Left	15	2 "	"	½	½	"
35	McHenry	July, 1902	M.	Right	15	8½"	Posterior	½	½	
36	Rose	Jan. 1896	"	Left	15	14 mos.	"	¾	¾	"
37	Allen	April, 1897	"	"	16	1 mo.	"	1	1½	"
38	Puckhaber	June, 1893	"	Both	16	8 mos.	"	...	...	Yes
39	Gieger	May, 1900	"	Left	16	6 "	"	½	1¼	No
40	Schade	July, 1898	"	"	16	18 "	"	1	1	
41	Redfield	May, 1901	"	Both	16	2 yrs.	"	...	...	"
42	Laherty	July, 1901	"	Left	16	7 mos.	"	½	½	"
43	Mortimer	Nov. 1901	F.	"	16	12 yrs.	Downw'd	½	½	
44	McHenry	Jan. 1902	M.	Both	16	2 "	"	...	...	No
45	Morris	Jan. 1900	"	Right	17	6 "	Posterior	¼	¼	No
46	Jocker	Dec. 1899	"	Left	17	1 mo.	"	½	½	"
47	Beck	July, 1898	F.	Right	17	1 year	"	1½	1½	"
48	Zimmermann	Oct. 1896	M.	"	17	13 mos.	"	¾	2¼	"
49	Healey	Dec. 1900	M.	Left	17	8 "	"	¾	1	"
50	Fessner	Mar. 1894	"	"	17	6 "	"	¾	¾	"
51	Enderlich	Jan. 1897	F.	Right	22	1 year	"	¾	1	"
52	Adult	Mar. 1896	M.	"	36	.....	"	1	1½	"
53	Hogan	July, 1901	F.	Right	20	7 yrs.	"	¾	½	"
54	Hayem	Oct. 1901	M.	Both	52	30 "	"	...	...	"

The points of special interest in these and four other cases more recently observed may be summarized as follows: In about one-third of the cases there was a distinct history of rhachitis in infancy. The ages at which the symptoms became noticeable appeared to be as follows:

Adolescents, twelve to seventeen	31
Later childhood, five to eleven	17
Early childhood, less than five	9
Unknown	1
Total	58

Forty-one of the patients were males, 17 were females. In 47 cases the deformity was unilateral, 25 of the right and 22 of the left side; in 11 it was bilateral. In 53 cases the neck of the femur was distorted in a direction backward and downward; in 3 directly downward; in 4 forward and downward. In each case of the last group the deformity was bilateral. Many of the cases were observed before the X-ray was available for diagnosis, but it is estimated that in about one-fourth of the adolescent cases the distortion was greatest in the vicinity of the head of the bone (epiphyseal coxa vara); in the others the neck of the femur as a whole was involved.

Symptoms. 1. **Mechanical Effects.** The character of the symptoms may be explained by a description of the distortion and of its direct effects upon the function of the joint. When the neck of the femur is depressed, for example, to a right angle with the shaft, the trochanter is elevated to a corresponding degree above Nélaton's line, and forms a noticeable projection as contrasted with the normal contour (Fig. 326), a projection that becomes more marked when the thigh is flexed and adducted (Fig. 325). In most instances the neck is displaced backward as well as downward, following the line of least resistance, and as the head of the bone remains in the acetabulum the trochanter is thrown forward and the limb is rotated outward. The ability to abduct the thigh is dependent upon the length and upon the upward inclination of the femoral neck (Fig. 178); when, therefore, this inclination is diminished the range of abduction is lessened, in part by the greater tension that is exerted upon the lower portion of the capsule, in part by the direct contact of the rim of the acetabulum with the neck and trochanter (Fig. 323), and in part by the adaptive contractions that always accompany displacements of this character. It is evident, also, that the distortion of the neck backward and downward changes the relation

of the acetabulum to the head of the femur, so that abduction or flexion tends to displace it from its socket. Thus the range of abduction, of inward rotation, and of flexion is limited, while that of adduction, outward rotation, and extension may be increased.

There is actual shortening of the limb dependent upon the upward displacement of the shaft of the femur. This is not often more than an inch in the ordinary type of adolescent deformity, but the apparent shortening, caused by the adduction and the accommodative upward tilting of the pelvis, may be extreme ; from two to three inches is not uncommon (Fig. 326).

FIG. 323.

Skiagram of coxa vara ; deformity most marked at the epiphyseal junction. This illustrates the mechanical limitation of abduction caused by the deformity, and the compensatory tilting of the pelvis. The patient is shown in Fig. 326.

2. **Physical Effects.** The symptoms of coxa vara of the ordinary form are : *discomfort, awkwardness, limp, shortening, atrophy, limitation of motion, deformity.*

Coxa vara is a more disabling deformity than genu varum or valgum, and its attendant symptoms of discomfort, weakness, and pain are, as a rule, more marked. This is explained by the fact that in coxa vara the head of the bone is in part displaced from the acetabulum (Fig. 324), while in the deformities at the

knee the joint surfaces remain in practically normal relation to one another.

The symptoms of *unilateral coxa vara* vary with the degree and with the duration of the deformity. The patient usually complains of sensations of stiffness and weakness, referred to the thigh. These are more noticeable on changing from a position of rest to one of activity, and at times, particularly after over-exertion, there may be actual pain. By far the most important symptom and the one that almost always induces the patient to seek treatment is the limp. This limp, accompanied, as it usually

FIG. 324.

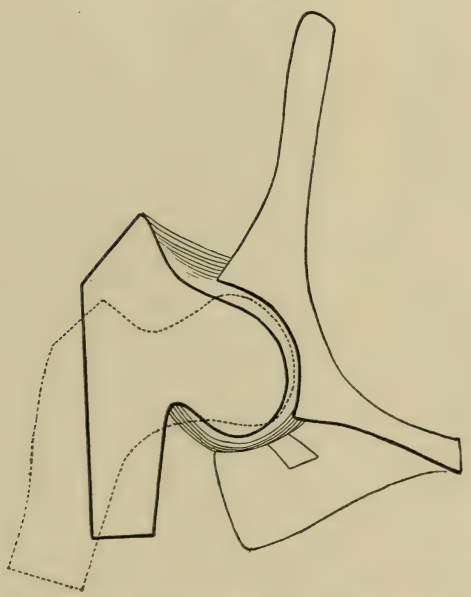

Cross-section of the pelvis and the deformed femur. A scheme to show the effect of the deformity in limiting abduction of the limb. The dotted outline shows the normal relation.

is, by outward rotation of the foot, resembles that caused by united fracture of the neck of the femur. On physical examination the actual shortening, explained by the elevated and prominent trochanter and the peculiar unequal limitation of motion, will make the diagnosis clear. In some instances there may be a slight degree of muscular spasm, and there is usually some atrophy of the muscles of the thigh.

Bilateral Coxa Vara. If the deformity is bilateral its effect upon the gait and attitude is more marked. The gait is extremely awkward, resembling somewhat that of knock-knees,

for the limitation of abduction forces the patient to sway the body from side to side in order that the legs may pass one another, and if the deformity is extreme the limbs may be crossed over one another, so that locomotion may be difficult. In the ordinary form of bilateral coxa vara the femoral neck on each side is displaced backward as well as downward, and as the head of the femur remains in the acetabulum the shaft is thrown forward, so that the trochanter is nearer the anterior superior spine than is normal. This displacement of the support lessens the inclination of the pelvis and lessens the normal lumbar lordosis. Bilateral coxa vara is not infrequently accompanied by other deformities, as, for example, knock-knee or flat-foot (Fig. 327).

Other Varieties of Coxa Vara. In rare instances the neck of the femur may be depressed directly downward or even downward and forward. In the latter instance the effect of the deformity upon the function of the joint is somewhat different from that of the ordinary type. Abduction is limited as in the common form, but inward rotation replaces outward rotation, and extension is limited in place of flexion. This type of deformity is almost always bilateral. It is accompanied, usually, by slight permanent flexion of the thighs; thus the lumbar lordosis is exaggerated; whereas, in the ordinary form it is usually lessened.

This description applies to the ordinary types of the deformity as it is seen in later childhood and in adolescence. It undoubtedly occurs in early life, but it is masked by the more noticeable distortions of other parts, and as an isolated deformity that demands treatment it is uncommon. One case was observed by the writer in a rhachitic child two and one-half years of age. The symptoms, though slight, were typical, and the diagnosis was confirmed by a Roentgen picture. In other cases seen in later childhood, the history of more or less discomfort for many years seemed to indicate that the deformity was caused directly by rhachitis.

In the majority of cases the symptoms begin insidiously, although, in many instances, they may follow injury or overexertion. (See Partial Epiphyseal Separation.) If the affection begins in adolescence and is untreated, the period of discomfort, during which the depression of the neck may be assumed to be progressive, is from two to four years; but if the deformity appears at an early age, the symptoms, though remittent in char-

acter, may continue indefinitely. When the resistance of the compressed bone becomes sufficient to insure stability, the discomfort ceases and the disability becomes less marked, as nature accommodates the mechanism to the new conditions.

FIG. 325.

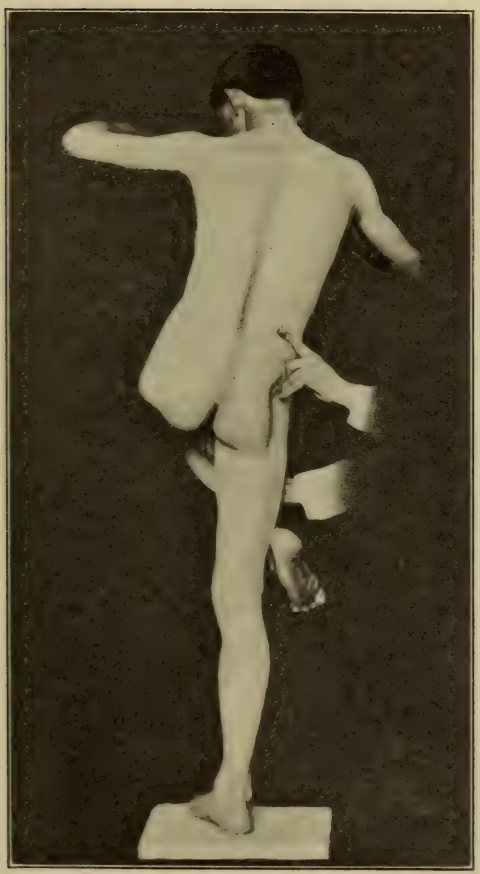

Coxa vara, showing the prominent trochanter.

FIG. 326.

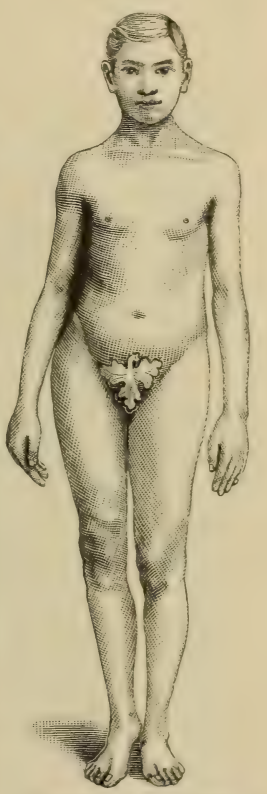

Illustrating the tilting of the pelvis and the apparent shortening of the limb in unilateral coxa vara. Actual shortening, three-fourths of an inch ; apparent shortening, two and a half inches. The deformity of the epiphyseal type was apparently induced by overexertion. (See skiagram, Fig. 323.)

Diagnosis. In most instances diagnosis may be easily made, and yet coxa vara is very often mistaken for *hip disease ;* in fact, we are indebted to this mistake for most of the specimens of the deformity that have been described. The essential differences between the two are as follows : In tuberculous disease of the

hip the motions of the joint are limited in every direction by reflex muscular spasm, and, as a rule, other evidences of the character of the disease are apparent. Coxa vara is a simple deformity; reflex muscular spasm is absent, except during exacerbations due to injury or overstrain, and movement is not limited in all directions, but only in abduction, flexion, and inward rotation when the deformity is of the ordinary type. Actual shortening is a late symptom of hip disease, while it is present from the very onset of coxa vara. It is a shortening explained by the elevation of the trochanter above Nélaton's line,

FIG. 327.

Double coxa vara of advanced degree, showing the involuntary crossing of the legs in flexion.

while such elevation in hip disease is a sign of destruction, either of the head of the bone or of a part of the acetabulum.

The deformity might be readily mistaken for *congenital dislocation of the hip*, particularly of the anterior variety, but this would be excluded by the history, since coxa vara is an acquired deformity. The diagnosis between the two affections may be easily made on the physical signs alone. In congenital dislocation, if the thigh be flexed and adducted to its extreme limit, the head and neck of the displaced bone can be distinguished beneath the distended tissues of the buttock. In coxa vara nothing but the prominent trochanter can be made out on similar manipula-

tion, while the abnormal mobility, characteristic of the dislocation, is absent. There is, however, a form of anterior dislocation in which the head of the femur has a secure support beneath the anterior superior spine in which diagnosis from the physical signs alone may be somewhat more difficult. An X-ray picture will always make the distinction clear, however.

FIG. 328.

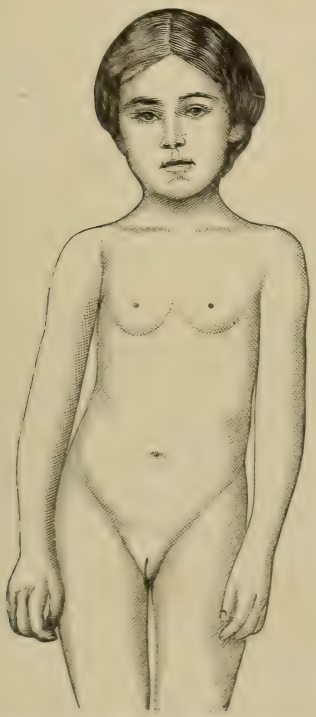

Unilateral coxa vara, showing the effect of slight depression of the neck of the left femur upon the attitude. (See Fig. 329.)

FIG. 329.

The patient, Fig. 328, eight months after cuneiform osteotomy. An absolute cure, both as regards symptoms and deformity.

Treatment. If the deformity were discovered in the early stage, one might hope to check its progress by a change in the surroundings and occupation of the patient. Standing, particularly in the attitude of rest, which throws additional weight upon the weakened part, should be avoided, and work of any kind that induces the familiar symptoms of strain should be discontinued. As much time as possible should

be spent in the open air, and diet and proper therapeutical remedies should be employed if evidence of constitutional weakness or rhachitis is present.

Locally massage of the limbs and joints and forcible manipulation, with the aim of overcoming as much of the restriction of the range of abduction as may depend upon the secondary changes in the soft parts, should be employed, reinforced by regular gymnastic exercises, with the object of improving the circulation, upon which the repair of the weakened bone depends.

If the deformity is unilateral temporary support may be employed. A perineal crutch (Fig. 226) or, if the circumstances of the patient permit, one of the convalescent hip splints that allows motion at the knee, may be used (Fig. 231). With support during the time of greatest strain—that is, when continuous walking or standing may be acquired—combined with proper exercises and massage, the weak part may become sufficiently strong to perform its function in a year or more, but supervision will be necessary for a much longer time.

Operative Treatment. Forcible Abduction. In certain instances, particularly those cases in adolescence in which the symptoms have advanced rapidly, it may be inferred that the bony structure of the affected neck is congested and softened. One may attempt, therefore, to restore the angle by forcibly abducting the thigh, as in the treatment of fracture or epiphyseal separation. (See page 549.) In this manœuvre the head is fixed by the lower portion of the capsule, and the deformed neck is forced against the upper border of the acetabulum as illustrated in the figures (Fig. 331). If the normal range of abduction can be restored, one may infer that the deformity has been corrected. The limb should then be fixed by a plaster spica bandage in this attitude of extreme abduction for two months, or until a time when consolidation in the new position is apparently complete.

A support should be used for a time, and the usual treatment by massage and exercise should be carried out during the period of convalescence.

Linear Osteotomy. The simplest and most efficient means of overcoming the adduction in older subjects is linear osteotomy of the shaft of the femur just below the trochanter minor. This may be performed by the subcutaneous method, as in the correction of the deformity of hip disease. When the bone has been divided the shaft is rotated inward until the foot is brought to the normal attitude, and it is then abducted to the normal limit;

in this attitude a plaster spica bandage is applied reaching from the axilla to the toes.

If the deformity is bilateral it is often sufficient to operate on the limb which is most affected. When the fracture is consolidated, massage, exercises, and manipulation are employed, as has been described. It may be assumed that the increased blood supply necessitated by the repair of the injury will affect favorably the weakened bone as well. The final result in several cases, in which the operation was performed by the writer, was very satisfactory.

Cuneiform Osteotomy. In younger patients the deformity may be remedied by removal of a cuneiform section of bone from the upper extremity of the shaft at the level of the trochanter minor (Fig. 330). In childhood the neck of the femur is short and the strain to which it is likely to be subjected slight; thus operative treatment may be indicated as a prophylactic measure. In fact, one should treat this deformity at the hip on the same principles as the similar distortions at the knee. Coxa vara cannot be rectified by mechanical treatment; therefore, unless it is directly contraindicated operative intervention should be advised.

In the technique of this procedure there are several points of importance. First, the restriction of abduction, of ligamentous or muscular origin, must be overcome by vigorous stretching and massage of the shortened tissues before the operation on the bone, otherwise it will be difficult to bring the two fragments into proper apposition. An incision is made from a point about one inch below the apex of the trochanter directly downward about three inches in length. The bone is thoroughly exposed by separating the periosteum from the site of operation. The base of the wedge should be about three-quarters of an inch in breadth, directly opposite the trochanter minor; the upper section should be practically at a right angle with the shaft, the lower being more oblique (Fig. 330, *2*). The cortical substance on the inner aspect of the bone should not be divided, but, reinforced by the cartilaginous trochanter minor, should serve as a hinge on which the shaft of the femur is gently forced outward, until the opening is closed by the apposition of the fragments after the upper segment has been fixed by contact with the margin of the acetabulum (Fig. 330, *3*); thus the continuity of the bone is preserved. The limb is then fixed in the attitude of extreme abduction by means of a plaster spica bandage, which should include the foot also, for about eight weeks, or until the union is firm. When the limb is brought to the line of the body the neck of the femur is restored

to its proper position (Fig. 330, *4*). This mechanical method of apposing the fragments is far more effective than any system of suture, and if the operation is carefully conducted there is no danger of displacement. In ordinary cases of this class, according to the writer's experience, the cure is absolute, both as to symptoms and to function. No after-treatment other than the support of a short Lorenz spica for a month or more is required. The opportunity for treatment of coxa vara in earliest childhood is rarely offered. It is usually the direct result of rhachitis, and

FIG. 330.

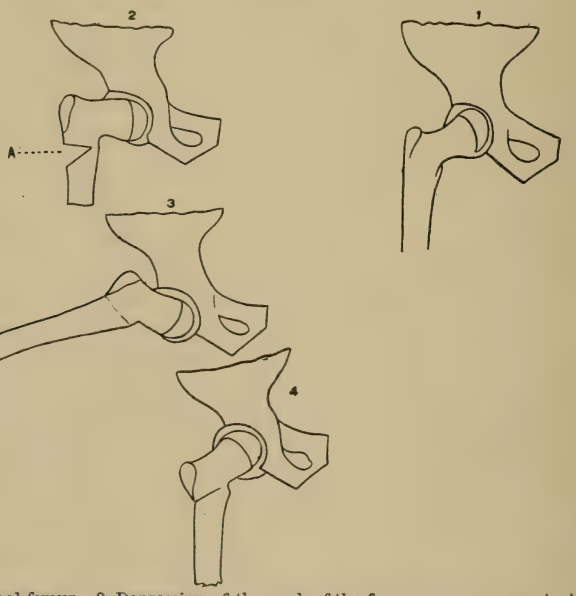

1. The normal femur. 2. Depression of the neck of the femur—coxa vara. *A*. A wedge of bone has been removed. 3. Abduction of the limb first fixes the upper segment by contact with the rim of the acetabulum, then closes the opening in the bone. 4. Replacement of the limb after union is completed elevates the neck to its former position.

in the early stage at least it is probably accompanied by other rhachitic distortions. It would be well, therefore, to examine the hip-joints of rhachitic children, especially those who present the deformity of genu valgum with reference to this distortion.[1]

Fracture of the Neck of the Femur.

Traumatic Coxa Vara. Fracture of the neck of the femur in childhood, although until recently unrecognized, is by no means

[1] The bibliography of the subject, to the extent of 127 references, may be found in an article by Wagner in the Zeits. f. Orth. Chir., 1900, B. viii. H. 2.

an uncommon accident, since twenty cases have come under the writer's observation during the past nine years.

Fracture of the neck of the femur in childhood, however, differs markedly in its symptoms and in its effects from that in later life. In childhood the immediate effects of the injury are far less disabling, and the patient is often able to walk about within a few days after the accident, from which it may be inferred that there is, in many instances, a bending and breaking of the neck without actual separation of the fragments. During

FIG. 331.

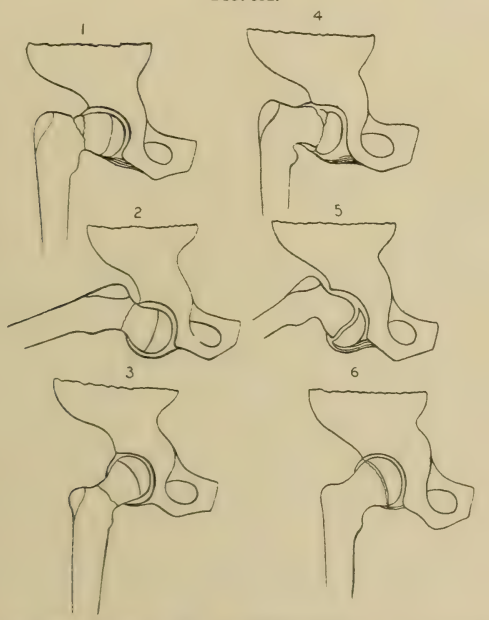

1. Fracture of the neck of the femur. 2. Restoration of the normal angle by forcible abduction. 3. The limb in normal position. Figs. 4, 5, and 6 illustrate separation of the epiphysis of the head of the femur treated by the same method.

the period of repair the limp and attendant discomfort are usually mistaken for symptoms of hip disease.

The diagnosis is usually simple. In all the cases there is a history of injury, usually a fall from a height, which confined the patient to the bed for several days or weeks. On physical examination shortening of half an inch to an inch is found, explained by the corresponding elevation of the trochanter. Motion in the joint is more or less restrained by voluntary and involuntary contraction of the muscles, but this restriction is much more marked in flexion, abduction, and inward rotation than in other direc-

tions ; a limitation explained by the nature of the displacement, the neck of the bone having been forced downward and backward.

The immediate effect of the injury is, as has been stated, less marked than in the adult, but the deformity often tends to increase in later years, because the right-angled relation of the neck to the shaft exposes it to greater strain. In a number of the patients examined several years after the injury, there was an increase of the actual shortening combined with permanent adduction. At this time the deformity could not have been distinguished, except for the history, from the ordinary coxa vara of a rather extreme degree.

Treatment. If the diagnosis is made after the accident, or before consolidation is complete, one should attempt to replace the neck in its proper relation with the shaft in order that subsequent deformity may be prevented. This may be accomplished by forcing the limb into extreme abduction, and in this position a plaster bandage, reaching from the axilla to the toes, should be applied (Fig. 331).

After consolidation of the fracture a hip splint or Lorenz spica may be worn for several months or until complete repair has taken place. Massage and forcible manipulation, if limitation of motion remains, combined with the avoidance of overstrain, may prevent the increase of the deformity. Otherwise the neck of the femur should be replaced in its normal position by the removal of a sufficient wedge of bone from the base of the trochanter as described under the treatment of simple coxa vara (Fig. 330).

Traumatic Separation of the Epiphysis of the Head of the Femur. As has been stated, in traumatic depression of the neck of the femur the fracture is usually at about the centre of the neck, which in childhood is but little more than an inch in length. In exceptional cases the head of the femur may be separated at the epiphyseal line. This disjunction is more likely to occur in adolescence and particularly in subjects suffering from coxa vara in the early stage. Thus sudden disability, following slight injury, in an adolescent who has complained of discomfort and limp for some time before, and who presents on examination the signs of depression of the neck of the femur, would suggest this accident ; but the exact diagnosis can be established only by a Roentgen picture or by operation.[1]

[1] Sprengel. Archiv f. klin. Chir., 1898, B. xlvii., S. 805. Clarke, Lancet, October 27, 1900.

The treatment is similar to that of fracture, but the functional derangement of the joint is likely to be greater for the reason that the articulating surface of the head of the femur is involved.[1]

Partial Epiphyseal Separation in Adolescence. As has been suggested, slight injury may, under favoring conditions, rupture the periosteum and the cortical substance at the junction of the epiphysis and the neck of the femur, and under the influence of use the head of the bone may be slowly depressed, the final result being the epiphyseal type of coxa vara that has been mentioned. The symptoms of this variety of deformity, which is practically limited to adolescence, resemble those of the ordinary form, except that they are more marked and more disabling.

In other cases the displacement may be greater or practically complete, in which case the disability is immediate, although the traumatism was apparently very slight.

This accident under these conditions practically never occurs in healthy children. Particular attention is called to this point, as the two classes of cases are usually confounded, traumatic depression of the neck of the femur being classed, as a rule, as epiphyseal separation.[2] The treatment has been described in the preceding section.

Fracture of the Neck of the Femur in Adult Life. The treatment by forcible abduction and fixation recommended for incomplete fracture of the neck of the femur or epiphyseal separation in childhood applies also to the same injury in older subjects. If the separation is complete the patient, under anæsthesia, is placed upon a pelvic support. Counter-traction is provided by a wide bandage passed between the thighs about the pelvis and fastened to the head of the table. The assistant makes traction on the limbs, gradually abducting them. When the limit is reached on the sound side the limb is retained in this position to serve as a model for the other and to aid in fixing the pelvis. A long plaster spica is then applied in this attitude of extreme abduction and extension over the knitted drawer, as described elsewhere. In certain instances, particularly in older subjects, the short Lorenz spica may be applied instead.

One often encounters cases in which the disability persists after fracture of the neck of the femur—a disability due in great part to flexion and adduction deformity. Such deformity may be, in

[1] Whitman. Medical Record, July 25, 1893; Annals of Surgery, June, 1897, February, 1899, and November, 1902.

[2] Hoffa. Zeitschrift f. Orthop. Chir., 1903, Band xi. Heft 3.

many instances, reduced by moderate force. If, as is often the case, the fracture has failed to unite, the upper extremity of the femur may be forced forward beneath the anterior superior spine and the limb may be fixed in an attitude of abduction and extension by a Lorenz spica, as originally suggested by Lorenz.

Coxa Valga.

Coxa valga is a term used to signify an abnormal elevation of the neck of the femur in its relation to the shaft, in contrast to coxa vara, an abnormal depression. This deformity is sometimes observed in limbs which have never supported weight. It is a possible result of injury also. It is of no importance from the orthopedic standpoint.

CHAPTER XVI.

DEFORMITIES OF THE BONES OF THE LOWER EXTREMITY.

Of the distortions of the lower extremity bow-leg and knock-knee are by far the most common, comprising about 15 per cent. of the total cases in orthopedic clinics. Of the two bow-leg is the more frequent in all tables of statistics, and it is probable that the proportion of bow-leg to knock-knee is much larger than would appear from the hospital records; for genu valgum is generally recognized as a serious deformity, while bow-leg is known to be of little consequence except from the æsthetic standpoint, so that its rectification is more often trusted to the power of nature.

Both deformities appear to be more common in male than in female children—a fact explained, perhaps, by the greater weight and the greater susceptibility of the former. But here, again, statistics may be influenced somewhat by the fact that bow-legs are considered to be of more consequence to the boy than to the girl, because of the concealment that the skirts will insure if the distortion is not outgrown in childhood.

Statistics. The relative frequency of the two deformities may be indicated by the statistics of the Hospital for Ruptured and Crippled for a period of ten years. During this time 5441 cases were recorded, 3452 cases of bow-legs (63.4 per cent.), 1989 of knock-knees (37.6 per cent.). Of the 3452 cases of bow-legs 2030 were in males (58.8 per cent.), and 1422 were in females (42.2 per cent.). The 1989 cases of knock-knees were more evenly divided between the sexes, 1024 being in males (51.4 per cent.), and 965 in females (48.6 per cent.).

It will be noted that 45 of the cases of genu valgum were in patients over fourteen years of age, as compared with 34 cases of adolescent or adult bow-legs. The writer's personal experience in the clinic enables him to state that a large proportion of the cases of genu valgum actually developed or increased to an extent demanding treatment during adolescence, while most of the cases of bow-leg deformity in patients more than fourteen

years of age had existed since early childhood or were the result of injury or disease.

BOW-LEGS.

	Year.	No. cases.	Males.	Females.	Over 21.	Over 14.
1	1899	400	236	164	0	5
2	1898	406	255	151	0	2
3	1897	467	268	199	4	1
4	1896	356	200	156	0	1
5	1895	336	200	136	2	1
6	1894	310	170	140	1	2
7	1893	262	157	105	3	3
8	1892	306	189	117	1	2
9	1891	303	174	129	1	1
10	1890	306	181	125	1	3
		3452	2030	1422	13	21

KNOCK-KNEES.

	Year.	No. cases.	Males	Females.	Over 21.	Over 14.
1	1899	202	120	82	1	4
2	1898	233	135	98	0	11
3	1897	222	120	102	2	5
4	1896	232	101	131	0	0
5	1895	210	109	101	0	2
6	1894	212	86	126	0	0
7	1893	162	80	82	1	2
8	1892	168	89	79	8	2
9	1891	189	92	97	1	2
10	1890	159	92	67	3	3
		1989	1024	965	16	31

The Etiology of Genu Valgum, Genu Varum, and of Other Distortions of the Bones of the Lower Extremity. The common predisposing cause of simple deformities and disabilities of the lower extremities—in other words, those not caused by local injury or local disease—is the erect posture, when for any reason the bones and the joints are unequal to the strain of locomotion and to the task of sustaining the weight of the body.

Time of Onset. At two periods of life the deformities under consideration most often develop. The first is in early childhood, when the upright posture is first assumed; the second is in adolescence, when the rapid growth and other changes incident to this period may lessen the stability of the supporting structures, and when the strain of laborious occupation may be added to that of the increasing weight of the body.

The deformities of adolescence are, however, relatively insignificant in number compared with those of early childhood, for in childhood inherited weakness or weakness that is the direct result of malnutrition at once develops into deformity under the strain of standing and walking. Thus, as a rule, the deformities under consideration first attract attention soon after the child

begins to walk, and the patients are usually brought for treatment during the second or third year of life. If the deformities are severe the body usually presents the evidences of general rhachitis; in other instances the distortion of the legs is almost the only sign of its presence, and in a certain number there may be no evidence whatever of malnutrition or disease.

Predisposition to Deformity. It is not always easy to explain why weak legs bend in one way rather than in another. In some instances it is probable that a slight degree of deformity is present before the child begins to walk. For example, a slight outward bowing of the legs is said to be common in early infancy, and the use of heavy diapers might favor an increase of the distortion. Knock-knee may be induced, apparently, by holding the infant on the arm with the knees pressed against the chest, and certain cases of knock-knee and bow-leg combined appear to be caused directly by this manner of carrying the infant habitually upon one arm.

FIG. 332.

Habitual posture as a factor in the etiology of rhachitic bow-leg.

The legs of rhachitic children, who have never walked, are often somewhat distorted, and in many instances this may be explained by the habitual postures (Fig. 332).

A moderate degree of bow-leg is not infrequently seen in vigorous infants who stand and walk at an early age. Aside from the determining curve in the bone that may be present before the child begins to walk, this predisposition toward bow-leg may be explained, perhaps, by the fact that young infants often separate the feet widely in walking, and the swaying of the body from side to side may tend to bend the legs outward. In weaker or less vigorous children a slight degree of knock-knee is not uncommon, induced more directly by weakness or inactivity of the muscles, as a result of which the child stands with the knees somewhat flexed and pressed together, while the feet are separated and everted, an exaggeration of the so-called attitude of rest.

Bow-leg is not uncommon in adult life, and it is popularly associated with strength and activity. Undoubtedly the attitudes of activity would tend to induce bow-leg rather than knock-knee, so that this tradition may have a foundation of truth. It is said to be common among those who ride constantly, and it may be a direct result of injury or disease of the knee-joint, but it may be stated that well-marked bow-leg in an adult has almost always existed since childhood. This statement cannot be made of genu valgum, since it may develop or increase during adolescence or even in adult life. The predisposing cause is weakness or overstrain, and, as has been stated, in the popular mind the deformity is characteristic of weakness.

The Attitude of Rest. Genu valgum is an exaggeration of what is known as the attitude of rest or relaxation, in which the weight of the body is thrown in great part upon the ligaments of the three joints of the lower extremity. In the attitude of rest the pelvis is tilted forward, the femora are rotated inward upon the tibiæ, and the feet are separated and everted, so that the greatest strain falls upon the inner side of the knees and of the feet. Thus, what is known as flat-foot is often combined with knock-knee; knock-knee may cause flat-foot, but more often the flat-foot may induce knock-knee, or both may be the effect of the same general cause. Genu valgum, in the slighter degree at least, may be induced directly by improper attitudes, but the attitudes are, as a rule, the result of overwork to which the mechanism is subjected; thus the knock-knee of adolescence is

so common among the bakers of Vienna that "baker's knee" is there synonymous with genu valgum.

Genu valgum may be secondary to distortion elsewhere. For example, compensatory knock-knee is usually combined with extreme adduction of the thigh; it may be the result of the inactivity necessitated by the treatment of hip disease; it may be a direct result of injury, and it is sometimes an accompaniment of osteomyelitis or osteoperiostitis of the tibia, which causes an overgrowth and abnormal lengthening of the leg. There are, however, exceptional cases which would not be classed with the ordinary deformity.

The Outgrowth of Deformity. In considering the treatment of the simple static deformities of the lower extremity which are usually the result of a temporary weakness of structure, one must first answer the question, "Will not the child outgrow it?" This belief in the spontaneous cure of deformity is very strong, not only among the laity, but among physicians as well; and it rests upon the common observation that crooked legs become straight, or at least less deformed, with the growth of the child. In fact, if one were to judge from the general observation of the effect of growth upon the deformities of this class, or even from the tracings of the legs of rhachitic children taken from year to year, one might conclude that all deformities of this class might be safely left to themselves. As an illustration of positive evidence on the subject, the observations of Kamps[1] on 32 cases of rhachitic distortion of the lower extremity may be cited. Four and one-half years after the cases were first seen and recorded examination showed that 75 per cent. were cured, 15.3 per cent. improved, while 9.7 per cent. were unimproved. His conclusions are that such deformities do not, as a rule, require special treatment in early childhood, but that after the age of six years the prognosis for spontaneous cure is unfavorable.

Veit[2] photographed a number of rhachitic children seen in the surgical clinic of the University of Berlin, and after a lapse of two or three years made another series of photographs of the same patients, who had meanwhile received no treatment. His conclusions are similar to those of Kamps, namely, that surgical treatment is not required for deformity of this character in children less than six years of age. In two classes of cases, however, the prognosis for spontaneous cure is not favorable, those in

[1] Beiträge zur klin. Chir., B. xiv. H. 1.
[2] Archiv f. klin Chir., B. l., S. 130.

which the growth has been checked by the rhachitic process, and in certain cases of extreme bow-legs, "O" legs (Fig. 333).

The rectifying force of nature acts in two ways. Assuming that the deformity reached its limit during the period of original weakness, it must, of course, become relatively less as the body increases in length and size. In fact, the outgrowth of deformity has a direct relation to the rapidity of growth during the early years of childhood. The second manifestation of the power of nature is more positive. It may be assumed that when the deformity is progressive all the tissues are affected by the weakness; consequently the attitudes of the child are those that can be most easily assumed under the abnormal conditions. But when the primary cause of the weakness, in most instances rhachitis, is no longer operative, the muscles take on new activity and vigor, and the actions and attitudes, in spite of the deformity, become approximately normal. Then, according to Wolff's law of transformation, the internal structure of the affected bones begins to change to accommodate itself to the new conditions of weight and strain induced by the change in action and attitude; and to this rearrangement of the internal structure the external shape of the bones must conform in a gradual growth toward the normal contour.

FIG. 333.

A type of deformity in which the prognosis as regards outgrowth is bad.

On this theory it is easily explained how the natural outdoor life of the country has long been celebrated as an effective treatment for this class of deformity. But it by no means follows that deformity is always outgrown even under favorable conditions. Improper attitudes that favor and cause deformity are often observed among those who are free from weakness and disability and from the influences of unfavorable surroundings; and such attitudes are, of course, more likely to persist in those who were once obliged to assume them because of weakness and

deformity. Again, the weakness of structure or function may be an inherited peculiarity, or it may be induced by disease or by improper surroundings, influences that may continue for many years and thus serve to check the natural tendency toward cure.

The observations on the outgrowth of deformity have been confined, as a rule, to the period of childhood, and most often

FIG. 334.

Extreme deformities, the result of infantile rhachitis. The left leg forms practically a right angle with the thigh. (See Fig. 338.)

they have been made with reference to the more serious grades of distortion, which are the direct result of rhachitis.

It must be borne in mind, however, that the true significance of these deformities in the adult must be judged from the æsthetic rather than from the medical point of view, and although the extreme degrees of bow-leg and knock-knee are relatively rare, yet in the minor grade both deformities are very

common in adult males and in all probability in adult females also.

In 1887 the writer[1] noted, among 2000 adult males observed on the streets of Boston, 400 cases of bow-leg and 32 cases of knock-knee. One may assume, then, that the legs of about one adult male in five deviate more or less from the line of symmetry—a conclusion that has been confirmed by many subsequent observations. It may be admitted that a certain number of the distortions under consideration are acquired during adolescence, but it is probable that the greater number of those that may be noted in walkers upon the streets represent the incomplete outgrowth of a deformity of childhood.

The statement is often made that these distortions of the legs are common in childhood, but rare in adult life. Just what the proportion may be in childhood it is impossible to say, but it is not likely to be greater than one in five. One must conclude that statistics, on which such statements are based, have been made up from the records of hospitals where it is extremely uncommon for an adult to apply for the treatment of bow-leg, to which he has become accustomed since childhood, unless the deformity is extreme or is attended by pain.

Granting that the power of nature is quite sufficient to modify or to cure even the more extreme distortions of childhood, still it is evident that this natural force is often ineffective in completing the cure. Therefore, in doubtful cases at least, one should lend assistance in that class of patients likely to appreciate the advantage of symmetry over deformity, even though it be unattended by discomfort or disability.

Genu Valgum.

Synonyms. Knock-knee, in-knee.

In the erect posture the thighs, whose upper extremities are separated by the pelvis and by the projecting femoral necks, incline slightly inward to the knees, forming an angle at the knee, opening outward, of about 172 degrees. This angle varies with the breadth of the pelvis, and it is, therefore, less in adult females than in males (Figs. 335 and 336). The internal condyle of the femur is slightly longer than the external; thus the inclination of the femur is compensated and the plane of the knee-joint is horizontal.

[1] New York Medical Record, July 30, 1887.

When the inward projection of the knees is increased to a noticeable degree the tibiæ are no longer perpendicular; their upper extremities incline inward so that in the erect posture the feet are separated when the knees are in contact (Fig. 337). In the slighter grades of knock-knee, which are due in great degree to laxity of the ligaments, the deformity is apparent only when the weight of the body is borne, but in more marked cases, although the distortion is increased by the weight of the body, it cannot be overcome when this is removed, because it depends upon actual changes in the shape of the bones themselves.

As has been stated, the normal inward inclination of the femur is compensated by the greater length of the internal condyle, and

FIG. 335. FIG. 336.

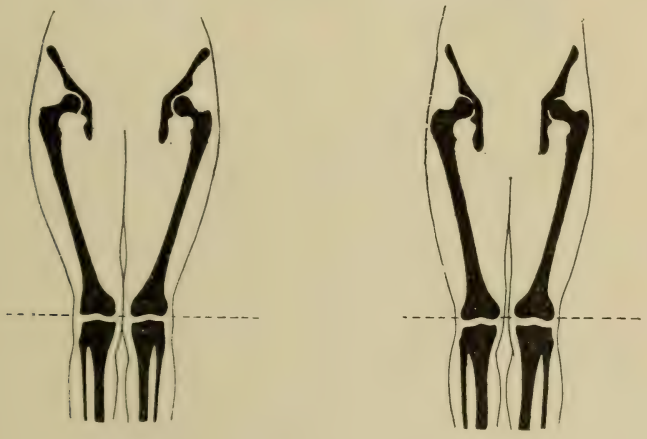

Female. Male.

The normal inclination of the femora. (Pfeiffer.)

in the deformity of knock-knee the plane of the knee-joint is still preserved by an apparent elongation of the inner condyle. Formerly it was supposed that there was an actual overgrowth of this part of the epiphysis, which caused the deformity, but the observations of Mikulicz and Macewen have shown that this apparent lengthening is in reality due in great part to a deformity of the lower extremity of the shaft of the femur, which is so bent that the epiphyseal line has an increased obliquity. And the hypothesis that bone grows more rapidly when relieved from weight and strain has been disproved by Wolff, who has demonstrated that changes in the bones are the result of accommodation to altered function and attitude. (See page 235.) The deformity

is not limited to the femur; in most instances there is a similar, although usually slighter, irregularity in the epiphyseal line of the upper extremity of the tibia, the shaft being so bent that when it is placed in the perpendicular position its internal condylar surface is higher than the external. In some instances the primary and principal deformity is of the tibia, the distortion being most marked in its upper third (Fig. 337).

FIG. 337.

Adolescent knock-knees. Deformity most marked in the tibiæ. (See Fig. 340.)

Changed Relation of the Femur and Tibia. In addition to the direct deformities of the bones there is a change in the relation of the femur to the tibia. The former is rotated inward and the latter is rotated outward. In some instances there is also a certain degree of overextension at the knee. This is more often observed in the adolescent type, in which there is laxity of the ligaments (Fig. 337). In the ordinary form of rhachitic knock-knee in childhood the habitual attitude is one of slight flexion

at the knees, and in extreme cases there may be actual limitation of the range of extension at the knee, and at the hip as well.

The Accommodative Attitude. When the limb is fully extended the deformity is most marked, because the shortened ligaments and tissues on the outer aspect of the joint become tense, and because the outward rotation of the tibia is increased. As the leg is flexed the deformity lessens, and in the attitude of complete

FIG. 338.

Skiagram of Fig. 334, showing the deformity to be due to distortions of the diaphyses of the bones, while the epiphyses are practically normal.

flexion it disappears (Fig. 340). This is explained by the fact that the posterior surface of the condyles is not affected by the deformity of the shaft, while the relaxation of the ligaments and the outward rotation of the femora allow the tibiæ to become parallel with one another. This accounts for the habitual attitude of slight flexion which is so often assumed by patients who thus unconsciously accommodate themselves to the deformity.

Secondary Deformities. The outward inclination of the leg throws more weight upon the inner border of the foot and tends to depress it into the attitude of valgus. Thus knock-knee in weak children is often accompanied by flat-foot, but in the more extreme grades of deformity the efforts of the patient to compensate for the abnormal separation of the feet may result in habitual supination; in fact, confirmed and extreme knock-knee in older subjects is usually accompanied by a slight degree of varus that becomes very evident after the correction of the deformity by operation. Even in the mildest type of knock-knee this compensatory and conservative effort of nature is shown by the so-called pigeon-toed walk, which is often the first symptom that attracts attention.

FIG. 339.

Deformity of the femur in genu valgum. (Mikulicz.)

Gait. The gait of the patient with well-marked genu valgum is peculiarly awkward and shambling. The knees "interfere," and must be assisted, as it were, in the effort to pass one another in walking. In the slighter cases the thigh is abducted and rotated outward at the moment of passing its fellow, the movement being then reversed as it, in its turn, supports the weight; but in the more severe type this voluntary effort of the muscles of the leg is not sufficient, and, in addition, the body is swayed from side to side and the legs are alternately swung outward and lifted around one another.

The deformity and the effects of the deformity on the gait and attitude are the most important symptoms, as of other distortions of similar origin. The patient is, as a rule, easily fatigued, and pain during the progressive stage, referred to the inner side of the knee, where the ligaments are subjected to continuous strain,

is a common symptom, particularly in the adolescent type of genu valgum.

Unilateral Knock-knee. This description refers particularly to the cases in which the deformity is bilateral. Not infrequently it is unilateral, the limb being so shortened by the distortion that a well-marked limp replaces the swaying gait. The pelvis is tilted toward the short limb, while the body is inclined in the opposite direction, thus in cases of long standing a permanent curvature of the lumbar spine may be present.

FIG. 340.

Adolescent knock-knee, showing the disappearance of the deformity when legs are flexed. (See Fig. 337.)

Knock-knee Combined with Bow-leg and with General Rhachitic Distortions. Occasionally the unilateral knock-knee may be accompanied by an outward bowing of its fellow; and in the marked distortions of the lower extremity, induced by rhachitis, the bones may be twisted and bent in various directions, although the outward expression of the deformity may be genu valgum. For example, the femora may be bent forward and outward above and inward and backward below, while the tibiæ may be bent inward above and outward and forward below.

In other instances, especially in the slighter rhachitic deformities, an outward bowing of the leg may accompany a slight degree of knock-knee, so that it may be difficult to classify the deformity.

In the more extreme deformities of the rhachitic type the shape as well as the contour of the bones is markedly modified, for example, the internal border of the tibia may become very prominent at its upper extremity, and may project beneath the skin like an exostosis (Fig. 341). A change in the contour of the fibula accompanies and corresponds to that of the tibia, although

FIG. 341.

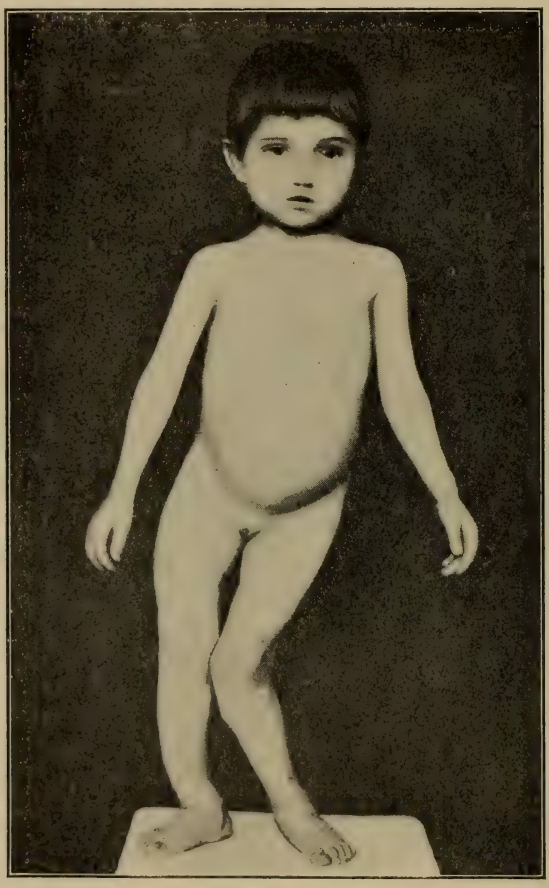

Knock-knee and bow-leg.

it is, as a rule, much less pronounced. As has been stated, the internal structure or architecture of the affected bones is changed to accommodate the new static conditions, and according to Wolff the internal change precedes the external deformity.

Pathology. In knock-knee due directly to rhachitis the changes in the bones and in the epiphyseal cartilages are char-

acteristic of that affection, but in the milder grades of deformity, aside from the change in the contour of the bones, the transformation of the internal structure, and in some instances slight thickening or irregularity of the epiphyseal cartilages, there is little noteworthy change from the normal (Fig. 339). The tissues on the internal aspect of the joint are relaxed; those on the outer side, the lateral ligaments, the capsule and the biceps muscle, are contracted and resist the reduction of the deformity. In the interior of the joint slight changes in the articulating surfaces of the bones, and evidences of chronic irritation of the synovial membrane have been described.

Measurements. There are various methods of measuring the deformity. One of the simplest and most practical is to trace the outlines on paper, while the child is seated with the limbs fully extended, the knees being sufficiently separated to allow the pencil to pass between them. The increase of the deformity, depending upon the laxity of the ligaments and upon the outward rotation of the tibiæ, may be estimated by measuring the distance between the two internal malleoli when the patient stands, the knees being slightly separated as before, and comparing this measurement with that between the similar points in the tracing.

In the early stage of progressive knock-knee, particularly in the type not caused directly by rhachitis, laxity of ligaments and the habitual assumption of the attitude of rest will account for the deformity, which the patient may be able to overcome, in great degree at least, by voluntary effort. This voluntary control of the deformity is very suggestive, as indicating certain factors in its etiology, and the principles that should be followed in its treatment.

Treatment. The treatment of the deformity under consideration may be classified as expectant, mechanical, and operative.

Expectant treatment should not be expectant in the sense that nothing is to be done to correct the deformity, but expectant in that more positive treatment by braces or by operation is delayed or avoided if it proves to be unnecessary.

During this period the predisposing cause of the deformity, if it is constitutional, should receive proper dietetic or medicinal treatment, as already described in the chapter on Rhachitis. And, if possible, the direct exciting causes of the deformity must be removed—that is to say, the improper attitudes, or, in the adolescent, the predisposing occupations should be discontinued. General massage of the limbs may be employed with advantage;

in older children special exercises may be practised, and in all cases, whether braces are used or not, direct manipulation of the distorted limbs is of the first importance.

Manipulation. The limbs should be vigorously massaged at morning and night, and forcibly straightened. The latter procedure is conducted as follows: The patient is seated in a chair,

FIG. 342.

The Thomas knock-knee brace.

FIG. 343.



Thomas knock-knee braces with pelvic band. The pelvic band may be divided also, the two parts being joined by straps (Fig. 344).

the limb being fully extended so that the deformity is made as extreme as possible. One hand then clasps the knee, the palm lying against its inner aspect; with the other the calf is grasped firmly and the leg is then gently straightened over the fulcrum formed by the palm of the hand, and is held in the corrected position for a moment. This manipulation should be continued

with gradually increasing force, although not to the extent of causing actual pain, for ten minutes at least twice in the day and oftener if possible.

Posture and Exercise. It has been stated that genu valgum is often accompanied, especially in the rhachitic cases, by flat-foot, while in another type the inversion of the feet, or in the more

FIG. 344.

Modified Thomas knock-knee braces applied.

severe cases the actual fixed attitude of varus, indicates the effort of nature to withstand and to compensate for the deformity at the knee. This serves as an indication for making the soles of the shoes thicker on the inner border, as in the treatment of flat-foot, in order to throw the strain upon the outer border of the foot. The patient should be instructed to walk with the feet

parallel with one another, and for older children the tip-toe exercises, in which the body is raised upon the toes as many times as the strength permits, or games or exercises in which the legs are extended should be encouraged. Such exercises are often efficacious in the early stage of adolescent knock-knee, for, as has been mentioned, genu valgum is an exaggeration of the attitude of rest; therefore, its progress should be checked by the assumption of the attitudes proper to activity. Bicycle, and particularly horseback, riding may be recommended also in this class of cases. A careful record of the deformity should be kept during this tentative treatment, and if it improves somewhat one is justified in delaying the more radical measures. This question may be decided, as a rule, in three months if instructions are faithfully followed.

Treatment by Braces. The most efficient brace for the treatment of genu valgum is the simple straight steel bar or splint extending from the trochanter to the heel of the shoe, without joint at the knee. The greater efficacy of the rigid bar as compared with the jointed brace is explained by the fact that the rectifying force acts constantly when the joint is fixed, and because, in many instances, the patient habitually flexes the knees so that direct pressure cannot be made upon the deformity by a brace that allows this attitude.

The Thomas Brace. The simplest and cheapest brace is that of Thomas, which consists of a light steel bar provided with a pad at its upper end for pressure against the trochanter, while the lower, rounded extremity is turned inward at a right angle, to pass through the heel of the shoe. The knee is fixed by a posterior bar attached to a thigh and calf band, as illustrated in the figure. When the brace is applied the knee is drawn backward and outward and is attached firmly to the brace by a roller bandage (Fig. 342).

In the more extreme cases in which the knees and thighs are habitually flexed, the addition of a pelvic band attached to the uprights by a free joint at the hips adds to the comfort and efficiency of the apparatus, as the attitude of outward or inward rotation can be regulated by twisting the uprights slightly. Or the pelvic band may be divided and attached by means of straps on the front and back. The uprights may be bent somewhat inward at first, and as the legs become straighter they are straightened and finally bent slightly outward to allow for the overcorrection of the deformity (Fig. 344). Twice a day the

braces should be removed to allow for massage, manipulation, and for voluntary exercises of the limbs. In most cases the braces are not employed at night, although the rectification of the deformity may be hastened by their constant use.

If the deformity is unilateral so that a brace is required for one limb only, the other shoe should be raised by a cork sole about three-quarters of an inch in thickness, to make walking easier. Children soon become accustomed to the braces and walk easily in spite of the absence of joints at the knees.

Another simple and efficient brace is that used at the Children's Hospital at Boston (Fig. 345). The upper part of the brace is turned backward and upward to lie against the buttock, and the feet can be rotated in or out by lengthening or shortening straps passing before and behind the body. Braces jointed at the knee are sometimes employed, but they are, as a rule, ineffective except in the slighter cases in which the deformity depends upon laxity of ligaments rather than distortion of bone.

FIG. 345.

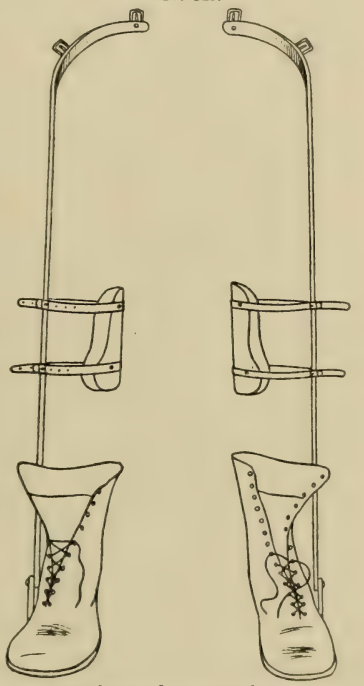

Long braces for genu valgum. (Bradford and Lovett.)

DURATION OF TREATMENT BY BRACES. The duration of the brace treatment depends, of course, upon the degree of deformity, the age of the child, and upon the efficiency of the apparatus. From six months to one year of treatment by this means is usually required. The cure is assured by the gradual adaptation of the parts to the new static conditions. The contracted tissues of the outer aspect of the joint become lengthened ; the lax ligaments on the inner side contract ; the internal structure of the condyles and of the adjoining diaphysis is gradually transformed and at the external contour of the bone becomes correspondingly straighter. When the braces are discarded attention should be paid to the attitudes, and the exercises that have been mentioned should be continued in order that relapse may be prevented.

The Plaster Bandage. When the bones are yielding, as in the deformity in young children, it may be corrected rapidly by the repeated applications of plaster bandages, the limbs being straightened as far as possible without causing discomfort at each sitting, or it may be corrected at once under the influence of anæsthesia, which is the better method.

Operative Treatment. Immediate correction of the deformity, when it is at all marked, is, as a rule, indicated after the age of four or five years, and is a satisfactory treatment at any age except during the period of active rhachitis. It is perhaps needless to remark that the necessity for operation implies neglect of proper preventive treatment or the failure of the manipulative and mechanical methods, because of their improper application. While it is possible to correct deformity of the bones by mechanical treatment in cases far beyond this limit of age, yet the time required and the discomforts of the treatment exclude it in all but very exceptional cases.

Osteotomy. At the Hospital for Ruptured and Crippled osteotomy is usually performed in the treatment of genu valgum by means of the small Vance osteotome, the so-called "subcutaneous osteotomy" (Fig. 316).

The limb having been prepared in the usual manner is semiflexed, and the inner surface of the knee is placed on a firm sandbag. With the fingers the femur is firmly grasped just above the condyles, so that its size and position may be accurately determined, and the sharp osteotome about the size of a lead-pencil is forced with its cutting edge parallel to the axis of the thigh down to the bone, at a point about one and a half inches above the external tuberosity. While it is held firmly in position against the bone it is turned to the transverse direction and is then driven through the cortex. When it enters the medullary canal, as is made evident by the lessened resistance, it is partly withdrawn and moved slightly to one side and the other, and driven through the cortical substance until by gentle force the bone may be fractured. The osteotome is then withdrawn; the minute wound is covered with a pad of dry gauze, or, if the oozing is profuse, it may be closed with a catgut suture. The deformity is then overcorrected sufficiently to simulate well-marked genu varum, and a plaster spica bandage is applied. If the deformity is bilateral both limbs are operated upon at the same sitting.

The plaster bandage is continued for from four to six weeks, and it is then usually supplemented by a brace, which may be

worn with advantage for several months, because of the laxity of the ligaments of the knee-joint, which usually accompanies extreme deformity of rhachitic origin. In less marked cases and in older subjects the support is unnecessary. Massage and exercises during the stage of recovery should be employed if possible.

Incomplete osteotomy and fracture in the manner described has been employed at the Hospital for Ruptured and Crippled in a very large number of cases without a single unfavorable result. The discomfort is insignificant, and confinement to the bed after the third day is unnecessary.

Cuneiform Osteotomy. In the more extreme cases of general rhachitic deformity of the lower extremity in which the

Fig. 346.

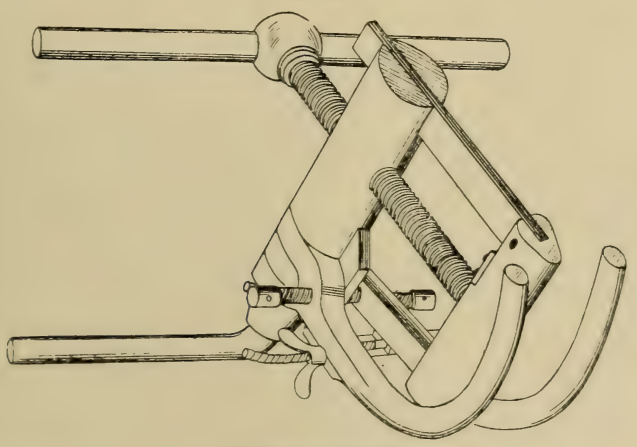

The Grattan osteoclast.

tibia is implicated, it is sometimes advisable, in addition to the osteotomy of the femur, to remove a cuneiform section of bone from the inner side of the tibia just below the epiphysis, in order to straighten the leg completely. In such cases it is better to perform the second operation at a later time, in order that the effect of the femoral osteotomy may be observed. In exceptional cases the deformity may be practically confined to the tibia; in such instances it should be corrected by a primary cuneiform or linear osteotomy.

Osteoclasis. Osteoclasis, by means of the Grattan osteoclast, is an effective operation. With this instrument the bone may be broken above the condyles at the desired point. The lower resistant bar is applied over the external condyle, the upper

about four inches higher. The limb is then firmly fixed by the hands of an assistant, and the breaking bar is screwed rapidly home, breaking or bending the bone at the point of election. The deformity is then overcorrected in the manner described. Not infrequently in rhachitic cases the principal or primary distortion is of the tibia. In such cases the correction is made at this point. If it is necessary to operate upon both the femur and the tibia the osteoclast, which bends and breaks, is to be preferred to osteotomy.

The adolescent type of genu valgum is not often extreme. As a rule, the deformity of the bone is of comparatively short duration, and it is accompanied by considerable laxity of ligaments. In the more chronic cases the osteotomy above the condyles may be performed in the manner described, but in Berlin and Vienna, where the deformity is more common than in New York, other procedures are often employed.

Wolff's Treatment. One method is that of Wolff, who by means of the "Etappen Verband" gradually corrects the deformity.

The patient is anæsthetized, and the limb, having been carefully protected with cotton, particularly so about the malleoli, the patella, and the inner condyle, is enveloped in a firm plaster bandage reaching from the malleoli to the pubes. When the plaster begins to harden one assistant steadies the pelvis, another holds the inner condyle, while the operator draws the leg inward with moderate but persistent force against the fulcrum formed by the hand of the second assistant, and holds it firmly in the partly corrected position until the bandage is firm. About three days later a wedge-shaped section of the bandage about one inch in width is removed from the part that covers the inner half of the knee, the outer half of the bandage being simply divided. The leg is then forced inward until the two sections are again brought into contact. The position is retained by an additional plaster bandage about the weakened part. This procedure is repeated at intervals until the leg is completely straightened—a result that is often accomplished in two weeks. No anæsthetic is required for the secondary corrections. When the deformity has been corrected the patient is allowed to walk about, and for convenience the plaster bandage is divided into a thigh and leg part, which are attached by lateral joints incorporated in its substance so that motion is allowed. This apparatus must be worn for several months, and is, of course, to be supplemented by massage and exercises.

Lorenz's Operation. Another means of correction of deformity without open operation is that employed by Lorenz, what he calls "Intra-articulare modelirerende redressement." In this operation the deformity is reduced under anæsthesia at one sitting by the gradual application of force by means of the Lorenz osteoclast. The reduction depends partly upon the stretching of the external ligaments and partly upon the actual bending of the diaphysis of the bone, as in the Wolff method, and sometimes upon actual separation of the epiphysis.

When the limb has been straightened, or somewhat overcorrected even, a long plaster bandage is applied which is worn for six weeks and is then replaced by a jointed walking brace to be worn for about a year. The operation is not attended by severe pain, and the patient is usually allowed to walk about in a few days.

Genu Varum.

Synonym. Bow-leg.

The term bow-legs includes, in its popular sense, all the distortions that cause a separation of the knees when the ankles are in contact with one another. But, strictly speaking, genu varum is the reverse of genu valgum—that is, the principal distortion is at or near the knee-joint—while bow-leg, as the name implies, is a simple bowing of the tibia and fibula, as a rule near the ankle-joint (Fig. 347). In true genu varum a line dropped from the head of the femur falls inside the knee (Fig. 333); the inner condyle of the femur and the inner tuberosity of the tibia bear the greater part of the weight; the outer condyle is on the same level or somewhat lower than the internal, and the outer tuberosity of the tibia may be somewhat higher than the internal. The femur is abducted and rotated outward; the tibia is rotated inward. These changes, it will be noted, are the reverse of those found in genu valgum. As has been stated, the deformity of genu valgum disappears when the legs are flexed, and in genu varum, if the legs are flexed and the knees are placed in contact with one another, the malleoli may be actually separated, simulating the deformity of knock-knee (Fig. 348). This is explained by the inward rotation of the femora, necessitated by placing the knees in contact with one another.

In genu varum the distortion of the bones is not as strictly confined to the neighborhood of the knee-joint as in genu valgum, and in simple bow-leg there is almost always a certain amount of

distortion at the knee, dependent, in part, upon laxity of the ligaments. It is proper, therefore, to use the two terms synonymously, although one must recognize a decided difference between the genu varum type, in which the deformity is greatest at the knee, and which is accompanied, as a rule, by marked

FIG. 347.

The genu varum type of bow-legs, showing the outward rotation of the femora.

FIG. 348.

The same patient, showing the separation of the malleoli when the knees are in contact.

laxity of the ligaments (Fig. 333), and the bow-leg type, in which the deformity may be strictly confined to the lower third of the leg (Fig. 353).

Symptoms. As was said of genu valgum, the deformity is the principal symptom. The gait is somewhat rolling, because

each foot must describe a part of the arc of a circle before reaching the ground ; and because of the inward rotation of the tibiæ, or because of the inward spiral twist of the bone that is sometimes present, patients often toe-in in walking.

Except in extreme cases the weakness and awkwardness characteristic of genu valgum are absent. This may be explained by the fact that the relation of the bones is such that the general attitude is one of activity, the weight falling on the outer side of the feet ; thus flat-foot is uncommon as an accompaniment of bow-leg, except in the early or rhachitic type.

FIG. 349.

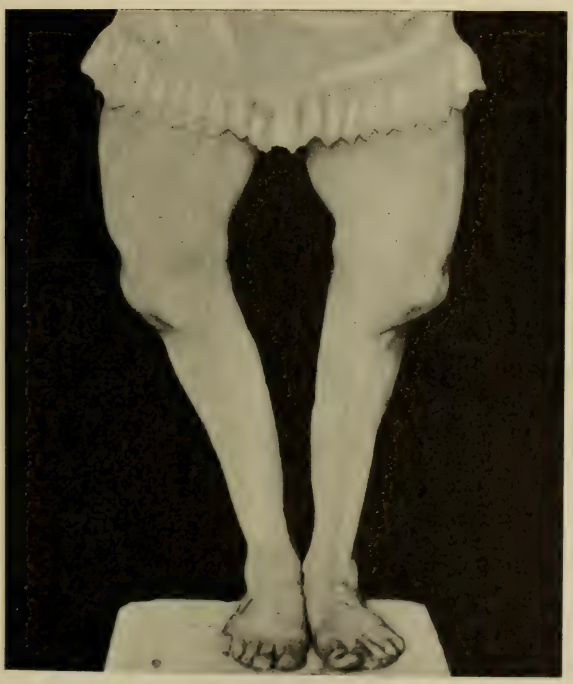

Genu varum of rhachitic origin in an adult.

Measurements. The full effect of the deformity appears only when the weight of the body is borne, but for practical purposes the tracing of the extended legs is the best method of recording the fixed deformity. In true genu varum the deformity is greatest at the knee, and in the distortion the apposed surfaces of the femur and of the tibia participate.

In simple bow-leg the deformity may be confined to the tibia,

which, in addition to the outward bowing, may be twisted inward somewhat upon its long axis.

Genu varum may be unilateral or it may be combined with genu valgum of its fellow (Fig. 341), and occasionally slight knock-knee and slight bow-leg may be present in the same limb.

Treatment. **Expectant Treatment.** The slighter cases of bow-leg in early childhood may be treated by manipulation. The leg, grasped firmly at the ankle and at the knee, is straightened with a certain amount of force over and over again. Gradual correction by this means may be hastened by making the sole of the shoe slightly thicker on the outer border. This aids also in correcting the secondary pigeon-toe, but if the foot is weak, as it usually is in rhachitic cases, this method should not be employed, as it might induce flat-foot.

FIG. 350.

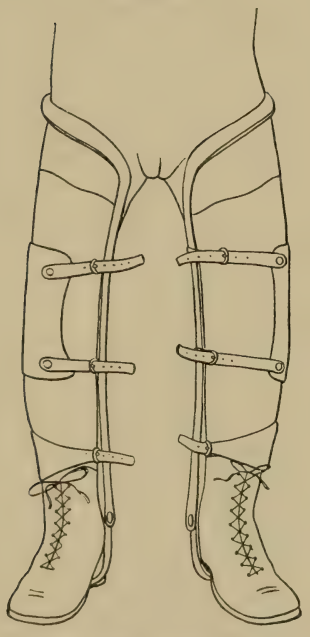

Long braces for genu varum. (Bradford and Lovett.)

Treatment by Braces. If the deformity is more extreme, or if improvement does not follow expectant treatment, apparatus should be employed. If the distortion is confined to the lower third of the tibia, a Knight brace may be used. It consists of two uprights attached to a foot plate; the inner bar is provided with a pad at its upper end for pressure on the internal condyle of the femur. The outer bar reaches to the head of the fibula, and the two are joined by a calf band. When applied the leg is drawn toward the inner upright by means of a lacing, which passes about it within the outer bar. When the lacing is made fast, the outer bar is bent toward the leg, and thus it aids somewhat in supporting it in an improved position. The foot plate may be dispensed with, and the brace may be attached to the shoe, and even the outer bar may be removed, leaving only the upright, which is held in position by the lacing. The apparatus, then, has the appearance of a gaiter, and has the advantage of being inconspicuous, although somewhat less effective than the Knight brace. By this apparatus, combined with vigorous

manipulation, the deformity may be corrected, in young children, in about six months.

If the outward bowing of the knee is marked, another form of apparatus will be necessary, and its effectiveness will be much increased if there is no joint at the knee. The outer bar, shaped to the contour of the leg, is attached above to a pelvic band and below to a foot plate, as is the short brace. An inner straight bar extends to the upper third of the thigh, and is attached to the outer bar by a thigh band. This inner upright is provided with a lacing of leather or canvas, similar to that of the short brace, which surrounds the knee and upper part of the leg, and thus draws it toward an improved position. The outer bar is then bent slightly inward and serves as an additional support. Another form of apparatus consists of a single upright, attached to the shoe and extending upward as high as possible on the inner aspect of the thigh. At its upper extremity a pressure pad is placed and the knee is drawn toward it by means of straps or bandages.

An improved brace of this kind is that in use at the Boston Children's Hospital, in which the upper part of the upright is curved upward and outward just below the groin, to a point on a level with and behind the trochanter, and is attached to its fellow by means of a strap passing across the buttocks so that the feet may be somewhat rotated outward if necessary (Fig. 350).

Operative Treatment. In children more than five years of age, and in cases of the more extreme type at an earlier age, or when the opportunity for mechanical treatment is lacking, immediate correction of the deformity is indicated. Either osteoclasis or osteotomy may be employed, and in some instances manual force is sufficient for the correction of the deformity. There is but little choice between the methods. Osteoclasis is somewhat safer possibly, and is to be preferred for the younger patients.

At the Hospital for Ruptured and Crippled, osteotomy is almost always performed. The small osteotome is inserted on the inner aspect of the tibia at the point of greatest deformity, and when the bone has been sufficiently weakened the fracture is completed by manual force. The fibula may be broken at the same time, or, as is usually the case, it may be simply bent outward. The deformity is overcorrected, and a well-fitting plaster bandage, including the foot and extending to the trochanter, is applied.

The patient usually remains in bed for a few days ; he is then dressed, and if he so desires is allowed to stand. Almost no pain or discomfort follows the operation, and, in fact, in properly selected cases, it is not only free from danger, but it has a very decided advantage over the simple mechanical treatment. If the child is in good condition, and if the deformity is overcorrected at the time of operation, apparatus will not be required in the after-treatment ; but in many instances some form of support is indicated, usually because slight deformity, due to laxity of ligaments or to deformity of the femur, appears when the weight of the body falls upon the legs.

It has been stated that the deformity of bow-leg depends in part upon a distortion of the femur as well as of the tibia. As a rule, the correction of the greater deformity of the tibia will be sufficient, but in more extreme cases a secondary osteotomy above the condyles will be necessary. This may be performed simultaneously with that on the tibia, but it is better to defer it until the effect of the primary operation has been observed.

FIG. 351.

Anterior bow-legs.

Anterior Bow-leg.

Synonym. Anterior curvature of the tibia.

Both bow-legs and knock-knees are often seen in children who present no signs of general rhachitis, but anterior bowing of the legs is almost always combined with general rhachitic distortions of the lower extremity, most often with knock-knees ; these in turn are caused by marked distortion of the femora, which may be bent forward and outward above, and inward at their lower extremities, "corkscrew deformity." In anterior bow-legs the tibiæ are usually flattened from side to side, curved inward or outward and bent forward, the projecting crests presenting sharply beneath the skin.

Symptoms. The effect of the anterior bowing is to throw the weight forward upon the foot ; thus the heels appear abnormally

FIG. 352.

Long anterior curvature of the tibia and flat-foot.

FIG. 353.

Rhachitic anterior bow-legs.

long and prominent, and the patient seems to sink forward at each step (Fig. 353). The knees are usually somewhat flexed, partly as the effect of knock-knee, with which the deformity is usually combined, and the feet are, as a rule, flat. As has been stated, anterior bowing is almost never seen as an independent deformity unless it is a relic of the more general distortion which has been "outgrown."

Treatment. Anterior curvature of the tibia must, as a rule, be treated by operation. After complete fracture of the tibia and fibula, the deformity may be overcome by forcing the bones directly backward. In many instances tenotomy of the tendo Achillis may be required. Cuneiform osteotomy of the tibia permits more perfect correction, but the final result is equally good after simple osteotomy or osteoclasis, and if one succeeds in separating the posterior part of the tibia so that it may conform to the straightened anterior border an actual elongation may be obtained.

General Rhachitic Distortions.

General rhachitic distortions of the lower limbs have been mentioned in connection with knock-knee and with anterior bow-leg. A more extended description is hardly necessary. The deformities are usually of the knock-knee type, and they may be treated on the same general plan that has been outlined in the description of the less extreme distortions.

CHAPTER XVII.

DISEASES OF THE NERVOUS SYSTEM.

From the orthopedic standpoint only those diseases that directly interfere with the function of locomotion or that cause deformity and for which local treatment is of benefit are of special interest. Even this limited class is not often seen in the early or progressive stage, and it is rather with the effects of a disease that is no longer present than with the disease itself that the orthopedic surgeon is especially concerned.

The relative importance of this branch of orthopedic work may be illustrated by the statistics of the Hospital for Ruptured and Crippled. In a period of ten years—1890–1899—42,124 new patients were examined in the out-patient department. Excluding cases that cannot properly be classed as orthopedic, 38,419 remain. In 2441 of these the nervous system was involved (6.3 per cent.); 2028 of the cases were in young children; 413 of the patients were more than fourteen years of age, and of this number 266 were adults.

Anterior poliomyelitis furnished about 75 per cent. of the total number. In 20 per cent. the cerebrum was involved, and 5 per cent. were miscellaneous cases. In 611 cases treated in a period of about two years there were 463 cases of poliomyelitis, 121 cases of paralysis of cerebral origin, 16 cases of obstetrical paralysis, 4 cases of pseudohypertrophic muscular paralysis, and 7 miscellaneous cases. These statistics will explain the selection of diseases of the nervous system for consideration and the order in which they are described.

Acute Anterior Poliomyelitis.

Synonym. Infantile paralysis.

Pathology. Anterior poliomyelitis is an acute inflammatory process of the area of the gray matter of the anterior cornua supplied by the anterior spinal arteries. It involves both the neuroglia and the cells, and it results in degeneration and atrophy of the interstitial tissue and of the ganglion cells.[1]

[1] Starr, Loomis-Thompson. System of Practical Medicine.

In the acute febrile form, comprising about three-fourths of the cases, there is an actual inflammation ; in the other type in which the paralysis is of sudden onset unaccompanied by constitutional evidences of disease, the symptoms may be caused by hemorrhage or by thrombosis.

The minute changes in the cord are characteristic of inflammation, distended bloodvessels, minute hemorrhages, infiltrating leucocytes, and serum. In the early stage the motor cells become cloudy in appearance, later they are swollen and lose their distinct outlines. The degenerative changes affect both the cells and neuroglia ; the affected gray matter shrinks and the nerve fibres atrophy, and the cord becomes distinctly smaller at the seat of the disease. When the motor conductivity of the cells is cut off, the muscles which are supplied by them are paralyzed and waste away. The circulation in the affected parts is impaired, contractions and distortions appear, and growth is retarded.

Etiology. The etiology of the disease is obscure. Exposure to heat, sudden chilling of the body, overfatigue, injury and the like are thought to be predisposing causes. The direct cause of inflammatory disease of the cord is supposed to be some form of infection.

The disease affects the sexes in nearly equal numbers, and those in perfect health as often as those whose resistance is enfeebled. It sometimes occurs in epidemics, and there are instances in which several members of the same family have been affected, but usually the cases are isolated and no adequate cause for the disease can be assigned.

Age. Acute anterior poliomyelitis is essentially a disease of infancy. This is illustrated by the combined statistics of several observers tabulated by Starr.[1]

	1st year.	2d year.	3d year.	4th year.	5th year.	6th year.	7th year.	8th year.	9th year.	10th year.
Seeligmuller	20	25	18	1	1	2	0	0	0	0
Galbraith	17	38	15	4	1	0	0	0	0	0
Sinkler	44	92	55	29	9	2	3	6	0	3
Gowers	21	21	25	9	17	4	2	6	4	0
Starr	16	38	27	9	10	4	2	2	4	3
	118	214	140	52	38	12	7	14	8	6

472, or 77 per cent., before the fourth year.

It is far more common during the warm months than at other seasons, as is illustrated in 452 cases tabulated by Starr.[2]

[1] Loomis-Thompson. System of Practical Medicine. [2] Loc. cit.

January	8	
February	5	
March	20	
April	9	
May	18	
June	49	327, or 72 per cent., during the four months, June to September.
July	97	
August	116	
September	65	
October	42	
November	11	
December	12	
	452	

Distribution of the Paralysis. The lower extremities are far more often paralyzed than the upper. In 416 of 595 cases, tabulated by Starr, the paralysis was limited to the lower extremities, as contrasted with 53 cases in which the upper extremities were alone involved.

	Duchenne.	*Seeligmuller.*	*Sinkler.*	*Starr.*	*Total.*
Both legs	9	14	107	40	170
Right leg	25	15	63	20	123
Left leg	7	27	62	27	123
Right arm	5	9	5	7	26
Left arm	5	4	8	4	21
Both arms	2	1	1	2	6
All extremities	5	2	35	5	47
Arm and leg same side	1	2	26	4	33
Arm and leg opposite sides	2	1	1	4	8
Trunk	1	0	22	3	26
Three extremities	0	0	10	2	12
	62	75	340	118	595

Symptoms. The disease is usually divided into several stages:

1. The stage of onset. This is usually attended by constitutional symptoms, by fever and headache, even by convulsions and delirium; by vomiting and intestinal disturbance, or occasionally by severe pain. In most instances the elevation of the temperature is not extreme, nor is the constitutional disturbance severe, and but for the paralysis the attack would be considered as one of the ordinary illnesses so common in childhood. In some cases, however, the fever is high, and there may be convulsions and prolonged unconsciousness, while in others there may be no premonitory symptoms whatever; the child is apparently well at night, but wakens in the morning paralyzed.

In many instances the weakness or paralysis caused by anterior poliomyelitis of a mild type is not discovered until the child begins to walk, when the awkward gait, or limp, or the distortion of a foot, may make it evident.

In a few hours or a few days after the first symptoms of the disease the paralysis appears; its area may extend slowly after

it is recognized, or its extreme limit may be reached at once. This original paralysis is always greater than that which finally persists. The duration of the first stage may be from a few hours to a week.

2. Then follows a stationary period, lasting from a week to a month; the constitutional symptoms cease, but the paralysis remains.

3. This is succeeded by the stage of partial recovery, lasting from one to six months or longer. The muscles which were paralyzed because of the secondary congestion and exudation about the local myelitis, recover their power in whole or in part, while those muscles supplied from the area in the cord in which the nerve cells have been destroyed, waste away. At this time the contractions and distortions in the paralyzed limbs appear.

4. The chronic stage. This may be considered to last until adult age or until the ultimate damage to the individual, due to the retardation of the growth and unbalancing of the mechanical equilibrium of the body may be summed up.

The sensation of the paralyzed part is not affected except in the extreme cases. The temperature is lower from the first. In many instances the limb is not only cold, but it is congested and blue. These circulatory disturbances are caused primarily by the interference with the vasomotor system, but they are confirmed later by the atrophy of the muscles and by the permanent contraction of the bloodvessels. Thus, in general, the impairment of the circulation corresponds to the degree of the paralysis, but not absolutely so. In certain cases the paralysis may be limited in extent, and yet the limb may be cold and congested, while in others in which the loss of power is much greater the temperature is but slightly lowered and the color remains normal. The same is true of retardation of growth. In most instances the ultimate shortening of the limb corresponds to the degree of the paralysis and consequent loss of function; but occasionally cases are seen in which the growth is markedly retarded, although but few of the muscles are paralyzed.

Diagnosis. It is doubtful if the diagnosis of acute anterior poliomyelitis could be made before the stage of paralysis. But after the paralysis has appeared there should be little difficulty in interpreting the symptoms. It is a disease usually of acute onset, followed by paralysis of certain muscular groups or of entire members. It is a flaccid paralysis, the reflexes are lost, the muscles no longer contract under faradism, and the reaction

of degeneration soon appears; the tissues waste, and the circulation is impaired in the affected parts.

It is usual to consider, first, in differential diagnosis the paralyses of cerebral origin, but this is more for the purpose of calling attention to the essential differences between the two than because they are likely to be confounded by one acquainted with the ordinary characteristics of cerebral and spinal disease.

Paralysis of Cerebral Origin in Childhood. In paralysis of cerebral origin the common form is hemiplegia. It usually follows convulsions, and the intelligence may be impaired. The paralysis is not complete, nor is it limited to groups of muscles; it is rather powerlessness or impairment of function, due to loss of cerebral control. The reflexes are increased and limbs are stiffened, not flaccid. The electrical reactions are not lost or changed in quality. Paralysis of cerebral origin may be also paraplegic or diplegic in its distribution, but in these cases the general characteristics are the same as in the hemiplegic form, except that the intelligence is more markedly affected.

Other Forms of Spinal Paralysis. Transverse myelitis is very uncommon in childhood. In this disease the distribution is equal, the reflexes are at first increased, and sensation as well as motion is lost.

Pott's Paraplegia. In this form of paralysis, also, the distribution is equal, the reflexes are increased, and the signs of the disease of the spine are always present.

Spastic Spinal Paraplegia. In this as in the preceding form the distribution is equal, and the reflexes are exaggerated.

Rheumatism and Joint Disease. In orthopedic practice anterior poliomyelitis is not often seen in the stage of onset unless pain is a prominent symptom, when the disease may be mistaken for rheumatism or for some form of joint disease. Cases of this type are not uncommon. The muscles are sensitive to pressure and the movements of the joints cause discomfort. In certain instances the paralysis may not be apparent on the first examination; when it does appear the diagnosis is, of course, established; therefore, the characteristics of diseases of the joints need not be detailed.

Multiple Neuritis. Multiple neuritis is usually a sequel of infectious diseases, or of metallic poisoning. In the cases due to metallic poisoning with lead or arsenic the paralysis usually begins in the extensors of the hands and feet, and is symmetrical in its distribution. This is true, also, of the localized forms of paralysis

following contagious diseases in which the dorsal flexors of the feet are most often involved. In multiple neuritis there is usually local sensitiveness lasting a longer time than in poliomyelitis; the paralysis is gradual in its onset, and sensation as well as motion is affected.

Diphtheritic Paralysis. Diphtheria is the most common cause of general weakness terminating in paralysis, but in these cases there is usually a history of the preceding disease. The paralysis appears first in the muscles of the throat and neck, and a general and increasing weakness precedes for a considerable interval the complete loss of power.

Weakness. Pseudoparalysis. Weakness caused by rhachitis or so-called pseudoparalysis, due to this or to other affections, is readily distinguished from actual paralysis by pricking the part with a pin, when muscular contraction and movement of the limb will be evident. This test of function is of value in showing the distribution of the paralysis. Loss of power in the tibialis anticus muscle, for example, causes valgus resembling closely the ordinary valgus due to simple weakness. In simple weakness the child withdraws the foot from the point of the pin, and the ability to move it in all directions is very evident; but if the tibialis anticus muscle is paralyzed the foot is always flexed in the abducted attitude. The same test may be made for paralysis of other muscles or muscular groups. It is a test that is easily applied and that is especially useful in the examination of young children.

Obstetrical Paralysis. Paralysis of the arm due to anterior poliomyelitis is infrequent as compared with that of the lower extremity. This form might be mistaken for obstetrical paralysis, but the history of the disability and its distribution should make the diagnosis clear.

Prognosis. Only in very rare instances does the disease of itself cause death. The prognosis as to function depends primarily upon the area of the destructive disease of the cord, secondarily upon the treatment of the weakened or disabled part.

As has been stated, the extent of the primary paralysis is very much greater than that which ultimately remains when the inflammatory changes about the diseased area in the cord have subsided.

The Electrical Test. During the early stages of the disease the degree of final paralysis may be fairly estimated by the electrical reaction. Within a week after the initial paralysis the reaction

to the faradic current in the muscles and nerves in direct connection with the diseased area is lessened and is soon lost. If the faradic irritability is retained in the paralyzed muscles, or if it is merely diminished, recovery may be predicted. The muscles which no longer react to the faradic irritation may still be made to contract by the galvanic current. In normal muscles the reaction is greatest at the closing of the negative pole. In the paralyzed muscles the reaction is slower, it requires greater stimulation, and the contraction is greater at the closing of the positive pole. This is known as the reaction of degeneration. The loss

FIG. 354.

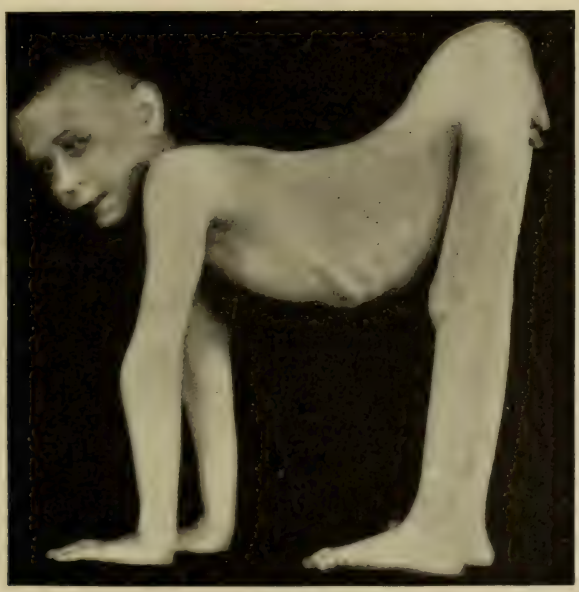

Anterior poliomyelitis. Extreme flexion deformity at the hips, inducing the quadrupedal attitude. (Gibney.)

of faradic reaction and the change in the galvanic reaction indicate that the function of the affected muscle is lost, although certain of its fibres may in time regain their power.

The Effects of Paralysis of Different Muscles and Groups of Muscles upon Function. The interest in anterior poliomyelitis lies in its immediate and ultimate effect upon the functional ability of the individual. These effects may be classified as *deformity of the part directly involved. The general effects of weakness, deformity, and loss of growth upon the body as a whole.*

Causes of Deformity. The deformities of anterior poliomyelitis are caused :

1. By the force of gravity.

2. By the unopposed action of the muscles whose power remains.

3. By functional use.

All these and other less important causes of deformity are, of course, combined in most instances. The relative importance of each factor varies, according to the muscular group that is involved, with the age of the patient, and with the strain to which the part is subjected. The influence of the different factors can be studied best in the foot.

Muscular Action and Gravity. In by far the larger number of cases, one or more of the anterior muscles of the leg, the dorsal flexors of the foot are involved. This is illustrated by the statistics of acquired talipes, tabulated elsewhere, the equinus type of deformity being three times as common as the calcaneus form.

If the anterior muscles are paralyzed in a child before the walking age, the foot drops under the influence of the force of gravity into the attitude of equinus. If this attitude is allowed to persist, the muscles on the posterior aspect of the limb, accommodating themselves to the habitual attitude, in time become structurally shortened. In such cases the equinus deformity is caused by the force of gravity ; it is increased by muscular action and it is fixed by muscular adaptation. That deformity is not caused directly by muscular action is shown by the fact that it may be prevented by stimulating the paralyzed muscles from time to time with galvanism, or even by systematic passive movements to the limit of dorsal flexion. Deformity is thus prevented, not by opposing muscular action, but by stretching the active muscles to their full limits from time to time, and thus preventing muscular adaptation and structural change. In the instance cited gravity and muscular activity are combined in the production of equinus, but in other instances gravity and muscular power may be opposed to one another. If, for example, the calf muscle is paralyzed while the anterior group retains its power, the deformity of calcaneus does not appear until the child begins to use the foot, when the peculiar helplessness calls attention to the disability, if the diagnosis has not been made before. Thus it is that equinus may be present when the child is still in arms, while the opposite deformity develops much more slowly.

Habitual Posture. There are other cases in which every vestige of muscular power is lost and in which the foot dangles. In this class there is no functional activity or tonic shortening of the muscles; consequently deformity is slow in making its appearance; it is not often extreme, and it becomes fixed only by the structural shortening of the inactive tissues, the ligaments, and fasciæ. There are, of course, other causes for habitual posture than the force of gravity and muscular action, such as, for example, the position of convenience in which a weak or disabled part might be placed, but such causes of deformity may be considered as instances of functional use or rather of adaptation to local weakness.

FIG. 355.

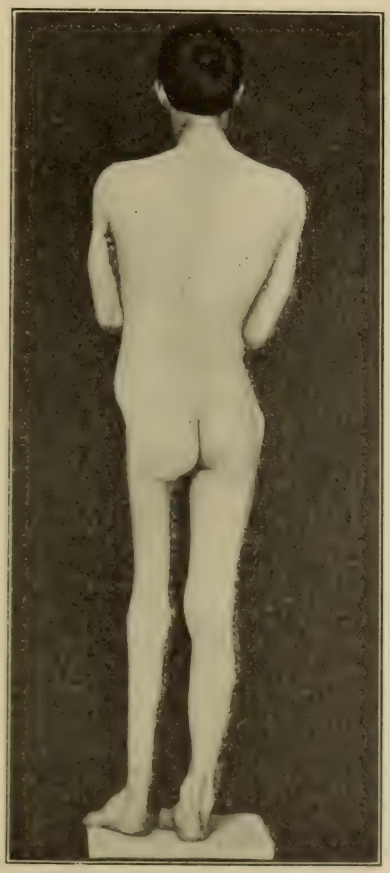

Anterior poliomyelitis. Duration seven years. Showing atrophy and slight lateral curvature of the spine; two and a quarter inches of shortening.

Functional Use as a Cause of Deformity. Thus far the force of gravity, unbalanced muscular power, and the structural changes in the tissues have been considered in the etiology of deformity, as it might develop in infancy. When, however, the patient stands and walks, existing deformities are exaggerated and distortions are developed and confirmed by the weight of the body falling on the unbalanced part, and by the action of the muscles in the attempt to supply the function of those that are paralyzed. Thus it is that the deformity develops far more rapidly when a fair amount of muscular power remains than when it is completely lost. (See Talipes.)

Subluxation. Aside from the distortions due to the causes that have been mentioned, there are others induced simply by weak-

ness ; for example, when laxity of ligaments and the failure of muscular support permits distortion of a limb and subluxation or even displacement at a joint (Figs. 356 and 357). Complete displacement is uncommon, and occurs practically only at the hip. In such cases there is usually flexion deformity of the limb. The femur is suspended by the contracted tissues attached to the anterior superior spine. This unyielding band forms a fulcrum by means of which force applied at the knee may cause sudden displacement of the head of the femur inward or upward and backward.

Deformities of the Upper Extremity. Deformities caused by paralysis of the muscles of the shoulder and upper arm are usually slight because the part is not subjected to the strain of weight bearing, and because the force of gravity is opposed to muscular contraction. In these cases the loss of support and the tension on the capsule allows a considerable separation of the joint surfaces so that the atrophied head of the humerus may be displaced forward or backward ; but there is not often fixed displacement, and consequently persistent distortion due to this cause is unusual.

Paralysis of the muscles of the forearm and of the hand is followed after a time by deformity of the fingers, caused primarily by unopposed muscular action, secondarily by accommodation and atrophy.

Deformities of the Neck. Paralysis of one or more of the muscles of the neck may induce a paralytic torticollis. This is, however, extremely uncommon.

Deformities of the Trunk. Paralysis of the muscles of the trunk may induce distortion and extreme lateral curvature of the spine. This curvature is not usually caused, as might at first appear, by contraction of the active muscles and thus a bending of the trunk with a convexity toward the weaker side. As a rule, the curvature is, as a whole, in the opposite direction. This is explained by the fact that if the paralysis is limited to one side and is extensive enough to cause distortion of the trunk, the muscles of respiration being involved, the chest wall becomes inactive and collapses. In compensation the opposite side of the thorax increases in volume and lung capacity and the weak, atrophied, and sunken side is drawn toward it. The same effect is observed when the arm and the shoulder muscles are paralyzed, the spine bending toward the side that is still active.

Paralysis of the posterior group of muscles, if extreme, may cause a kyphosis. Paralysis of the muscles of the abdomen may induce lordosis, but in this group of cases the lower extremities are usually involved, and the secondary distortions due to posture and to functional use mask the direct effect of the paralysis of the muscles of the trunk. And, again, the overuse of the arm

FIG. 356.

Anterior poliomyelitis, causing genu recurvatum. (See Fig. 357.)

muscles in patients whose lower extremities are paralyzed, and the suspension of the body on crutches in walking, modify the ultimate effects in those cases in which the paralysis is widespread in its area. (See Lateral Curvature.)

Retardation of Growth and Secondary Deformities. The effects of anterior poliomyelitis are not limited to the paralysis and to

atrophy of the muscles, but all the component tissues of the affected limb are involved as well. The bones become relatively atrophied, and their growth is retarded to a degree proportionate to the extent of the paralysis and to the functional disability that has resulted. It has been stated, however, that retardation of growth does not always correspond to the amount of paralysis. In some instances paralysis of a single muscle, which does not seriously compromise the function of the part, is attended with greater shortening of the limb than in other cases in which the paralysis is far more extensive. Thus it may be inferred that certain cells in the spinal cord are especially concerned in the growth and nutrition of the bones, and that interference with the function of these cells may not correspond absolutely to the extent of the destructive process. However this may be, it is certain

FIG. 357.

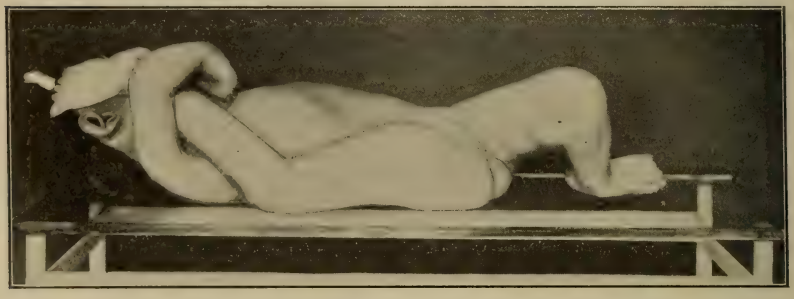

Anterior poliomyelitis. Paralysis of muscles at the hip allows subluxation of the femur. The same patient as in Fig. 356.

that atrophy and retardation of growth are much greater when a limb is not used than when by the aid of apparatus it has been enabled to carry out, in part at least, its proper function. It is evident, also, that retardation of growth will be more marked during the period of rapid development; thus, the younger the patient the greater should be the ultimate inequality of the limbs.

RETARDATION OF GROWTH. The ultimate shortening varies from one to three inches. In the slighter degrees of paralysis affecting the leg, the shortening may be less than an inch, but when the thigh muscles are paralyzed, also, it may be much more (Fig. 355). This inequality is usually very evident in the size of the two feet.

When both limbs are paralyzed so that locomotion is very seriously interfered with, the retardation of growth is especially

marked, and the contrast between the trunk of the patient and the attenuated lower extremities is very striking.

SECONDARY DEFORMITIES must include, besides those already mentioned, the compensatory distortions of the trunk that may follow paralysis of the limbs. Thus a short leg might cause a lateral curvature of the spine, or great flexion contraction of the thigh might induce abnormal lordosis. As a matter of fact, the final effects of disabilities of this character are very complex, and are influenced by many factors of which only a general indication is practicable.

Treatment. The treatment of the acute stage of anterior poliomyelitis is symptomatic. If the diagnosis has been made, such measures as would tend to relieve the congestion about the diseased area should be employed ; cathartics, sedatives, and counter-irritation of the spine, for example. When the acute symptoms have subsided local treatment to maintain as far as possible the nutrition of the muscles, to prevent deformity, and to relieve the strain upon the weakened tissues is indicated. The nutrition of the parts may be improved by massage, by muscle-beating, by the direct application of heat to the cold extremities, and by the use of galvanism, as long as it will induce contraction of the paralyzed muscles.

Deformity may be prevented by moving each joint to the limit of the range of motion in all directions several times a day, and by supporting the limb with appropriate apparatus. Deformity in those parts in which it is favored by muscular action and by the force of gravity appears much more rapidly than is generally supposed. The indications of equinus, for example, are apparent within a few weeks after paralysis of the anterior muscles of the leg. The first indication of such deformity in this class is the discomfort caused by passively moving the foot toward dorsal flexion. This limitation of the range of motion rapidly increases, and as it increases it is confirmed by muscular adaptation and finally by structural shortening.

The Principles of Mechanical Treatment. The object of a brace is to prevent the deformity due to weakness and to utilize the muscular power that remains, so that the disabled member may carry out its function. As each muscle has an essential function the paralysis of any one must be followed by a certain disability and usually by deformity. Muscles vary in importance as they do in strength, and the ultimate disability caused by paralysis may be predicted very accurately by one who is familiar with this function.

Paralysis of the Anterior Muscles of the Leg. Paralysis of the anterior leg group causes the so-called steppage gait; the toes drag on the floor when the limb is swung forward, and this necessitates an awkward lifting of the knee. The result of such paralysis is equinus. Slight equinus has a tendency to throw the knee backward, "recurvatum," in order that the patient may place the entire sole on the ground. More marked equinus obliges the patient to bear the weight entirely on the front of the foot, and causes flexion both at the knee and hip. If but one of the muscles of the anterior group is paralyzed the

Fig. 358.

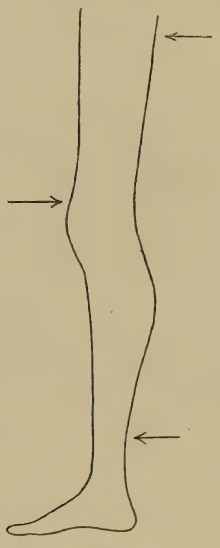

Fig. 359.

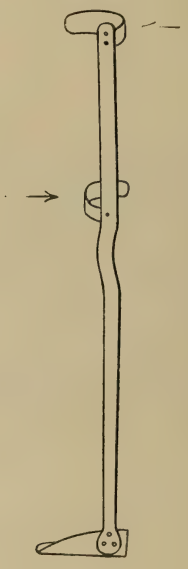

The Judson brace for paralysis of the quadriceps extensor muscle in connection with deformity of the foot.

tendency to equinus is in so far lessened, but there is an inclination to lateral distortion. Paralysis of the anterior muscles causes an awkward gait and often deformity, but the propelling force of the limb remains. The indication for support is simple, to prevent the foot from dropping to the extent that incommodes the patient, or practically to hold the foot at a right angle with the leg.

Paralysis of the Posterior Muscles of the Leg. If, on the other hand, the calf muscles are paralyzed the resistance of the foot is lost and it is simply dorsiflexed when weight is

thrown upon it. Thus the brace must be arranged to prevent dorsal flexion, and it must be strong enough to support the strain which is transmitted from the foot plate of the brace to the front of the leg. The various weaknesses and deformities of the foot

FIG. 360.



A brace for complete paralysis of the limb, showing a form of lock at the knee and a limited joint at the ankle.

FIG. 361.

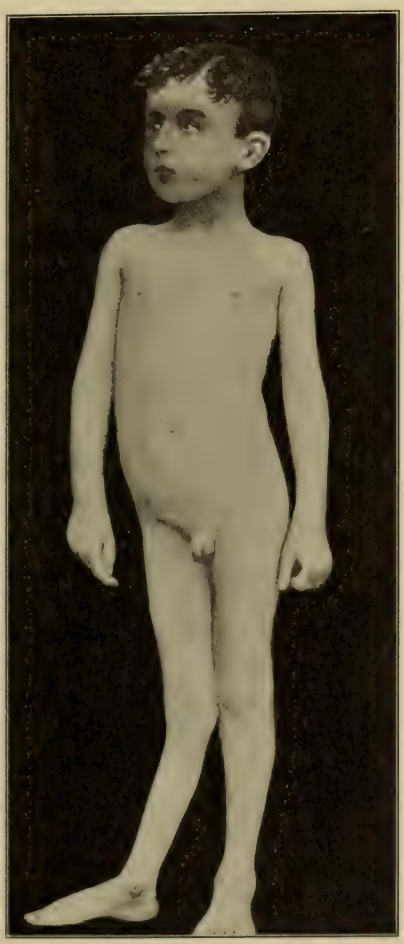

Anterior poliomyelitis. Paralysis of the anterior and posterior muscles. Recurvation of the right knee.

and the means of treating them are described at length elsewhere. (See Talipes.)

Paralysis of the calf muscles not only affects the foot, but it weakens the knee as well, and genu recurvatum is often a

secondary effect. In many instances, therefore, it will be necessary to support the knee as well as the ankle during the earlier stages of the treatment.

Paralysis of the Thigh Muscles. Paralysis of the quadriceps extensor muscle causes primarily a peculiar gait. The patient, unable to extend the leg upon the thigh, throws or swings it forward, then locks the joint by direct contact of the bones and by the resistance of the posterior tissues, by inclining the body somewhat forward as the weight falls upon it. In this manner, again, the knee may be overextended. Or if extension is checked by shortening of the tissues, induced possibly by habitual assumption of the sitting posture, the patient being unable to lock the joint effectively by complete contact of the bones, often trips and falls because of the insecurity of the support. When in the normal subject the weight is borne upon one limb in the attitude of rest, in which the muscles are thrown out of action, the knee-joint is locked, but the insecurity of this support is illustrated by the school-boy's trick of striking the back of the knee with the hand, when, the muscles being taken unawares, the person falls to the ground. This insecurity is constant when the extensor of the leg is paralyzed.

Paralysis limited to the quadriceps extensor muscle is, however, very unusual. In almost all cases some of the leg muscles are involved also, and the brace usually must serve to support the foot as well as the knee. In its ordinary form such a brace is constructed of two lateral upright bars, reaching nearly to the pubes on the inner and to the trochanter on the outer side, joined to one another by bands passing beneath the thigh and the calf, and attached to a light steel foot plate. If the dorsal flexors of the foot are paralyzed the ankle-joint is arranged to allow dorsal flexion, but to prevent extension beyond the right angle. If the calf muscle is paralyzed a reverse catch is used, or the uprights are attached directly to the foot plate without a joint (Fig. 359); or the so-called limit joint, allowing only a few degrees of motion in either direction, is used (Fig. 360). (See Talipes.) In the treatment of young children the joint is also omitted at the knee, the limb being firmly held in the extended position during the active period (Figs. 359 and 362). This is of advantage because the joint is the weakest part of the brace and it soon becomes loose under the severe strain to which it is subjected. In older subjects a joint is arranged with a spring catch, the brace being held in the straight position when the patient is walking about, but

allowing flexion when the sitting posture is assumed. This is, of course, a great convenience (Fig. 360). In fitting the brace the lateral bars should be adjusted to support the limb without uncomfortable pressure, and the joints should be exactly opposite the normal centres of motion. The thigh and leg bands should be properly fitted to the contour of the soft parts so that half the limb is contained within them. These are smoothly covered with leather, and the limb is held in position by leather bands

FIG. 362.



Brace for complete paralysis of the anterior muscles of the limb; before and after covering.

that complete the circumference. Other bands are applied across the front or back of the limb, either to support it or to fix it firmly in place. In the ordinary brace without the joint at the knee there are three anterior bands, one across the front of the thigh, another across the leg, and the third, a wide knee-cap, supports the greater part of the strain (Fig. 362).

PARALYSIS OF THE MUSCLES OF THE HIP. The effect of paralysis of the muscles about the hip is difficult to describe, as

in these cases many other muscles are usually involved. If all the muscles are paralyzed the thigh dangles. This is, however, very unusual, for the tensor vaginæ femoris almost always retains its power and is one of the causes of flexion deformity which is so often present in cases of this character.

Paralysis of the iliopsoas muscle makes it impossible for the patient to flex the thigh directly. If the adductors are paralyzed he must lift the thigh with the hand when adduction is desired. Paralysis of the glutei is made evident by the atrophy and by the weakness of the extending power of the limb.

The distribution of the paralysis of the muscles of the hip may be ascertained by placing the patient in the recumbent posture; the leg is then lifted from the table, and by placing the thigh in different positions the ability of the patient to move it may be tested, in older subjects by voluntary effort, in younger ones by pricking the part slightly with a pin.

General weakness of the muscles of the hip causes an awkward, insecure gait, accompanied usually by outward rotation of the limb, and, as has been stated, there is almost always accompanying paralysis of other muscles of the extremity. In such cases a pelvic band must be attached to the leg brace. The pelvic band is made of sheet steel of about 18 gauge, two inches wide, fitted to the pelvis, which it encircles midway between the crest of the ilium and the trochanter. At this point it is attached to the brace by a free joint (Fig. 363). When the band is accurately adjusted and strapped firmly about the pelvis, the necessary security is assured and the attitude of the limb in walking can be regulated. If greater support is desired a perineal band may be applied as described in the chapter on disease of the hip-joint.

If both limbs are paralyzed double braces must be used. If the muscles of the lower part of the back are much weakened the pelvic band may be replaced by a corset or some form of back brace. Fortunately these cases are uncommon.

Paralytic Scoliosis. Paralytic scoliosis requires the support of corsets or braces as a rule, such as are used in the treatment of other forms of distortion of the back. (See Lateral Curvature.)

Paralysis of the Arm. Paralysis of the arm is uncommon, and treatment is rarely demanded.

In some instances a shoulder support may be of service or a brace to hold the arm at a right angle if the biceps is paralyzed. If the muscles of the scapula retain their power the operation of

arthrodesis might be of service in fixing the dangling joint, and the same operation might be useful at the elbow. It is, of course, evident that one of the lower extremities, although hopelessly weakened, may be braced so that it may serve as a simple prop to bear weight, but as the function of the arm is quite different, extensive paralysis of its muscles makes it practically useless to the individual.

Operative Treatment. The Reduction of Deformity. In a large proportion of the cases of anterior poliomyelitis the patients are not seen by the orthopedic surgeon until months or years have elapsed since the original attack. They are then brought for treatment because of secondary deformity often of an extreme degree. At least half of the cases of talipes are due to this cause, and with the deformity of the foot are often combined other distortions varying in degree with the extent of the paralysis. Many of the patients hobble about on a distorted foot, others use crutches, and in a smaller number the only method of locomotion is creeping on all-fours. In the cases in which the patient has habitually used crutches allowing the paralyzed limb to "dangle," there is usually marked flexion at the three joints. The thigh is flexed upon the pelvis, the leg is flexed upon the thigh, and the foot hangs downward and inward (plantar flexed) in an attitude of equino varus.

However extreme the paralysis of a lower extremity may be, the limb may be made useful as a prop when properly braced; this prop will enable the patient to dispense with the use of crutches and thus free the arms from unnecessary work. Even if both limbs are paralyzed they may at least serve as supports to enable the patient to stand erect and to propel himself with the aid of crutches. If a limb has been disused for a long time, the atrophy is usually extreme, the bones are fragile, and the growth has been greatly retarded as compared with those limbs in which deformity has been prevented and in which the weight of the body has been sustained in functional use. In this class of cases the first step must be the reduction of deformity; the foot must be brought to a right angle with the leg, the limb must be brought to the straight line, and the flexion at the hip must be overcome in order to enable the patient to stand erect without bending the spine forward in compensatory lordosis.

Acquired deformity of the foot is far less resistant than is the congenital form, and by tenotomy and the proper application of force it may be readily straightened, usually at one sitting.

The flexion contraction at the knee may be overcome also by careful and persistent manual stretching combined, if necessary, with division of the contracted tissues on the posterior aspect of the joint. (See page 412.)

The flexion deformity at the hip is usually fixed by the contraction of the tissues about the anterior superior spine of the ilium, including the tensor vaginæ femoris muscle, which is rarely paralyzed. These tissues, together with the fascia, may be divided subcutaneously, or by open incision, if necessary ; after which the deformity may be reduced by gradual forcible extension of the thigh while the pelvis is fixed by flexing the other limb upon the body. When the contraction deformities are overcome lateral deviation at the knee is corrected, if it be present, in the same manner, and the bony points having been carefully protected by padding a long spica plaster bandage is applied to fix the limb.

The lesser degrees of deformity may be reduced by other means, for example, by repeated applications of plaster bandages under slight corrective force, or by manipulation, or by braces and bandaging.

Paralytic knock-knee may be corrected by the Thomas knock-knee brace, and this brace when attached to a pelvic band is a useful form of support in the routine treatment of paralysis of the leg (Fig. 339).

The Thomas caliper knee brace is another cheap and useful support. It is of especial service when there is flexion or lateral deformity of the limb (Fig. 259).

When distortion has been overcome and when functional use has been made possible by proper support, the development of active muscles which have been thrown out of use by the distortions, and of those in which part of the muscular substance has been retained, is surprising. In many of these cases the distortions which developed during the temporary paralysis have alone prevented recovery, and this latent power may be revived even after years of disuse. Thus in many instances prognosis is impossible until the deformities have been corrected and until the limb, properly supported, has been enabled to resume its function.

Tendon Transplantation. This operation is best adapted to the treatment of distortions of the foot caused by paralysis of the muscles of the leg, and the procedure is described at length in that section.

Paralysis of the muscles of the arm and hand is unusual. The operation of tendon shortening combined with transplantation of

the tendons of one or more active muscles may be of service in the treatment of wrist-drop, and opportunities may suggest themselves in other situations whenever it is possible to utilize the muscular power to better advantage.

Arthrodesis. As has been stated of tendon transplantation, arthrodesis is of greatest service at the ankle-joint, where it may

Fig. 363.



Leg brace, with pelvic band. Double uprights. No joint at knee. For paralysis of the anterior thigh and leg muscles.

serve to fix the foot at a right angle with the leg. (See Talipes.) In exceptional cases arthrodesis or excision at the knee may be advisable in the older patients, but in young subjects the strain upon the long, weak lever formed by the two bones will almost always induce deformity. Arthrodesis at the hip might be of

service in complete paralysis of the pelvic muscles, at the shoulder when the muscles attached to the scapula are active, and in exceptional cases at the elbow and wrist to assure an improved position. The operation is described elsewhere.

Osteotomy. In rare instances, particularly in the extreme deformities in the adult, osteotomy of the femur at the hip or knee may be necessary in order to overcome resistant distortion.

Recapitulation of Treatment. This consists in support and electrical stimulation of the muscles during the period of recovery, together with a suitable brace to hold the limb in the best possible position for usefulness when the final extent of the paralysis has become evident. With the support any treatment that will improve the nutrition of the part is of service; massage and muscle beating are of especial value. The limb in which the circulation is deficient should be protected from the cold by proper covering, and its nutrition may be improved by the direct application of heat, the hot-air or hot-water bath both being useful. Above all else, functional use, which is made possible by apparatus, is of the first importance in preserving and stimulating whatever muscular power remains; and special gymnastic exercises to this end may be employed if practicable. The prevention of deformity during the growing period is of great importance. Every morning and night the joints of the paralyzed part should be passively moved to the normal limits in all directions in order to prevent the gradual limitation of the range of motion which is the first indication of the deformity. Lateral deviation of the limb or foot may be prevented by passive manipulation and by careful adjustment or modification of the support. Braces should be strong, and as simple as may be in construction. Elastic bands and springs, applied with the design of replacing paralyzed muscles, are of little practical use, since they are ineffective in action, difficult to adjust, and easily disarranged. The parent, when treatment is begun, must be impressed with the fact that a brace must be strong enough to serve its purpose even though its weight be objectionable; that its period of usefulness is limited, and that it must be replaced when it is outgrown; that the breaking of a brace from time to time is unavoidable, and that such accidents, in so far as they are evidences of the functional activity of the patient, are favorable indications.

Careful supervision of the patient, even though the weakness is not great, will be necessary during the period of growth. The

contrast between the development and symmetry, the muscular power and practical utility of a limb that has received this care and supervision, and one that has been neglected, is sufficiently striking to impress anyone with the necessity for this tedious and apparently never-ending treatment.

Thus, in this as in other chronic diseases and disabilities, the character and the duration of the treatment, its object, and the final results that one may expect to attain by it should be explained to the parents when the care of the patient is undertaken.

CHAPTER XVIII.

DISEASES OF THE NERVOUS SYSTEM (Continued).

Cerebral Paralysis of Childhood—Spastic Paralysis.

Cerebral paralysis or palsy is in orthopedic practice second only in frequency and importance to anterior poliomyelitis. It is, however, entirely different in its distribution and in its effects. It is a form of disability that is characterized by motor weakness, by stiffness and loss of control, rather than by paralysis. It affects entire members and it results in atrophy, contractions, and deformity.

It may involve half the body, hemiplegia.

It may be limited to the lower extremities, paraplegia.

It may involve both the upper and lower extremities, diplegia.

In rare instances but one extremity is affected, monoplegia.

Distribution. In 451 cases of cerebral paralysis analyzed by Peterson,[1] 332 were of the hemiplegic type, 73 were of the diplegic type, and 46 were of the paraplegic type. In 121 cases observed at the Hospital for Ruptured and Crippled, 63 were paraplegic or diplegic and 58 were hemiplegic. The hemiplegic form of paralysis is usually acquired ; the diplegic and paraplegic forms are usually congenital.

Etiology and Pathology. Cerebral paralysis may be divided into two classes—the congenital and the acquired.

Congenital Paralysis. Paralysis of intra-uterine origin may be the result of maldevelopment or injury or a secondary effect of intercurrent disease of the mother. Paralysis caused by injury at birth is usually the result of rupture of bloodvessels of the meninges due to prolonged labor or to the pressure of instruments.

Acquired Paralysis. Acquired paralysis may be due to hemorrhage, embolism, thrombosis, or to disease. Sachs[2] presents the following classification of causes and effects :

[1] American Text-book of Diseases of Children.
[2] Sachs. The Nervous Diseases of Children.

PARALYSIS OF INTRA-UTERINE ORIGIN.

Large cerebral defects—true porencephaly.

Hemorrhages of intra-uterine origin—softening.

Agenesis corticalis.

PARALYSIS OCCURRING DURING LABOR.

Meningeal hemorrhage—very seldom intracerebral. Resulting conditions: meningo-encephalitis chronica; sclerosis; cysts; atrophies; porencephalies.

FIG. 364.

Congenital cerebral diplegia. Idiocy.

PARALYSIS ACQUIRED AFTER BIRTH.

1. Meningeal hemorrhage—very seldom intracerebral. Embolism: thrombosis in marantic conditions, and occasionally from syphilitic endoarteritis. Results of these vascular lesions: cysts; softening; atrophy; sclerosis, diffuse and lobar.
2. Chronic meningitis.
3. Hydrocephalus.
4. Primary encephalitis (Strümpell).

General Symptoms. **Motor.** The effect of the lesion of the brain and of the secondary changes in the cord is to impair the voluntary control of the limbs supplied from the affected area, and at the same time the inhibition of the higher centres is impaired or lost. Thus, together with the loss of power, there is usually a corresponding exaggeration of the reflexes causing a

FIG. 365.

Spastic paraplegia.

spastic rigidity of the limbs. This induces distortion, which finally becomes fixed by the adaptive changes in the tissues. As the centres for the nutrition of the paralyzed parts are not involved, the muscles do not waste and the circulation is but little affected. Thus the atrophy as compared with paralysis of spinal origin (anterior poliomyelitis) is comparatively slight, and this, together with the loss of growth, is due rather to the general

effects of the disease and to the loss of function than to the direct influence of the nervous lesion.

Mental. In this form of paralysis the lesion is of the brain, and the direct injury of its structure and the interference with its development is likely to cause mental impairment. This mental impairment is usually more marked in the paraplegic or diplegic than in the hemiplegic form, because in the latter but half the brain is involved, and because the injury or disease occurs at a later period of its development. So, also, the mental development is usually less interfered with in the paraplegic than in the diplegic type. For, although both hemispheres were originally in all probability involved, yet the recovery of power in the arms shows that the injury was less extensive than when the weakness persists in one or both of the upper extremities.

It is estimated that in 50 per cent. of the hemiplegic cases the patients are feeble-minded, although comparatively few (13 per cent.) are idiotic. In the paraplegic and diplegic forms of paralysis about 70 per cent. of the patients are feeble-minded, and from 40 to 50 per cent. are idiotic. (Sachs.)

Epilepsy is an accompaniment of about 45 per cent. of all forms of cerebral paralysis, and in 20 per cent. of the cases athetoid or associated movements in the paralyzed parts persist. (Peterson.)

Congenital Weakness and Paralysis.

The congenital form of cerebral paralysis is often seen in orthopedic clinics, because the effect of the lesion of the brain in retarding both the mental and physical development first attracts the attention of the mother. Thus, infants are brought for examination because they are unable to sit or stand or to talk at the usual time. In certain instances the cause of the physical weakness is simple idiocy. In such cases the vacant expression, the inability of the child to recognize even its mother, the extreme weakness, and the absence of the spastic rigidity of the limbs will make the diagnosis clear.

In another class of cases the weakness appears to be caused simply by retarded cerebral development. The patient is apathetic and weak. In these cases, also, there is no evidence of paralysis, and the evident intelligence of the patient distinguishes this type from the idiotic class.

In the characteristic form of cerebral paralysis as seen in early life the child may be idiotic, or simply apathetic, or apparently

normal in intelligence, but it is always weak, and in the sitting posture the spine is usually bent backward into a long, more or less rigid curve. It makes no effort to stand, and when placed in the erect posture it will be noticed that the thighs are usually pressed closely against one another and that the feet are extended. The limbs are "stiff." There is a peculiar resistance to flexion at the extended joints, which slowly gives way under steady pressure. This is the characteristic spastic rigidity (Fig. 364).

FIG. 366.

Acquired cerebral hemiplegia.

Deformities. These children usually begin to stand and to walk at about the third year or later with an awkward, shuffling gait; the limbs are usually flexed, adducted, and rotated inward; the knees touch one another or the legs may be crossed, while the feet turn inward in a persistent attitude of slight equinovarus. The equilibrium is very easily disturbed, partly because of the deformities and partly because of direct lesion of the brain. In the majority of the congenital cases the paralysis is paraplegic in its distribution; perhaps 15 per cent. are of the hemiplegic variety, and in a somewhat larger number the paralysis is diplegic in distribution (Fig. 364).

It has been stated that the typical deformity of the foot was equinovarus, but in older subjects who have walked about in the attitude of flexion at the hips and knees there may be an accommodative distortion of the foot toward valgus, or even to an extreme degree of calcaneovalgus.

As has been stated, in a certain number of cases the intelligence is not impaired, but more often the patients are distinctly feeble-minded. They are very nervous, easily startled, emotional, and are often unable to speak distinctly, yet it is interesting to

note that this peculiar emotional excitability often passes for an extreme degree of brightness of intellect and quickness of perception. In fact, parents often remain unconvinced that the child is lacking in mental power until it reaches an age when comparison with other children makes this conclusion inevitable.

Acquired Paralysis.

As in adult life, the common form of acquired cerebral paralysis in childhood is hemiplegia. About two-thirds of all the cases occur in the first three years of life; and in about 20 per cent. of these the affection of the brain is a complication of infectious disease. The onset is usually sudden, and is accompanied in the majority of cases by fever, convulsions, and loss of consciousness. When the child regains consciousness the paralysis of the arm and leg is at once evident, and in about 20 per cent. of the cases the face is paralyzed also.

Deformities. At first the paralysis is a simple powerlessness, but soon the exaggeration of the reflexes is evident. As has been stated, there is a loss of voluntary power and an increase of the reflexes or "stiffness" of the paralyzed members. They are no longer competent to assume the more difficult attitudes and functions, and these are replaced by those that are simpler; thus flexion becomes habitual.

In typical hemiplegia the foot is plantar flexed and adducted. The leg is flexed on the thigh and the thigh on the trunk, and with the flexion adduction is usually combined. The arm is held against the thorax, the forearm is flexed upon the arm in an attitude midway between pronation and supination. The hand is flexed upon the arm and inclined toward the ulnar side and the fingers are clasped over the adducted thumb (Fig. 366).

Disability. The loss of power is not absolute; in most instances the patient is able to walk with an exaggerated limp, dragging the stiffened and distorted limb, which serves as a prop rather than as an active support. So, also, the control of the upper extremities is in part retained; the patient is able to abduct the arm, to partly extend the forearm, sometimes to extend the fingers and to abduct the thumb, but the power to dorsiflex the hand and at the same time to extend the fingers is not usually retained in a case of this character.

Loss of Growth. The growth of the patient as a whole is usually retarded to a certain extent by the lesion of the brain.

There is in addition a certain degree of inequality in the growth of the two halves of the body. This inequality is more marked in the upper than in the lower extremity. Shortening to the extent of an inch in the lower extremity is not usually exceeded, but the growth of the arm and hand may be very markedly checked. This disproportionate loss of growth in the upper over the lower extremity, although it may be explained in part by the situation of the lesion of the brain, depends more directly upon the interference with function. The lower extremity is rarely disabled to an extent that prevents its use in locomotion, consequently its nutrition is preserved; whereas the same degree of paralysis of the arm utterly unfits it for its more difficult functions and it becomes a useless appendage. With the disuse of function there is a corresponding diminution of nutrition and a consequent atrophy and loss of growth.

Extreme deformity and disability, as in the type described, is rather unusual. In many instances there is almost complete recovery from the paralysis, only an awkwardness and slowness of movement, combined with an increase of reflexes and a slight hemiatrophy of the body exists. In some cases a slight degree of equinus is the only deformity ; in others weakness of the arm may persist, although complete control of the lower extremities has been regained.

The final effect of the paralysis is almost always more marked in the upper than in the lower extremity ; thus, when contractions and deformities of the lower extremity are present the arm and hand are often practically disabled.

Treatment. 1. **Hemiplegia.** The treatment from the orthopedic standpoint consists in stimulating the nutrition of the paralyzed parts, in preventing deformity, and in improving the functional ability. The results of treatment are, of course, very greatly influenced by the mental condition of the patient. If the mental power is not impaired one may count upon the efforts of the patient to aid the surgeon ; whereas, if the patient is idiotic there is but little encouragement for active treatment. If the patient is seen before the secondary contractions have appeared, deformity may be prevented in great degree by regular massage and by passive movements in the directions opposed to the habitual positions. If the spastic contraction is slight the control of the movements of the leg may be made easier by the use of a light jointed leg brace attached to a pelvic band. By this means the movements are controlled and the excessive expenditure of

nervous energy necessary to guide the limb may be lessened. This support should be supplemented by massage and exercise, and in the milder type of paralysis the control of the limb may be greatly improved.

In many instances the patients are not seen until late childhood, when the deformities have become fixed. The foot is usually turned inward and downward (equinovarus); there is flexion at the knee and often flexion and adduction at the hip, the resistance of the contractions being dependent upon the duration of the deformity. In such cases the distortions must be corrected by force and by division of more resistant tissues, including often the tendo Achillis, the plantar fascia, and in many instances the hamstrings and the adductors of the hip. The limb is then fixed in a plaster-of-Paris bandage for a sufficient time to overcome the more direct tendency to deformity. When the bandage is removed a brace is of service in guiding the limb, and regular massage and forcible passive movements together with proper exercises should be employed whenever practicable. In this class of cases the deformities may be overcome in most instances, but there is a tendency toward flexion at the knee, and stiffness and awkwardness in movement usually persist.

In many of the milder hemiplegic cases the only deformity is of the foot. This should be treated by division of the tendo-Achillis and by support for a time until the deformity habit has disappeared.

If the arm is but slightly affected proper exercises will greatly improve its ability. In the more extreme cases, in which the fingers are clasped over one another, treatment is of little avail. In another class, in which the patient has the power of extending the fingers only when the wrist is flexed, the power of dorsiflexion may be restored or improved by transplanting the flexors of the carpus on the radial and ulnar border to the extensors, which have been overlapped and shortened to the proper extent. These tendons may be exposed by lateral incisions, and may be attached to the dorsal tendons by passing them about the border of the radius and of the ulna, or the tendons may be elongated by silk, which may be inserted directly to the median surface of the tarsus or metatarsus. In such instances one hopes that fibrous tissue will be deposited about the artificial tendon and finally replace it. In other instances the two tendons have been pushed through an opening in the interosseous membrane to the

dorsal surface of the wrist, and there united with the tendons of the extensors of the fingers. The results of these operations as far as improving the attitude is concerned are usually good. The transplantation of other tendons may be of service, but the operation is limited in usefulness for the reasons stated.[1] Athetoid movements of the hand and arm may be relieved somewhat by prolonged fixation in a plaster bandage, or by arthrodesis at the wrist-joint.

FIG. 367.

Cerebral paraplegia, second stage in treatment, the long replaced by the short spica. This patient, at the age of eight years, was unable to stand without assistance. The spastic contractions and deformities were overcome by tenotomies and by force, and a double long spica bandage was applied. This was worn for eight months. It was then replaced by the bandage shown in the illustration. Six months later this was removed. There is at present no deformity, and the child walks fairly well.

2. **Paraplegia.** The treatment of spastic paraplegia is much more difficult than that of hemiplegia, because the disability is very much greater, and because the mental impairment is usually more marked.

[1] Townsend. Transactions American Orthopedic Association, 1900, vol. xiii.

In general, the treatment in infancy is by massage and by manipulation. When the child shows a desire to walk an attempt should be made to relieve the spastic contractions. In certain instances complete correction of all deformities, followed by prolonged fixation of each joint in the overcorrected attitude, may be of service (Fig. 367). This may be combined with multiple tenotomies if the contractions are more resistant. The advantage of tenotomy, aside from the simple correction of deformity, is that by elongation of the tendon the response to the exaggerated motor impulses is lessened and an opportunity for more effective control is afforded. The beneficial effect of complete division of contracted parts in checking spasmodic contractions is very marked in older patients. Transplantation of tendons from the flexor to the extensor aspect of the limb to overcome persistent flexion of the knee may be of service in certain cases. According to the method of Lange, the tendons are exposed by incisions on the lower lateral aspects of the knee. They are then carried forward beneath the skin and are attached to the insertion of the quadriceps extensor tendon, which is exposed by a median incision. The actual insertion is usually made by a strong cord of silk prolonged from the extremity of each tendon. This is necessary to give it sufficient length. The good effect of the operation is to be ascribed in all probability in far greater degree to the removal of the deforming force than to the extending action of the flexor muscles. Except in the very mild cases of paraplegia, and as an aid in retaining the limbs in the improved position after operative treatment, braces are of little value. The trunk is not, as a rule, deformed except in the diplegic cases in which the mental impairment is great. Manipulation, massage, and posture are of some service in correcting and preventing this distortion.

Prognosis. It is stated by Peterson[1] that the patients in whom the paralysis is paraplegic or diplegic in distribution usually die before the twentieth year, and that but few of those in whom it is hemiplegic reach the age of forty. This prognosis applies, it may be assumed, rather to the extreme cases accompanied by mental impairment than to the milder forms. In almost all cases the patient, even if idiotic, is finally able to stand and to walk. As a rule, there is for a time a gradual improvement in motor power and in mental control as well. It

[1] Transactions American Orthopedic Association, 1900, vol. xiii.

is evident that in a class in which mental enfeeblement is so common and in which epilepsy is present in so large a proportion of cases, moral and mental training is of great importance.

Orthopedic treatment, although it has no direct action upon the lesion in the brain, certainly has an indirect effect upon the mental as well as upon the physical condition of the patient. When deformity has been corrected and when contractions have been overcome, functional use requires less mental effort; and motor control may be still further improved by drilling the patient constantly in simple movements. Such exercises improve the motor communications and the ability of the paralyzed part as well.

Spastic Spinal Paralysis.

Occasionally one encounters cases of spastic paraplegia in which there is no cerebral impairment. In such cases the lesion appears to be confined to the spinal cord and to be a degeneration of the distal portions of the pyramidal tracts due to imperfect development.[1] The treatment is similar to the ordinary form of spastic paraplegia, but the prognosis is far more encouraging.

Progressive Muscular Atrophy.

Progressive muscular atrophy, as the term implies, is a progressive wasting of the muscles, with corresponding loss of power, terminating finally in paralysis and deformity. Its cause is apparently some developmental defect.

Under this title are included two varieties of disease:

1. The myelopathic form, in which the primary disease is apparently of the spinal cord.

2. The myopathic form, in which the disease appears to be primarily of the nerve terminals and the muscular fibres.

The second variety is usually designated as muscular dystrophy to distinguish it from the spinal form.

Myelopathic Paralysis or Atrophy. The myelopathic form of muscular atrophy, the Aran-Duchenne type, usually begins in the small muscles of the hands and spreads from the periphery to the trunk. Fibrillary twitching of the affected and unaffected muscles is fairly constant, and the reaction of degeneration may be present. The disease is practically limited to adults, and from the orthopedic standpoint it is of little interest. In another form, the Charcot-Marie-Tooth type, usually classed with the

[1] Spiller. Philadelphia Medical Journal, June 21, 1902.

muscular atrophies, the paralysis may begin in the muscles of the legs, causing deformity of the equinus or equinovarus variety. The lesion of the cord in muscular atrophy is of the anterior cornua, and resembles closely that of the subacute form of anterior poliomyelitis.

FIG. 368.

Progressive muscular dystrophy, showing the enlargement of the calves and the atrophy of the shoulder muscles.

FIG. 369.

Progressive muscular dystrophy, facio-scapulo-humeral type. Extreme lordosis and flexion contractions at the hips.

Myopathic Paralysis or Muscular Dystrophy. The myopathic form of muscular atrophy may be preceded by apparent hypertrophy (pseudohypertrophic muscular paralysis), it may be primarily atrophic, or the two forms may be combined.

It differs from the myelopathic form in several particulars. It is a disease of childhood. It is often hereditary and its distribution is different.

The affection is divided according to the distribution into two main varieties:

1. The facio-scapulo-humeral type (Landouzy-Dejerine), in which the muscles of the face and shoulder girdle are primarily affected (Fig. 369).

2. The juvenile form of Erb, in which the muscles of the back and of the upper arms are first involved.

The etiology, pathology, and clinical course of the atrophic do not differ essentially from the pseudohypertrophic form.

Pseudohypertrophic Muscular Paralysis. Pseudohypertrophic paralysis is characterized by progressive weakness of the muscles of the trunk and of the legs, associated with apparent hypertrophy of the calves due in great part to a deposit of fat in the wasting muscles (Fig. 368).

The symptoms are caused by a degenerative atrophy of the nerve terminals and of the muscular fibres and an increase of the connective tissue and replacement of the muscular substance by fat.

Diagnosis. The interest in this latter affection from the orthopedic standpoint lies in the diagnosis in the early stage of the affection. At this time the patient is evidently weak; he walks with an awkward, shambling gait, and climbing stairs is especially difficult. There is usually an increased lordosis and a peculiar swaying or waddle, a disinclination to stoop, and an evident difficulty in regaining the erect posture, and there may be discomfort or pain referred to the lumbar region. If the disease is advanced, the peculiar hard, resistant enlargement of the calves, combined, it may be, with atrophy of the muscular groups of the upper extremity, and weakness of the muscles of the back, makes the diagnosis evident, but in young children the disease may be mistaken for *Pott's disease*, *simple weakness*, or *postural deformity*. Although there is a superficial resemblance to the general symptoms of Pott's disease, yet the specific signs of disease of the vertebræ, pain, and muscular spasm are absent.

Weakness, a result of malnutrition or disease, is general in character and its cause is usually apparent; it is, of course, not accompanied by local hypertrophy. Retarded cerebral development causes general weakness as far as inability to stand is concerned, but the cause is in this class also usually apparent.

Postural deformities in childhood always have a cause, and as one is not content to treat a deformity without ascertaining its cause, this search will bring to light the peculiar symptoms of the disease.

Treatment. In certain instances the discomfort referred to the back, due in part to the lordosis, may be relieved by a light spinal support. Massage and muscle-training may enable the patient to utilize the remaining power to best advantage.

In the later stages of the disease there may be secondary deformities, most marked in the feet, which may be fixed in the equinus or equinovarus attitude. This deformity may be corrected by tenotomy or otherwise, if the patient has not already become so weak that walking or standing is impossible.

Hereditary Ataxia. Friedreich's Disease.

Hereditary ataxia is an ataxic paraplegia caused by sclerosis of the posterior and lateral columns of the spinal cord. The early symptoms are inco-ordination and weakness of the legs; later similar symptoms appear in the upper extremities and speech is affected. In well-marked cases there is usually distortion of the feet toward equinus or equinovarus, and occasionally a posterior or lateral curvature of the spine. In one case recently under treatment at the Hospital for Ruptured and Crippled, the rectification of the deformity of the feet was at least of temporary benefit.

Neuritis.

Localized neuritis after contagious disease or from other causes may result in temporary weakness or paralysis of the dorsal flexors of the foot, cause toe-drop, and, finally, deformity. In such cases the foot should be supported by a brace in normal position. This not only prevents deformity, but it hastens the cure by preventing tension upon and structural lengthening of the weakened muscles. The same treatment may be applied for wrist-drop from metallic poisoning. The hand should be supported by a suitable brace in the attitude of dorsiflexion until the muscles have recovered their power. Obstetrical paralysis has been considered under affections of the shoulder.

Hysterical Joint Affections and Deformities. Functional Affections of the Joints.

So-called hysterical and functional affections may be divided into two groups:

1. Those in which there is no actual disease or weakness.

2. Those in which the symptoms of disease or injury, or of their effects, are exaggerated or prolonged.

The first class of cases is small, the second is large.

Simulation, whether voluntary or involuntary, of organic disease can deceive only those who are not familiar with the characteristics of the disability that is simulated. Every disease has certain well-defined symptoms which can no more be imitated by a well person than a disabled part can suddenly take on the normal appearance and function.

"Hysterical Hip."

The hysterical hip is supposed to simulate actual tuberculous disease.

Diagnosis. The symptoms of actual disease of this joint are pain, limp, limitation of motion due to reflex muscular spasm, muscular atrophy, distortion, and in the later stages the local signs of a destructive process; for example, heat, swelling, abscess and displacement of the parts, shortening of the limb, and the like. As these later symptoms could not be simulated, they need not be considered.

In actual disease symptoms and effects follow one another in regular sequence and correspond closely to the pathological conditions that cause them. Pain is not a pronounced symptom; it is more likely to be concealed than exaggerated and it is usually referred to the knee. Local sensitiveness is not marked, and it is often absent. Distortion of the limb when it occurs in the early stage, before the destructive changes are advanced, is caused by involuntary muscular contraction, and whenever this distortion is great the reflex muscular spasm, which involves every muscle about the joint, is also great; so that the range of motion in the joint is small, and it may be absolutely restricted. With the distortion there is always a corresponding atrophy of the muscles of the limb. If pain is present it is usually worse at night than during the day.

The hysterical simulation of hip disease is characterized by an exaggeration of the symptoms and by absence of the physical signs of disease. There is usually an exaggerated limp, great distortion, marked local sensitiveness and pain, but absence of muscular spasm, atrophy, or other signs of disease.

The age of the patient, the history of the supposed disease, and

the other evidences of hysteria that are usually present will confirm the diagnosis.

The same principle applies, of course, to the differential diagnosis of simulated disease at other joints. The knee and the hip are those that are most often involved.

Hysterical Deformities.

"**Hysterical Club-foot.**" Local deformity distinct from simulated joint disease is sometimes seen. Several cases of this character in which the foot was distorted have been under treatment at the Hospital for Ruptured and Crippled recently. The differential diagnosis is simple.

TALIPES is either congenital or acquired. Congenital talipes and all the acquired varieties, other than those of paralytic origin, may be at once excluded from consideration. Paralytic talipes in the vast majority of cases begins in early childhood, when it is either caused by anterior poliomyelitis or of cerebral hemiplegia or paraplegia. When these are excluded the remaining causes of deformity are very limited. Every variety of nervous disease has well-defined symptoms. If actual paralysis is present the muscles atrophy and the electrical reactions are changed. In hysterical contractions the muscles do not atrophy, and the electrical reactions are unchanged.

"**Hysterical Scoliosis.**" A case was recently under observation at the Hospital for Ruptured and Crippled in which distortion of the trunk persisted for more than a year, and until a suit for damages was finally decided. In this case there was a most exaggerated lateral twist of the spine, so that the shoulder approached the pelvis. The deformity, however, was not fixed, but it could be completely reduced when the patient was in the recumbent posture. There was no paralysis, no persistent spasm, no evidence of disease or injury. The deformity was of a nature that could not be explained by any conceivable lesion, and other signs of hysteria were present.

Treatment. The principles of the treatment of pronounced hysteria, of which simulated joint disease or deformity are but unusual manifestations, are considered at length in medical and neurological works, and the subject does not call for special mention here. It is evident, of course, that an unequivocal diagnosis must be the first and essential step toward cure. In this class of cases apparatus is not often indicated unless the

deformity has persisted for so long a time that the disused muscles have become incapable of performing their proper functions.

Functional Affections of the Joints.

"**Neurotic Joints.**" In this class, although there is no absolute distinction between it and the preceding variety, there is usually a physical basis for the symptoms, however much they may be exaggerated.

The patients are not usually hysterical; in fact, hysteria in the ordinarily accepted sense is uncommon, and although the larger proportion of patients are women, yet men and children are by no means exempt from the so-called functional affections.

It must be borne in mind, also, that many of these cases are classed as neurotic simply because the cause of the symptoms is not apparent. It is only within a few years that the slighter degrees of weak foot and its effects have been recognized, and it is probable that such cases, together with anterior metatarsalgia, the painful fascia of the contracted foot, achillodynia, and the like might be considered as neurotic by one unfamiliar with their symptoms. It may be inferred that as diagnosis becomes more accurate the more restricted will become the class of cases of purely imaginary disability, in so far at least as the locomotive apparatus is concerned.

A "neurotic joint" is often caused by injury. A sprain of the ankle, for example, may have been treated by prolonged immobilization, either because the patient had originally impressed the physician with the severity of the symptoms or because of persistent discomfort. When the dressing is removed there may be congestion and discoloration due to impaired circulation, weakness and atrophy of the muscles due simply to disuse, and a certain degree of infiltration and stiffness caused by the original injury. In cases of this character the disability may be prolonged because the patient or the physician mistakes the effects of disuse for the symptoms of serious injury or disease. When the diagnosis has been made treatment should be directed to increasing the activity of the circulation and thus the nutrition of the part, by counter-irritation, by massage, by passive movements, by voluntary exercises and the like, but cure can only be completed by restoring functional use. If, therefore, the disability is of long standing a temporary brace will be required to protect the part from injury, and to increase the patient's

confidence. In milder cases it is possible that without support or treatment, other than an assurance of the absence of serious weakness, cure may be accomplished, but this is certainly unusual.

What has been said of exaggerated disability at the ankle following traumatism applies to the treatment of similar affections elsewhere. The knee-joint is very often the seat of so-called neurosis. Injury at this point in nervous children is often followed by a persistent flexion contraction that may continue for weeks after all signs of the injury have disappeared. When the attempt is made to straighten the knee the patient screams with pain and the muscular resistance is very great. In such cases the immediate rectification of deformity and the application of a plaster bandage to hold the limb in the corrected position is indicated. It must be borne in mind that the persistent assumption of a deformed position for weeks or months must be followed by certain structural changes in the contracted muscles and weakness in the opposing groups. Thus some assistance may be required in the treatment even of the purely hysterical deformities because of this weakness.

In all forms of traumatic neurosis, so called, the possibility of a physical basis for the symptoms should be considered, the location of the pain or discomfort, and its connection with certain movements or attitudes should be investigated. If such discomfort is induced or is aggravated always by a certain motion or attitude it is reasonable to infer that this has a well-defined cause, especially as the pain of a neurotic affection is not often of this definite character. In this class of cases limitation of movement for a time to the painless range of motion by some form of support may be indicated.

Thus far injury has been considered as the starting point of the symptoms, but in many cases there is no history of injury. In this class the symptoms may have been induced by rheumatism or gout or rheumatoid arthritis, or by neuritis, and such possible causes should be investigated and excluded before the diagnosis of simple neurosis is made. In neurasthenic patients or those who are anæmic, or overworked, the pain and discomfort is often localized in the spine. The "neurotic spine" has been considered elsewhere. In the treatment of all cases of this group the general condition of the patient should receive consideration, and in connection with the local treatment a change of occupation and of scene is often of advantage.

It is hardly necessary to insist again that an accurate diagnosis is the first essential of successful treatment. If this is impossible at least one may by exclusion of those injuries and disabilities and diseases which are evidently not present arrive at a general conclusion as to the character of the ailment and shape his treatment accordingly.

CHAPTER XIX.

CONGENITAL AND ACQUIRED TORTICOLLIS.

Synonym. Wryneck.

Torticollis is, as the name implies, a twisted neck, a distortion caused in most instances by active contraction or by shortening of one or more of the lateral muscles that control the head. Similar distortion may be due to disease of the spine, so-called false torticollis, but this should be classed as a symptom of the underlying disease, not as simple torticollis, of which the distortion itself is the important disability that demands treatment.

Torticollis may be divided primarily into two classes: the congenital and the acquired.

Congenital torticollis is a painless shortening of the tissues on one side of the neck of intra-uterine origin.

Acquired torticollis is, in most instances, accompanied in its early stages by local pain and sensitiveness, and by active contraction of the affected muscles. After a time these acute symptoms disappear, leaving simply the deformity. Thus, from the therapeutic standpoint, torticollis may be classified as *acute* and *chronic*, the latter class including the congenital form.

The sternomastoid is the muscle that is usually involved primarily, both in the congenital and acquired forms; thus, in typical torticollis the head is drawn somewhat forward and is inclined toward the contracted muscle, while the neck is pushed, as it were, away from the contraction (Fig. 370); the chin is slightly elevated, and turned toward the opposite shoulder—an attitude explained by the normal action of the affected muscle. Irregular distortions of the head, as posterior or anterior torticollis due to contraction of muscles other than the sternomastoid, are, however, not infrequent. These will be mentioned in the consideration of the forms of acquired torticollis.

Statistics. Torticollis is comparatively an uncommon deformity. In a period of twenty-seven years 507 cases were treated at the Hospital for Ruptured and Crippled, as contrasted with upward of 5000 cases of congenital and acquired talipes.

Acquired torticollis is by far the more common variety, as is

shown by the fact that of the 507 cases but 87 were supposed to be of congenital origin.

It is often stated that torticollis is more common in males than in females, and that the right side is more often affected, yet 46 of the 87 congenital cases were in females and the contraction was of the left side in 38 of the 58 cases in which the affected side was specified. Of the entire number of cases available for comparison 246 were in females and 198 in males; in 236 instances the contraction was on the left and in 196 on the right side of the neck. From these statistics it would appear that the deformity is somewhat more common in females than in males, and that the left side is more often affected than the right.

Congenital Torticollis.

In most instances the deformity of congenital torticollis is slight at birth, and it may not attract attention until the child sits or walks. Thus it is often difficult to distinguish the con-

FIG. 370.

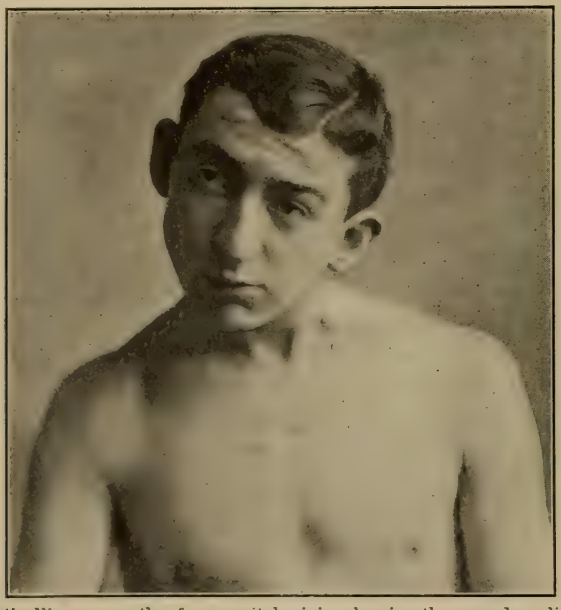

Left torticollis, apparently of congenital origin, showing the secondary distortions of head and face.

genital form from the deformity that may have been acquired in infancy, especially as the patient may not be brought for treatment until the distortion has persisted for many years.

In early infancy slight torticollis may be demonstrated by fixing the shoulder on the affected side and drawing the head forcibly in the opposite direction, when the shortened muscle becomes prominent beneath the skin, evidently restricting the range of motion. In most instances the sternal division of the muscle appears to be more shortened than the clavicular portion.

In exceptional cases the deformity even in infancy may be extreme, and it may be accompanied by well-marked asymmetry of the face and even by distortion of the skull. In this class

FIG. 371.

Right torticollis, showing the displacement of the head toward the opposite side.

the shortening may involve all the lateral tissues, both anterior and posterior. Slight asymmetry may be present at birth and becomes more marked with the growth. Even in the acquired form it appears usually soon after the onset of the deformity, becoming more marked with its continuance. Its cause is the constrained attitude, the restriction of normal use, and consequently of the blood supply, combined with the tension upon the tissues of the face, as is evidenced by the fact that it becomes less noticeable after the deformity has been corrected.

In the well-marked cases of long standing, whether congenital or acquired, the face is shorter and flatter, the nose and the corner of the mouth and the eyelids even on the affected side are drawn downward, and the skull shows evidence of atrophy and deformity.

Secondary distortions also appear in the trunk in chronic cases. These are rotation of the spine to compensate for the lateral distortion of the head and an increase in the dorsal kyphosis, "round shoulders." Among the minor secondary deformities upward bowing of the clavicle caused by the tension of the contracted muscle may be mentioned (Fig. 370).

In the early stage of torticollis the head is tilted toward the contracted tissues, but when the deformity is of longer standing the head following the compensatory convexity of the cervical spine appears to be displaced toward the opposite shoulder and the inclination may be less marked (Fig. 371).

The compensatory deformities that have been indicated are slight in infancy, but they become more marked in later childhood, for in many instances the shortened muscle ceases to grow; thus, an original shortening of half an inch, as compared to its fellow, may be increased to two or more inches in later years. This fact emphasizes the importance of treatment as soon as may be possible after the distortion is discovered.

As has been stated, the important contraction is usually of the sternomastoid muscle, but if the deformity is uncorrected all the lateral tissues become shortened, so that at a later stage complete division of the cervical fascia as well as of the muscles may be necessary before the deformity can be corrected.

Typical wryneck caused by shortening of the sternomastoid muscle is by far the most common form of congenital torticollis, but occasionally cases are seen in which the head is but slightly inclined to one side and in which the shortening appears to involve the lateral tissues in general rather than a particular muscle. In rare instances, although the deformity resembles that of typical torticollis, the greatest shortening will be found to be of the posterior muscles on one side, particularly of the trapezius and the levator anguli scapulæ. Thus the scapular may be elevated and tilted forward. This form of torticollis appears to be one variety of congenital elevation of the scapula. (See page 229.) Torticollis due to defective development of the upper extremity of the spine is a rare deformity that does not require special description.

Etiology. It may be assumed, disregarding the possible influence of hereditary predisposition, that congenital torticollis is, in most instances, caused by a constrained or fixed position in the uterus for a longer or shorter time before birth. It is, in fact, a simple distortion ; and that it has, in the majority of cases, no deeper significance is proved by the fact that it may be easily and completely cured by simple division or elongation of the contracted tissues.

It would seem that a deformity to be properly congenital must be present at birth, yet the theory, first advanced by Stromeyer, that congenital torticollis is usually the result of injury at birth, has been so generally accepted that it merits further consideration.

Hæmatoma of the Sternomastoid Muscle. Hæmatoma is considered to be, and undoubtedly is, evidence of injury. During difficult delivery fibres of the muscle are ruptured, usually in the upper or middle third of the anterior border, hemorrhage follows, which in turn is surrounded by an encapsulating area of inflammatory material. This forms a firm, cylindrical tumor in the substance of the muscle, which becomes noticeable about two weeks after birth, or at least this is the time when it is usually discovered by the mother. As a rule, the tumor is not sensitive to pressure ; it may or may not be accompanied by restriction of motion in the direction causing tension on the muscle. The tumor remains for from three to six months, when it usually disappears, leaving no trace of its presence.

The theory of Stromeyer, which until recently was generally accepted, is that congenital torticollis is usually caused by rupture of the muscle and by myositis about the hæmatoma. This inflammation may involve and ultimately destroy a large part of the substance of the muscle, replacing it with fibrous tissue, which, contracting, causes deformity.

This theory is extremely improbable for the following reasons:

1. Rupture of muscle elsewhere is practically never followed by myositis and contraction.

2. It has been demonstrated by Heller[1] that it is impossible to cause myositis and contraction by any form of injury to the muscles of animals unless it be combined with actual infection with pyogenic germs.

3. Most of the cases of congenital torticollis seen soon after birth present no evidence of hæmatoma or injury, viz. : In 7 of

[1] Heller. Deutsche Zeits. f. Chir., Bd. xlix. H. 2 and 3, S. 234.

55 cases of supposed congenital torticollis, investigated by the writer, there was a history of injury at birth. In 48 cases no mention was made of injury. In the 7 cases referred to the deformity was accompanied by hæmatoma or there was a history of a swelling, apparently of this nature; but in 2 of these the hæmatoma was coincident with intra-uterine shortening of the muscle.

4. Cases of hæmatoma of the sternomastoid muscle are not, as a rule, followed by torticollis. Seven consecutive cases of hæmatoma were examined by the writer with special reference to this point. In all the evidence of violence in delivery was clear. Two were delivered by forceps, 3 were breech presentations, and in 2 version was performed. In 1 case an arm was broken and in another paralysis resulted from injury to the brachial plexus. Six of the children lived until the swelling had nearly or entirely disappeared, and in none did torticollis accompany or follow the hæmatoma.

5. In certain cases a congenitally shortened muscle may be ruptured at delivery; thus the hæmatoma is simply a complication of torticollis, not its cause. Bruns[1] has reported such a case, and two others have been observed by the writer, in one of which club-foot was present also.

6. Hard tumors of the sternomastoid muscle are not always the result of injury; myositis may be of syphilitic origin apparently occurring in intra-uterine life. In other instances tumors of fibrous or sarcomatous nature have been removed from the substance of the muscle. Sixteen cases in which cartilaginous nodules, apparently of congenital origin, were found in the muscle have been reported.[2]

Congenital torticollis in the majority of cases is of intra-uterine origin. If it follows injury at birth it is probably an indirect result of local pain, discomfort, and irritation of the nerves or of an actual infectious inflammation of the injured part rather than an effect of the absorption of effused blood.

Pathology. In the ordinary type of congenital torticollis, as demonstrated at operations on children, the substance of the affected muscle or muscles is simply lessened in amount, and there is a disproportionate area of tendinous substance as compared to the contractile tissue. In other instances the muscle may be almost entirely replaced by fibrous tissue, or it may be traversed

[1] Cent. f. Chir., 1891, No. 26. [2] Leugemann Beitr. z. klin. Chir., Bd. xxx. H. 1.

by fibrous bands, or patches of scar-like tissue may be distributed throughout its substance. These degenerative changes, considered to be evidences of pre-existing myositis, are probably more common among the acquired than the congenital form, and, as a rule, they are found only in cases of long standing. Secondarily all the lateral tissues of the neck are shortened to correspond to the habitual attitude, and the compensatory curvatures of the spine in time become fixed, so that torticollis may be classed as one of the causes of scoliosis.

Acquired Torticollis.

Acquired torticollis is an affection of early life, at least 80 per cent. of the cases beginning in the first ten years of life.

As has been stated, congenital torticollis is usually a painless shortening of the muscles, while acquired torticollis is, as a rule, a painful affection secondary to injury or disease of some of the structures of the neck, which causes peripheral irritation of the nerves and active contraction of the neighboring muscles. Thus, as a rule, the number of muscles involved in the deformity is greater than in the congenital form; for example, in the ordinary form of acquired wryneck the trapezius, which receives in part the same nerve supply, is usually involved together with the sternomastoid; and irregular forms of distortion caused by contraction of other groups are not uncommon.

Varieties. The varieties of acquired torticollis may be classified conveniently as follows:

1. The simple or mechanical form due to scar contraction following destruction of the skin or deeper tissues, as from burns or disease.

2. *Acute torticollis* caused by direct irritation of the muscle, by injury, by inflammatory affections of the surrounding parts, combined in most instances with irritation of the peripheral nerves, which causes reflex contraction of certain muscles or muscular groups.

3. *Spasmodic Torticollis.* A form of convulsive spasm, "a disorder of the cortical centres for rotation of the head." (Walton.)

4. *Irregular Forms of Torticollis.* Paralytic, ocular, psychical, and the like.

The first class, that due to scar contraction, needs only to be mentioned.

Etiology of Acute Torticollis. The second class is the most important form of torticollis, both as to frequency and as to its effect in causing permanent distortion. Of this group, one of the most common, and at the same time the least important form, is the simple stiff neck, supposed to be due to cold or to muscular rheumatism. Its onset is, in childhood, sometimes accompanied by slight fever and malaise; the affected muscle is somewhat sensitive to pressure and motion or tension causes discomfort. The distortion, in great part voluntary and accommodative, is of short duration as a rule. Strains and direct injury of the muscles of the neck may cause deformity, which usually disappears when the local sensitiveness has subsided. Traumatic hæmatomata, similar to those caused by injury at birth, are sometimes observed in older subjects. These usually disappear after a time, leaving no trace of their presence.

FIG. 372.

Bilateral contraction of the sternomastoid and trapezii muscles. (See Fig. 373.)

Another form of torticollis is secondary to cellulitis and to infiltration following the breaking down of tuberculous cervical glands. This may become a permanent distortion if the deformity is allowed to persist or if the tissues of the neck are injured by the suppurative process.

By far the most important variety of this class is the *acute spastic torticollis* due to active tonic contraction of one or more of the muscles of the neck. The exciting cause of the spasm appears to be irritation of the peripheral nerves in the nasopharynx or in its neighborhood, and the muscles most often affected are those supplied in part by the spinal accessory nerve. Thus torticollis of this form may follow tonsillitis, pharyngitis, measles, diphtheria, and the like. It may be preceded by "toothache" or "earache," or it may be an accompaniment of what appears to be the ordinary form of stiff neck, or of enlarged or suppurating cervical glands. In this form the torticollis is

caused directly by tonic contraction of the muscles. Reflex spasm of this character is, however, often associated with the distortion, due primarily to injury of the neck or to some local inflammatory process, so that a sharp distinction between the divisions of this second class is impossible. Many of the patients are known to be of a nervous temperament, and overstudy, anxiety, sudden shock, and the like are considered to be predisposing causes.

This variety of acquired torticollis completely overshadows in importance all other forms, as is indicated by the statistics of 212 cases treated at the Hospital for Ruptured and Crippled in which the cause seemed to be apparent. Of the 212 cases 181 may be fairly assigned to this class.

The apparent exciting causes of cases of acquired torticollis treated at the Hospital for Ruptured and Crippled are shown in the following table:

Enlarged cervical glands	14	Cold in the neck	5
Suppurating " "	41	Rheumatism	18
Scarlet fever	14	Vaccinia	1
Diphtheria	7	Fever	6
Mumps	6	Malaria	5
Measles	2	Injury to the neck	35
Sore-throat	8	Rhachitis	3
Suppurating otitis	3	Syphilis	1
Toothache	6	Cicatricial contraction	3
Cellulitis of the neck	2		
Furuncle " "	1	Total	181

Torticollis associated with chorea	4
" " " epilepsy	1
" " " cortical irritation	5
" " " hysteria	1
" " " meningitis	1
" " " hemiplegia	3
Spasmodic torticollis	8
"Functional torticollis"	8
Total	31

Symptoms of Acute Torticollis. As a rule, the distortion of the neck, slight at first, is more noticeable at night than in the morning; it then gradually increases until the deformity becomes fixed. In other instances the onset is sudden, sometimes accompanied by fever.

As has been stated, in most instances several muscles are more or less involved in the contraction, particularly the sternomastoid and the trapezius, and in such cases the deformity is more marked and persistent than when the sternomastoid is alone affected. Less often the contraction is of the posterior group, "posterior torticollis," when the head is tilted backward and the chin is turned more toward the opposite side than in the typical lateral form. In other cases the contraction appears to affect the small

muscles that control the small joints at the upper extremity of the spine, when the head may be tilted forward with but slight lateral inclination, resembling closely, except in the history, the symptomatic wryneck of Pott's disease. In rare instances the muscles on both sides of the neck may be contracted simultaneously (Fig. 372). The contracted muscles are usually sensitive to manipulation and attempted rectification of the deformity causes extreme pain and is resisted by the patient. The child is, as a rule, nervous and irritable; it often complains of neuralgic pain about the contracted part which is increased by sudden or unguarded movements or strain; thus "getting the patient to

FIG. 373.

Bilateral torticollis after treatment. (See Fig. 372.)

bed" is often a tedious proceeding, because of the difficulty of supporting the head comfortably with the pillows.

In many instances the affection is of short duration; in others, particularly those in which the reflex spasm is aggravated by local inflammatory processes, there appears to be but little tendency toward recovery. In such cases, after several weeks or months, the local pain and sensitiveness may subside, together with the active spasm, but the deformity remains, caused by adaptive shortening of the muscles and fascia, aggravated in some instances by actual myositis. The muscles atrophy and degenerate and present at a later stage the same pathological appearances that are found in the congenital form.

Diagnosis. Torticollis is most often confounded with *Pott's disease*. This would seem to be hardly possible in cases of the simple painless contraction of chronic torticollis. In the acute form, however, there may be more difficulty in distinguishing between the two. The main points have been mentioned already in connection with Pott's disease. In acute torticollis the affection is of sudden onset, not preceded by the stiffness and neuralgic pain that characterize tuberculous disease. The deformity of torticollis is almost always of the regular type—that is, the head is tilted toward the contracted muscles while the chin is rotated in the opposite direction. The spasm and contraction of the affected muscles are apparent, and direct tension upon them is painful. If, however, the tension is relaxed by inclining the head toward the contraction, movement of the head in other directions will be found to be practically unrestricted.

In Pott's disease the spasm of muscles is general, the deformity is not of a regular type, since the chin often points to the side toward which the head is inclined. Steady tension with the aim of reducing the deformity is not, as a rule, painful; in fact, it is often agreeable to the patient. Finally the limitation of motion cannot be lessened by inclining the head toward the muscle that seems to be most contracted, for the reflex spasm of Pott's disease limits motion in every direction. As a rule, the diagnosis is easily made, but in cases complicated by suppuration of the cervical glands it is sometimes impossible to exclude Pott's disease until after the effect of treatment has been observed.

Disease of the cervical spine, other than tuberculous, is comparatively rare, and resembles in its symptoms Pott's disease rather than torticollis. *Arthritis* of the atloaxoid articulation may be a manifestation of rheumatism; it may follow infectious disease, or it may occur as an isolated infection. It is of sudden onset, and it resembles acute spastic torticollis, except that all the surrounding muscles are affected rather than a particular group; in fact, but for the history it could not be distinguished from tuberculous disease of this region.

Although the diagnosis of torticollis is simple, it is not always easy to determine the muscle or muscles involved in the contraction.

The effect of unilateral contraction of the different muscles is as follows:

The sternomastoid inclines the head toward the contraction, displaces it toward the opposite shoulder, elevates the chin, and turns it away from the contracted muscle.

The trapezius has much the same action, but the backward inclination and rotation are more marked.

The action of the complexus resembles that of the trapezius, but the rotation is less.

The splenius inclines the head backward and toward the contracted muscle, but does not turn the chin in the opposite direction.

The scaleni have the same action, except that the head is inclined forward.

As has been stated, in acute torticollis several muscles are often involved, but the spasm is usually greater in one or in one group than in another. The seat of greatest contraction may be determined by the deformity, by the evident spasm that resists reposition, and by the local sensitiveness on palpation. As a rule, when the primary contraction is of the posterior group, the deformity is more marked than in other forms. Bilateral contraction of the muscles is rare, but it is occasionally seen (Fig. 372).

Treatment. The treatment varies according to the cause and with the duration of the deformity. Excluding, for the present, the rare and irregular forms of wryneck there are, from the remedial standpoint, two forms of torticollis:

1. The chronic form, in which the local pain and sensitiveness are absent, but in which there is resistant and permanent deformity. As has been stated, congenital torticollis is included in this class.

2. The acute form, in which the distortion is of short duration and in which permanent contraction may be prevented.

The Treatment of Chronic Torticollis. By Manipulation. Congenital torticollis, if of moderate degree, can be overcome in early infancy by methodical stretching of the contracted parts. One person fixes the arm and another draws the head gently but firmly in the direction opposed to the contraction, over and over again, meanwhile massaging the tissues of the neck. The procedure should be repeated several times a day; it causes slight momentary discomfort if properly performed, but this ceases when the stretching is discontinued. Care should be taken also that the posture may, as far as possible, favor the reduction of the deformity; thus while the child is in the mother's arms the head should be supported, and when asleep the pillow may be arranged in a manner to prevent the improper position. In this way the torticollis may be entirely corrected or its progress may be checked until more effective treatment is indicated.

Hæmatoma. The evidence of injury at birth should be treated by massage with some bland ointment; if it is accompanied by deformity the manipulation already described should be employed.

In the great majority of cases of congenital torticollis the patient is not brought for treatment until the deformity has become an eyesore to the parents. The contracted muscle is then usually an inch shorter than its fellow, the disparity increasing, as a rule, with the growth of the child. In such cases the immediate correction of the deformity is indicated, and this implies in most instances, division of the contracted parts by subcutaneous tenotomy or by open incision.

By Subcutaneous Tenotomy. If the deformity is comparatively slight and if the contraction seems to be limited to the sternomastoid, and particularly to its sternal portion, one may hope to overcome the most resistant part of the contraction by the subcutaneous operation. Aside from the possibility of wound infection, which at the present time is an argument of very little weight, subcutaneous tenotomy has the advantages of simplicity, apparent freedom from the danger which parents associate with an operation, and it leaves no scar behind. It is inadequate, however, for the correction of advanced cases.

The patient and the instruments having been prepared as for an ordinary operation, a sand-bag is placed beneath the shoulders and the head is inclined so that the contracted muscle is thrown into relief beneath the skin. The sternal insertion of the tendon is seized with two fingers and the tenotome is inserted beside it and passed beneath it at a point about an inch above the sternum. It is then divided by a sawing motion of the knife. Division of this part of the muscle in this situation is practically free from danger, and in the slighter degrees of deformity one can by vigorous manipulation and forcible traction overcome the resistance offered by the other tissues. If bands of fascia resist the correction, they may be divided by superficial nicking with the tenotome in the lateral region of the neck. As a rule, however, in cases of this type the open incision is to be preferred, as it allows the opportunity for free division of the contracted parts with less danger of injury to the bloodvessels and nerves in this neighborhood.

By the Open Method. The incision should be made in the line of the muscle midway between the sternal and clavicular insertion. In the milder cases in childhood it need be little more than an inch in length. A director may be passed beneath the

tendon, and on this it may be divided. The clavicular insertion and the non-resistant bands of fascia may be divided as they appear.

In cases of very great deformity in the adult some of the posterior as well as the lateral muscles are involved. In such instances the contracted parts may be divided at the upper border of the neck through an incision from the mastoid process backward along the lower border of the scalp, the scar being concealed by the hair.

Overcorrection of the Deformity. The object of treatment is not only to straighten the head, but also to overcome all restric-

FIG. 374.

Torticollis, left, showing the method of fixing the head in the overcorrected position. After operation.

tion of motion that may remain after the division of the more resistant parts, and the operation, whether open or subcutaneous, must be supplemented by a vigorous kneading of the lateral tissues with the ulnar border of the hand while traction is made upon the arm and head. Finally, the head is rotated away from

the contracted parts, the aim being to completely overcome the secondary curvature of the cervical spine.

It may be stated that Lorenz considers it possible to correct torticollis, even of long standing, by this system of systematic kneading and stretching without previous division of the contracted tissues, but the use of so much force appears to be undesirable if by so slight an operation it may be avoided.

Not only should all resistance be overcome by vigorous manipulation at the time of operation, but the head should be fixed during the process of repair in the overcorrected position. Thus in the treatment of typical torticollis the chin should be turned to a point over the middle of the clavicle on the operated side, and the head should be inclined toward the opposite shoulder. In this attitude a plaster bandage should be applied surrounding the head and the thorax. This bandage should remain until all local sensitiveness has disappeared, and until the tendency toward deformity has been checked. This fixation in the overcorrected position is very important in childhood, as an aid in overcoming the deformity habit, but it may be dispensed with in the treatment of adults (Fig. 374).

The plaster bandage is retained from four to eight weeks. When it is removed massage, manipulation, and gymnastic training are indicated. Twice a day the head should be forced to the extreme limit of overcorrection. Traction on the neck in self-suspension by means of the sling used in the application of the plaster jacket, a regular system of exercises for the muscles of the neck and back, and supervision of the habitual postures will usually assure a complete cure. If, however, the deformity habit is strong so that the head has a marked tendency to resume the former attitude, some support is indicated. A simple and effective support is the jury mast as used in the treatment of Pott's disease with the plaster jacket or attached to a brace. In the treatment of children a band of elastic tape arranged to draw the head toward the shoulder as suggested by Sayre, or a Thomas collar, may be sufficient.

As has been stated, the necessity for support, provided the deformity has been thoroughly overcorrected, depends upon the care that is to be exercised in the after-treatment. When exercises and massage can be efficiently employed, the support is not essential. In other cases it may be worn for several months with advantage.

The principles of the treatment of the chronic or painless form

of torticollis that have been outlined apply to the acquired as well as to the congenital form, when adaptive shortening has replaced active contraction. Acquired torticollis is, in most instances, however, a preventable deformity; thus operative treatment would be rarely required had the patient received proper treatment.

The Treatment of Acute Torticollis. The insignificant form of torticollis called stiff neck may be treated by hot applications; a firm, thick collar of flexible cotton stiffened by several layers of adhesive plaster is an agreeable support in the more painful cases.

In true acute spastic torticollis the cramp-like contraction of the muscles is secondary to irritation elsewhere. This one should always try to remove, and, as has been stated, the general condition of the patient may require treatment as well. But the important indication is to support the head in order to relieve the pain and to correct the distortion. In the early stage the support of the collar that has been described may be sufficient, but, as a rule, patients of this class are not seen until the distortion has persisted for weeks or months even, so that a more efficient form of support is required—such is the plaster jacket and jury mast. The elastic tension of this appliance overcomes the spasm and relieves the discomfort and apprehension which have lowered the vitality of the patient (Fig. 53). If the spasm is the result of the irritation of enlarged or suppurating cervical glands, as is often the case, the rest afforded by the brace is an effective treatment of the cause as well as of its effect, and if suppuration is present this support is most convenient for the dressing that may be required. When the acute symptoms and deformity have been relieved manipulation and exercises may be employed in the manner already described.

In cases of longer standing, particularly when the posterior muscles are involved, the deformity may be forcibly corrected under anæsthesia, and the head may then be fixed in a plaster dressing in the manner already described. This treatment may be employed at an earlier stage in selected cases. As a rule, when deformity has been allowed to persist for six months or more, its rectification will require division of the more resistant tissues.

Spasmodic Torticollis.

Spasmodic torticollis, a form of convulsive spasm of the muscles of the neck that is somewhat similar in its general char-

acteristics to writer's cramp,[1] must not be confounded with the acute torticollis of childhood, in which tonic spasm of the affected muscles, due usually to some well-defined irritation of the peripheral nerves, is the characteristic. Spasmodic torticollis is an affection of adult life. Of 32 cases collected by Richardson and Walton,[2] but 2 were in patients less than twenty years of age. The sexes are equally liable to the affection, and the contraction is as frequent on one side as on the other.

The onset of the affection is usually gradual. The first symptoms are often sensations of stiffness and discomfort in the muscles of the neck; a "drawing sensation" and a momentary twitching or slight contraction which draws the head to one side. These symptoms increase slowly until the head is habitually inclined in the attitude of torticollis. For a time the patient can correct the position voluntarily, or by supporting the head with the hand can restrain the twitching of the muscles, but in well-established cases the head is persistently inclined to one side and the convulsive spasm is uncontrollable. This latter symptom is the most marked peculiarity of the affection; at intervals the head begins to twitch, and it is finally drawn by the convulsive contraction of the muscles into an attitude of extreme deformity. As the muscles most often affected are the sternomastoid and trapezius the attitude is usually one of typical torticollis. The spasmodic clonic contractions may involve the muscles of the face or of the chest even. They are more marked when the patient is excited or when sudden movements are necessary. As a rule, patients complain of neuralgic pain in the head and neck, aggravated by the cramp-like contractions.

Etiology and Pathology. The etiology is obscure. Many of the patients present a neurotic family or personal history, and overwork, shock to the nervous system, and the like are cited as predisposing causes. The affection has been compared to writer's cramp, as in certain instances the spasm appeared to be caused by constrained positions of the head necessitated by certain occupations, aggravated, it may be, by the strain of defective eyesight.

The affected muscles may be hypertrophied from constant activity, and in the later stages of the affection they are, as a rule, permanently shortened. No characteristic changes in the nerves or in the central nervous system have been recorded.

[1] Spasmodic torticollis is defined by Walton as a "disorder of the cortical centres for rotation of the head." American Journal of the Medical Sciences, March, 1898.

[2] American Journal of the Medical Sciences, January, 1895.

Prognosis. There is little tendency toward spontaneous recovery. As a rule, the spasm becomes more constant and other muscles become involved.

Treatment. It is perhaps unnecessary to state that the general condition of the patient and the possible local and general causes of the spasm should receive consideration. As a rule, however, the patient will have exhausted both constitutional and local treatment before coming under observation.

In the mild and early cases the avoidance of predisposing causes combined with massage, systematic muscle training, and in exceptional instances mechanical support may be of service; but in the chronic, severe, and persistent cases of this class the resection of nerves supplying the affected muscles has alone proved to be efficient. If the spasm is limited to the sternomastoid and trapezius muscles, resection of the spinal accessory nerve may be sufficient; but if other muscles are involved or if the spasm recurs after the original operation, the removal of the posterior branches of the upper cervical nerves, together with extensive division of the contracted muscles upon the same side and sometimes upon the opposite side also, may be required.

Resection of the spinal accessory nerve was first performed by Campbell de Morgan, of London, in 1866, and since then the operation has been repeated many times by other surgeons with temporary or permanent benefit to the patients. According to Pétit, of 26 patients so treated 13 were cured and 7 were permanently improved. In 5 others the benefit was but temporary, and 1 died from erysipelas following the operation.[1]

The Operation. The spinal accessory nerve passes downward and backward from the jugular foramen and enters the anterior border of the sternomastoid muscle at a point about one and a half inches below the tip of the mastoid process. At this point it should be exposed. Dr. E. Eliot, Jr., from a special study of the course and relations of the nerve, suggests the following method:[2]

"The incision should be generous, for the nerve is situated at a considerable depth, and should extend from the mastoid process above downward to one or two inches beyond the angle of the jaw. The anterior edge of the sternomastoid should then be exposed. In the upper part of the wound the posterior and inferior portion of the parotid gland may have to be drawn

[1] L'Union Médicale, July 9, 1897. [2] Annals of Surgery, May, 1895.

forward, although usually it does not overlap the muscle. When this is done it is comparatively easy to expose by blunt dissection the transverse process of the atlas, as it lies directly below the mastoid process above, while immediately in front of this bony prominence, and running downward and forward from the mastoid process toward the angle of the jaw is the posterior belly of the digastric. Behind this lie the main vessels of the neck, with the spinal accessory nerve emerging from the jugular foramen, and the operator is certain that no harm can be done to these structures as long as he remains superficial to the digastric belly, which in its turn lies at a considerable depth—in fact, at about the level of the transverse process of the atlas.

"Owen and Pétit have drawn attention to the fact that the nerve usually enters the mastoid muscle at a point opposite the angle of the jaw. I have found, however, in a large majority of cases that, on leaving the internal jugular it assumes a definite relationship with the transverse process of the atlas. Never above it, sometimes directly over it, usually a fraction of an inch in front of its most prominent part, the nerve may easily be detected in the small amount of connective tissue that envelops it, and from this point to its entrance into the belly of the muscle it may be isolated with safety, and treated by any suitable procedure. If, exceptionally, it should escape detection, the anterior border of the muscle should be drawn sharply backward at a point opposite the angle of the jaw, the nerve in this way put on the stretch, and by blunt dissection in the adipose tissue that separates the under surface of the muscle from the sheath of the vessels the nerve may be readily exposed. Usually the nerve passes from under the posterior belly of the digastric, at a point just in front of the transverse process of the atlas, to a point on the deep surface of the muscle just behind its anterior margin opposite the angle of the inferior maxilla. It is sometimes accompanied by a small artery and vein, the latter easily visible, the former a branch of the occipital. Rarely the nerve lies at a considerable distance from the transverse process of the atlas; in one case as much as half an inch anteriorly. Here the nerve could be found at its entrance into the muscle, the landmark of the transverse process having failed to localize its situation."

Richardson suggests that if the nerve is not readily found its position may be ascertained by drawing the finger-nail firmly across the bottom of the wound, a sharp contraction following pressure upon it. The nerve having been isolated a section of an

inch should be removed. Richardson advises in addition vigorous stretching of both extremities. After division of the nerve the spasmodic contraction relaxes and the muscles become flaccid, allowing the head to be brought to the normal position, or if the deformity has become permanent the contracted parts may be divided as in the ordinary form. Fixation of the head is not, as a rule, required. The operation should be supplemented by massage and by muscle-training. If the spasm has been confined to the muscles supplied by the spinal accessory nerve, the treatment may be permanently successful, but in many instances the spasm may recur in other muscles. Of these, the posterior group of the opposite side is more often affected, and a similar operation for resection of the posterior branches of the upper cervical nerves may be indicated. This has been performed with success by Smith, of London; Keen, Richardson, and others. According to Smith,[1] the operation should be conducted as follows: An incision is carried downward from the occiput about three inches in length, parallel to and one inch from the spinous processes. It is continued through the trapezius to the edge of the splenius. The complexus is then divided and the posterior branches of the nerves are exposed; those of the three upper nerves which supply the posterior rotators are then resected.

Keen[2] operates in a somewhat different manner, by a transverse incision two and a half inches in length from the middle line of the neck on a level with a point one-half an inch below the level of the lobule of the ear. The trapezius is divided transversely, afterward the complexus, care being taken to spare the great occipital nerve. The posterior branch of the second cervical nerve is then resected; the suboccipital nerve is then looked for in the suboccipital triangle, traced down to the spine, and divided. The external trunk of the posterior division of the third occipital nerve is then exposed below the great occipital and divided close to the bifurcation of the nerve trunk; thus the nerve supply of the chief posterior rotators, the splenius capitis, the rectus capitis, posticus major, and the obliquus inferior is removed.

The paralysis that follows even such extensive operations seems to inconvenience the patient but slightly, while the relief from deformity and from the constant spasm is a more than sufficient compensation for whatever weakness or disability may result.

The following are the conclusions of Richardson and Walton:[3]

[1] Spasmodic Wryneck, London, 1891.
[2] Annals of Surgery, January, 1891.
[3] Annals of Surgery, January, 1891.

1. Palliative treatment, whether by drugs, apparatus, or electricity, will rarely prove successful in well-established spasmodic torticollis.

2. Massage may prove of value in comparatively recent cases.

3. Resection affords practically the only rational remedy.

4. Operation on the spinal accessory nerve may afford relief, even if other muscles than the sternocleidomastoid are affected. On the other hand, the affection previously limited to the sternocleidomastoid may spread to other muscles in spite of this operation.

5. No fear of disabling paralysis need deter us from recommending operation, as the head can be held erect even after the most extensive resection.

6. The most common combination of spasm is that involving the sternomastoid on one side and the posterior rotators on the other, the head being held in the position of sternomastoid spasm with the addition of retraction through the greater power of the posterior rotators.

7. It seems advisable in most cases to give preference to the resection of the spinal accessory as the preliminary procedure.

In a later communication Richardson and Walton[1] report very satisfactory final results on cases treated by resection of nerves supplying the muscles that were affected by the spasm on one or both sides, combined with complete division of the muscles as well, when permanent contraction was present.

Kalmus[2] has reviewed the literature of the subject. In 11 cases of simple stretching of the spinal accessory nerve 3 were cured. In 68 cases the nerve was resected; of these 23 were cured and 20 were improved. In 4 there was no improvement, and in 1 the patient died. In 15 cases the resection of the nerve was supplemented by division of cervical nerves; 10 of these were cured and 3 were improved. In 2 others the sternomastoid muscle was divided.

Irregular and Exceptional Forms of Torticollis.

Paralytic Torticollis. One or more of the muscles of the neck may be paralyzed, as from anterior poliomyelitis, and thus a deformity, due at first to simple weakness and later to the permanent effects of the disability, may be the result.

[1] American Journal of the Medical Sciences, 1896.

[2] Zur Operativ Behand. Caput. Obst. Spasticum, Beiträge zur klin. Chir., 1900, Bd. xxvi.

Diphtheritic Paralysis and Torticollis. The muscles of the neck may be involved in paralysis following diphtheria. In this form the trapezii muscles are, as a rule, affected, so that the head hangs forward, but occasionally the paralysis may be accompanied by contraction of one of the sternomastoids. The history, the evident weakness, and the paralysis of the soft palate or other parts, which is often present, usually make the diagnosis clear.

Cervical Opisthotonos. In the course of certain forms of disease of the nervous system, for example, cerebrospinal or basilar meningitis, the head may be drawn backward by spasm of the posterior muscles. A slight degree of the same deformity is sometimes seen in ill-nourished infants not suffering from serious disease. This and the preceding distortion are of some importance, because they may be mistaken for symptoms of Pott's disease and they have been described in that connection. (See page 62.)

Rhachitic Torticollis. During the course of acute rhachitis, particularly when the characteristic deformity of the lower part of the spine is well marked, the head may be tilted backward usually as a compensatory attitude, but occasionally slight spasm of the posterior muscles may increase the distortion; so, also, when lateral deviation of the spine is present due to rhachitis the neck may participate in the deformity as in other forms of rotary lateral curvature. This is not torticollis, however, in the proper sense.

Ocular Torticollis. Several cases have been recorded in which the head was habitually held in a distorted attitude because of defective vision or irregularity in the action of the muscles of the eyes. This is, however, rather an improper attitude than a variety of true torticollis[1] (Fig. 154).

Psychical Torticollis. A distortion of the head, apparently due to the inability of the patient to control the muscles of the neck, has been described by Brissaud.[2] The deformity was not due to muscular spasm, since it could be corrected by the pressure of a finger on the head. The condition is called by Brissaud a local paralysis of the will—a form of neurosis allied to neurasthenia, epilepsy, and functional spasm.

[1] Medical News, June 11, 1898, p. 772.

[2] Thèse de Paris, 1894.

CHAPTER XX.

DISABILITIES AND DEFORMITIES OF THE FOOT.

General Description of the Foot and of its Functions.

THE function of the foot is twofold: to serve as a passive support of the weight of the body, and as an active lever to raise and propel it. For the proper performance of these functions the foot is constructed to allow elasticity under pressure, and an alternation of attitudes under strain, that protect it from injury.

The Arches. The most noticeable peculiarity of the foot is the arrangement of its arches. As has been suggested by Ellis and others, the construction and shape of the arched part of the

FIG. 375.

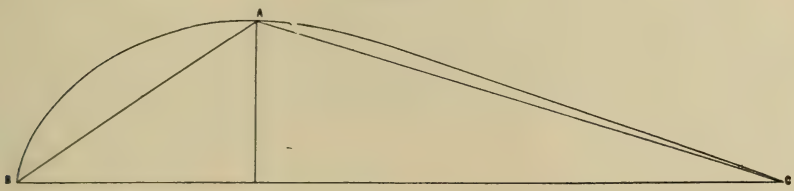

Longitudinal section of the cast of the arch at the point A in Fig. 376. A, the astragaloscaphoid junction; B, the internal tuberosity of the os calcis; C, the head of the first metatarsal bone.

foot may be better understood by considering it as half of the arch formed by the two feet. This complete arch may be demonstrated by making an imprint of the apposed feet in plaster of Paris. The plaster cast which represents it will appear in shape somewhat like an inverted saucer, the part of each foot that rests upon the ground forming half of an irregular ring. If the plaster cast is sawed into equal sections it will be seen that the highest or thickest part of each division is at the astragaloscaphoid junction; from this point the arch descends sharply to the tuberosities of the os calcis, and gradually to the outer border, beneath the cuboid bone, and to the metatarsophalangeal joints (Fig. 375). A cross-section of the cast will show the contour of what is sometimes called the *transverse arch* (Fig. 376), while the section through the long diameter will demonstrate the shape of the

longitudinal arch. In descriptions of the longitudinal arch it is often divided into two parts, of which the outer division is formed by the os calcis, the cuboid, and the two outer metatarsal bones. Of this outer arch, the highest point is at the calcaneocuboid articulation (Fig. 377), and although it is normally a permanent arch, yet the soft tissues are forced downward beneath it when

FIG. 376.

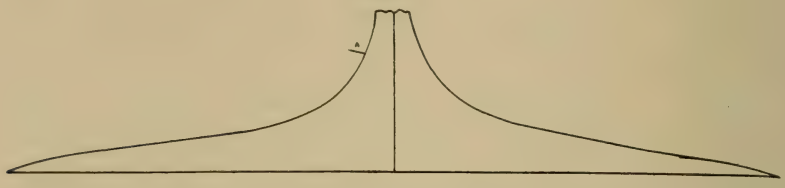

Cross-section of the cast of the arches of the apposed feet. A, the internal and inferior surface of the astragalonavicular junction.

weight is borne, so that the outer border of the foot makes an imprint throughout its entire length, as contrasted with the inner and deeper arch formed by the os calcis, the astragalus, the navicular, the cuneiform, and the three inner metatarsal bones (Fig. 378). This division, although an artificial one, is of some service in calling attention to the fact that the outer or lower

FIG. 377.

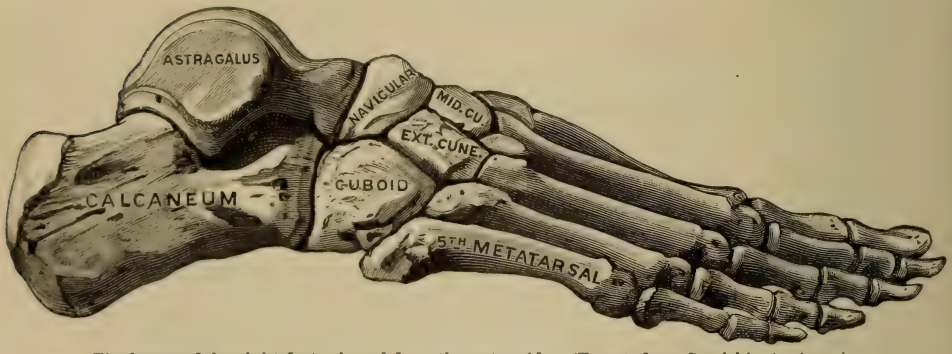

The bones of the right foot, viewed from the outer side. (Testut, from Gerrish's *Anatomy*.)

arch is more solidly braced, and, therefore, better adapted for continuous weight bearing than is the higher and more elastic inner arch.

The diagram of the longitudinal arch, showing its sharp descent from the highest point to the centre of the heel, indicates that the heel is well adapted for weight bearing, while the long anterior pillar composed of several bones is less strong but more

elastic; thus one instinctively extends the foot in descending stairs, for example, to avoid the unpleasant jar of direct shock received upon the heel. Of this anterior pillar, the third metatarsal bone is the most direct support, while the more movable first and fifth metatarsals, more under muscular control, aid in balancing the weight and sustaining it in the different attitudes.

Both divisions of the longitudinal arch are permanent arches, but there are two others which are obliterated under weight—one of these is that formed by the heads of the metatarsal bones, the *anterior metatarsal arch.* In the unweighted foot the second and third metatarsal bones occupy a higher plane than their fellows, but when the erect posture is assumed the anterior arch is depressed to allow all the metatarsal heads to bear their share of the weight. The other arch does not rest upon the ground, but

FIG. 378.

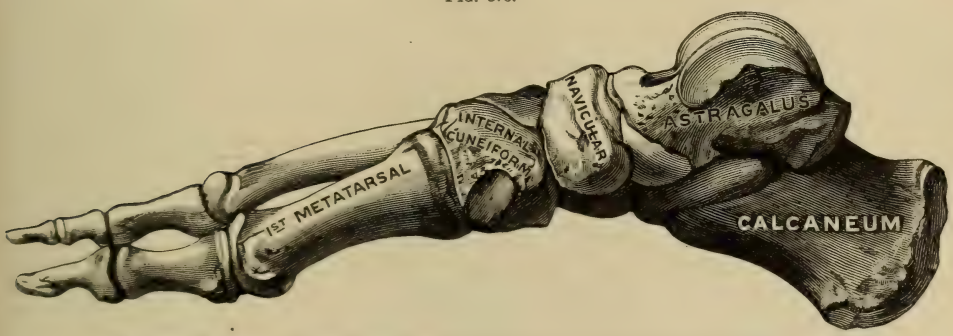

The bones of the right foot, viewed from the inner side. (Testut, from Gerrish's *Anatomy.*)

is formed by the internal border of the foot, which curves slightly outward, so that when the two feet are placed side by side an interval remains between them, widest at the highest point of the longitudinal arch, as is shown in the diagram by the upright section which divides the cast of the two soles from one another, the *internal arch* (Fig. 376). When the weight is borne this curved contour of the foot becomes straighter, or is obliterated, or is even transformed to an arch whose convexity is internal (Fig. 396).

The Foot as a Passive Support. The foot is supported by the muscles, by ligaments, and by the strong plantar fascia that covers in the sole. When the foot is actively used it is in great part supported by the muscles, but when it serves as a passive support, as in standing, the ligaments bear the greater part of the strain, and its normal elasticity allows the bearing surface to

expand slightly as the arches are slightly depressed. If this normal elasticity is diminished, as is sometimes the case, the supports of the arch are subjected to abnormal pressure and the individual may suffer from sensitive corns or calloused skin beneath the bones (Fig. 418). Or if the ligaments allow abnormal expansion the arches may become permanently depressed, and, as a result, the range of motion necessary to the proper functional use of the foot may be permanently restricted (Fig. 398).

When the statement is made that the foot broadens and that the arches are slightly depressed under weight, it must not be understood that the longitudinal arch is simply flattened by direct pressure and by elongation of elastic ligaments and fascia. Ligaments and fascia are not elastic in this sense, and they are not, in the normal foot, overstretched. The change in contour is the effect of normal motion in the joints of the foot, by which it is placed in the most favorable attitude for weight bearing without muscular exertion—the so-called attitude of rest.

Of the changes of contour that distinguish the foot used as a passive support from the one that bears no weight, the most significant is the obliteration of the outward curve of its internal border. This change is due to the fact that the astragalus, bearing the leg, rotates inward and downward on the os calcis until it is checked by the resistance of the ligaments and by the interlocking of the bones. The head of the astragalus thus becomes slightly prominent, the inner border of the foot is depressed, and an attitude is attained in which the weight of the body may be supported with but slight muscular exertion. In this attitude of rest, as von Meyer has explained, there is general fixation of joints of the lower extremity which makes support possible with the least muscular exertion. The pelvis tilts slightly backward until tension is brought upon the anterior part of the capsule of the hip-joint; the femur rotates slightly inward on the tibia, which in turn falls slightly inward upon the everted foot. To unlock the joints the pelvis must be tilted forward or the hip must be flexed.

The Foot in Activity. The second function of the foot is as a lever to raise and to propel the body. The calf muscles supply the power and the heads of the metatarsal bones serve as the fulcrum on which the weight is to be lifted. When the foot is used as a lever, it should be held in such relation to the leg that the line of weight, passing downward through the centre of the

knee and ankle-joints, is continued over the second toe or practically the centre of the foot. As the body is lifted over the fulcrum the leg is turned outward in its relation to the forefoot, because the inner side of the fulcrum, formed by the first metatarsal bone, is longer than its outer side; thus the strain is directed toward the outer and stronger side of the foot (Fig. 379).

In the proper walk, which is the best illustration of the leverage function, the feet should be held practically parallel to one another, so that the line of strain may fall through the centre of the foot. As one foot is advanced it first bears weight momentarily on the heel, then upon its outer border; the heel is then raised, and the body is lifted over the toes, the great toe giving the final impulse to the step, so that if the walker is looked at from behind he appears to be in-toeing at the termination of each step. Thus, during the walk, there is an alternation of postures, and the foot, under muscular control, assumes the attitudes most opposed to that of passive support.

Improper Postures. The alternation of postures and the leverage action of the foot are by no means necessary to simple progression; for example, both feet might be fixed in plaster bandages, yet walking would be possible, just as it is possible on two wooden legs. Indeed, an approximation to such a manner of walking is often seen, in which the feet are practically held in the passive attitude, the weight being borne upon the heels. Such a walk is necessarily jarring and ungraceful, and if it is not the result of weakness and deformity it predisposes to them because of the disuse of proper function.

One means of making the leverage function difficult is the custom of turning the feet outward. Outward rotation of the feet is normal in the passive attitude of weight bearing, because it enlarges the base of support, locks the joints, and throws the strain upon the ligaments to relieve the muscles. On this very account it is the improper attitude for activity because the strain falls upon the inner border of the foot, or to the inner side of the fulcrum, and makes the proper exercise of muscular power and alternation of postures impossible. In other words, the attitude, normal when the foot is used as a passive support, is abnormal when it is in active use.

The Movements of the Foot. The junction between the foot and the leg is made by means of the astragalus, a bone which is not intimately connected with either part, since it moves upon the leg and upon the foot, and to it no muscles are attached.

The primary movements of the foot are four in number—dorsal flexion, plantar flexion, adduction, abduction.

Simple dorsal and plantar flexion are confined to the ankle-joint, but complete plantar flexion is combined with slight adduction, and dorsal flexion with abduction, because the external facet of the astragalus allows a greater range of motion on the external malleolus than is permitted about the internal malleolus.

The range of motion at the ankle-joint is from sixty to eighty degrees; thus dorsal flexion to ten or twenty degrees less than

FIG. 379.

Illustrating the involuntary adduction of the forefoot, due to the obliquity of the bearing surface of the metatarsus, in the proper attitute for walking.

FIG. 380.

The improper attitude of outward rotation, in which there is disuse of the leverage function.

the right angle, and plantar flexion to fifty to sixty degrees more than the right angle (Figs. 381 and 382).

Adduction and abduction of the foot are carried out in the mediotarsal and subastragaloid joints.

Adduction, the motion of turning the foot inward in its relation to the leg, is always accompanied by inversion of the sole or supination, because of the shape of the joint surfaces between the astragalus and os calcis, where the greater part of the motion takes place. Simple adduction and abduction without supination or pronation is possible to a very limited extent in the medio-

tarsal joint. Its range may be tested by fixing the heel, when the forefoot may be moved slightly from side to side upon the astragalus and os calcis. The range of motion in the sub-astragaloid joint is twice as free as in the mediotarsal joint. The character of the motion between the astragalus and os calcis is rotation on an axis passing through the upper and inner part of the head of the astragalus, downward and outward to the outer tuberosity of the os calcis. Thus for all practical purposes adduction, inversion, and supination are synonymous terms, as are abduction, pronation, and eversion.

FIG. 381.

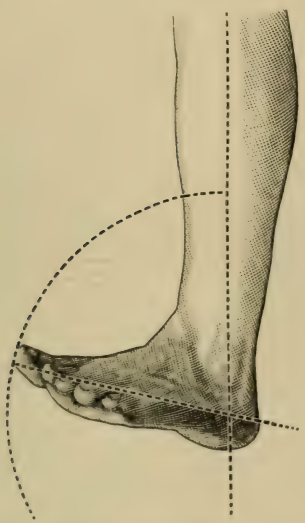

Voluntary dorsal flexion.

FIG. 382.

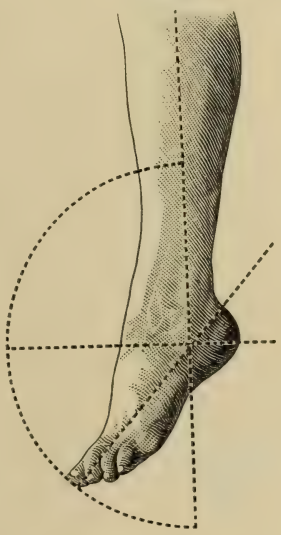

Voluntary plantar flexion.

In these attitudes the astragalus moves with the foot upon the leg bones, as contrasted with adduction and abduction, in which the centre of motion is below the astragalus.

In the movement of adduction of the foot the astragalus is fixed between the malleoli, and upon it the os calcis glides forward and its anterior extremity turns slightly inward; the sustentaculum tali moves backward, its inner superior surface is elevated, and its external surface is depressed. Meanwhile the forefoot, following the motion of the os calcis, is carried inward about the head of the astragalus; its inner border is elevated, and its outer border is depressed, so that the sole looks inward and downward. In this attitude all the arches are increased in depth (Fig. 383).

In abduction the bones move upon one another in the reverse

direction, the curves are lessened, and that of the inner border is obliterated (Fig. 384).

The extreme of adduction is only attained in the position of plantar flexion, because in this position the adduction possible at the ankle-joint, in part due to the contour of the astragalus and in part to the greater mobility allowed in the joint when the narrow posterior border of the astragalus is alone in contact with

FIG. 383.

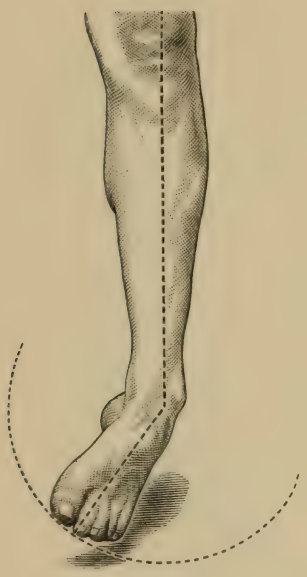

FIG. 384.

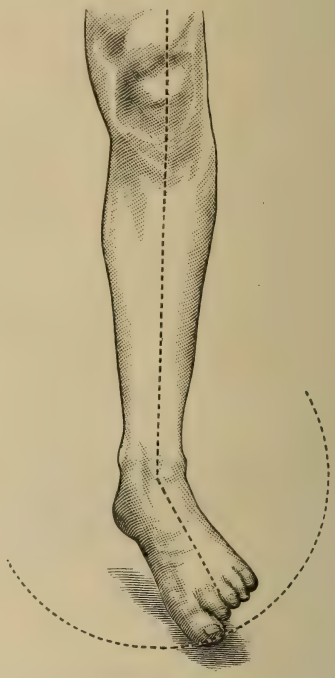

Voluntary adduction. Voluntary abduction.

In these postures the foot moves upon the astragalus, which is practically fixed between the malleoli. Adduction, the turning of the foot inward in its relation to the leg, is always accompanied by elevation of its inner and depression of its outer border. This is known as supination or inversion of the foot. The reverse of this attitude—pronation or eversion—is an accompaniment of abduction, as is illustrated in the figures.

the malleoli, is added to the adduction which the joints of the foot permit.

Extreme abduction is attained in the attitude of dorsal flexion, its extent being about one-half that of adduction; the entire range of motion between the two extremes being about forty-five degrees.

In this description the foot is considered as moving on the leg, but in the attitude of rest the foot becomes the fixed point

and the astragalus moves upon the os calcis in the manner and to the position already mentioned in the description of abduction—

FIG. 385.

Tibialis anterior of right side; outline and attachment areas. (Gerrish.)

FIG. 386.

Peroneus tertius of right side; outline and attachment areas. (Gerrish.)

The direct dorsal flexors.

i. e., it slips downward and forward and turns inward, and at the same time the anterior extremity of the os calcis turns slightly

Fig. 387.



The calf muscle.
Gastrocnemius of right side; outline and attachment areas. (Gerrish.)

Fig. 388.

The plantar flexor.
Soleus of right side; outline and attachment areas. (Gerrish.)

inward and downward, and its inner border is depressed. Corresponding to this movement, as the inner border of the foot

Fig. 389.

Peroneus longus of right side; outline and attachment areas. (Gerrish.)

Fig. 390.

Peroneus brevis of right side; outline and attachment areas. (Gerrish.)

The direct abductors.

becomes straight or bulges inward, the navicular is forced forward and downward and the longitudinal arch is depressed. As has

Fig. 391.

The most important adductor. Tibialis posterior of right side; outline and attachment areas. The most of the muscle is represented as if seen through the bones. (Gerrish.)

been mentioned, the turning of the leg inward and the corresponding turning of the foot outward in its relation to it locks in a manner the ankle-joint, and at the same time throws the strain upon the ligaments, so that standing in the erect posture is possible with but little muscular exertion (Fig. 396).

To put it in a simpler manner, the leg supporting the weight of the body has a tendency to tilt the foot over toward the inner side and to evert the sole; thus, under increasing superincumbent weight, the point of greatest pressure on the sole shifts from its centre and outer border toward the inner border. If, on the other hand, the body is raised upon the toes, the arch is relieved from strain and the weight falls upon the front and outer part of the foot. Plantar flexion and adduction represent, as contrasted with the passive attitude of supporting weight, the attitude of activity in which the foot is supported and controlled by the muscles.

The Function of the Muscles. The most important function of the dorsal flexors is to lift the foot as it is swung forward of the plantar flexors, to serve in the active propulsion of the body. The difference in function is shown by the relative strength of the two groups, the plantar flexors being five times the stronger; in fact, the calf muscle (gastrocnemius and soleus) alone is three times as strong as all the other muscles of the foot combined. It is practically the leverage muscle, the others serving more especially to fix and to hold the forefoot, or fulcrum, in its proper relation to the leg. It is also a powerful adductor and supinator of the foot in the attitude of plantar flexion (Figs. 387 and 388).

The muscles that most directly support the inner arch of the foot are the tibialis

posticus and tibialis anticus, whose tendons meet in their insertions in front of the astragalus in the form of a V. The tibialis anticus supports the internal border of the foot from above, and is the direct supinator of the foot in dorsal flexion —that is, if unopposed it elevates the inner border of the foot, when it acts as a dorsiflexor. The tibialis posticus is the most powerful adductor (Figs. 385 and 391). The extensor longus hallucis is an adjunct of the tibialis anticus in its action on the foot as a whole. The extensor longus digitorum, including the peroneus tertius, is a dorsal flexor and abductor.

The flexor longus hallucis, passing directly beneath the sustentaculum tali, aids in supporting the weak part of the foot and its position demonstrates the importance of the proper functional use of the great toe (Fig. 395).

The peroneus longus and brevis support the outer arch, and the former binds the foot together and holds the great toe firmly against the ground; thus it indirectly supports the longitudinal arch against direct pressure (Figs. 389 and 390). They also serve as abductors and pronators.

The relative strength of the muscles and their functions is shown in the following tables:[1]

DORSAL FLEXORS OF THE FOOT; STRENGTH RECKONED IN KILOGRAMMETRES.

Tibialis anticus	0.871
Extensor longus digitorum	0.280
Extensor longus pollicis	0.155
Peroneus tertius	0.087
	1.393

PLANTAR FLEXORS.

The calf muscle.	Soleus	3.256
	Gastrocnemius	2.831
	Flexor longus pollicis	0.218
	Peroneus longus	0.118
	Tibialis posticus	0.094
	Flexor longus digitorum	0.078
	Peroneus brevis	0.055
		6.650

RELATIVE STRENGTH OF THE SUPINATORS OF THE SUBASTRAGALOID JOINT.

	Strength.	*Weight of the muscles.*
Soleus	1.021	157.0 grammes.
Gastrocnemius	0.709	120.0 "
Tibialis posticus	0.337	39.6 "
Flexor longus pollicis	0.172	33.2 "
Flexor longus digitorum	0.123	12.3 "
	2.362	362.1 "

[1] Ueber die Arbeitsleistung der auf die Fussgelenke Wirkenden Muskeln, R. Fick, Leipzig, 1892.

RELATIVE STRENGTH OF THE PRONATORS OF THE SUBASTRAGALOID JOINT.

	Strength.	*Weight of the muscles.*
Peroneus longus	0.282	24.0 grammes.
Peroneus brevis	0.192	16.5 "
Extensor longus digitorum	0.164	18.2 "
Peroneus tertius	0.067	3.5 "
Extensor longus pollicis	0.045	12.3 "
Tibialis anticus	0 021	49.2 "
	0.771	123.7 "

RELATIVE STRENGTH OF THE SUPINATORS OF THE MEDIOTARSAL JOINT.

Tibialis anticus	0.238
Tibialis posticus	0.078
Flexor longus pollicis	0.034
Flexor longus digitorum	0.033
Extensor longus pollicis	0.030
	0.413

RELATIVE STRENGTH OF THE PRONATORS OF THE MEDIOTARSAL JOINT.

Peroneus longus	0.162
Peroneus brevis	0.090
Extensor longus digitorum	0.085
Peroneus tertius	0.033
	0.370

It will be noticed that the strength of the pronators and supinators (abductors and adductors) of the mediotarsal joint is nearly equal, and that the great preponderance of power of the supinators of the subastragaloid joint is owing to the fact that the calf muscle is a supinator. When the foot is at a right angle with the leg, the power of the calf muscle not being utilized, the pronators are stronger than the supinators. It will be noticed, also, that the tibialis anticus muscle, which supinates the mediotarsal joint, is reckoned among the pronators of the subastragaloid joint.

The Foot Considered as a Mechanism. In the study of the deformities, and particularly of the functional weaknesses of the foot, one must never lose sight of the fact that it is a mechanism, subject to mechanical laws, and that its deformities and disabilities, its relative strength or weakness, may be best appreciated by comparing it with the normal standard. As in other machines, marked deformity or distortion is evident at a glance, even though the apparatus is not in use, but functional ability can be judged only by the manner in which active work is performed.

As has been stated, the foot is, in activity, a lever, by means of which the weight of the body is lifted and propelled. If it is loosely constructed or insufficiently supported by the ligaments, it is evident that it cannot be properly controlled by the muscles. If, on the other hand, the muscular power is insufficient, it is

evident, also, that the weight of the body cannot be lifted and properly balanced upon it. The structure of the foot may be

FIG. 392.

Extensor proprius hallucis of right side; outline and attachment areas. (Gerrish.)

FIG. 393.

Extensor longus digitorum of right side; outline and attachment areas. (Gerrish.

normal, and its muscles may be of normal strength, yet the strain placed upon it may be disproportionately great. The strain may be overweight of body, or the overwork of a laborious occupation,

FIG. 394.

Flexor longus digitorum of right side; outline and attachment areas. The muscle is represented as seen from in front through the bones. (Gerrish.)

FIG. 395.

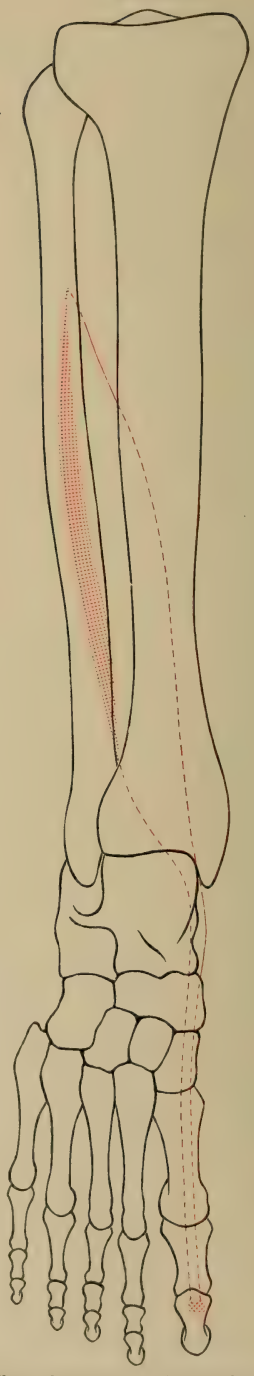

Flexor longus hallucis of right side; outline and attachment areas. The muscle is represented as seen from the front through the bones. (Gerrish.)

but more often the machine is overworked simply because it is subjected to mechanical disadvantages in the performance of its functions, by the assumption of improper attitudes.

One of the most common of such attitudes is, as has been mentioned, that of turning the feet outward in walking; for as the fulcrum is displaced outward, the strain falls through the inner and weaker side of the foot. As a consequence of the improper attitude there is usually, to a greater or less degree, dis-

FIG. 396.

An attitude that simulates the flat-foot. (See Fig. 397.)

FIG. 397.

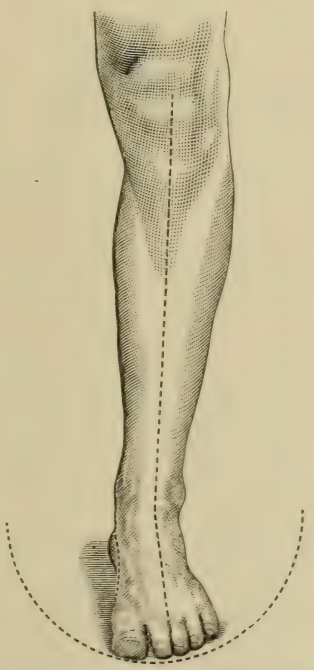

Fig. 397, compared with Fig. 396, illustrates the voluntary protection of the foot from overstrain.

use of the active leverage function of the foot; the active lift of the calf muscle is replaced by exaggerated flexion at the knee, the foot being used somewhat as if it were a movable pedestal (Fig. 380).

This disuse of the active attitudes may be unnecessary, just as the outward rotation of the feet with which it is associated is a habit, a habit that is often the result of improper teaching. On the other hand, the habitual assumption of the passive attitude

may be induced by injury or disease of the foot, or by corns or bunions, or by improper shoes. Under such conditions the strain of the leverage function increases the discomfort; consequently it is discontinued. It must not be inferred that such improper attitudes lead directly to weakness and discomfort, for in most instances an ungraceful carriage and gait are the only ill effects. The improper attitudes must, however, lessen the power and resistance of the foot, and they must be reckoned, therefore, among the predisposing causes of disability and deformity.

FIG. 398.

Typical "flat-foot" of moderate degree, illustrating the component elements of abduction and depression of the arch.

The passive attitude, it will be remembered, is the attitude of rest, in which the ligaments bear the greater part of the strain and in which the arches of the foot are depressed or obliterated.

The Weak Foot.

Synonyms. Splay-foot, flat-foot.

The introductory pages lead naturally to the consideration of the most important of the acquired disabilities of the foot, a disability whose most important characteristic in the mildest and in the most advanced type is the *persistence of the passive attitude*, or an approximation to it, in place of active motion and alternation of posture. Disuse of function is followed by restriction of motion, particularly in the range of adduction and plantar flexion, and finally by persistent deformity, a deformity which is simply an exaggeration of the normal posture assumed when the foot supports weight (Fig. 396). This is the so-called flat-foot (Fig. 398). At first glance it may seem that the depression of the arch is the most noticeable peculiarity in a well-marked case of flat-foot, and that the popular name is, therefore, an appropriate one, but on closer examination it will be evident that the normal relation between the leg and the foot is changed. This change, which, from the functional standpoint, is of far greater importance than the depth of the arch, may be analyzed as follows :

Anatomy. 1. The leg is displaced inward, so that the weight falls upon the inner side of the foot. 2. The leg is rotated

inward, so that a line drawn through its centre, prolonged from the crest of the tibia, instead of falling over the second toe now points inside the great toe, or even over the centre of the internal border of the foot (Figs. 398 and 401).

It has been stated that under normal conditions, in the act of passive weight bearing, the astragalus rotates downward and inward upon the os calcis, depressing its anterior and internal border until the movement is checked by the strong ligaments connecting the bones, the calcaneonavicular, the deltoid, and the interosseus; in other words, the leg has a tendency to slip downward and inward from off the foot. In the weak foot this inclination has become an accomplished fact, for the normal movement has become so exaggerated by the distention of the ligaments and by the weakness of the supporting muscles that an actual subluxation is present. The astragalus has rotated and

FIG. 399.

The relation of the astragalus to the os calcis.

FIG. 400.

The relation of the astragalus and os calcis in flat-foot.

slipped far to the inner side of its normal position, to an attitude of exaggerated rotation and plantar flexion, so that its head can be plainly felt on the internal border of the foot. The anterior extremity of the os calcis is depressed and is turned slightly inward and its internal border is lowered (Fig. 400).

The navicular bone has been depressed with the head of the astragalus, although to a less degree, it has been forced further away from the os calcis, and the entire inner border of the foot is lowered. Thus the depression of the arch is always accompanied and preceded by a bulging inward of the inner side of the foot.

The typical flat-foot is, as it were, broken in the centre (Fig. 398), the posterior division having turned inward and downward, while the forefoot is forced downward and outward. The dislocation may be so extreme that the entire sole of the foot rests

upon the ground, and a callus even may be found at the point that usually represents the highest point of the arch, which now supports the greatest burden.

In this change of relation between the bones the arched part of the foot or waist appears much broader than normal, even broader than the front of the foot; the heel projects, the external malleolus is depressed and carried forward by the rotation of the leg, and is much less prominent than normal; the internal malleolus is more prominent, and with the astragalus it overhangs the bearing surface of the sole. The entire mechanism is twisted and out of gear; its motion is, therefore, very much restricted. It is manifestly impossible for the patient to adduct the forefoot — that is, to turn it inward about the head of the displaced astragalus. Plantar flexion is also much limited, because of the persistent adduction and plantar flexion of the astragalus. Dorsal flexion, on the other hand, although it is actually restricted, may appear to be abnormally free, because the forefoot is abducted and slightly dorsiflexed upon the head of the astragalus (Fig. 398).

Fig. 401.

Weak feet, showing the inward rotation of the legs when the abducted feet are placed side by side.

The disability and its accompanying deformity are found in every grade of severity. Pain begins when, the support of the muscles being insufficient, the ligaments begin to give way under strain, allowing the bones to occupy an abnormal relation to one another. It is evident, therefore, that the individual in whose foot the arch is well formed and whose ligaments are firm, will suffer from the symptoms of strain long before the arch has been depressed or deformity has become apparent; also, that the lateral inward bulging, characteristic of advancing deformity, must be

very great before the arch is completely flattened. In this type the prominent deformity is lateral displacement (valgus). On the other hand, if the individual has inherited a low arch, as is characteristic of certain races, or if, as the result of weakness in early life, the arch has been depressed or has never formed, accommodative changes in the bones will have taken place during growth, so that the flat-foot of this type will not be attended with as much change in its relation to the leg, and, therefore, disturbance of function, as in the typical case that has been described. This latter class of cases exemplifies the popular type of flat-foot that may exist without pain or disability, and in which the most noticeable peculiarity is the obliteration of the arch (planus). (Contrast Figs. 402 and 404.)

In certain instances abnormal laxity of ligaments allows deformity of the valgus type when weight is borne, yet the foot, controlled by efficient muscles, may be apparently normal in functional ability, while in other cases in which the ligaments are normal and yet are subjected by insufficient muscular protection to overstrain, disability and pain may precede noticeable deformity.

Fig. 402.

Weak feet, arch not depressed.

It is evident that the lowering of the arch is of secondary importance in the deformity, andthat the popular significance of painful flat-foot, as an inherited and irremediable weakness, is most misleading. Yet it seems to have governed the treatment of the disability until very recently. On the one hand, the early cases were overlooked because the foot was not flat, while those in which the deformity was more advanced were simply neglected or were treated by simple supports beneath the arch or by operation, without regard to the loss of function, and, therefore, without hope of ultimate cure.

As has been stated, there is one feature common to every grade of the so-called flat-foot: the foot regarded as a machine is

weak as compared to the normal standard—weak because of the persistence of the attitude of rest and relaxation, as contrasted with that of activity and strength, and weak because the proper relation between the power and the fulcrum is changed. Even the inherited flat-foot or the flat-foot which has never caused symptoms is weak in the sense that, in use, it lacks the spring and elasticity characteristic of the perfect machine. The term weak foot may be used, then, to indicate all types of the disability.

In one weak foot the arch has disappeared (Fig. 398); in another weak foot the arch is of normal depth, but the foot is abducted or pronated in its relation to the leg (Fig. 397). In one case the deformity appears only under weight; in another the foot is held rigidly in the deformed position by muscular spasm. In one instance there may be great deformity without pain; and in another disabling weakness and pain without noticeable deformity. In one case the foot is unable to perform its functions because of its inherent weakness; in another the disability may be due simply to the improper use of a normal structure.

Pathology. Supposing the foot to have been normal before it began to break down, it is evident that persistent deformity could not have been acquired without marked changes in its internal structure. In a general way these changes have been indicated already. The ligaments on the internal aspect of the foot and of the ankle-joint are weak and distended; the unused portions of the articular surfaces of the joints may be denuded of cartilage, while new facets may have formed to accommodate the changed relations of the bones. For example, the external malleolus may be in direct contact with the os calcis; evidences of injury and of abnormal pressure may be found in the thickened periosteum, in formation of osteophytes, while the internal structure of the bones has been changed in adaptation to the new conditions. The muscles which are no longer used in the leverage function, the plantar flexors and adductors, have become atrophied, a change that is made evident by the shrunken calf. The muscles on the inner border of the foot have been overstretched, while those on the upper and outer part have become shortened and contracted. Such a foot represents an extreme, it may be an irremediable degree of deformity; but in by far the greater proportion of the cases the pathological changes have not advanced to a stage that interferes with successful treatment.

Etiology. In all cases the actual symptoms of pain and disability are due to a disproportion between the burden or strain and the ability of the machine to perform it.

This theory accounts for the fact that the weak foot, although very common in childhood, does not, as a rule, cause troublesome symptoms until adolescence, when the weight and strain put upon it are increased. It explains why the foot, which may be fairly normal in structure, breaks down often in later adolescence or early adult life when the continuous strain of regular occupation is undertaken. It is evident, also, that an occupation that induces a persistence of the passive attitude, that of waiters, cooks, and bartenders, for example, exposes the feet to greater strain than one which encourages alternation of postures. And that the symptoms are likely to be more severe and the deformity to be greater among those who are obliged to labor than among those who are not. Overwork or strain, of occupation or otherwise, may be temporarily disproportionate because of general weakness, as, for example, during pregnancy or after recovery from exhausting disease; or because of local injury or disease of the foot itself which weakens it directly or induces improper attitudes. On this theory one may very easily explain what has proved such a stumbling-block for students, viz., that there is no constant relation between the degree of deformity and the severity of the symptoms, for, although all flat-feet are mechanically weak, yet all weak feet are not necessarily painful feet. Pain is not caused because the foot is flat; it is a symptom of progressive deformity and of strain and injury to the joints. The progress of the deformity may be temporarily or permanently checked at any stage, either by removal of the exciting cause or because of the resistance of the tissues; then the pain intermits or ceases.

This conception of the foot as a mechanism, of which grades of efficiency may be recognized, has a great advantage, since it enables one to perceive wherein a foot is weak, even though the weakness causes no symptoms whatever, and thus to prevent discomfort and deformity by a recognition of its predisposing causes. Finally from this standpoint one cannot fail to appreciate the importance of improper shoes in the etiology of this and of all forms of acquired weakness of the feet, a subject to which special attention will be called in another section.

Statistics. A brief analysis of 1000 cases of so-called flat-foot treated at the Hospital for Ruptured and Crippled will represent fairly the points of general interest in this class of cases:

THE AGE AND SEX OF THE PATIENTS.

Age.	*Males.*	*Females.*	*Total.*
Ten years or less	68	30	98
Ten to fifteen	112	87	199
Fifteen to twenty	144	83	227
Twenty to twenty-five	94	53	147
Twenty-five to thirty	68	41	109
More than thirty	132	88	220
	618	382	1000

Foot affected: right, 133; left, 138; both, 729.

In 58 cases the cause of the disability appeared to be injury, and in 65 instances it was, apparently, due to rheumatism or to rheumatoid arthritis. The symptoms usually appear first in one foot, and, as a rule, they are at all times more marked on one side. Of 569 instances, in which the duration of symptoms was recorded, it was six months or less in 409.

The age of the patients is of interest as bearing on the question of prognosis; 426 were between ten and twenty years of age, and 780 were less than thirty.

Hospital statistics cannot adequately represent the subject, for, as a rule, it is because of disability and pain that these patients apply for treatment. In the larger proportion of the cases recorded muscular spasm and rigidity were present, in 234 instances to such a degree that forcible overcorrection was advised—an operation rarely necessary in private practice.

It is in childhood that the prevention of subsequent weakness and deformity is of the first importance, yet but 98 children of ten years of age or less are recorded, and many of these were brought, not for weakness or deformity, but for treatment of the symptomatic in-toeing.

Symptoms. As has been stated, the symptoms of the weak foot, although similar in type, vary in severity according to the local condition and the disturbance of function, the work to be performed, and the susceptibility of the individual. The earliest symptom is usually a sensation of weakness; the patient begins to recognize as familiar a feeling of discomfort, of tire and strain about the inner side of the foot and ankle; sometimes after long standing a dull ache in the calf of the leg or pain at the knee, hip, or in the lumbar region, symptoms more common in women than in men; or after overexertion a momentary sharp pain radiating from the point of weakness; thus the patient often dates the history of his trouble from a long walk or other form of overwork. After a time the patient may become aware that he is accommodating his habits to his feet; he rides when he once walked; he

sits when he once stood; he no longer runs up or down stairs or jumps off the street-car. His feet have lost their spring, as he expresses it, which means that the foot is no longer supported and controlled by muscular activity and is no longer used as a lever. Not infrequently early symptoms are pain and tenderness at the centre of the heel, explained in part by the jarring heel walk which is always assumed when the foot is weak, and in part by the strain upon the attachments of the deep plantar ligaments. The patient may complain that he cannot buy comfortable shoes; the reason is that the weak foot under use is changed in shape, so that the shoe that was comfortable in the morning compresses the foot painfully at night; thus increasing discomfort from corns, bunions, painful great toe-joints, and deformities of the toes is experienced. Coldness and numbness, congestion and increased perspiration, caused by the impaired circulation and weakness, are common symptoms in this class of cases. Actual pain is, as a rule, felt only when the foot is in use; it ceases under temporary rest or relief from disproportionate work, and it is this remittance of symptoms, together with the fact that the discomfort is usually more marked in damp weather, that leads so often to the mistaken diagnosis of rheumatism. The foot is weak and vulnerable; the patient recognizes the fact that he has what he speaks of as a weak ankle, or sprain, or gout, or rheumatism, but if he has accommodated himself to the weakness but little discomfort is experienced. In many instances such relief or accommodation is impossible, and it is, therefore, among the working class that one oftener sees the frank and rapid development of the disability and deformity. The range of motion becomes more and more restricted; the habitual attitude, at first exaggerated to deformity only under the influence of the weight of the body, remains as a permanent displacement of the bones. The weak and dislocated foot is subjected to constant injury, to what may be likened to a succession of slight sprains, so that local congestion, tenderness, and swelling may appear together with muscular spasm, rigidity, and pain on passive motion. Because of this rigidity of the foot, which has lost the power to accommodate itself to inequalities of the surface, the patient dreads to cross a rough pavement, for every misstep is a source of pain. Another symptom, the discomfort felt in changing from a position of rest to activity, which is usually present in slight degree at every stage, now becomes more prominent. The patient, after sitting or on rising in the morning, is unable to walk, but staggers or limps for

several minutes, a symptom explained by the fact that when the foot is at rest there is a partial reposition of the displaced bones, which must again be forced into the deformed posture that has become habitual. The local tenderness and muscular spasm are increased by use, so that the patient may have difficulty in removing the shoe at night, and the symptoms relieved by the rest of Sunday become progressively worse during the week. The pain and discomfort are more general in character, and are often referred to the dorsum of the foot, representing muscular rigidity and tension, and to the ankle where the external malleolus is grinding out a facet in the projecting os calcis. The patient may now complain of discomfort in the feet and cramps in the legs, even when in bed, and the appearance of weakness, awkwardness, and depression of spirits may be so noticeable that the case is sometimes mistaken for serious disease of the nervous system.

The appearance of such a foot has already been described, and the effect of the deformity on its functions should be evident. The gait is slouchy and cloddy, what has been spoken of as the pedestal walk; the feet are simply pushed by one another, in the attitude of eversion, the knees are slightly flexed and the weight is borne entirely upon the posterior segment of the foot. The muscles have atrophied, the foot is cold and congested from its continued inactivity, and it is usually bathed in perspiration. A certain range of motion remains at the ankle-joint, but adduction is absolutely restricted by the shortened and spasmodically contracted muscles on the outer and upper surface. This type represents, of course, only the severe variety that is more likely to be seen in hospital than in private practice; and it would seem, were it not for the evidence to the contrary which the histories of the patient present, that the nature of the trouble must be recognized at a glance. But in the milder and earlier cases the diagnosis is not always so easily made.

Diagnosis. In all cases of suspected weakness of the foot a thorough and orderly examination should be made, not only of its appearance, but also of its functional ability and of the manner in which it is used. Such an examination is not merely for the purpose of diagnosis, which is usually apparent, but in order that the amount and character of the temporary or permanent changes in structure and function may be properly estimated.

Attitudes. One begins the examination by noting the manner of standing and walking. The heel walk, the exaggerated turn-

ing out of the feet, the slouchy gait in which the leg is never completely extended, in which the power of the calf muscle is not applied, and in which the essential postures of the foot are disused, are all elements of weakness that should be corrected whether they cause symptoms or not.

Distribution of Weight and Strain. The distribution of the weight of the body and the habitual use of the foot are often made evident by examining the worn shoe. If it is bulged inward at the arch or worn away on the inner side of the sole it shows weakness (Fig. 405). The same observations are then made on the bare feet, particular attention being paid to the line of strain or leverage; thus a line drawn down to the crest of the tibia from the centre of the patella, continued over the foot, should meet the interval between the second and third toes; if it falls over or inside the great toe, it shows that the foot is working at a disadvantage (Fig. 401).

Contour. The contour of the foot should then be examined; its internal border should curve slightly outward, so that if the feet are placed side by side with the toes and heels in apposition a slight interval remains between them; if this slight concavity is replaced by a noticeable convexity when weight is borne the foot is weak (Fig. 402). This change in contour is the earliest and sometimes the only evidence of deformity. The arch of the foot, properly protected by the muscles and by a proper attitude, sinks but slightly under weight; there is a slight elasticity only, as the strain is thrown more to the inner side of the median line, and if the depression is marked it shows weakness.

Bearing Surface. The exact amount of bearing surface may be shown by an imprint upon carbon paper or by smearing the sole with vaseline; then, as the patient stands upon a sheet of white paper, the outline of the foot should be traced so that the relative size of the imprint to that of the foot may be shown and compared with the normal standard.

Another method is that suggested by Lovett. The patient stands upon a square of plate glass fixed in a table, so that by means of a mirror beneath the bearing surface may be examined under different degrees of pressure and in different attitudes (Fig. 407).

The Range of Motion. The balance of the foot, as shown by the range of motion, is next to be tested, for its limitation is one of the earliest signs of improper attitudes and of weakness. This range of motion varies somewhat within normal limits; it is

usually greater in childhood than in adult life, greater in the slender than in the massive foot, and greater in the foot used properly than in one that is not. The first test is applied to simple dorsal and plantar flexion; the leg must be fully extended at the knee; the line of strain must be in its normal relation, so that the foot may be neither adducted nor abducted, and the observation must be made on its outer border.

In this position the patient should be able to flex the foot from ten to twenty degrees less than the right angle, and to extend it from forty to fifty degrees beyond the right angle, the range of motion being from fifty to sixty degrees (Figs. 381 and 382).

By far the most important test is that of the power of adduction or inversion of the foot, the test of the mediotarsal and subastragaloid joints, a motion in which the os calcis is drawn forward and inward under the astragalus, while the forefoot is flexed about its head. With the leg extended and the patella in the median line the foot is turned inward as far as possible; the elevation of its inner border or supination and the turning in of the heel are well illustrated in Fig. 383; the actual range of adduction is somewhat difficult to measure, but it is about thirty degrees. Even the mild and early cases of weak foot usually show some limitation of this most important motion, and in many instances it is completely lost, the patient turning the entire leg in the effort to adduct the foot. The less important motion of abduction may be tested also (Fig. 384); its range is about half that of adduction, so, also, the range of supination or inversion of the sole is nearly twice as great as that of pronation or eversion of the sole. In other words, the internal border of the foot can be raised twice as far from the floor as can the external border. The range of passive motion is then tested by pushing the foot in all directions. The range of dorsal flexion is from five to ten degrees beyond that of voluntary motion, while passive extension, so far as it applies to the ankle-joint, is about the same as the voluntary, although the forefoot may be still farther bent downward at the mediotarsal joint. The limit of passive adduction is considerably beyond that of voluntary inversion.[1]

Passive motion serves several purposes; contrasted with the

[1] As adduction and supination and abduction and pronation are always combined, one term is used to signify the movement inward or outward; thus, supination means adduction; abduction implies pronation. A fixed attitude of adduction and supination is called varus; a fixed attitude of abduction and pronation is called valgus. Varus and valgus signify, therefore, deformity. Thus the term valgus, although it may be properly applied to designate the deformity of weak foot, is usually reserved for the more extreme distortion of talipes. (See Figs. 383 and 384.)

range of voluntary motion it shows the habitual use of the foot, since the motion least used is most limited. It also makes evident the slight restriction of motion and the presence of local tenderness, which, even in early cases, are usually present. Thus, if pressure is made just in front of and below the internal malleolus, at the astragalonavicular junction, and if at the same time the foot is forcibly adducted, the patient will complain of pain at the point of pressure and of a feeling of constriction and tension about the dorsum of the foot before the normal limit of motion is reached. When the foot is dorsiflexed the plantar fascia is put upon the stretch, and its condition may be noted, for a contracted and sensitive plantar fascia may cause sufficient discomfort to induce improper attitudes and thus it may predispose to further disability.

Varieties. This mode of examination will demonstrate the disability, and the secondary changes in the mechanism, which must be overcome before a cure can be accomplished. By it one will learn to recognize several grades of weak foot:

1. The normal foot improperly used, as shown by the manner of standing and walking (Fig. 375).

2. The foot, which because of laxity of ligaments or insufficient muscular support, is forced by the weight of the body into an attitude of deformity; that is, in which the foot under weight falls into an abnormal attitude of abduction in its relation to the leg, as evidenced by the inward projection of its inner border and by the overhanging internal malleolus, showing that the leg has been displaced inward on the foot. As a rule, there is sufficient laxity of ligaments to allow a depression of the arch, as shown by the imprint, but in other instances, although the arch seems lower because of the characteristic attitude of pronation, in which the leg, as it were, overhangs the foot, yet the imprint shows that there is no increase in the area of bearing surface. Indeed, if the eversion is sufficient to raise the outer border of the foot, this may be even smaller than normal; thus, an individual may suffer from so-called flat-foot whose arch is actually exaggerated (Fig. 397).

3. The weak foot, which shows typical deformity under use and in which the range of voluntary motion is somewhat limited, particularly in the direction of plantar flexion and adduction. Forced motion causes discomfort and pain, indicating a certain permanent accommodative change in structure, which is not apparent when the foot is not in use (Fig. 396).

4. The foot which presents typical and permanent deformity,

whether it is in use or not, and in which the range of both voluntary and passive motion is much restricted. In all of these varieties the improper functional use of the foot, particularly the loss of active leverage, is very evident when the patient walks (Fig. 405).

Limitation of Motion and Muscular Spasm. Limitation of motion is caused by the accommodative changes in structure to the habitual postures or to the deformity. These are first evident in the muscles and ligaments, and, finally, in the articular surfaces of the bones. Added to this underlying limitation of motion there is usually a certain degree of muscular spasm, which varies in degree with the local congestion, irritation, and inflammation of the joints and tissues. In the quiescent flat-foot it may be absent, but on renewed injury or overwork of the weak structure it again appears. It depends also upon the irritable condition of the overworked and contracted abductor muscles, practically the only group which retains functional power; thus the spasm, as has been stated in describing the severe and painful type of weak foot, is greater after the day's use and relaxes somewhat during the night. The degree of muscular spasm and rigidity corresponds with the intensity of the symptoms, but by no means with the depression of the arch or with the duration of the deformity.

Extreme Types of Weak Foot. 1. **Persistent Abduction.** In one type of deformity the foot is twisted outward and upward. It may be everted to such an extent that practically the weight is borne upon the heel and the ball of the great toe. In such instances the astragalus, although rotated inward upon the pronated os calcis, is, of course, not plantar flexed nor is the anterior extremity of the os calcis depressed. The entire foot is simply held in an attitude of extreme abduction and dorsal flexion by the spasm and contraction of the flexors and abductors, so that the leg must be bent at the knee and inclined forward to bring the sole to the ground. Such extreme cases are uncommon. They are often the direct result of injury, so-called chronic sprain. Less extreme examples of this class are very common. The foot is simply turned to one side (valgus) and the arch appears to be depressed because of the attitude, whereas it may be in reality exaggerated in depth.

2. **Pes Planus.** As has been stated already, and as is well-known, there is a type of painless flat-foot sometimes called pes planus, in which the flatness of the foot is more noticeable than the other components of the deformity that have been described. This is probably the result of inherited laxity of ligaments or of

rhachitis or other form of acquired weakness in early life, so that a normal arch was never present. Such a foot controlled by normal muscles may be strong and efficient, but it is, nevertheless, deformed, and it is doubtful if its possessor ever could attain the grace and elasticity of gait possible under normal conditions. It is said, also, that a low arch is normal in certain races, for example, the negro, but it is certain that the American negro is not exempt from the pain and disability incidental to the broken-down foot, whether his arch was originally low or not.

It is evident, of course, that the breaking down of a properly shaped foot, provided with normal ligaments, will be attended

FIG. 403.

Weak feet and slight knock-knees.

by greater pain and greater disability than of one in which the arch was originally low and of which the ligaments were weak, because it is during the progression of the deformity and particularly in its early stages that such symptoms are most prominent. When the bones of the arch rest upon the ground or when final stability has become assured, pain may cease, and permanent accommodation to the new conditions may increase the ability of the deformed member. Such an outcome might be quickly accomplished in the foot originally flat, while in the other instance

the symptoms, although remitting from time to time, might continue during the life of the sufferer.

The abducted foot, in which there is no depression of the arch, and the simple flat-foot, in which the element of abduction is less prominent, represent the two extremes of weak foot. In the majority of cases the abduction is combined with a certain laxity of the supports of the longitudinal arch as well.

One may recognize, then, in the weak foot three types of deformity:

1. Valgus, or abduction.
2. Valgoplanus, or abduction and depression.
3. Planus, or depression.

This distinction is of some importance from the standpoint of prognosis at least in the adolescent and adult cases, as the prospect of anatomical cure corresponds with the order of classification.

Weak Foot in Childhood.

There can be no doubt that in many instances the origin of the weak foot may be traced to early childhood. Certainly, deformities and improper attitudes are very common at this period, and it is much more likely that they are ingrown than outgrown. Actual pain from the weak foot is rare at this age. The child may complain of fatigue and may be weak and awkward, but it is usually because of the very evident deformity rather than because of symptoms that advice is asked. In these cases, as in every case, the habitual attitudes and use of the feet are of the first importance.

Out-toeing and In-toeing as Symptoms of the Weak Foot in Childhood. One of the most frequent of the improper postures is that of exaggerated outward rotation of the feet, which is not only an ungraceful attitude, but a direct cause of weakness as well. The opposite attitude of inward rotation, the so-called "pigeon-toed" walk, is most offensive to relatives and friends, and it is for correction of the attitude that the child may be brought for treatment. The attitude is, in many instances, a sign of the weak foot, for on examination the bulging on the inner side, the inward rotation of the leg in its relation to the foot, and the depressed arch show very plainly that it is the foot and not the attitude that requires treatment; in fact, the attitude is, in this class of cases, really a safeguard against increasing deformity, and it will correct itself when its cause is removed. Particular emphasis is

laid upon this point, which is very generally overlooked, because the routine treatment of the "pigeon-toes" in these cases might be the cause of direct harm.

Weak Ankles. "Weak ankle" is a term popularly applied to the weak foot of childhood, in which the foot is in a position of valgus when in use, so that the shoe is worn away on its inner side. Weak ankles are very common in very young children and are often one of the results of general weakness due to defective assimilation. At this age the foot is, in addition, usually flat (Fig. 403), but in the valgus or weak ankle of later years the arch is often practically normal in outline.

FIG. 404.

Congenital flat-foot. Rigid deformity of an extreme type, illustrating the component abduction and obliteration of the arch.

Outgrown Joints. In older children prominent or "outgrown" joints often attract the mother's attention; the internal malleoli appear prominent because of the position of valgus, or because of the turning out of the feet the malleoli may strike against one another, "interfere," and thus there may be an actual hypertrophy of the projecting bones from local irritation.

Another type is the long, slender foot, in which the navicular is prominent because of the strain and pressure put upon it by the improper attitudes; its position is often shown by the point of wear in the leather of the shoe (Fig. 402).

In the weak foot of childhood, although restriction of voluntary

and passive motion may be present, there are, as a rule, but little local tenderness and muscular spasm, and, as has been said, but little actual pain. Thus it differs greatly from the adult type, for the reason that the weak foot in childhood has not been subjected to the strain of constant occupation or to the burden of the increased weight of the body. There is another important difference also; the foot of the adult is obliged to bear greater strain than any other part, and although normal in structure it may be overstrained, so that in many or in most instances the weakness of the foot may be the only disability. But in childhood, when such exciting causes are absent, a weak foot is very often a local indication of general weakness and loss of tone.

FIG. 405.

Flat-foot; extreme deformity in childhood.

Irregular Forms of Weak Feet. Occasionally the apex of the inward bulging and deformity is not at the mediodorsal joint, but anterior to it in the cuneiform region. In such cases the internal cuneiform bone may be enlarged and sensitive to pressure.

Another form is the combination of a plantar flexed toe with a depressed arch (Fig. 406). Extreme deformity of this class is usually congenital. A milder type is not uncommon. (See Hallux Rigidus.)

Weak Feet and Deformity of the Legs. In childhood weak feet are often seen in combination with slight knock-knees (Fig. 403), although more marked knock-knee usually induces in compensation the opposite attitude of adduction. (See Knock-knee.) Bow-leg in childhood is usually accompanied by slight inward rotation of the feet, but in later life there is usually a certain

degree of compensatory valgus, although it does not, as a rule, cause discomfort.

General Weakness. The direct effects of the weak and painful foot have been described in detail. It must be borne in mind that the feet are the foundation of the body, and that an insecure foundation affects the entire mechanism. General functional weakness and awkwardness, the flat chest, round shoulders, or other curvatures of the spine, are often observed as accompaniments or effects of weak feet. Thus, as a rule, the systematic treatment of any form of postural weakness must include the treatment of the feet as well.

FIG. 406.

Hammer-toe flat-foot. (Nicoladoni.)

Recapitulation. The disability and deformity of the weak or so-called flat-foot are caused by a disproportion between the strength of the foot and the weight and strain to which it is subjected.

The foot may be weakened by injury or disease; it may be overburdened by the body weight, or overstrained by laborious occupation, or the broken-down foot may be simply one indication of general bodily weakness. It is unnecessary to enumerate all the various factors that singly or combined lead to this disability. It may be stated, however, that the weak foot is in many or most instances the only disability that demands treatment. Its most constant predisposing causes are the direct injury caused by improper shoes and the mechanical disadvantages to which it is subjected by the assumption of improper attitudes.

All weak or flat feet are mechanically weak, but all weak feet are by no means painful feet. Pain, the symptom of overstrain or injury, bears no definite relation to the degree of deformity.

In certain instances exaggeration of the arch may be combined with persistent abduction of the foot; in others, the flattening of the arch may be the most noticeable deformity, but in most cases the two are combined in varying degree. And as each deformity is an evidence of weakness, it seems hardly necessary to make a radical distinction between the two, except as regards prognosis. For the abducted foot in which the arch is intact is almost always an acquired deformity of short duration, whereas in the case of the foot in which the arch is obliterated the deformity usually

dates from early childhood, and it is, therefore, far less amenable to treatment as far as perfect cure is concerned.

Treatment. The principles of the treatment which leads to the permanent cure of the weak and deformed foot are very simple, but the application varies somewhat according to the grade and duration of the deformity. The object of treatment is to so change the weak foot that it may conform not only in contour but in habitual attitudes and in power of voluntary motion to those of the normal foot, because complete cure is impossible unless normal function is regained. The first step must be, therefore, to make passive motion free and painless to the normal limit. In other words, the obstructions to the motion of the machine must be removed before the power can be properly applied; for the increase of muscular strength and ability, on which ultimate cure depends, is not possible while motion is restrained by deformity or by pain or by adhesions or contractions.

The weak foot, because of inefficient ligaments and muscles unable to hold itself in proper position, must be supported, in many instances, until regenerative changes have taken place in its structure. Such support is necessary to retain the joints in normal position, and to hold the weight in proper relation to the foot, otherwise normal function is impossible. When these essentials are provided the patient may cure himself by the proper functional use of the foot and by the avoidance of attitudes that place it at a disadvantage.

It may be well to describe, first, the treatment that must be applied to all classes of weak foot in which a cure is to be attempted, and which by itself is sufficient in the milder types, before calling attention to the modifications that may be necessary in special cases.

The Shoe. In practically all cases it will be necessary to provide the patient with a proper shoe, for the shoe is usually the direct cause of the minor deformities, and indirectly, in many instances, of more serious disability. Indeed, most of the deformities and disabilities of the foot are incidental to civilization and are, therefore, confined to the shoe-wearing people. The direct effect of the ordinary shoe is to lessen the area and the adjustability of the fulcrum by cramping the toes together. Indirectly it causes deformities—corns, bunions, and the like—which serve to make active movement or leverage painful, so that it is replaced by the passive attitude.

The proper shoe should contain sufficient space for the independent movements of the toes. This motion is illustrated in the walk of the barefoot child. As the weight falls on the foot the toes spread, and as the body is raised on the foot they contract. The important leverage action of the great toe and the support afforded by it to the arch of the foot have been mentioned already. The shape of the sole should correspond to the shape of the foot and the heel should be broad and low (Fig. 407). It will be noted that the front of the sole of the shoe in the figure (407) appears to be pointed slightly inward. Such a shoe aids in preventing abduction, and it is therefore an important adjunct to the brace in restraining deformity.

FIG. 407.

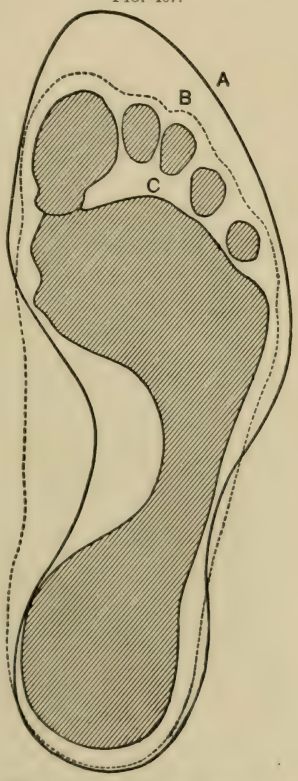

The proper relation of the sole to the shape of the foot. A, outline of sole: B, outline of foot; C, imprint of foot.

Raising the Inner Border of the Shoe. A simple expedient in the treatment of the weak foot and an aid in balancing it properly is to make the inner border of the sole and heel of the shoe slightly thicker in order to throw the weight toward the outer side of the foot. This is of special importance in the treatment of the slighter degrees of what is known as weak ankle, and it is always of service in the treatment of any grade of weak foot.

Attitudes. The patient's attention is then called to the three elements of weakness. He is instructed to guard against valgus (Fig. 391) by throwing the weight on the outer side of the foot (Fig. 392) and to guard against abduction by holding the feet parallel with one another in walking (Fig. 374); the significance of the bulging on the inner side of the foot is pointed out to him, and how this may be prevented by the avoidance of the postures just indicated, and by aiding the arch by the power of the great toe. The importance of leverage is shown him, that he must try to press down the sole of the shoe with his toes, and employ the active lift of the calf muscles by fully extending the leg and raising the body on the foot from

time to time (Fig. 374). Finally, he must avoid long continuance in one position, especially the passive posture, which, even in the normal subject, simulates the attitude and deformity of weak foot. In short, he must be instructed in the mechanics of the foot and taught how the weak foot may be protected as well as strengthened.

Exercises. It is important, also, to demonstrate to the patient the normal range of motion of the foot, motion which, if restricted, must be regained by voluntary and passive exercises. Voluntary exercise should be devoted to strengthening the adductors and plantar flexors; thus the foot should be adducted and supinated then dorsiflexed in the attitude of slight adduction (Fig. 378) over and over again at every opportunity. Tip-toe exercises are especially useful; the patient, placing the feet in the attitude of moderate inward rotation, raises the body on the toes to the extreme limit, the limbs being fully extended at the knees, then sinking slowly, resting the weight on the outer borders of the feet, in the attitude of marked varus, twenty to one hundred times. This exercise is somewhat difficult, and it cannot be carried out properly if there is any limitation of motion or sensitiveness at the mediotarsal joints. The best of all exercises is, however, the proper walk, in which the leverage power of the foot is employed, and in which it passes through the proper alternation of postures (Fig. 374). Treatment by massage and special gymnastic exercises is, of course, of benefit if the patient can command it, although by no means essential to the cure.

Support. In many instances the simple treatment that has been outlined is all that is required, and the symptoms of tire and strain are quickly relieved, but in the majority of cases the patient is not able to prevent deformity voluntarily; consequently a support is necessary to hold the foot in proper position and to relieve discomfort. It is usually necessary in the treatment of the weak foot of childhood because one cannot command the aid of the patient.

In selecting a support for the weak foot the nature of the deformity that is to be prevented should be borne in mind; that the acquired flat-foot, for example, is not a direct breaking down of the arch, as is usually taught, but a lateral deviation and sinking—a compound deformity, as has been already described (Fig. 393). Thus a brace to be efficient must hold the foot laterally as well as support the arch. But it must not prevent the normal motions of the foot, and thus interfere with the increase of muscular strength and ability, on which ultimate cure depends.

The supports that have been ordinarily used for flat-foot do not fulfil the conditions; the pads and springs placed beneath the arch are intended to support it by direct pressure without regard to the valgus or the abduction; they are usually ill-fitting, and are often of such length and shape as to splint the foot and thus to restrict its motion. Leg braces which control the valgus do not often hold the foot accurately, and their weight and unsightliness are fatal objections to their use, especially so in the early

FIG. 408.

The attitude in which the plaster cast should be taken. In the reproduction the chair upon which the foot is resting has been removed. This attitude is important, because in it the foot assumes the best possible contour. If the foot is simply pressed downward into the plaster cream, the ordinary method of making the model, the shape will be found to be quite different from that taken in the manner illustrated.

cases, in which prevention of subsequent deformity is of such importance.

A brace should never be applied to a deformed and rigid foot because it cannot adapt itself to the support; the spasm and rigidity must be first relieved by preliminary treatment, that will be described in the consideration of this class of cases.

The Construction of the Brace. To properly construct a brace to meet these conditions, it is necessary to provide the mechanic with a plaster cast of the foot, taken in the attitude in which one

wishes to support it. Such a model may be easily and quickly made in the following manner:

The Plaster Cast. Seat the patient in a chair; in front of him place another chair of equal height; on it lay a thick pad of cotton-batting and cover it with a square of cotton-cloth. Put about a quart of cold water into a basin and sprinkle plaster of Paris on the surface until it does not readily sink to the bottom; then stir. When the mixture is of the consistency of very thick cream pour it upon the cloth. The patient's knee is then flexed, and the outer side of the foot, previously smeared lightly with vaseline, is allowed to sink into the plaster, and, the borders of the cloth being raised, the plaster is pressed against the foot until rather more than half is covered. The foot should be at a right angle with the leg, and the sole should be in the plane

FIG. 409.

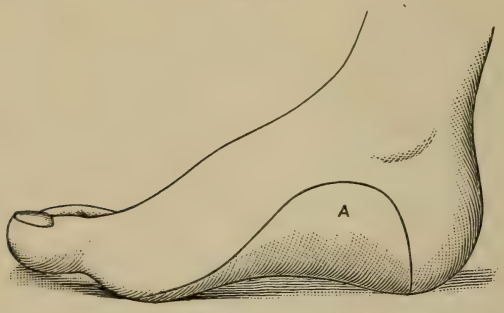

A, the astragalonavicular joint. The internal flange of the brace should rise well above all the prominent bones to a point about half an inch below the malleolus.

perpendicular to the seat of the chair (Fig. 408). As soon as the plaster is hard its upper surface is coated with vaseline, and the remainder of the foot is covered with plaster; the two halves are then removed, smeared lightly with vaseline, and bandaged together. The interior is dampened with soapsuds, and it is then filled with the plaster cream. In a few moments the plaster shell may be removed, and one has a reproduction of the foot, which, when properly made, should stand upright without inclination to one side or the other (Fig. 412).

In most instances it will be of advantage to deepen in the plaster model the inner and outer segments of the arch, in order that the arch of the brace may be slightly exaggerated, especially at the heel, so that the depression of the anterior extremity of the os calcis may be prevented.

The Brace. Upon the model the outline of the brace is drawn as illustrated in the diagrams. The best sheet steel, 18 to 20 gauge, cut after the pattern is moulded upon it and tempered, so that, as it is applied for the purpose of preventing deformity, it may be practically unyielding to the weight of the body.

It will be noticed that the brace clasps the weak part of the foot and holds it together; the broad internal upright portion (Fig. 409) covers and protects the astragalonavicular junction, rising well above the navicular; the external arm covers the calcaneo-

FIG. 410.

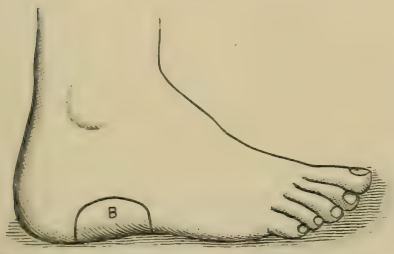

B, the calcaneocuboid junction. The external flange extends from the centre of the heel to a point just behind the base of the fifth metatarsal bone.

FIG. 411.

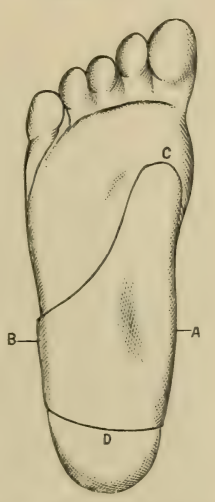

C, the great toe-joint; D, the centre of the heel.

cuboid junction and the outer aspect of the foot to a height sufficient to hold the foot securely (Fig. 410). The sole part provides a firm, comfortable support, yet, reaching only from the centre of the heel to just behind the ball of the great toe, it does not restrain the normal motions of the foot (Fig. 411). The brace may be nickel-plated and japanned, which makes a smooth finish, or tin-plated, or galvanized, which makes a more durable covering. It may be covered with leather, or an inner sole may be placed on its upper surface; but this is not usually necessary. As it is fitted to the foot, it finds and holds its own place in the shoe, so that no attachment is required; thus it may be changed from one shoe to another. Not only does it hold the foot laterally and from beneath, but there is an element of suggestiveness in the slight leverage action which is very important, and which is the distinctive feature of this brace as contrasted with simple sole plates or other supports.

The Positive Action of a Proper Brace. The patient, instructed to throw his weight upon the outer side of the foot and wearing

the shoe which has been tilted in the same direction by thickening the inner border of the sole and heel, presses down the external arm and thus lifts the internal flange against the inner side of the foot, which is instinctively drawn away from the pressure and thus toward the normal contour. He no longer everts or turns the feet outward in walking, because this causes positive discomfort, and he is not likely to assume the passive attitude, because of the suggestive lateral pressure of the support. With the foot held in the proper attitude the patient may again walk with the proper spring; thus the brace itself becomes a positive aid in the physiological cure. It is important, also, that a shoe of proper shape, as shown in the diagram (Fig. 407) be worn, as it aids the brace by holding the forefoot in a slightly adducted attitude.

FIG. 412.



A cast marked for the mechanic. In most instances the internal flange is lengthened as in this diagram, as compared with Fig. 409, in order to straighten the support so that light steel (gauge 20) may be used. (See Fig. 413.)

The shape of the brace, in general like that of the diagram, is modified in certain cases; for instance, the entire internal aspect of the foot may be weak and must be covered by the internal flange. In very heavy subjects the sole portion must be made larger, although this is a disadvantage, as it lessens the leverage action; other slight modifications may be necessary in special cases. If any portion of the rim of the plate causes discomfort, the edge may be turned away slightly at the point of pressure by a wrench. After a few days the patient no longer notices the presence of the brace, and as its presence in the shoe is not evident, it may be worn indefinitely. Steel is the lightest and strongest, and, on the whole, the most satisfactory material for the brace. It will, of course, rust in time, and for this reason

each patient should be provided with two pairs of braces, in order that the rusted pair may be returned to the bracemaker for repairs. In hospital practice heavier material is used and the braces are plated with tin, which is fairly resistant.[1]

It is usually necessary for from three months to a year or longer, according to the condition of the patient and the strain to which the feet are subjected. The brace, properly made and adjusted under the proper conditions, causes no more pressure or discomfort than a well-made shoe, for its principle is quite different from that of the ordinary supports that are in common use, to which this objection has been made. This brace supports the arch primarily by preventing abduction, consequently its pressure is felt upon the lateral aspect of the foot, a pressure that the patient can relieve by improving his attitude. The brace should afford support when necessary, and at all times suggest and enforce a proper attitude; it is, however, but one of the essential factors in the general scheme of treatment. The ordinary form of brace is made in the shape of an inner sole, as in the diagram (Fig. 414). As it supports the sole of the foot, and by the elevation of its inner border tends to throw the weight more toward the outer side; it is a useful aid in treatment, but, providing no lateral

FIG. 413.

The outline of the sole part of the brace.

FIG. 414.

The sole plate ordinarily used in the treatment of weak foot. (After Bradford and Lovett.)

support, it cannot prevent the inward bulging of the foot, which is the most important element of the deformity.

In the treatment of children the foot should be moved in all directions, but particularly in dorsal flexion and adduction to the

[1] In many instances there is a rapid improvement in the shape of the foot under treatment, and it is often advisable to make a second cast in such cases, in order that the brace may conform to the improved contour.

full limit at morning and at night, until the child has regained the normal muscular power and ability. Special gymnastics and massage are always desirable, and they may be necessary in certain cases. Bicycling may be cited as one of the best, and roller-skating as one of the worst exercises for the weak foot. A year is about the time required for a cure of the weak foot in childhood, although attention to the shoes and to the attitudes must be continued indefinitely.

The Rigid Weak Foot.

One may now contrast with the mild types of weakness that have been described the cases of extreme deformity in which the symptoms are disabling and in which the foot is rigidly held in the deformed position by muscular spasm and by secondary changes in its structure. Such cases, often considered hopeless as regards a cure or even relief, are in reality the most satisfactory from the remedial standpoint, and in no other type of painful deformity can so much be accomplished by rational treatment as in this class. The deformity must be considered as a dislocation in which the astragalus has slipped downward and inward from off the os calcis, which, in turn, is tipped downward and inward and into a position of valgus. The remainder of the foot is turned outward, so that the relation of the leg and the forefoot is entirely changed ; in fact, the forefoot is almost entirely disused (Fig. 405).

Corresponding to the duration of the disability, one finds accommodative changes in the soft parts and in the bones, but such changes are by no means as marked as those recorded in the reports of autopsies which have been made in cases of advanced and irremediable deformity. In fact, by far the greater number of patients are young adults in whom the extreme deformity is of comparatively short duration, and in whom complete cure is possible.

In the treatment of such a condition one must first reduce the dislocation and overcome the obstacles that contracted muscles and ligaments may offer to free and normal motion; then rest must be assured to the injured and congested parts in order to relieve the patient from the pain from which he has suffered so long.

Forcible Overcorrection. By far the most effective treatment is forcible overcorrection of the deformity, under anæsthesia. When the patient is under the influence of the anæsthetic the muscular spasm relaxes, and it will be seen that this accounts for about

half of the restriction of motion, the remainder being caused by the adaptive changes that have been mentioned. The object of the operation is to overcome the residual obstruction, and to assure the patient against a relapse, by fixing the foot for a sufficient time in the position of extreme adduction and supination, the attitude directly opposed to that which has become habitual.

This is the object of forcible overcorrection as the first step in the systematic repair of the disabled mechanism; its principle must not be confounded with forcible correction carried out with the object of simply remoulding the arch of the foot, or in which the simple correction of the deformity is the object in view.

One first extends the foot forcibly, then flexes it to the normal limit, then abducts and adducts, the different motions being

FIG. 415.

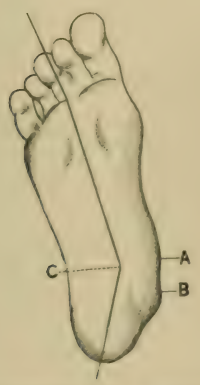

The deformed foot before operation. A, the projection of the displaced astragalus and navicular; B, the inner malleolus; C, the mediotarsal joint, showing the outward displacement before, the inward rotation behind, this point.

FIG. 416.

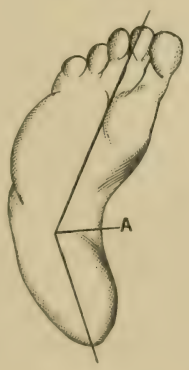

The overcorrected foot, showing the reversal of the lines of displacement. (See Fig. 417.)

carried out over and over until the rigid foot has become perfectly flexible. In cases of long standing it is often necessary to draw the patient to the end of the table, so that the foot may be taken between the knees, in order to supply the required force by the thigh muscles. This forcible manipulation is accompanied by the audible breaking of adhesions, and in favorable cases by complete disappearance of the deformity. In certain instances it will be necessary to divide the tendo Achillis, when, for example, the range of dorsal flexion is limited by resistant accommodative shortening of the calf muscles, or when there has been very great pain and tenderness at the mediotarsal joint, and it is desired to remove the strain

of leverage completely; traumatic cases come especially under this head. Tenotomy has one great advantage: it necessitates longer fixation in the plaster bandage, and gives the patient the benefit of rest, and the opportunity for prolonged after-treatment. When the passive range of motion has been regained, the foot is turned downward, then inward and upward into the position of extreme varus. By this manipulation the os calcis is drawn under the astragalus and thrown into the supinated position, and the scaphoid is flexed about and under the head of the astragalus, which is then lifted to the limit of normal flexion. The attempt is always made to bring the extreme outer border of the inverted foot up to a right angle with the leg, which is the limit of normal flexion in this attitude. The foot, thickly padded with cotton, especially about the toes, is then fixed in this posture of club-foot by a firm plaster-of-Paris bandage extending to the knee (Fig. 407). Surprisingly little discomfort, considering the force that it is sometimes necessary to apply, is experienced after the operation. The familiar and often intense pain, from which the patient has suffered so long, is entirely relieved by the correction of the deformity; there is often a sense of tension about the outer side of the ankle and dorsum of the foot, but this is not, as a rule, of long duration.

Functional Use in the Overcorrected Attitude. As soon as possible, often on the following day, the patient is encouraged to stand and walk, bearing his weight on the foot. Walking serves two purposes: to still further overcorrect the deformity, and to accustom the patient to a posture entirely different from that so long assumed. Meanwhile the contracted tissues on the outer side become thoroughly overstretched; the weakened ligaments and muscles on the inner side are relaxed, and the local irritation rapidly subsides under the rest from the constant injury to which the foot has been subjected.

The patient is not confined to the bed or house, although if both feet are in plaster bandages crutches are, of course, necessary. The time that the feet should remain in the overcorrected position depends upon the duration of the deformity and the severity of the symptoms, or from two to six weeks, the usual time being about four weeks. At the end of about three weeks, or whenever the patient can support the weight on the plaster bandage, without a sensation of discomfort, it is removed; the foot is placed in the normal attitude and a cast is taken for the brace (Fig. 408). Immediately after, the foot is returned to the club-foot position and the plaster bandage is reapplied.

When the brace is ready the plaster bandage is finally removed; the foot is now in good position, and in many instances the arch is exaggerated in depth. For the first few days prolonged soaking in hot water or the use of the hot-air bath, with subsequent massage at intervals during the day, will be found useful in overcoming the swelling and local tenderness that may remain. It is always insisted that a new shoe of the Waukenphast pattern shall be obtained, the sole and heel of which are raised a quarter of an inch on the inner border to aid in the balancing of the weak foot. The brace is then applied, and the patient is never allowed to walk without its support. When the shoe is removed at night, he is instructed to turn the toes in and to bear the weight on the outer side of the foot until it has regained its strength; in other words, the deformity is never allowed to recur.

FIG. 417.

The forcible overcorrection of flat-foot. The proper position in the plaster bandage.

Systematic Manipulation. The systematic treatment is then begun by the surgeon and the patient, the first essential being the attainment of free and painless passive motion in all directions. These motions, which have been so long restrained by deformity, cannot be regained without effort, and during this critical stage, treatment must be carried out by the surgeon himself; if he trusts to the patient or to his friends a cure is out of the question. At least once a day the full range of motion must be carried out to the normal limit. Three motions—abduction, flexion, and extension—are usually free and painless; but the fourth, that of adduction, is almost invariably resisted by the same quality of muscular rigidity that was present before the operation. By far the most effective method of overcoming this resistance is conducted as follows: The patient being seated in a chair, the surgeon sits or stands before him. Let us suppose

that the left foot is to be adducted or, as the patients express it, twisted. The surgeon places the foot between his knees; his left hand encircles the heel, the fingers grasping the projecting os calcis and tendo Achillis; the base of the palm lies against the mediotarsal joint on the inner and inferior aspect of the foot; the right hand grasps the outer side of the forefoot and toes; then, by steady pressure of the thigh muscles, the forefoot is forced downward and inward (adducted and supinated) (Fig. 338) over the fulcrum formed by the projecting palm, which lies upon the left knee, the fingers holding the heel steadily in place. This inward twisting is at first resisted by a mixed voluntary and involuntary muscular spasm, which gradually gives way under steady pressure. When the limit of adduction has been reached, the foot is held firmly until all pain has subsided; then the patient is instructed to attempt voluntary movements while the foot is guided by the hands; in other words, the patient attempts to adduct the foot while the surgeon supplies the power, which in all cases of this type has been completely lost. This passive manipulation to the extreme limit of normal adduction, plantar and dorsal flexion, is continued from day to day until there is no longer a sensation of pain or tension. For as long as there is the slightest spasm or painful restriction of passive motion, the voluntary assumption of proper attitudes is checked, and until this power is regained there is danger of relapse. During active treatment, therefore, the patient, by means of massage and active and passive exercises, must constantly work to one end, namely, to regain the lost power of voluntary adduction.

The time necessary to rest the feet, to overcome the local irritation and muscular spasm, to regain, in part at least, the range of passive motion, and to place the patient in the same position, as regards a cure, as in the milder types of deformity, is from three to six weeks. Usually the patients are told that a month will be necessary, and that at the end of that time they may return to work, free from pain and from the danger of relapse, and that the feet will constantly grow stronger under the work which was before too great for their strength. The time necessary to re-educate the adductor muscles in their proper function depends, in great degree, upon the intelligence and persistence of the patient. Although in after-treatment massage and special exercises are of benefit, the essentials are very simple; they are an effective brace, a proper shoe, the passive manipulation that has been described until its object has been attained,

and the proper walk, the best and easiest of exercises. Finally, one must force into the patient's understanding the method of protecting the weak foot by the alternation of strain, and by proper postures.

Other Varieties of Rigid Weak Foot. The foot which is fixed in the abducted position without depression of the longitudinal arch is simply one variety of the rigid weak foot, which should be treated in the same manner. It may be stated, also, that a very large proportion of the so-called chronic sprains of the ankle are of this type, and that the disability will yield very readily to treatment, conducted for the purpose of restoring impaired function, in the manner that has been indicated.

In certain instances the apex of the deformity lies in front of the astragalonavicular joint, in the naviculocuneiform region, and the internal cuneiform bone may be enlarged and sensitive to pressure. Such cases should be treated on the same general principles as the ordinary variety.

In rare instances marked depression of the arch is accompanied by flexion contraction of the great toe, as if the result of an attempt to support the weak arch. This was described by Nicoladoni as hammer-toe flat-foot (Fig. 406). The association of painful great toe (hallux rigidus) and weak foot is mentioned elsewhere (page 718).

There are other cases in which the deformity of flat-foot is complicated by rheumatoid arthritis or chronic rheumatism, of which the evidence is seen in various joints, but in which the pain and discomfort seem to be concentrated in the feet, which are absolutely stiff and deformed. In such cases one can hardly expect a complete cure; but although the function of leverage may not be regained, still one may hope, by overcoming the deformity, to hold the weight of the body in its proper relation to the foot, so that the pain of a progressive dislocation may not be added to the pain of disease. In a number of instances forcible correction has been employed by the writer in cases of this type, and in all the improvement in the general condition, consequently in the resistance to the disease, after the relief of the local pain and discomfort, has been very great.

Between the two classes of cases, the mild and the severe, one finds every grade of deformity. All cases in which there is marked muscular spasm, local tenderness, and swelling require temporary rest; in many instances simply rest from functional use combined with massage; in others, rest in a plaster bandage

in the adducted position. In the milder and ordinary class of cases the use of a brace and shoe will alone relieve spasm and pain, and the range of motion can usually be regained by manipulation, passive motion, and by the proper use of the foot.

Occasionally, even in childhood, one may encounter marked limitation of normal motion, particularly in dorsal flexion, not due to pain and muscular spasm, but to actual shortening of the muscle. This may be the accommodative shortening that is characteristic of long-standing deformity; in other instances it would appear to be the result of a slight and unnoticed neuritis or anterior poliomyelitis, which has resulted in muscular inequality. If the contraction does not yield readily to manipulation or to mechanical stretching, forcible correction, and, if necessary, tenotomy should be employed in the manner already described; for whatever may be the theory of its causation it is again emphasized that obstruction to motion in any direction must be overcome before a complete cure is possible.

Adjuncts in Treatment. It must be apparent that in many instances the cure of the weak foot is out of the question, either because of the want of energy or opportunity on the part of the patient, or because of the local or general conditions, types familiar in out-patient practice.

The Thomas Treatment. In such cases raising and strengthening the inner side of the shoe by the wedge-shaped leather sole, as used by Thomas, splints the painful foot and aids in relieving the strain.

Plaster Strapping. If the symptoms are more acute the adhesive plaster strapping, as advocated by Cottrell and Gibney for the treatment of sprains, is often of service, although it is applied in a different manner, and with a different object in view. One end of a strip of adhesive plaster, about fifteen inches long and three inches wide, is applied to the outer side of the ankle just below the external malleolus; the foot is then adducted as far as possible, and the band is drawn tightly beneath the sole and up the inner side of the arch and leg, and is stayed in this position by one or two plaster strips about the calf. Narrow plaster straps are then applied about the arch and ankle, in the figure-of-eight manner, and a bandage is applied. The manner of application, although not the attitude, is shown in Fig. 266. The object of the dressing is to aid in holding the foot in the proper position by the support and suggestiveness of the plaster, and to provide the firm compression about the arch that is always agree-

able to the sufferer from weak foot. This treatment, combined with the built-up shoe, is often very effective in overcoming the acute and disabling symptoms of the weak and injured foot, which are, as has been stated, often the result of extra strain or injury; in other words, a sprain of a weak foot. Consequently, when these symptoms are relieved, the patient who has become habituated to the weakness and deformity, considers himself cured. By persistent manipulation and subsequent support with the adhesive plaster one may overcome the resistance to deformity in the majority of cases. Forcible correction under anæsthesia is, however, preferable.

Operative Treatment. The various cutting operations for the relief of flat-foot do not call for extended comment. The typical operation, the removal of a wedge from the astragalonavicular region, aims simply at removal of the deformity. It should be restricted to those cases in which the adaptive changes are so marked that functional cure is impossible.

Arthrodesis. To fix the foot at the astragalonavicular articulation in the attitude of slight adduction is a useful aid in restraining deformity of the valgus type in paralytic disability, and it may be of service in the treatment of certain cases of weak foot of a slighter grade in the class of patients not amenable to ordinary treatment.

The operation of advancement of the posterior extremity of the os calcis, as proposed by Gleich, in order that it may be placed in relation to the leg somewhat like that of a Pirogoff amputation, offers little hope of ultimate cure. For since the disability is not due to primary depression of the arch, it can hardly be cured by exaggerating its depth in this manner. Supramalleolar osteotomy, in which the bones of the leg are divided above the ankle, and the distal extremity turned inward, with the aim of directing the weight toward the outer border of the foot, has been advocated by Trendelenburg. In practice the operation is by no means always successful, while the bow-leg deformity that results, if the object is attained, is an unfortunate accompaniment of the treatment. It may be mentioned in this connection that fracture at the ankle-joint, followed by faulty union in a position of valgus, is a form of traumatic flat-foot that may be cured by this operation. In operative treatment the element of rest, necessary for weeks or months, must be taken into consideration, as explaining in part the immediate favorable effect of whatever procedure is adopted.

In conclusion, the following points are again emphasized: Flat-foot in its surgical sense is a compound deformity, in which the abnormal relation between the foot and the leg, causing the improper distribution of the weight and the strain and disuse of normal function, is of vastly greater importance than the depression of the arch, which has given the name to the disability.

The weak and deformed foot can be cured, but only by the application of the simple principles that any mechanic would apply to a disabled machine whose structure and use were known to him. In other words, there can be no permanent cure of weakness and deformity unless normal function is regained, or effective treatment unless it has this end in view.

The term weak foot has this advantage over others that imply deformity, in that it may be properly applied to the earliest indications of disability. Once weakness is recognized, its causes may be analyzed and appreciated at their proper value. Flat-foot is a particularly objectionable and misleading term, and it should be discarded or at least used only to describe those cases to which it can properly be applied.

CHAPTER XXI.

DISABILITIES AND DEFORMITIES OF THE FOOT (Continued).

The Hollow or Contracted Foot.

Synonyms. Non-deforming club-foot, talipes arcuatus, talipes plantaris, talipes cavus.

The depth of the arch and the corresponding area of the bearing surface of the sole of the foot vary greatly in different individuals, and, although marked differences in appearance and function are possible within a normal range, yet, as a rule, the low arch is characterized by a certain relaxation and weakness of structure, while the exaggerated arch implies a corresponding contraction and loss of normal elasticity.

The hollow or contracted foot may be divided into two classes —the primary and the secondary. In the first class the simple exaggeration of the arch (talipes arcuatus) is the only change from the normal condition. In the second the high arch is combined with a certain limitation of the range of dorsal flexion at the ankle-joint (talipes plantaris—Fisher).

Etiology. The simple hollow foot may be an inherited peculiarity. The depth of the arch may be exaggerated by the habitual use of high heels (postural equinus), or by excessive use of the calf muscles, as by professional dancers.

The secondary variety, in which the hollow foot is combined with slight equinus, is usually acquired, and in the majority of cases its origin may be traced to a mild and transient form of anterior poliomyelitis or neuritis in early childhood. This causes temporary weakness of the anterior group of muscles of the leg, and thus a slight toe-drop, followed by secondary contraction of the tissues of the sole and of the muscles of the calf. In the history of many of these patients it will appear that after recovery from scarlatina or other contagious or infectious disease the child seemed weak or awkward. These symptoms became less marked or practically disappeared; yet a trace remained, although not of sufficient importance to call for treatment, until adolescence or adult life, when the greater strain and weight put upon the feet

brought to light the latent disability. The affection may undoubtedly develop in later years as the result of neuritis, or of gout or rheumatism. It may be caused by a sprain or fracture of the ankle, and it may be a result of habitual posture to compensate for a leg shortened by injury or disease.

The exaggerated arch which is a part of a more important deformity, as of equinovarus or calcaneus, or that which is simply a part of the general deformity caused by diseases of the nervous apparatus, does not belong to the class of disability under consideration.

FIG. 418.

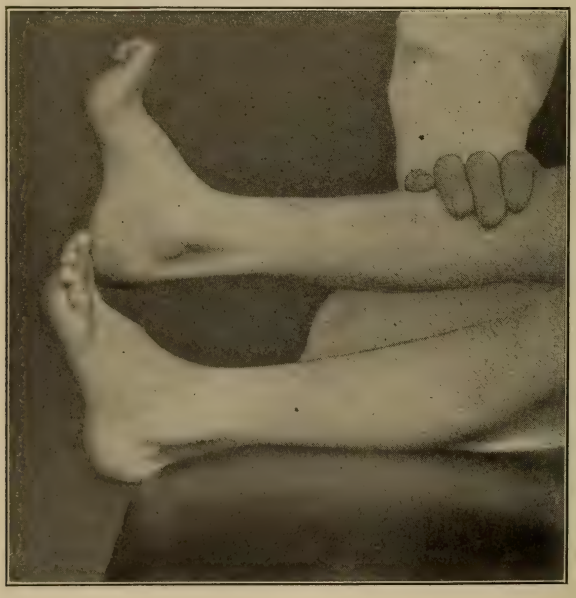

The contracted foot of slight degree.

Symptoms. The simple hollow foot often exists without symptoms; in fact, it is often considered as a particularly well-formed foot rather than a deformity. The usual complaint in these cases is that one is unable to buy comfortable shoes because the ordinary shoe does not support the arch, or because the upper leather exerts uncomfortable pressure on the dorsum of the foot. The convexity of the dorsum, of course, corresponds to the depth of the arch, and in many instances the cuneiform bones project sharply beneath the skin, and painful pressure points or even inflamed bursæ in this locality may cause discomfort.

In the well-marked cases in which the weight is borne entirely on the heel and the front of the foot, calluses and corns usually form at the centre of the heel and beneath the heads of the metatarsal bones. The patient may complain of neuralgic pain about the great toe, the metatarsal arch, or in the sole of the foot. The gait is often ungraceful, as the patient walks heavily upon the heels with the feet turned outward. In such cases "the ankles may be weak and turn easily." In the more advanced cases of this type the foot may assume the position of valgus when weight is borne, so that the more noticeable symptoms are those of the weak foot or so-called flat-foot, even though the depth of the arch is exaggerated.

FIG. 419.

Contracted foot, marked.

Contracted foot, of the more severe grade, is almost always accompanied by a certain limitation of dorsal flexion; and as the shortening of the plantar fascia is often more marked at its inner border, a slight inversion of the forefoot or varus may be present also.

When the exaggerated arch is combined with limitation of dorsal flexion the deformity is usually greater. This limitation may be very slight, or it may be well marked; and a slight degree of permanent equinus even may be present, but so slight as it does not, as a rule, attract attention.

This type of the contracted foot was first clearly described by Shaffer in 1885 under the title of "non-deforming club-foot,"[1] and later by Fisher, of London, as "talipes plantaris."

The symptoms are similar to those of the simple hollow foot, but they are almost always more marked. The gait is awkward and jarring, the feet being turned outward to an exaggerated degree. The patient is easily fatigued, and often complains of the weakness about the ankle and inner side of the arch, characteristic of the weak foot, and of sensations of tire and strain in the calf of the leg. The discomfort from corns, the pain referred to the metatarsal region, the great toe, and to the sole of the foot have been described already.

On examination the exaggeration of the arch is evident, and an imprint of the sole shows that the weight is borne entirely on the heel and on the heads of the metatarsal bones, which may be very prominent beneath the thickened skin, as if the subcutaneous pad of fat had been absorbed. The anterior metatarsal arch is often obliterated, and the toes are usually habitually dorsiflexed at the first phalanges, the permanent flexion, with the resulting pressure against the leather of the shoe being indicated by a row of corns upon their dorsal surfaces (Fig. 419).

The contracted plantar fascia may be demonstrated by forcible dorsal flexion of the foot, when the tense bands, in many instances very sensitive to pressure, may be felt beneath the skin.

On testing the motion of the foot, the limitation of dorsal flexion, both of the voluntary and the passive range, will be evident. In voluntary flexion the toes are drawn up and the tendons are plainly seen on the dorsum, showing the effort made by the accessory muscles to overcome the abnormal resistance.

The limitation of dorsal flexion may be demonstrated in the manner suggested by Shaffer, by asking the patient to flex the feet while standing erect with the back to the wall, when, in spite of the effort made, "the feet remain glued to the floor."

Treatment. In the ordinary form of contracted foot, as has been stated, the disability is much more marked than the deformity; and the disability is due to secondary changes in the structure of the foot, by which its elasticity is impaired. If this can be restored in some degree permanent relief will follow. If the simple hollow foot (cavus), or the secondary type (plantaris), were discovered in early childhood, massage and methodical

[1] New York Medical Record, May 23, 1885.

stretching would, in all probability, be sufficient to relieve the contractions; but, as a rule, no symptoms are noticed until later life. Even then, especially in the simple form, they are often slight and may be relieved by a shoe with a broad heel and a high (Spanish) arch or by a foot plate that equalizes the pressure on the sole.

In the more advanced cases of the milder type methodical forcible manual stretching of the parts may elongate the tissues sufficiently to relieve the symptoms. The Shaffer[1] "traction shoe" may be used with advantage for the same purpose. In the more resistant cases, however, division of the contracted parts and forcible correction of deformity is indicated.

Operative Treatment. The patient having been anæsthetized, a tenotomy knife is introduced beneath the skin to the inner side of the central band of fascia. This is divided by a sawing motion, and if on forced dorsal flexion other tense bands appear they are divided also. Forcible massage, with the aim of making the foot flexible and reducing the depth of the arch, is then employed. If sufficient force cannot be employed by the hands, the Thomas wrench may be used as in the treatment of club-foot; the object being to elongate the foot, to remove the contraction, and thus by increasing the area of bearing surface to relieve the painful pressure on the heads of the metatarsal bones. If the contraction of the tendo Achillis cannot be overcome by forcible manipulation it may be divided. The foot, held in an attitude of dorsal flexion, is then fixed in a well-fitting plaster bandage, a thin board, shaped to the foot, having been incorporated in the bandage, in order that firm and even pressure may be exerted upon the sole. As soon as possible, often on the following day, the patient is encouraged to walk about, in order that the pressure of the body weight may be utilized to flatten the foot still more, while its tissues are in a yielding condition.

The bandage may be worn for six weeks, or, if the tendo Achillis has been divided, until its repair is complete. A well-fitting shoe should be worn, and methodical massage and stretching of the tissues should be continued as long as the tendency to deformity remains.

By this treatment the symptoms may be relieved, and in many instances a return to the normal shape and function can be assured.

[1] New York Medical Journal, March 5, 1887.

Weakness of the Anterior Metatarsal Arch.

Anterior Metatarsalgia and Morton's Neuralgia. A peculiar spasmodic pain about the fourth toe was described by Morton, of Philadelphia, long before its predisposing and exciting causes were understood. For this reason a description of the symptoms may with advantage precede a consideration of the weakness of which they are usually the result.

Typical cases of Morton's[1] painful affection of the foot are characterized by a sudden cramp-like pain in the region of the fourth metatarsophalangeal articulation.

The pain may begin as a burning sensation beneath the toe, as a numb or tingling feeling, as a sudden cramp, or as a peculiar feeling of discomfort about the articulation that increases in severity until it becomes almost unbearable. At first the pain is confined to the neighborhood of the affected joint, but unless it is relieved it radiates to the extremity of the toe, to the dorsum of the foot, or up the leg. In many instances the onset of the pain is preceded by the sensation of something moving or slipping in the foot; in some cases the pain may be induced by sudden movements, missteps, or long standing, and in practically all the cases the pain is felt only when the shoes are worn. The frequency of the recurrent cramp varies; in some cases it is felt only at infrequent intervals; in others it practically disables the patient. When the cramp habit has been acquired, very slight causes may induce the pain, for example, a thin-soled shoe, a hot pavement, "the sticking of the sock to the foot," and the like, but, as has been stated, except in the very advanced and chronic cases, the pain is never felt except when the shoe is worn.

To relieve the pain the patient removes the shoe, rubs and compresses the front of the foot, flexes and extends the toes, and the like. After the cramp is relieved a sensation of soreness remains, and occasionally slight swelling may appear, but in most instances there are no external signs, although the affected articulation is usually sensitive to deep pressure at all times.

The more distinctive term, anterior metatarsalgia, a term suggested by Poulosson, of Lyons, in 1889, may be employed to include Morton's neuralgia, and similar symptoms of pain and discomfort about the anterior metatarsal arch. For in many instances the cramp-like pain is referred to other points, for

[1] T. G. Morton. American Journal of the Medical Sciences, August, 1876.

example, to several adjoining joints, or the discomfort caused apparently by direct pressure on the bones of the weakened arch may be more troublesome than the irregular attacks of neuralgic pain.

Etiology and Pathology. In 78 cases of anterior metatarsalgia in which the location of the pain was noted, it was referred to the fourth metatarsophalangeal articulation in 60; to the third and fourth articulation in 6; to the second, third, and fourth in 6, and in but 6 was the fourth articulation free from pain. The pain is most often unilateral, or, if the second foot is affected, it is usually after a considerable interval.

The affection is more common in females than in males. Of 84 cases 64 were in women and 20 were in men.

Anterior metatarsalgia is not an affection of early life, the average age in the reported cases being more than thirty years. It is relatively more frequent in private than in hospital practice, and not infrequently the patients are of a distinctly nervous type. In many instances it is supposed to be a family inheritance. The affection is usually extremely chronic. Occasionally the symptoms may cease spontaneously, and in such instances a particular pattern of shoe usually receives the credit of the cure.

Morton considered the affection to be a painful affection of the plantar nerves due to compression or pinching by the adjoining fourth and fifth metatarsophalangeal articulations. This compression was explained by the anatomical construction of the foot—*i. e.*, the mobility of the fifth metatarsal bone which allowed it to roll above and under the fourth, its relative shortness which allowed the head and base of the adjoining phalanx to be brought against the adjoining head and neck of the fourth bone, and, finally, by the peculiar distribution of the external plantar nerve between these bones that made it or its fibres more liable to injury. This natural mobility and thus the predisposition to compression might be exaggerated by a sprain, or possibly by rupture of the transverse metatarsal ligament, or the pain might be induced by wearing tight shoes, but in many instances no cause could be assigned. On this theory Morton advocated excision of the head of the fourth metatarsal bone to remove the point of counter-pressure. This operation has been performed many times, but practically no pathological changes in the resected bone or in the surrounding parts have ever been discovered.

In more recent years the true significance of Morton's neuralgia and of similar pains in the front of the foot has been made more

clear by the study of the relation of weakness of the anterior transverse metatarsal arch to the symptoms. Attention was first called to this point by Poulosson, of Lyons, and again by Roughton, Woodruff, and others, and in a much more thorough and convincing manner by Goldthwait,[1] of Boston, in 1894.

The Anterior Metatarsal Arch. If one examines a normal foot one notices that the two middle metatarsal bones, the second and third, are slightly longer and on a higher plane than their fellows. On the sole of the foot the arch is shown by the depression immediately to the outer side of the muscular projection of the great toe-joint. When weight is borne all the metatarsal bones are on the same plane and the arch is obliterated, but when the weight is removed the arch reforms with a certain natural resiliency. In walking and standing the weight is balanced on the head of the third metatarsal bone, as shown by a thickening of the skin beneath its head, but the strain on the metatarsal arch is relieved somewhat by the balancing action of the muscles about the first and fifth metatarsal bones, the inner and outer supports of the arch, and by the active assistance of the toes themselves. When the arch is weak or broken down this natural resiliency is lost, and, in some instances, the centre of the forefoot is not only depressed but it is fixed in this abnormal attitude.

In the ordinary type of depressed anterior arch the deformity may be shown by an imprint of the foot, in which the flabby tissues of the depressed arch encroach upon the clear space representing the longitudinal arch, and obliterate what Goldthwait calls the re-entering angle to the outer side of the great toe-joint, which in the normal foot indicates the highest point of the metatarsal arch. In many instances, however, the imprint of the foot subject to Morton's neuralgia may be, to all intents, normal, and, on the other hand, depression of the metatarsal arch, one of the very common results of improper shoes, may be present, yet unaccompanied by pain or discomfort.

Depression of the anterior arch, the result of the loss of the activity of the accessory supports of the arch, predisposes to pain because of abnormal pressure upon the persistently depressed articulations from beneath, and it predisposes to pain, as the writer has endeavored[2] to explain, because the metatarsophalangeal joints of an arch, that is habitually depressed, are exposed to the direct lateral compression of a narrow or ill-shaped shoe.

[1] Boston Medical and Surgical Journal, vol. cxxxi. p. 233.
[2] New York Medical Record, August 6, 1898.

This point may be illustrated in the hand. When lateral pressure is applied, the hand is folded together and the anterior metacarpal arch is increased in depth, but if the fingers are dorsiflexed so that it is fixed in a depressed position, then lateral compression causes great pain at all the articulations (Fig. 420); or if one finger is dorsiflexed and the corresponding metacarpal bone is thus forced below the level of its fellows, lateral compression causes pain at the compressed joint. Or if the metacarpal bone of the little finger is made to override the fourth, lateral pressure causes pain usually of a more acute character than at the other joints, because the opportunity for direct pressure is more favorable.[1] Finally, if firm pressure is made upon one or

FIG. 420.

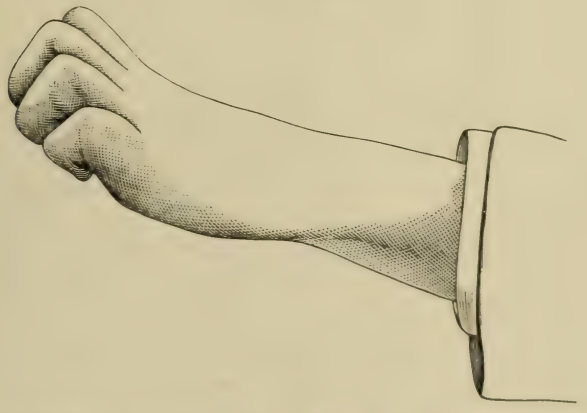

Position of the fingers corresponding to dorsiflexion of the toes, an attitude in which lateral pressure causes pain.

the other side of the head of the depressed metacarpal bone of the dorsiflexed finger in the palm of the hand, a point of sensitiveness, representing apparently the digital nerve, can be made out. The same experiments may be tried upon the foot with the same results, and it would seem to make clear the mechanism of the pain of Morton's neuralgia and the allied forms of discomfort at the front of the foot.

Anterior metatarsalgia is in most instances the result of weakness or depression of the anterior metatarsal arch as a whole or in part, and the quality of the pain corresponds fairly to the form of weakness or deformity. If, for example, the entire arch is rigidly depressed, as in certain rheumatic affections, the dis-

[1] This anatomical peculiarity is well known to school-boys.

comfort is likely to be caused, in great degree, by the direct pressure of the sensitive depressed metatarsophalangeal joints on the sole of the shoe; or, if lateral pressure is exerted as well, the discomfort or pain may be referred to the metatarsal arch in general. If the metatarsal arch is weakened, depressed, and broadened, but not rigid, the discomfort is often referred, as in the preceding instance, to the centre of the arch, and this discomfort is increased, in some instances, by a painful callus representing abnormal pressure at this point. If one of the metatarsal bones falls below its fellows, the lateral pressure of a narrow shoe may cause neuralgic pain at this joint, but in many cases in which the anterior arch is depressed the patient makes but little complaint of pain. In certain instances, more particularly those of Morton's typical neuralgia, the foot may appear to all intents normal; in such cases it may be inferred that the sharp and characteristic pain is caused by pressure applied to the overriding fifth metatarsal bone, just as similar pain is felt if the hand is suddenly compressed while the fifth metacarpal bone is in the same position. This theory is the more probable when one considers the symptoms; for example, the sensation of something slipping or moving, the necessity for the removal of the shoe to flex and extend the toes and to compress the foot, apparently with the instinctive aim of replacing a depressed arch, or a misplaced bone in the arch. It would also explain how the shoe may be the most direct of the exciting causes of the deformity, in that it compresses the forefoot and throws more weight upon it by elevating the heel. If the arch is depressed or becomes depressed, or if a bone in the arch overrides another, this compression causes the symptoms.

That classical Morton's neuralgia is but one expression of weakness of the anterior arch of the foot is illustrated by an analysis of 30 cases seen recently in private practice:

	Cases.
The pain was referred to the fourth toe in	12
" " " third and fourth toes in	4
" " " second, third, and fourth toes in	2
" " " third toe in	3
" " " second and third toes in	2
" " " second toe in	6
" " " to all the toes in	1
The right foot was involved in	13
The left " "	7
Both feet were affected in	8

Twenty-four of the patients were females; four were males.

The Influence of the Shoe in Causing Disability and Pain. In the etiology of pain and discomfort about the anterior arch

one must recognize the shoe not only as the direct cause of the pain, but also as the most important of the predisposing causes of weakness of the anterior arch, of which the pain is a symptom, since it compresses the toes, lifts them off the ground by its "rocker sole," and thus, by preventing their normal function, throws additional strain and pressure upon the arch. In fact, in a very large proportion of feet that are supposed to be normal in appearance and functional ability, the toes are habitually dorsiflexed in a claw-like attitude, that shows entire disuse of their function both as to support and progression. Women wear shoes with narrower soles and higher heels than men, and this seems the most reasonable explanation of the fact that they are more subject to the affection.

The shoe also predisposes to habitual elevation of the fifth metatarsal bone, because this bone almost invariably overhangs the narrow sole. The fourth metatarsal bone becomes, therefore, the outer support of the arch, and is almost always found to be on a lower level than the adjoining bones. This relation, together with a laxity of muscular and ligamentous support induced by injury or otherwise, may account for the location of the pain at this point in the majority of cases. Although in certain instances a neuritis may follow direct injury, yet this assumption is not at all necessary to explain the symptoms. Nor is it likely that the peculiar distribution of the nerves at this point has any direct influence on the pain, for the nerve supply of all the joints and all the toes is practically identical.

Other Factors in the Etiology. Besides the general effect of the shoe, and the possible influence of an inherited predisposition to the affection, which seems evident in certain cases, or of weakness or direct injury of the anterior arch, one recognizes among the causes or complications of anterior metatarsalgia weakness of the longitudinal arch, or flat-foot, which may be combined with a depression of the anterior arch. Less often the longitudinal arch may be exaggerated in depth and the dorsal flexion of the foot may be limited by a shortened tendo Achillis; thus more pressure is brought upon the front of the foot. In these cases the pain may be increased by corns or calloused skin beneath the depressed bones, and in many instances the discomfort of the depressed arch of the ordinary type is, in great part, caused by a sensitive corn or fibroma at the point of greatest depression, and the patient may be entirely relieved by its removal. (See Contracted Foot.)

Although the symptoms of anterior metatarsalgia may be explained in most instances by the primary effect of improper shoes, by weakness and abnormality of the foot itself, and by the local sensitiveness of the parts that are continually subjected to strain, pressure, and injury, yet in some instances the symptoms can be accounted for only by local neuritis; in others they are aggravated by gout or rheumatism or general debility, and, as has been mentioned in a large proportion of the cases, the patients are of a distinctly nervous type.

It may be stated, in conclusion, that anterior metatarsalgia in its milder forms is a very common affection, and one rarely treats a patient who does not know of other cases similar to his own.

Treatment. The most important local treatment is to provide the patient with a proper shoe. This shoe must be of proper shape with a thick sole, so broad that no lateral compression of the toes is possible, with a high arch, as suggested by Gibney, in order to remove a part of the pressure from the heads of the metatarsal bones, and a low heel.

FIG. 421.

A brace for anterior metatarsalgia. *A* indicates a point beneath the fourth metatarsophalangeal articulation, which is elevated in order to support the depressed articulation.

As an immediate treatment a firm bandage about the metatarsal region, as suggested by Morton, may aid in supporting the metatarsal arch, or, better, adhesive plaster strapping may be applied about the entire metatarsus, with the object of compressing the foot somewhat as a tight glove compresses the hand. Beneath or slightly behind the affected joint or the depressed arch, a pad, preferably an oval piece of sole-leather, about one inch by three-quarters of an inch in size and one-quarter in thickness with bevelled edges, may be fixed to the sole of the foot with adhesive plaster, so that depression of the arch or overriding of the adjoining bones may be prevented. This pad, suggested by Poulosson and Goldthwait, usually relieves the pain, and when the exact place has been ascertained it may be fixed to the sole of the shoe.

As a rule, however, a metal support will be found to be more comfortable and far more efficient. This may be constructed of light steel (19 gauge) upon a plaster cast of the sole of the foot,

of which the natural depressions, indicating the anterior and the longitudinal arches, have been somewhat exaggerated. The anterior extremity of the brace is made as wide as the foot, and extends forward slightly beyond the metatarsophalangeal articulations. The brace serves to support the anterior as well as the longitudinal arch. In certain instances one or more of the metatarsophalangeal articulations may be sensitive to motion. In such cases the sole plate must extend from the heel nearly to the extremities of the toes in order to splint the foot for a time. If there is slight depression of the longitudinal arch it may be further corrected by raising the inner border of the heel and sole of the shoe; but if it is more pronounced a flat-foot brace (Fig. 411) may be employed, whose anterior extremity is modified to support the metatarsal arch, as is shown in Fig. 421. If, on the other hand, the arch is exaggerated and if dorsal flexion is limited, treatment with the aim of relieving this deformity will be necessary, as described under "contracted foot." When the immediate symptoms of pain and local discomfort have been relieved, the patient must endeavor to strengthen the natural supports of the arch by proper functional use of the foot, and by regular exercises of the muscles, more especially by methodical forced flexion of the toes, as this motion elevates the anterior metatarsal arch (Fig. 422). Massage of the foot and forcible manipulation of the toes for the purpose of overcoming restriction of motion are of special value.

If the anterior arch is rigidly depressed, as in some instances, its flexibility must be restored by manipulation or by forcible correction under anæsthesia before a brace can be applied. If the symptoms are very acute, and particularly if they have followed direct injury, the parts should be placed at rest and the anterior arch should be elevated and supported by a properly applied plaster bandage.

In chronic and resistant cases, or when conservative treatment cannot be applied, resection of the neck and head of the metatarsal bone at the seat of pain may be performed as advocated by Morton. The operation is very simple. An incision is made over the dorsal surface of the joint, and the bone is divided by bone forceps. The toe is not, as a rule, removed, but after the operation it slowly recedes between the adjoining metatarsophalangeal joints, causing a rather noticeable deformity. The operation is, as a rule, successful, but in the majority of cases it is unnecessary.

The general condition of the patient should, of course, receive attention, and local applications, electricity, and the like, may be of benefit in special cases.

A *sensitive callus* beneath the arch may require treatment, and in certain cases its removal may be the only treatment required other than an improved shoe. But, as a rule, the cause of the callus is habitual depression of one or more of the metatarsophalangeal articulations, so that cure can only be assured by supporting the arch and by strengthening its natural supports in the manner already described.

Woodruff[1] described a case of what he called "incomplete luxation of the metatarsophalangeal articulation," in which the symptoms, practically identical with those of Morton's neuralgia,

FIG. 422.

Exercise for the weakened metatarsal arch.

are ascribed to an upward displacement of the proximal phalanx at the fourth metatarsophalangeal joint

It may be stated in this connection that in the ordinary forms of metatarsalgia patients often refer the pain and local sensitiveness to the anterior extremity of the metatarsal bone rather than to its lateral aspect. Persistent dorsal flexion of the toes that is so commonly associated with depression of the arch may strain the capsular ligament, and, subjecting this portion of the joint to abnormal pressure, may explain the location of the pain. But except in extreme cases it can hardly be classed as a subluxation.

Another writer, Guthrie,[2] described a case in which intense pain followed overextension of the third phalanx upon the second. Such cases are extremely uncommon, and need only be mentioned.

[1] New York Medical Record, January 18, 1887.

[2] Lancet, March 19, 1892.

Achillobursitis.

Synonyms. Achillodynia, achillobursitis anterior, retro-calcaneobursitis.

Under the title of Achillodynia, Albert,[1] of Vienna, in 1893, called particular attention to an affection characterized by pain and sensitiveness about the insertion of the tendo Achillis, symptoms usually caused by irritation or inflammation of the small bursa lying between the insertion of the tendon and the bone (Fig. 423).

Etiology. In the acute cases the cause of the bursitis often appears to be a strain of the tendon or direct injury, as the symptoms appear immediately after running or jumping or after a fall, sometimes after a long walk or bicycle ride.

In the subacute cases the symptoms may begin almost imperceptibly, so that it may be impossible to assign a direct cause other than the pressure of the shoe, aggravated, it may be, by an exostosis of the os calcis beneath the insertion of the tendon or by concretions within the bursa. In many instances rheumatism, gout, gonorrhœa, or one of the infectious diseases appear to be associated, directly or indirectly, with the onset of the symptoms, or the bursa may be secondarily involved in tuberculous disease of the os calcis.

FIG. 423.

Bursa between the tendo Achillis and the os calcis.

Symptoms. In a typical case pain is felt in the back of the heel at the insertion of the tendon; the pain is increased by use of the foot, and particularly by the attitudes in which the strain on the part is increased, as, for example, in descending stairs. There is also sensitiveness to pressure about the back of the heel on either side of the insertion of the tendon. In most cases a slight swelling, often more prominent on the inner than the outer side of the tendon, indicates the situation of the bursa.

In the chronic cases the enlargement of the bursa is very noticeable, and, in addition, the entire posterior aspect of the heel often appears to be thickened. This is due probably to the secondary irritation about the fibrous expansion of the tendon and the adjoining periosteum. In many cases the symptoms are

[1] Wiener med. Presse, January 8, 1893.

pronounced; pain is often felt in the bottom of the heel or it radiates up the back of the leg. The patient, unable to use the power of the calf muscle, everts the foot in walking, thus subjecting the arch to overstrain, so that the symptoms of the weak foot are often added to those of the original trouble. Not infrequently, however, the two affections may be associated from the beginning in one or the other foot. The patient complains much of stiffness and weakness at the ankle and subastragaloid joints. In the acute cases, or in acute exacerbations, there is usually burning and throbbing pain characteristic of acute inflammation, but in the subacute form the pain is slight, and is troublesome only after overexertion.

Pathology. The pathological changes do not differ from those found in and about other bursæ under similar conditions. In the mild cases the lining membrane is simply congested, and the cavity contains serous fluid. In the chronic cases the walls are much thickened,[1] the lining membrane is fringed and reduplicated; the contents are semisolid, and sometimes calcareous masses are present. Similar changes are found, however, in the bursæ of apparently normal subjects, so that the condition of the bursa may not always correspond to the character of the symptoms. Suppuration of the sac occasionally occurs, and it may be the seat of tuberculous or syphilitic disease. In cases of long standing the parts adjoining the bursa, the expansion of the tendon, and the periosteum become thickened, so that the bone appears to be increased in breadth and may actually become so.

Treatment. When once established the affection is usually of a very chronic nature, as is explained by the strain to which the sensitive part is subjected by the use of the foot. It is, therefore, important to apply efficient treatment at the beginning of the affection if an opportunity is afforded. Efficient treatment implies absolute rest, and in all cases of any severity, particularly those of acute onset, a well-fitting plaster bandage should be applied to hold the foot slightly inverted and at a right angle to the leg. This should be worn until all symptoms have subsided. In very mild cases, following immediately on a strain or overuse, simple rest with the application of heat, massage, and pressure may be efficient. And in the subacute cases the symptoms may be relieved by the application of a long, broad band of adhesive plaster, from the toes over the back of the heel to the upper

[1] Rossler. D. Z. f. Chir., Bd. lxii. H. 1 and 3.

third of the calf, the foot being slightly plantar flexed. This is firmly fixed by narrow strips of plaster about the metatarsus, the heel, and the calf. By this means pressure is exerted upon the bursa, and much of the strain is removed from the tendon.

In persistent cases a brace may be used with advantage for the purpose of preventing strain upon the tendon. Two lateral uprights with a calf band and padded strap that crosses the upper third of the leg are attached to the shoe, provided with a stop joint at the ankle as used in the treatment of paralytic calcaneus to prevent dorsal flexion. (See Talipes.) As the patient is usually sensitive to jar, the heel of the shoe should be replaced by one of thick rubber. In connection with the brace the stimulation of the cautery and the pressure of the adhesive plaster strapping seem to hasten the absorption of the effusion in and about the bursa. If weakness or depression of the arch is present, as a result of the disability or combined with it, a foot plate should be applied, and general affections, with which the disability is sometimes associated, should, of course, receive attention.

Operative Treatment. In persistent cases, in which the symptoms are not relieved by treatment, the enlarged bursa should be removed by an incision on the inner side of the tendon, as the swelling is usually most prominent here. A plaster bandage is then applied and is continued until the symptoms have subsided. If the case is a chronic one, it may be advisable to divide the tendo Achillis in order to completely remove for a time the strain upon the sensitive part. In any case, a brace of the character already described may be required for a time after the plaster support has been removed. Operative treatment is, of course, indicated in acute suppurative inflammation, in tuberculous disease, or if an exostosis beneath the bursa or concretions within the sac are present, as shown by an X-ray negative.

Achillobursitis Posterior.

Tenderness, pain, and swelling at the back of the heel may be due to inflammation of the small superficial bursa that lies between the tendon and the skin. The cause is usually injury or the pressure of the shoe. The symptoms resemble somewhat those of achillobursitis anterior, but the swelling is more superficial, and the pain is caused by direct pressure rather than by tension on the tendo Achillis. In the ordinary case removal of the pressure will at once relieve the symptoms, but if the discom-

fort is considerable a plaster bandage may be worn for a week or more.

Sensitive points at the back of the heel are usually caused by the pressure of the shoe. In rare instances prominent points, or exostoses of the os calcis are present, that may require special protection or removal.

Strain of the Tendo Achillis.

Not infrequently, and usually as the result of strain or overuse of the foot, patients complain of symptoms similar to those of achillobursitis, but on examination one finds that the pain and sensitiveness are referred to the tendon itself. There is no swelling at its insertion, or pain on lateral pressure on the os calcis. The sensitive area may be as high up as the junction of the tendon with the muscle, and, again, the midpoint of the tendon seems most painful.

The cause in some cases may be a direct strain of the tendon or of the muscular fibres near its origin, or inflammation of its fibrous covering due probably to the same cause. The treatment is similar to that of the milder type of achillobursitis, by the adhesive plaster strapping, by rest, and, later, by massage. Recovery is usually rapid.

Painful Heel—Calcaneobursitis.

Pain referred to the bottom of the heel and sensitiveness to pressure on standing are common symptoms of the weak or flat-foot. Pain at this point may be one of the symptoms of achillobursitis also. In rare instances the painful point is clearly localized, and is confined to a small area in the neighborhood of the inner tuberosity of the os calcis. The cause of the symptoms in such cases may be an inflamed bursa lying between the periosteum and the fatty tissue of the heel. Such bursæ may contain hard substances or even a fasciculated neuroma.[1]

More general pain and tenderness referred to the heel is often caused by direct pressure and bruising of the tissues by overuse of the feet.

Treatment. Treatment must be directed to the condition of which the pain is a symptom, and, as has been stated, it is most often one of the symptoms of the weak or broken-down arch.

[1] Brousses et Berthier. Revue de Chir., August, 1895.

If the tender point is localized, and if the pain is increased by jars, a thick rubber heel combined with an inner sole, so cut out as to remove the direct pressure on the sensitive point, will often relieve the symptoms. In persistent cases, in which the sensitive point is distinctly localized, operative intervention for the removal of the bursa is indicated. The tissues of the heel may be turned forward in a horseshoe-shaped flap, which will allow a thorough examination of the affected parts.[1]

Sensitiveness due to direct contusion, or bruising of the tissues caused by overuse, must be treated by rest and by change of occupation, unless a reduction of the body weight or improvement in attitudes relieve the symptoms.

Plantar Neuralgia.

Synonym. Plantalgia.

Pain referred to the sole of the foot and sensitiveness to pressure on the plantar fascia are usually symptomatic of the contracted foot (cavus); less often such symptoms accompany the weak or broken-down arch.

Pain, tenderness, and thickening of the fascia sometimes follow injury (rupture of the fascia),[2] and a similar condition has been described by Franke as one of the sequelæ of influenza.[3]

Treatment. Pain in the sole of the foot, symptomatic of the contracted or of the weak foot, may be relieved by the treatment of the conditions of which it is a symptom. In the rare instances in which the fascia is itself injured or diseased, local rest, as afforded by the plaster bandage, is indicated until the acute symptoms have subsided.

Erythromelalgia.

Weir Mitchell[4] has described a series of cases characterized by attacks of heat, redness, pain, and often swelling most marked about the soles of the feet. Of 27 cases all but 2 were in women, many of whom were of a nervous or neurasthenic type. The affection appears to be a form of vasomotor disturbance. Disturbances of the circulation and burning pain in the soles of the feet are common symptoms of the weak foot and of allied affections,

[1] Duplay. Clin. Chir. de l'Hôtel Dieu, Série 1897.
[2] Lederhose. Verhand. der Deut. G. f. Chir., XXIII. Kong., 1894.
[3] Archiv f. klin. Chir., 1895, Bd. xlix.
[4] American Journal of the Medical Sciences, 1878, vol. lxxvi.

but in such cases there is not the flushing and swelling characteristic of erythromelalgia. In this affection the circulatory disturbances are not, as a rule, confined to the feet, but are seen in the legs and even in the upper extremities.[1] It deserves mention as a possible explanation of symptoms in obscure cases.[2]

Hallux Rigidus.

Synonyms. Hallux flexus, painful great toe.

Hallux rigidus is a painful affection of the great toe-joint, characterized by restriction of motion, particularly of the range of dorsal flexion. In advanced cases the first phalanx may be slightly plantar flexed together with its metatarsal bone; hence the name hallux flexus, applied by Davies-Colley, who first described the affection.

Fig. 424.

The dotted outline shows the shape of the steel splint that may be inserted in the sole of the shoe for hallux rigidus.

The restriction of motion may be complete, as implied by the term rigidus; the joint appears unduly prominent or enlarged, usually slightly congested, and pressure or forced movement causes pain.

The symptoms of which the patient complains are a burning or throbbing pain in the joint, increased by standing, and particularly by walking, because of the enforced movement of the stiff and painful articulation. There are many cases in which there is no actual deformity of the joint or other noticeable change; the restriction of motion is much less, and the symptoms are correspondingly slight.

Etiology. Typical hallux rigidus is most common in adolescence, and it is very often associated with the weak or broken-down foot. In such cases the toe is crowded into the narrow part of the shoe, and is thus subjected to lateral and to longitudinal pressure as well as to the additional strain that the attitude, characteristic of the weak foot, throws upon it. In some cases the habitual plantar flexion of the toe may be the result of an instinctive effort to support the weak arch (hammer-toe flat-foot—Nicoladoni). In other instances hallux rigidus is caused directly by traumatism; as by stubbing the toe, by kicking

[1] Kahane. Klin. therap. Wochen., May 20, 1900.
[2] Prentiss. Transactions of the Association of American Physicians, 1897, vol. xii. p. 303.

a hard object, or by other form of strain or injury. The affection appears to be, primarily, a form of periarthritis, caused by injury or pressure. The restriction of motion is in part due to muscular spasm, and in part to the irritative and accommodative changes in the ligaments and tendons. In more advanced cases changes in the cartilage and shape of the articulating surfaces, due to disuse of function and to pressure and friction, may be present.

Treatment. If the rigid and painful joint is not associated with a weak arch, it may be relieved by providing the patient with a proper shoe which exerts no pressure on the sensitive part. Motion of the joint may be lessened by increasing the thickness of the sole, or, if necessary, it may be entirely restricted by the insertion of a brace of tempered steel between the two layers of the sole, as shown in the diagram. If, as in some instances, the flexed and painful toe is associated with rigid flat-foot, both deformities may be overcorrected, under anæsthesia, and retained in proper position by a plaster bandage, as a preliminary treatment.

If the milder type of painful joint is associated with the ordinary weak foot, the treatment of the latter condition will usually relieve the symptoms. In this class, particularly among the poorer patients, the shoe may be raised on the inner side and the sole stiffened by means of the wedge-shaped sole, as already described in the treatment of the weak and flat-foot. If painful motion is restricted and the exciting causes of the disability are removed, relief of the symptoms is usually immediate. In the chronic cases, in which the pathological changes are more advanced, excision of the joint may be necessary.

Painful Great Toe-joint in Older Subjects.

A similar condition of the joint is sometimes found in older subjects. In many instances the foot is well formed, and the restriction of motion in the joint is very slight; yet forced dorsal flexion causes pain, and long standing or walking induces discomfort, particularly a dull ache in the joint and sharp neuralgic pain referred to the terminal phalanx. In some cases the onset of the symptoms may be ascribed to a long walk or "mountain climb," in others to wearing tight shoes, and in some instances no definite cause can be assigned by the patient. In cases of this type the symptoms are often supposed to be evidences of gout or rheumatism. Admitting that in certain instances the

discomfort may be aggravated by a constitutional disease, still no relief can be obtained by medication unless it is combined with the local treatment that has been described in the preceding section. The relief afforded by such treatment alone proves, in many instances, that the affection is purely local in its character (Fig. 424).

As has been mentioned, pain referred to this joint is a common symptom of the weak foot and of the contracted foot as well. It is also caused by simple pressure on the joint, and by the use of improper shoes which force the toes into the abducted position.

In rare instances pain directly beneath the great toe and sensitiveness to pressure about the sesamoid bones seem to indicate an

FIG. 425.

Simple congenital varus, adduction without supination—a form of pigeon-toe.

inflammation of the tendon sheath or local periarthritis. If the discomfort is persistent the sesamoid bones may be removed. As a rule, such symptoms occur only in combination with pain or deformity of the great toe-joint.

Hallux Varus.

Adduction of the great toe is not infrequent in infancy, and it may be associated with a slight degree of varus deformity (Fig. 425). The peculiarity attracts the mother's attention because of the difficulty of drawing on the socks. In many instances the muscles seem abnormally developed, and the toe appears to be somewhat prehensile in its movements.

Treatment. The abnormal mobility may be checked by inclosing the toes with a narrow strip of adhesive plaster; in any event, the ordinary shoe may be depended upon to correct any residual deformity of this character. If the adducted toe is combined with varus, it represents a slight degree of club-foot that must be corrected in the ordinary manner. (See Talipes.)

Fig. 426.

An appliance constructed of leather bands and elastic webbing for the correction of in-toeing. Name of the inventor unknown.

Pigeon-toe.

Congenital hallux varus forms one variety of what is known as pigeon-toe, or the habitual turning in of the feet in walking. The inward rotation may be due also to bow-legs, or it may be an effect of congenital talipes that persists after the cure of the deformity, or of the exceptional variety of coxa vara in which the depressed necks of the femora are turned forward. In most instances pigeon-toe in childhood is symptomatic of weakness either of the arch of the foot or of the knees (genu valgum). In such cases it is a conservative effort of nature that serves to check further deformity, and it needs no treatment other than that which may be applied to the weakness of which it is a symptom.

In the exceptional cases, in which the posture is not symptomatic of weakness or the effect of deformity, the sole of the shoe may be raised slightly on the outer border. This will correct the attitude in the milder type, if combined with instruction and training. In rare instances the in-toeing seems to be caused by limitation of the range of outward rotation at the hip-joints, a restriction that must be overcome by systematic stretching of the contracted parts. In these and in the more obstinate cases of the simple type appa-

ratus may be applied, similar to that used in the after-treatment of congenital club-foot, to hold the feet in the proper attitude (Fig. 426). It must be borne in mind that the proper attitude of the feet is one of parallelism not of outward rotation, and that slight pigeon-toe will, as a rule, correct itself as the child grows older.

Hallux Valgus.

Hallux valgus is a deformity in which the great toe is turned outward to an exaggerated degree. Outward deviation of the toe is so common, owing to the use of improper shoes, that it is not recognized as a deformity, at least from the popular standpoint, unless the joint appears to be much "enlarged," forming a so-called bunion.

Hallux valgus is practically a partial dislocation of the phalanx upon the metatarsal bone. In well-marked cases the metatarsal bone is adducted or turned inward, so that an abnormal interval separates its head from its fellows, while the phalanx is displaced outward and articulates only with the outer condyle. The angle thus formed, or, more properly, the inner condyle of the adducted metatarsal bone, makes the prominent or "outgrown" joint (Fig. 435). This projects sharply beneath the skin, and is exposed to injury and to the pressure of the shoe; thus a bursa develops beneath the skin, while a corn or callus forms on its superficial surface. The projecting bone, covered by the irritated bursa and the thickened skin, makes up the bunion.

In many instances the other toes are displaced outward, in the direction corresponding to that of the great toe, or this may be rotated on its long axis and lie above or beneath its fellows.

Pathology. The pathological changes are such as usually follow deformity, disuse of function, and injury. The cartilage on the exposed condyle atrophies, the sesamoid bones, together with the tendon, are displaced outward, the tissues on the outer side undergo accommodative shortening, while those on the inner side are correspondingly lengthened and attenuated. The surface of the bone beneath the irritated periosteum is often roughened and irregular, and exostoses may form about the condyle, and thus aggravate the effects of the external pressure.

Etiology. The deformity is the direct effect of shoes that are too narrow and of improper shape, and in some instances too short for the foot, so that the great toe is subjected to lateral and longitudinal pressure. The deforming effect of the shoe is

increased if the arch is weak, so that the toe is forced forward into the narrower part of the shoe when the foot is in use. The deformity may be increased by injury or by the changes that follow gout, rheumatism, rheumatoid arthritis and the like, and in rare instances the distortion may be the direct result of such diseases; but all other factors are of slight importance when compared to the deforming influence of the ordinary shoe. The deformity begins at a very early age; it advances more rapidly during adolescence, but the symptoms do not often become troublesome until later years. Both toes are affected, as a rule, although the deformity and its accompanying symptoms are usually more marked on one side.

Symptoms. As has been stated, the slighter grades of deformity are not recognized as such, and it is usually because of the pain due to the irritated corn or bursa, and incidentally because of the outgrown joint, that the patients apply for treatment.

Treatment. The symptoms in the ordinary cases may be relieved by providing a proper shoe, by which pressure on the joint is completely removed (Figs. 407 and 432). The sole should be strong, and it should be slightly thicker along the inner side, so that the sensitive joint may be inclined away from the upper leather. In cases in which the deformity is not far advanced the use of a proper shoe that allows space for an improved position of the great toe, combined with methodical manual correction of the deformity and exercise of the disused muscles, while the toe is guided in the proper directions by the fingers, will relieve the symptoms promptly and practically cure the deformity. If the longitudinal or the metatarsal arches are depressed they should be properly supported (Figs. 404 and 421).

Several forms of correcting braces have been devised to be worn during the day, a digitated stocking and special shoe being, of course, necessary.

A simple device for holding the toe in an improved position is the Holden toe-post, recommended by Walsham and Hughes. This is a thin piece of metal so fixed in the front and inner side of the sole of the shoe that it separates the first and second toes from one another and holds the former in an improved position. It, of course, necessitates a special shoe and a special shoemaker to fit it in its proper place.

Sampson[1] makes the toe-post of tin and places it in a cardboard inner sole, as illustrated in the diagrams (Figs. 427–430).

[1] Johns Hopkins Bulletin, January, 1902.

The use of a splint at night is also of some service. For this purpose a piece of celluloid about one-eighth inch in thickness, one inch in width, and about six inches in length may be used. This, having been moulded to the proper contour by placing it

FIG. 427.

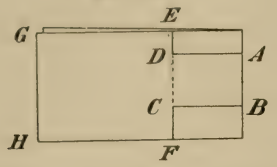

Making the pattern for a toe-post. A heavy piece of paper folded once along the line *A B*. *A D E* and *B C F* are cut away, leaving the tongue *A D C B*. *A D* should equal the depth of the shoe at that point, and *A B* should be as wide as the length of the slit in the cardboard inner sole. The tongue is inserted in the slit, and the bases folded back and cut away to conform to the front of the inner sole. When removed and straightened out this forms the pattern in Fig. 428.

FIG. 428.

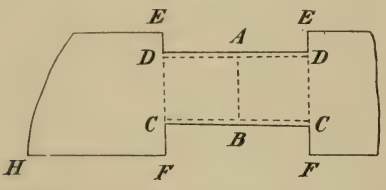

Pattern of paper from which the tin is cut. The edges *D D* and *C C* are to be turned in. Tin is folded along the dotted lines *A B—D C* and *D C* forming the toe-post in Fig. 429.

FIG. 429.

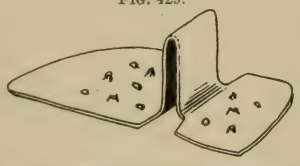

Shows the toe-post ready to be inserted into the cardboard inner sole. Rough points on the upper and under surfaces of the base, which are made by punching holes with an awl, hold the toe-post to both the inner sole of the shoe and the cardboard inner sole.

FIG. 430.

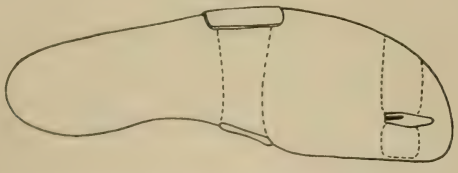

Cardboard inner sole with toe-post and foot adductor attached. (Sampson.)

in hot water, is secured by tapes to the inner side of the toe and foot.

It may be stated that in the class of cases that can be successfully treated by mechanical correction few patients will be

found who are sufficiently interested in the cure of the deformity to submit to the slight discomfort that the wearing of even a carefully adjusted brace entails.

Operative Treatment. In cases in which the deformity is of long standing, and in which the projecting condyle or the exostoses make protection of the sensitive joint difficult, an operation is indicated. The primary object of the operation is to remove the projecting bone. This may be accomplished by a slightly curved incision about the inner aspect of the condyle, the centre being below the joint, so that the scar will not be subjected to pressure. The flap of skin is raised, the periosteum and part of the capsule are lifted from the bone, and the entire condyle is removed with a chisel, so that the surface is made perfectly smooth. Contracted tissues that resist a corrected position of the toe are stretched or divided, and the wound having been closed with sutures a plaster bandage is applied about the foot and toe. This may be worn with advantage for several weeks. The after-treatment consists in the use of a proper shoe and daily manual adduction of the toe, in order to retain the improved position.

Cuneiform osteotomy of the metatarsal bone is an effective operation if the base of the wedge includes the projecting bone. Resection of the head of the metatarsal bone is an effective operation, and it may be indicated if the deformity is extreme.

As has been stated, hallux valgus is often combined with the weak or broken-down arch; in such cases the foot must be supported by a properly fitted brace. This is of special importance after treatment by operation.

Bunion. The discomfort of hallux valgus is caused in great part by the irritated bursa and the overlying corn. These symptoms may be relieved by rest and by hot applications. Afterward the callus or corn may be removed, and the sensitive bursa may be protected by a bunion plaster. Operative treatment should be deferred until after the acute symptoms have subsided.

Hammer-toe.

Hammer-toe is a contraction of one of the toes, usually of the second, in which the first phalanx is dorsiflexed, the second plantar flexed, while the third may be flexed or extended. The contracted toe is overlapped by its fellows; its projecting dorsal surface is subjected to the pressure of the upper leather of the shoe, and the terminal phalanx, forced against the sole of the

shoe and compressed by the adjoining toes, becomes flattened into a club or hammer-like form. The nail is distorted and often "ingrown;" in most cases a corn or callus forms upon the extremity of the toe, and a small bursa and corn over the projecting knuckle on the dorsal surface. A third corn or callus is often found beneath the head of the metatarsal bone which has been forced downward by the flexion of the toe.

Hammer-toe is usually bilateral; it may be congenital and even hereditary, but it is usually acquired, the effect of shoes that are too short and too narrow. The second toe is deformed most often, because it is the longest and because it suffers most from the lateral compression as well. The deformity begins, as a rule, in early childhood, when, the growth of the foot being rapid, it is more likely to suffer from the effects of outgrown shoes, and socks as well.

Symptoms. The symptoms are practically those of the corns or blisters caused by the pressure of the shoe, but they are often sufficiently troublesome to interfere seriously not only with the comfort, but with the ability of the patient.

Treatment. The resistance to the rectification of the deformity is caused by the accommodative changes that follow habitual malposition. In cases of long standing all the tissues may be involved in the contraction, of which the most resistant are the shortened capsular and lateral ligaments of the first interphalangeal joint.

The congenital hammer-toe of the infant may be treated by manipulation. When the resistance is overcome the toe may be held in proper position by narrow strips of adhesive plaster passed over and under it and about its fellows. In older children a digitation in the stocking will often hold the toe in place if the deformity is slight and if a wide shoe is worn. In adult cases, in addition to the manipulation and shoe, a retention apparatus, in the form of a light plantar splint, or stiffened inner sole to which the toe can be attached, should be worn. If the deformity is more resistant the toe may be straightened by force, aided, if necessary, by the subcutaneous division of the contracted ligaments; but in advanced cases the most effective treatment is resection of the joint. Sufficient bone should be removed to permit the correction of the deformity, or, in case of its recurrence, to prevent the projection of the joint above its fellows. A splint of celluloid or other material should be worn for a time. By this operation permanent relief may be assured, and it is to be preferred to the mutilation of amputation.

Overlapping Toes.

Overlapping toes are very common among adults, owing to the pressure of the narrow shoe; and not infrequently such deformity is seen in infancy and is apparently congenital. Deflected or deformed toes may be treated in infancy by manipulation and by support with strips of adhesive plaster in the manner described.

In childhood exercise and proper shoes will usually correct acquired deformity. In older subjects an inner sole somewhat like a sandal, to which the toes may be attached by bands of tape, may be employed if the deformity is considered by the patient of sufficient importance to demand treatment.

Exostoses of the Foot.

Simple exostoses of the foot, as distinct from those that are incidental to disease, as, for example, to osteoarthritis, are, in most instances, induced by pressure upon a projecting bone of a somewhat deformed foot. The common examples are the hypertrophy of the navicular, often seen in flat-foot of young children, the projection of the cuneiform bones on the dorsum of the hollow or contracted foot, the enlargement of the internal condyle of the first metatarsal bone complicating hallux valgus, and the exostoses of the os calcis in achillobursitis. As a rule, the treatment of the deformity of the foot and the removal of pressure will relieve the symptoms without other treatment. Operative removal may be required in exceptional cases.

Fracture of Metatarsal Bones.

Fracture of a metatarsal bone, most often the second or the fifth, may occur without apparent cause other than walking. The pain and the subsequent swelling in such cases may be inexplicable until the diagnosis is made clear by an X-ray picture.

Displacement of the Peronei Tendons.

Permanent displacement of these tendons forward of the malleolus is not uncommon as a result of paralytic deformity, particularly talipes calcaneus, and in such instances it gives rise to no symptoms. Displacement of one or both of the tendons, or rather a laxity of their attachments that allows an occasional displacement or slipping from the groove behind the malleolus,

may result in serious disability, because of the pain that follows the displacement and because of the weakness and insecurity of which the patient usually complains.

The cause of the laxity of the tissues that allows displacement in feet otherwise normal may have been injury, but as the affection is often bilateral, the predisposition may be congenital.

Treatment. If the displacement is recent, as when it follows injury, the tendons should be replaced, and the foot should be fixed in a plaster bandage until repair has taken place. If, as in certain instances, dorsal flexion is limited, the restriction should be overcome before the bandage is applied. If the displacement is habitual, a brace may be applied to restrain those motions at the ankle that induce it. In the chronic cases an operation with the aim of fixing the tendons by deepening the groove in the malleolus, or by suturing the displaced sheath in its normal position, may be indicated. If on examination the cause of the displacement appears to be a shortening of the tendon it may be divided and lengthened in the ordinary manner.

Shoes.

The shoe as a factor in the etiology of deformity and disability has been mentioned several times in the preceding pages, but it is a subject of such importance that it would seem to call for special consideration.

The object of the shoe is to cover and protect the foot, not to deform it or to cause discomfort; therefore, the one should correspond to the shape of the other. If the feet are placed side by side the outline and the imprint of the soles will correspond to the accompanying diagram (Fig. 431). The outline demonstrates the actual size and shape of the apposed feet, emphasized by enclosing them in straight lines. Thus, each foot appears to be somewhat triangular, being broad at the front and narrow at the heel. The imprint shows the area of bearing surface, and owing to the fact that but a small portion of the arched part of the foot rests upon the ground it appears to be markedly twisted inward. The sole of the shoe, if it is to enclose and support the bearing surface, must also appear to be twisted inward in an exaggerated right or left pattern. It will be straight along the inner border to follow the normal line of the great toe, and a wide outward sweep will be necessary in order to include the outline and thus avoid compression of the outer border of the foot (Fig. 432).

This demonstration of the true form of the foot is almost an indispensable preliminary to an intelligent discussion of the relative merits of shoes, and, indeed, it is somewhat of a revelation to

FIG. 431.

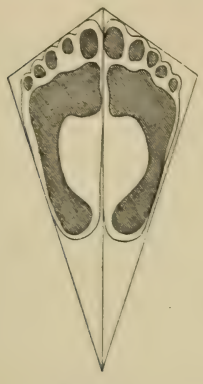

Normal feet.

FIG. 432.

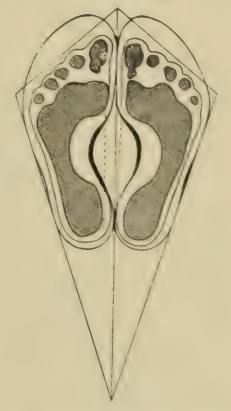

Proper soles for normal feet.

those who have thought of the foot only as it has been subordinated to the arbitrary and conventional standard of the shoemaker. The ideal, or shoemaker's foot, upon which lasts are fashioned, is much narrower than the actual foot; the great toe is not a power-

FIG. 433.

Shoemaker's feet.

FIG. 434.

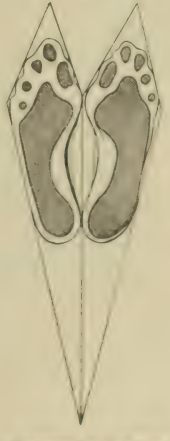

Shoemaker's soles.

ful movable member, provided with active muscles, but is small and turns outward, so that the forefoot is somewhat pyramidal in form and turns upward as if to avoid contact with the ground.

This imaginary foot, drawn after the shape of the ordinary last, appears in the diagrams (Figs. 433 and 434). Upon it the sole of the shoe has been indicated, to contrast it with the shape of that necessary to include the outline of the normal foot. The actual foot is thus compressed laterally by the shoe until the

FIG. 435.

Skiagram of a foot modelled to fit the shoe, illustrating the etiology of hallux valgus.

stretching of the leather, during the "breaking-in" process, allows it to overhang the sole. The great toe is forced outward, and, with its fellows, is compressed, distorted, and lifted off the ground by the rocker-shaped sole (Fig. 436). Finally, although in the foot there is a well-marked metatarsal arch (convexity upward), the sole is almost invariably fashioned with a convexity

downward. Thus the foot, according to the age at which the reshaping process is begun and the constancy of the application, is gradually changed in shape and altered in function (Fig. 435).

This remodelling, however, is often accompanied by such discomfort that the individual rebels and wears a shoe with a square toe, which, from the conventional standpoint, is supposed to show a meritorious effort to follow nature. But the demonstration of the actual foot makes it evident that it is a properly shaped sole, which serves as a support, not the part which projects beyond the foot, that is of importance. If the shoe with the square toe is wider, and straighter on the inner side than another with a pointed toe, it is in so far an improvement. But, as a matter of fact, one of the worst types of shoe provided for children, in shape very like the old-fashioned coffin-lid, owes its popularity to the square toe. The same comment may be made on the so-called "common-sense" shoe, which is well named, since it may be assumed that a properly shaped shoe is an evidence of uncommon sense.

FIG. 436.

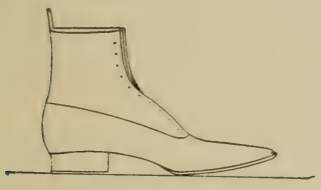

The rocker sole.

FIG. 437.

The flat sole.

The object of the heel is to make walking easier by inclining the body somewhat forward. The high, narrow heel is an insecure support, and aids deformity by throwing more strain upon the forefoot and pushing it forward into the narrowest part of the shoe. The heel is, of course, unnecessary in childhood, and should not be worn, since it limits the necessity for and therefore the use of the normal range of motion at the ankle-joint. The ordinary shoe by restricting the functional use of the foot, favors awkwardness and improper attitudes. It compresses the toes, and is directly responsible for corns, bunions, ingrown toe-nails, and deformities, and indirectly it causes or aggravates nearly every weakness to which the foot is liable. This assertion does not need support of argument, since in some degree it has been proved by the personal experience of every shoe wearer.

The shape of the proper shoe corresponding to the undistorted foot has already been demonstrated (Fig. 432). The sole should be thick enough for protection, but not so rigid as to limit normal motion; it should follow the imprint of the foot, projecting somewhat beyond the outline of the toes; it should be flat from end to end and from side to side (Fig. 437), and the upper leather should be capacious. In other words, the front of the shoe should be designed to permit and to encourage normal functional activity, the slight adduction of the great toe, and the alternate expansion and contraction of its fellows, as may be observed in the barefoot child. The heel should be broad and low. Most adult feet are more or less deformed, and, therefore, better suited by an improved than by a perfect shoe. Of this class, what is known as the wide Waukenphast pattern is the best. In selecting the better from the worst of the "ready-made" shoes, the breadth of sole, the angle of outward deviation of the soles when the two are placed side by side, and the capacity of the upper leather must be the determining points.

The most effective work for reform can be accomplished by providing proper shoes for children and thus preventing deformity. The inspection of children's feet shows that atrophy and compression begin at a very early age, and if protection could be assured during the period of rapid growth, serious distortion might be prevented.

Socks. Although of far less importance than the shoes, the socks worn by children deserve special mention as a factor in deformity, since they are often too short and too narrow and are made of unyielding material, so that the proper action of the toes is restrained. Theoretically, the socks, like the shoes, should be rights and lefts; but if they are sufficiently large and of a texture to expand readily to the shape of the foot, but little trouble need be anticipated on this score.

CHAPTER XXII.

DEFORMITIES OF THE FOOT.

Talipes.

In the preceding chapters the disabilities of the foot, of which the symptoms of pain and discomfort were of greater importance than actual deformity, have been described. One now passes to the consideration of the congenital and acquired disabilities, of which deformity is the most noticeable feature.

Fig. 438.

Paralytic equinus. Recovery from paralysis, but deformity persists.

Distortions of the foot are, practically, fixed positions in normal attitudes or what are exaggerations of normal attitudes; in other words, the ordinary deformities can be voluntarily simulated, and the centres of motion, at which the foot is deformed, are the centres of normal motion. If the foot has been fixed in the

abnormal attitude during the period of formation and rapid growth, or if it has been used for any length of time in the abnormal position, the deformity becomes exaggerated beyond the possibility of imitation, and secondary variations in its shape, size, and nutrition follow.

The deformities of the foot are grouped under the generic name of talipes, derived from talus (ankle) and pes (foot), signifying, therefore, a form of deformity in which the patient walks upon his ankles. Talipes was thus originally synonymous with the popular term club-foot, but at the present time it is used simply as a prefix to the descriptive titles of the different distortions, while club-foot is usually applied only to the most common of the congenital deformities, equinovarus, in which the distorted foot is club-like in form.

Varieties. There are four *simple* varieties of the distorted foot or talipes:

1. **Talipes equinus**, the extended or plantar flexed foot. In well-marked cases the patient walks upon the heads of the metatarsal bones, an attitude that suggested the name equinus (horse-like).

2. **Talipes calcaneus**, the dorsiflexed foot, in which the heel is prominent, and which alone bears the weight in walking; hence, calcaneus from calcaneum, the heel bone.

In these forms the centre of motion is at the ankle-joint. Under the terms equinus and calcaneus are included not only the cases of marked deformity, but also those in which the range of dorsal or plantar flexion is sufficiently limited to interfere with function, even though the change in the contour of the foot is slight.

3. **Talipes varus**, the inverted foot. In this deformity the foot is turned in or adducted, and combined with the inward twist there is practically always a certain degree of supination or inversion; that is, the inner border of the sole is elevated and the outer border is depressed, so that the weight falls to the outer side of the centre of the foot.

4. **Talipes valgus**, the everted foot. This deformity is the reverse of varus. The foot is abducted and the sole is everted, so that in use the weight falls on the inner border.

In these forms of lateral deformity the centres of motion are at the mediotarsal and subastragaloid joints.

These simple deformities, in which the foot is persistently extended or flexed, or twisted in or out, are comparatively uncommon.

Compound Deformities. As a rule, the deformities are combined in varying degree; thus the overextended or the overflexed foot is usually twisted inward or outward, making four varieties of compound deformity:

1. **Talipes equinovarus**, the extended and inverted foot.
2. **Talipes equinovalgus**, the extended and everted foot.
3. **Talipes calcaneovarus**, the flexed and inverted foot.
4. **Talipes calcaneovalgus**, the flexed and everted foot.

FIG. 439.

Congenital calcaneus. In this form the arch is obliterated; in the acquired form it is increased.

In these more important deformities the arch of the foot may be increased or diminished in depth. It is, for example, usually increased in calcaneus and equinus, and it is usually diminished in valgus; but this secondary or subordinate deformity is not recognized in the ordinary classification. If the arch of the foot is simply exaggerated, the condition is sometimes called pes cavus; if it is lessened or lost, it is called pes planus. These slight degrees of distortion, in which the functional disability is usually more important than the deformity, are rarely classed as

forms of talipes. Simple cavus, the hollow or contracted foot, and pes planus, one of the forms of the common weak or flat-foot, have been described elsewhere. (Chapters XX. and XXI.)

Etiology. From the remedial standpoint, the cause of the deformity is of far greater importance than its form. Thus, one divides the distortions of the foot into two groups:

1. **The congenital form**, in which the foot, in process of formation, has slowly grown into deformity before birth.

2. **The acquired form**, in which the foot, perfect at birth, has at a later time become distorted.

The congenital club-foot may be considered simply as a twisted foot, of which the component parts, although distorted to a greater or less degree, are capable of regaining perfect form and function.

FIG. 440.

Congenital valgus.

This is practically true of the great majority of cases, although there are instances in which congenital deformity is complicated by defective formation of the foot or leg, or in which the deformity is caused or at least accompanied by paralysis; as, for example, in certain forms of spina bifida or other defect or disease of the nervous apparatus.

The acquired deformity is nearly always a consequence of paralysis of spinal origin (anterior poliomyelitis). Certain muscles or groups of muscles being paralyzed, usually in early childhood, the muscular force of the foot is unbalanced, and it is drawn into a distorted position by the contraction of the unopposed muscles and by the influence of gravity. This distortion is confirmed and increased by the accommodative changes in the

structure that accompany functional use and growth in the abnormal attitude.

Far less often acquired talipes may be the result of paralysis of cerebral origin, of other forms of cord disease, and of local paralysis following neuritis or injury to a nerve trunk. It may be caused by scar contraction, as after a severe burn, or by direct

FIG. 441.

Congenital club-hands and feet, combined with anchylosis of nearly all the joints. (Compare with Fig. 442.)

injury, or by disease that may interfere with subsequent growth (Fig. 265). Such are, however, extremely uncommon causes. Thus it is evident that whereas congenital talipes is a simple distortion capable of perfect cure, acquired talipes is capable only of rectification and not of perfect cure unless recovery from the original disease, of which it is a result, has taken place.

Etiology of Congenital Talipes. As of other congenital deformities, the etiology of talipes is more or less conjectural. Occasionally the influence of inheritance is apparent, and, again, two or more children with club-foot may be born of the same mother; but, as a rule, nothing bearing upon the deformity appears in the family or personal history. The most reasonable explanation as applied to the majority of cases is the mechanical. This is, in brief, the theory that the foot has from some cause remained

FIG. 442.

The etiology of congenital club-hands, club-foot, and anchylosis of the joints. The habitual attitude at birth. Photograph at age of three months. (See Fig. 441.)

for a longer or shorter time in a constrained or fixed position, and has thus grown into deformity.

It has been claimed by Eschricht[1] and also by Berg[2] that about the third month of intra-uterine life the thighs of the embryo are abducted, flexed, and rotated outward, the legs are crossed, and the feet are plantar flexed and adducted, so that the inner

[1] Deutsche klinik, 1851, No. 44.

[2] Berg. Archives of Medicine, New York, December 1, 1882.

surfaces of the thighs, the tibial borders of the legs, and the plantar surfaces of the feet are held in close apposition to the abdomen and to the pelvis of the fœtus. Later there is an inward rotation of the legs, so that the feet are turned gradually outward until the soles are brought into contact with the uterine wall, the feet then being in the attitude of abduction and dorsal flexion. According to this theory, there is a regular succession of attitudes during intra-uterine life. If the inward rotation of the lower extremity is prevented or if it is incomplete, the foot, remaining in the original position, becomes deformed. Thus equinovarus, being the normal attitude of the early and middle period of intra-uterine life, is not only the most common, but it is the most intractable of the congenital deformities. But if the constraint or pressure is not exerted until a later period, after rotation has taken place, when the foot has attained or nearly attained its normal size and shape, it will then induce the rarer and comparatively slight grades of deformity, such as calcaneus or valgus.

This theory, which seems interesting and reasonable, appears to rest on a very insecure basis. Bessel Hagen[1] states that in embryos of 30 mm. in length the foot is in extreme plantar flexion ; in those of 90 to 100 mm. the foot is at a right angle to the leg ; and from this size to that at full term the foot may be found in any position—abducted, adducted, or dorsiflexed. He states, also, that supination is not the usual attitude at an early period, but is more common near the termination of intra-uterine life, and when it is present it is more often combined with dorsiflexion. In other words, there is no time when the foot regularly and normally assumes the attitude of club-foot, from which it is changed by the rotation of the limbs. Scudder,[2] after similar investigations, arrived at practically the same conclusions. He states that there is no necessary relation between the age, the rotation of the limbs, and the position of the feet.

Although the rotation theory may not be absolutely accepted, still it would appear that there is, during the process of development, a more or less regular change in the attitudes of the limbs and feet. If they are fixed in one position during this period of rapid growth, distortion must follow ; if the constraint is slight, and if its influence is exerted at a late period, the deformity will be slight ; if it occurs at an early period, the deformity will be more resistant.

[1] Die Pathologie und Therapie des Klumpfusses Heidelberg, 1899.
[2] Boston Medical and Surgical Journal, October 27, 1887.

One of the causes of constraint, and thus of ultimate deformity, appears to be the interlocking of the feet. Many museum specimens show this, and in some of the cases of talipes seen during the first week of life the feet may be replaced in the attitude in which they had been fixed before birth (Fig. 281). Intra-uterine pressure, although not usually the direct cause of club-foot, undoubtedly has an influence in aggravating the deformity. The effect of pressure is not infrequently shown in atrophic areas of skin, and bursæ even are sometimes found over prominent bones.

FIG. 443.

Intra-uterine "amputations." The patient is a tailor.

Entanglement in the umbilical cord, the direct pressure of intra-uterine or extra-uterine tumors, and the like may be mentioned also as possible causes.

Evidence of restraint and of abnormal attitudes of the limbs is seen not infrequently in connection with club-foot; for example, in hyperextension or fixed flexion of the knees, and in cases of extreme deformity, the foot is often smaller than normal and otherwise asymmetrical. The distorted foot may be imperfect in structure; toes may be absent, "spontaneous amputation" (Fig. 443), or constricting bands about the leg or foot may be

present. Such abnormalities are usually ascribed to amniotic adhesions. Talipes may be combined with evidences of impaired or arrested development; with harelip, extrophy of the bladder, spina bifida, and absence of patellæ; or with other deformities, such as club-hand and wryneck, fixed flexion at the knees, and the like; or there may be evidence of intra-uterine disease, as in anchylosis of joints (Fig. 441) or so-called fœtal rickets. Finally, deformities of the foot may accompany or are caused by absence of bones, as of those of the foot; or other deformities and malformations, showing evidently an abnormality in the original make-up of the germ. This latter group, which includes the complications of club-foot and imperfection of structure, is comparatively small, and, as has been already stated, in the great majority of cases congenital club-foot is a simple deformity capable of perfect cure.

Statistics. The most accurate statistics are those compiled from the records of the Hospital for Ruptured and Crippled.[1] In the combined statistics are included the data of 3453 individual cases of talipes. Of these 1650 were congenital and 1803 were acquired. The relative frequency of the congenital and acquired forms of talipes has given rise to much discussion in the past, and statistics on this point are at considerable variance with one another. This may be explained by the fact that acquired talipes is, as a rule, a preventable deformity. At the present time the extreme degrees of acquired talipes are comparatively rare, and the deformity is usually of a much slighter grade than the corresponding form of congenital distortion.

	Males.	*Females.*	*Total.*
Sex of congenital talipes	1065	585	1650
Percentage	64.5	35.5	
Sex of acquired talipes	975	828	1803
Percentage	54.1	45.8	

Congenital talipes is much more common among males than among females. All statistics are in accord upon this point. Acquired talipes is more equally divided between the sexes.

	Right.	*Left.*	*Both.*	*Total.*
Foot affected in congenital talipes	510	440	710	1660
Percentage	30.7	26.5	42.7	
Unilateral 950 = 57.2 per cent.	Bilateral 710 = 42.7 per cent.			

	Right.	*Left.*	*Both.*	*Total.*
Foot affected in acquired talipes	781	768	254	1803
Percentage	43.3	42.6	14.1	
Unilateral 1549 = 85.9 per cent.	Bilateral 254 = 14.1 per cent.			

[1] W. R. Townsend. A Statistical Paper on Club-foot. Transactions of the Medical Society of the State of New York, 1890. These statistics were supplemented for me by Dr. N. B. Waller.

In congenital talipes the deformity is nearly as often of both as of one foot, while in the acquired form unilateral deformity is far more common. In each variety the right foot appears to be more often affected than the left.

THE RELATIVE FREQUENCY OF THE DIFFERENT FORMS OF CONGENITAL TALIPES.

	Cases.	*Percentage.*
Equinovarus	1272	77.0
Valgus	123	7.4
Varus	85	5.1
Calcaneovalgus	52	3.1
Equinus	40	2.4
Calcaneus	28	1.7
Equinovalgus	28	1.7
Calcaneovarus	7	
Cavus	5	
Valgocavus	1	
Equinocavus	1	
Different deformity in each foot	18	
Total	1660	

RELATIVE FREQUENCY OF THE DIFFERENT FORMS OF ACQUIRED TALIPES TOGETHER WITH THE ETIOLOGY.

	Spinal.	Cerebral.		Other forms of paralysis.	Traumatic.	Total.	Per ct.
	Anterior poliomyelitis.	Hemiplegia.	Paraplegia.				
Equinovarus	479	28	35	4	29	575	32.5
Equinus	321	66	46	3	26	462	26.1
Calcaneus	219	3	1	0	1	224	12.6
Valgus	134	4	7	1	27	173	9.7
Equinovalgus	114	0	5	0	3	122	6.9
Calcaneovalgus	76	0	0	0	2	78	4.4
Varus	41	2	1	0	5	49	2.7
Calcaneocavus	12	0	0	0	0	12	
Equinocavus	22	0	0	0	2	24	1.3
Calcaneovarus	11	0	0	0	0	11	
Cavus	35	1	0	0	0	36	2.0
Varocavus	1	1	0	0	0	2	
	1465	105	95	8	95	1768	
Deformity different on each side	.....	.....	.....	.....	.....	50	

Anterior poliomyelitis	1465 = 82.8	per cent.
Cerebral	200 = 11.3	"
Traumatic	95 = 5.3	"

COMPARATIVE FREQUENCY OF THE DIFFERENT FORMS OF TALIPES, CONGENITAL AND ACQUIRED.

	Congenital.	*Acquired.*
Equinovarus	77.0 per cent.	32.5 per cent.
Valgus	7.4 "	9.7 "
Varus	5.1 "	2.7 "
Calcaneovalgus	3.1 "	4.4 "
Equinus	2.4 "	26.1 "
Calcaneus	1.7 "	12.6 "

It will be noted that in three-fourths of the congenital cases the deformity is equinovarus, and that equinus and calcaneus,

rare as congenital deformities, comprise 38 per cent. of the acquired forms.

Occasionally the deformity is different in each foot, far more often in the acquired than in the congenital form (50 of the former, or 19 per cent., of the 254 acquired bilateral deformities as compared with 18, or less than 3 per cent., of the bilateral congenital). In 7 of the 18 congenital cases the deformity was equinovarus on one side, calcaneus on the other; in 3, equinovarus and calcaneovalgus, and in 3, simple varus and valgus. The 50 cases of acquired talipes represented every combination of deformity.

In 31, or 4 per cent., of the 735 cases of congenital talipes tabulated by Waller the distortion was combined with other congenital defects or deformities, viz., in 12 cases with double club-hands; in 6 cases with defective development of the hands, webbed fingers, and the like; in 7 cases with spina bifida; in 3 cases with absence of one or more bones of the leg; in 1 case with torticollis; in 1 case with harelip; in 1 case with dislocation of the knee and anchylosis of an elbow; in 2 cases with general rigidity and deformity of the joints.

The Anatomy of Congenital Club-foot. **Talipes Equinovarus.** Congenital talipes is, in the great majority of cases, the form in which the foot is twisted inward and downward, so that in extreme cases it resembles the club-like extremity that has received the popular name of club-foot. The ordinary congenital club-foot, in early infancy, is simply a foot held in an exaggerated attitude of plantar flexion, adduction, and supination. The dorsum of the foot looks forward and slightly outward and upward, the plantar surface is abnormally concave, and looks backward, inward, and downward. The foot often seems somewhat smaller than normal, and the heel appears to be ill-formed. Upon the outer dorsal surface the body of the displaced astragalus projects; the external malleolus is prominent, while the internal malleolus lies deep beneath the redundant tissues of the internal aspect of the foot.

In many instances the turning inward of the foot is so extreme that it conceals the equinus element of the deformity (Fig. 444). Thus equinovarus is often classified as varus, especially by English authors.

The internal structure of the foot is rearranged to correspond to the external contour; thus the relation of the bones to one another, and even the shape of the individual bones, are more or

less altered as the deformity is more or less of an exaggeration of the attitudes that the normal foot is capable of assuming. These

FIG. 444.

Typical congenital equinovarus (club-foot).

FIG. 445.

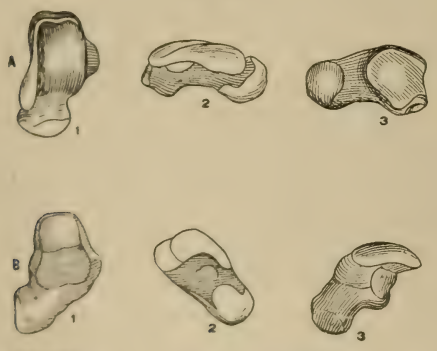

The deformities of the astragalus in club-foot. A, astragalus of a normal infant; 1, from above; 2, from within; 3, from without. B, the astragalus in club-foot in the same positions. (Adams.)

changes are most marked in the astragalus and os calcis. The astragalus is thicker at its external than at its internal border, or somewhat wedge-shaped from without inward; it is plantar

flexed, so that a large part of its body protrudes from between the malleoli. Its neck is often somewhat longer than normal, and it is, as a rule, depressed and deflected inward (Fig. 445, B). The os calcis is also in an attitude of plantar flexion; the internal tuberosity is drawn upward to the vicinity of the internal malleolus, its anterior extremity looks downward and inward, and it is often bent inward, corresponding to the deformity of the neck of the astragalus. Its external surface looks downward and forward, and it lies directly beneath the astragalus instead of to its outer side, as in the normal relation.

The navicular is drawn inward and upward, and articulates with the inner part of the deflected head of the astragalus; it lies in close proximity to and is often in contact with the internal malleolus; the cuboid is displaced upward and inward, and lies to the inner side of the anterior extremity of the os calcis. The remaining bones are changed in position, but not materially in shape. In many instances the tibia is rotated inward upon the femur, and this inward rotation of the leg may persist after the deformity of the foot has been corrected. Less often the tibia is slightly twisted inward on its long axis. In other cases there is often a moderate degree of knock-knee and laxity of the ligaments at the knee. As a rule, however, these are secondary or compensatory effects of club-foot that do not appear until the child begins to walk.

The ligaments are altered to correspond to the changed relations of the bones. Those on the short side are more or less resistant, according to the duration of the deformity. The muscles are normal as to their structure and their origin and insertion, but the direction of the tendons as they pass across the foot is altered somewhat. Those attached to the inverted side, the extensor and adductor group, are shortened and are relatively stronger than those on the outer side, which are lengthened and atrophied from disuse.

To sum up: all the component parts of the foot participate in the deformity. The most noticeable changes in the bones are in their position and relation to one another, but the astragalus, os calcis, and navicular bones are usually distinctly abnormal in contour.

The most resistant structures in the deformed foot are the plantar fascia and the ligaments that bind the scaphoid, the os calcis, and the internal malleolus to one another. The muscles that are most active in retaining and increasing the deformity are

the tibialis anticus, the tibialis posticus, and the combined gastrocnemius and soleus.

The changes that have been outlined, which are comparatively slight and which may be easily rectified soon after birth, become more marked as the part develops; and when the child begins to walk the weight of the body, combined with growth and functional use in the abnormal position, increases and fixes the deformity.

In the adolescent or adult type of club-foot that has never been treated the deformity is so extreme that the patient actually appears to walk on the outside of his ankles, as the term talipes implies. The feet turn directly inward, or even inward, upward, and backward, and the peculiar walk, by which interference of inverted feet is avoided, has given another name (reel foot) to the deformity.

FIG. 446.

Talipes equinovarus in adolescence, apparently of the acquired form, showing the displacement of the astragalus and its relation to the scaphoid, also the atrophy and distortion of the bones of the leg.

In such cases knock-knee is usually well marked. This, although it may be present at birth, is, as has been stated, usually a secondary distortion caused in great part by the accommodation to the deformity; that is, by the diminution of the base of support and by the interference of the feet (Fig. 449.)

The legs are shrunken from disuse. Over the outer border of the foot, in the neighborhood of the calcaneocuboid articulation, there is a large callus with an underlying bursa. The foot itself is atrophied and is much smaller than the normal. The changes in the bones are much more marked; only a small part of the articulating surface of the astragalus lies between the malleoli, and this posterior extremity is flattened out to the shape

of a wedge. There is consequently backward displacement of the leg bones, which is most apparent in the position of the external malleolus. In fact, the changes in the foot may be so great as to make the component parts almost unrecognizable (Figs. 444, 445, and 446). All the bones of the foot are more or less atrophied, and the normal area of cartilage has, to a great extent, disappeared from the articular surfaces of the disused joints.

FIG. 447. FIG. 448.

Talipes equinovarus.

The tendons on the front of the foot. Showing the tendons in the sole of the foot and the extreme displacement of the os calcis.

In this advanced stage the normal functional activity of the foot has disappeared. It is practically a simple rigid support, to which the patient has been so long accustomed that he may walk with comparative ease and with no discomfort other than that caused by the corns and bunions at the pressure points. In these extreme cases, cure in the sense of perfect functional recovery is, of course, out of the question; but relief of the

deformity—that is, replacement of the foot in the axis of the leg, at a right angle to it and in the plantigrade attitude—is nearly always possible.

Symptoms. The symptoms of congenital club-foot have been, to all intents, included in the description of the deformity. The functional disability is, of course, considerable, although some patients are surprisingly active and are able to walk long distances. As the discomfort from club-foot is due almost entirely to the corns or inflamed bursæ over the bony prominences, its degree depends, of course, upon the use to which the foot is subjected.

Treatment. In considering the treatment of congenital club-foot it is customary to divide it into several classes corresponding to the degree of resistant deformity.

The first class would include the very slight or non-resistant cases in which the deformity may be almost entirely corrected by slight manual force.

The second class comprises those cases in which a certain amount of varus and well-marked equinus remain, which it is impossible to overcome by manipulation.

The first and second classes include the forms of infantile club-foot.

The third class comprises the cases of more extreme deformity and those in which the resistance to the correction is great, as in many of the cases in early childhood or those of later years that have been inefficiently treated.

A fourth class would include the untreated cases in the adolescent or adult.

Congenital club-foot (talipes equinovarus) treated at the proper time—that is to say, in early infancy and in a proper manner—in a great majority of cases may be perfectly cured both as to form and function.

The club-foot in childhood, in which treatment has been delayed or in which it has been ineffective, may be practically cured as to form and function, but a certain amount of atrophy of the foot and leg persists as a consequence of the disuse of the distorted part.

Club-foot in the adult may be made straight, but perfect functional cure is, of course, impossible.

Although congenital club-foot is an eminently curable deformity, yet perfect and permanent cure requires minute attention to details during the active stage of treatment, supplemented by

long-continued and careful supervision after the cure is supposed to be complete. No other deformity presents such a record of failures and incomplete cures, of relapses after apparent cure, of tedious and ineffective treatment by braces, and of unnecessary and mutilating operations. Some of the failures may be explained by the neglect of the parents or by want of opportunity. A few are due to the unusual obstacles in the deformity itself, but by far the greater number must be accounted for by failure of the physician to apprehend the true nature of the deformity or by his inexperience in the practical details of treatment.

Principles of Treatment of Infantile Club-foot. The infantile club-foot is, as has been stated, simply a twisted foot. It is true that there are slight changes in the bones; but the bones of an infant's foot are represented by yielding cartilage, which will rapidly reform under changed conditions. The ligaments, which are accommodated to the deformity, may be easily stretched, together with the more resistant muscles and their tendinous insertions, and when the proper relation of the bones to one another has been restored the joints will undergo an accommodative transformation.

The treatment of club-foot may be divided into three stages:

1. The rectification of the external deformity.

2. The support of the foot in proper position during the process of transformation of its internal structure and until the normal muscular power, unbalanced by the deformity, has been regained.

3. The period of supervision. This would include the treatment of possible complicating deformities at the knee, the laxity of ligaments and the like, as well as the oversight of the functional use of the foot and the limb during the early years of life.

On examining the infantile club-foot one will notice the same muscular activity that characterizes the normal foot. The normal infant moves the foot in various directions, in a more or less regular alternation of postures, but the motion of the club-foot is in one direction only, that toward which the foot is turned. The muscles on the back and inner side of the leg, which are alone active, become relatively irritable and hypertrophied as compared with those on the front and outer side that are disused. Thus muscular activity of the deformed foot is in reality harmful, because it increases deformity and still further disturbs the muscular balance. For this reason the temporary restraint of motion, necessary during the rectification of the deformity, may be con-

sidered rather of advantage than otherwise. When movement is again allowed and encouraged it must be in the directions opposed to the attitudes of deformity, with the aim of so strengthening the weakened group of muscles at the expense of the stronger that the balance of muscular power may be re-established.

The First Stage of Treatment. Rectification of Deformity. It should be stated at once that "rectification of deformity" does not mean apparent symmetry, a misapprehension to which the majority of failures in treatment may be ascribed. It means that when deformity is really rectified all contracted and resistant parts must have been so elongated that every passive motion and attitude possible for the normal foot is equally possible and as easily attained in that which was deformed. This is functional rectification as contrasted with the simple straightening of external deformity.

The most important part of the club-foot deformity is varus. The foot that is rolled over and twisted inward to the attitude of extreme adduction (Fig. 444) must be untwisted and forced into an attitude of extreme abduction or valgus, the so-called overcorrection (Fig. 440). Until this is accomplished no attention whatever need be paid to the residual equinus. There are two reasons for dividing the procedure into two parts: First, that the attention of the surgeon may be concentrated on one and the most important part of the deformity; second, because by this preliminary untwisting the os calcis is brought into the upright position, into its proper relation to the astragalus, to the bones of the leg, and to the tendo Achillis, so that the true degree of equinus may be appreciated.

Preliminary Manipulation. As a rule, the second or third week of life is as early as mechanical treatment can be undertaken. Until then preliminary manipulation by the nurse, more particularly manual straightening of the deformity by gently drawing the foot toward abduction and retaining it in the improved position for a few minutes, as often as is possible, may be of service in overcoming its resistance. As a treatment by itself, however, simple manual correction is tedious and ineffective, although partial cures have been attained by perseverance in this means alone.

Mechanical Treatment. This is the treatment of choice and routine for infantile club-foot, and two methods may be described:

1. By the plaster bandage.
2. By some form of simple splint.

The principle of the two is essentially the same. The foot is drawn toward an improved position and retained there by the plaster bandage, or it may be fixed to some form of metal splint or brace whose shape is gradually changed from week to week, as the resistance lessens.

Gradual Rectification of Deformity by Means of the Plaster Bandage. In this treatment care should be taken to avoid undue pressure, irritation of the skin, or insecurity of the bandage. One should place shreds of cotton between the toes; and the outer aspect of the ankle, where the skin is thrown into folds

FIG. 449.

Neglected club-foot, showing the secondary knock-knee.

when the foot is straightened, should be smeared with vaseline. A narrow strip of adhesive plaster, long enough to reach from the knee to a point an inch or more below the heel, is applied to the outer side of the leg. A thin layer of cotton is wound about the leg, just below the knee, in order to protect the skin from the hard margin of the plaster bandage, and a similar strip is carried about the toes. The foot is then drawn gently toward the abducted position as far as may be without causing discomfort. While it is held in this attitude a narrow bandage, preferably flannel or cotton flannel, is smoothly applied to the leg

and foot, the band of adhesive plaster being drawn out between the folds about the ankle. A very light plaster bandage is then applied from the upper part of the leg to the extremities of the toes, and into this bandage the projecting strip of adhesive plaster is incorporated, so that no displacement of the dressing is possible. The turns of both the plaster and the flannel bandage should be made from within, downward and outward, so that the tension aids in retaining the foot. When the plaster bandage, which during the hardening process has been constantly rubbed and manipulated so that it may fit the part perfectly, and which need not be thicker than blotting paper, has become firm, a long stocking is drawn over it and is attached to the body clothing. At the end of a week the bandage is removed. The leg and foot are gently bathed with alcohol, thoroughly dried, powdered, and protected as before, and the bandage is again applied. At this second dressing the irritable adducting muscles, after the interval of complete rest, will be much less active and the contracted tissues will be less resistant, so that the foot may be easily turned somewhat outward or beyond the line of the leg.

After four or five applications of the bandage, at weekly intervals, the foot, in ordinary cases, can be held without resistance in the attitude of extreme equinovalgus. The sole, which at first looked backward, inward, and upward, will be turned in the opposite direction, forward, outward, and downward, and the inner border of the foot, which was concave, is now convex (Fig. 440). When the varus has thus been overcorrected, treatment is directed to the secondary equinus. At this stage it is well to cover the bottom of the foot with a foot plate of thin wood (splint wood or cigar-box cover) to give the plaster bandage more solidity, and in order that its pressure may aid in flattening the rounded sole. At first one carries the foot upward (toward dorsal flexion), while it is still retained in the abducted position, but when the right-angled attitude has been attained it is brought nearer to the axis of the leg. The everted position, or the attitude opposed to varus, is retained, however, until correction is completed. In correcting the equinus a certain amount of force is required, sufficient to cause some discomfort during the application of the plaster, but not sufficient to occasion suffering afterward. The force is applied by means of the sole plate to the entire foot, so that the posterior extremity of the os calcis may be drawn downward by actual lengthening of the tendo Achillis, and not, as is often the case, by an overcorrection of the

forefoot, while the heel remains in its original position of plantar flexion. By the proper application of force the equinus is gradually overcome; the sharp indentation or fold at the insertion of the tendo Achillis is lessened, and the heel becomes more prominent.

The reduction of the equinus may be somewhat more difficult than that of the varus, but it should be entirely corrected in three or four months from the time of beginning the treatment. As has been stated, correction of the deformity implies overcor-

FIG. 450.

The first application of the plaster bandage, showing the improved position. (Compare with Fig. 444.)

rection (Fig. 439); and it is well, when this has been attained, to hold the foot for several weeks, by means of the plaster bandage, in an attitude of extreme pronation and dorsal flexion (calcaneovalgus) in order to impress, as it were, the new position upon its structure. This concludes the first stage of the treatment, the simple rectification of deformity.

Correction by the plaster bandage has the great advantage of placing the treatment entirely under the control of the surgeon. When properly applied, the support fits perfectly, it is

light and clean, and it holds the foot in the desired attitude without undue pressure.

The disadvantages of the treatment are due almost entirely to its improper application. For instance, the bandage may be too heavy, or the padding may be so thick that it does not retain its position. Excoriations are usually due to carelessness in the application of the bandage, or because it is not removed in proper season. The fear of compression, of atrophy of muscles, of stunting the growth of the limb is groundless. At the end of the plaster-of-Paris treatment, the corrected foot is, as a rule, larger than one that has remained untreated. The stunted foot is the result of non-treatment, or of ineffective treatment by braces or otherwise; not of the enforced rest necessitated by the proper reduction of deformity.

The Rectification of Deformity by Splints and Braces. Of mechanical supports there are many varieties. Complicated appliances should be avoided because they are unnecessary and because they serve to distract attention from the prime object of treatment, the rapid and systematic correction of deformity. Of the simpler braces that used by Judson is one of the best and will serve as a type to illustrate this form of treatment. The method of application may be described in Judson's own words: "The apparatus which I have conveniently used to effect this reduction before the child learns to stand is a simple retentive brace which acts as a lever, making pressure on the outer side of the foot and ankle at A, in Figs. 451 to 454, inclusive, and counter-pressure at two points, one on the inner side of the leg at B, and the other at the inner border of the foot at C. It is advisable to keep in mind that this simple instrument is a lever, because if we know that we are using a lever with its three well-defined points of pressure we can make the apparatus more efficient than if we view it, in a more general way, as an apparatus for giving a better shape to the foot.

"I use a little brace made of sheet brass, doing the work with a few simple tools. An advantage of doing the work one's self is that there is no room for doubt as to where the blame lies if the apparatus does not work well. Two curved disks, B and C, Figs. 453 and 454, are riveted to a shank, D, and thus is formed that part of the brace which applies the two points of counter-pressure; while, on the other hand, the point of pressure is brought into action by a third disk or shield, A, which is drawn tightly against the outer side of the foot and ankle, and held in

place by a strip of adhesive plaster, E, which includes the leg and the piece which connects the two disks, B and C. The disks are lined with two or three thicknesses of blanket, easily renewed, when necessary, with a needle and thread. These braces are so cheap and easily knocked together that it is nothing to apply new and larger ones, using heavier material for the shank as the child grows. In general, three sizes will be enough, the shanks being 12 gauge, $\frac{3}{8}$ in. wide; 14 gauge, $\frac{1}{2}$ in. wide; and 16 gauge, $\frac{5}{8}$ in. wide. The disks are conveniently made from 22 gauge, $1\frac{1}{4}$ in. wide. The rivets are copper belt rivets, No. 13. A lip turned on the edges of the disks, with the flat pliers, gives

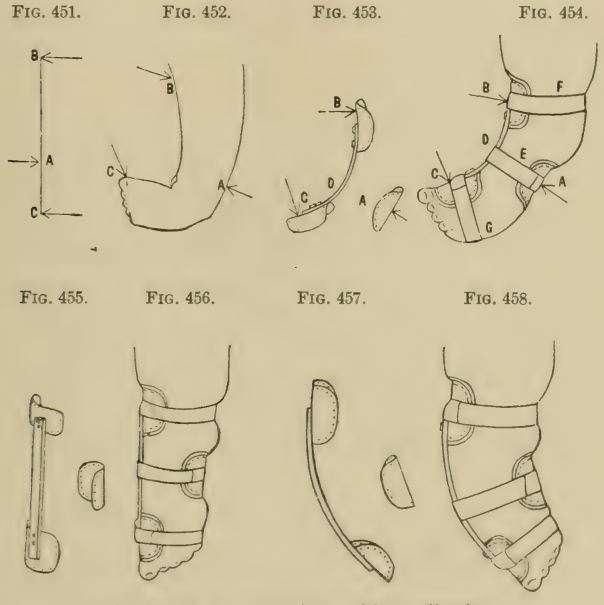

The Judson club-foot splint and its application.

stiffness to the thin brass and protects the skin from the rough edge. If more easily obtained, tin disks, light bars of iron or steel, and ordinary iron rivets would doubtless answer.

"The brace is applied with three strips of adhesive plaster. The upper and lower pieces, F and G, Fig. 454, are simply to keep the apparatus in place, which they do effectively if ordinary gum plaster is used; while by drawing the middle strip, E, tightly over the shield, and straightening the brace from time to time, the deformity is gradually and gently reduced. At each reapplication the brace is made a little straighter than the foot at that

stage. This may readily be done by the hands, and then the adhesive strip is to be tightened over the shield until the shape of the foot agrees with that of the brace. After a few days the brace is to be made still straighter and again reapplied, and made tight until another point of improvement is gained. The brace is applied very crooked at the beginning of treatment, as in Figs. 453 and 454, and is straightened from time to time, and a longer brace applied as the deformity is reduced and the patient grows. It should be removed every week or two weeks, and an interval of a few days allowed for freedom from the brace, when the mother is advised to manipulate the foot constantly, using as much force as she will in the direction of symmetry. Manipulating the foot during these intervals is of great importance, as cases have occurred in which varus and equinus have been entirely overcome by the mother's hand alone.

"By this simple and prosy treatment, carried out systematically and without haste, or violence, or pain, the foot, unless it is a frightful exception, may with certainty be changed from varus to valgus. At the same time the tendo Achillis is lengthened until the position of the foot is near the normal, or at right angles with the leg, as the result of manipulation and giving the brace from time to time a partly anteroposterior action. Figs. 453 and 454 show approximately the shape of the brace at the beginning of treatment; Figs. 455 and 456 when the varus is reduced, and Figs. 457 and 458 when valgus has taken the place of varus. The foot, in this latter stage, may not hold itself valgus when left to itself, but with almost no force and with one finger it may be pushed into valgus."

When the varus deformity is reduced the equinus is gradually corrected by carrying the splint behind the internal malleolus; and, finally, if necessary, direct upward pressure may be applied by lengthening the brace and applying it to the posterior aspect of the foot and leg. It may be noted that manipulation and stretching the contracted parts when the brace is removed is of much importance in the correction of deformity by this or other means. Splints of wood, tin, felt, and the like may be employed, but they present no particular advantage over that which has been described.

Tenotomy. The equinus has been spoken of as the secondary deformity, but its complete correction is often more difficult than that of varus. The mechanical stretching of the contracted parts by means of the plaster-of-Paris bandage or the brace is often

accomplished with ease; but in many instances time will be gained, after the foot has been forced into the position of equinovalgus, by the division of the tendo Achillis, which is the most resistant of the shortened tissues. After division of the tendon it is often necessary to use considerable force to stretch the other contracted parts, and to force the foot up to the limit of normal dorsal flexion, which is the object of the operation. Occasionally the obstacle seems to be in the posterior ligament of the ankle, and it is sometimes of service to reinsert the knife and to divide this structure, in part at least, so that it will give way under manipulation. When the foot has been forced into the position of overcorrection it is fixed in a plaster bandage, which is allowed to remain for several weeks, until the interval between the separated ends of the tendon is filled in with the new tissue.

In many instances the leg is rotated inward upon the thigh, and the habitual attitude is accompanied by accommodative changes in the ligaments of the knee-joint. During the rectification of the club-foot this secondary distortion may be, in part at least, corrected by forcible manual rotation of the leg outward on the thigh several times daily.

Recapitulation. The management of the first stage of the treatment of infantile club-foot is, then: manipulation of the foot by the nurse from birth until systematic rectification can be begun; mechanical correction, first of the varus and then of the equinus deformity, terminating with a period of retention in the overcorrected position (calcaneovalgus). Division of tendons, other than the tendo Achillis, is not often necessary. The time required for the completion of the first stage of the treatment, or overcorrection of deformity, should not, under favorable conditions, exceed three months.

The rapid correction of deformity in the manner described, begun as early as possible and accomplished as quickly as possible, cannot be too strongly urged. In the first months of life the tissues are not resistant, the bones are practically entirely cartilaginous, and when the foot in its external appearance is rectified the rapid growth in the first months of life will change the internal structure to conform to the normal conditions. The fear of atrophy, compression, or other harm from the temporary fixation necessary during rectification is groundless, and, in fact, exercise, so-called, except in the direction opposed to deformity, is harmful rather than beneficial.

Correction of deformity may be accomplished by holding the foot in an improved position by strips of adhesive plaster, or by the elastic traction of rubber bands attached to the leg and foot. As compared with the ease, rapidity, and certainty of correction by means of the plaster bandage such methods are uncertain and ineffective, and they will not therefore be described in detail.

The Second Stage of Treatment. Support and Restoration of Function. When the deformed foot has been corrected, in the sense that all normal motions can be carried out by passive force, the first and most difficult part of the treatment will have been completed, and, in some instances, the deformity is actually cured. Such a result is unusual, however, for although the foot may be normal in appearance, its muscular balance has not been restored. This is shown by the fact that when support is removed the foot usually hangs downward and inward, and there is little apparent power in the dorsiflexors and abductors to draw it upward and outward. If at this stage treatment were abandoned the deformity would almost invariably recur, at least in part. For this reason the foot must be supported in proper position until the slack of the lengthened tissues has been taken up by development in the normal attitude, aided by massage and stimulation of the muscles. Practically, support is always necessary until the child has begun to walk.

The Retention Brace. The form of retention brace will vary somewhat according to the indications of the individual case. The object is to hold the foot in what is called the overcorrected attitude—that is, dorsiflexion and eversion. This may be accomplished by splints of pasteboard, leather, tin, and the like; but a light metal brace provided with a sole plate and upright, as shown in Figs. 483 and 484, is preferable. The best support is the Taylor brace, the invention of Dr. C. F. Taylor, of New York (Fig. 459). This consists essentially of a light upright that extends along the inner side of the leg to the knee, and a thin steel foot plate of the exact size of the sole, with an upright flange on the inner side, rising to a point just above the dorsal surface of the foot, against which the foot is pressed closely, so that recurrence of the varus deformity is prevented. The joint at the ankle is provided with a catch that prevents plantar flexion, but allows dorsiflexion. By bending the upright and the sole plate the foot may be held in slight abduction and eversion. The apparatus is applied with straps, as illustrated, and, if necessary, its position is further fixed by a band of adhesive plaster,

applied on the inner side of the leg to hold the heel firmly against the foot plate. The foot is thus held constantly at a

FIG. 459.

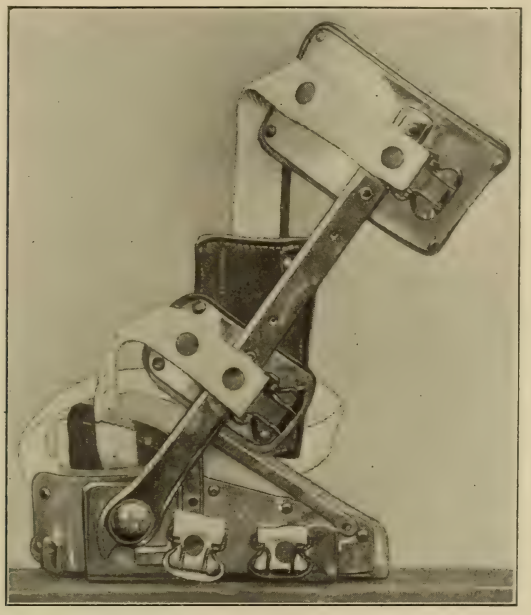

The Taylor club-foot brace.

FIG. 460.

FIG. 461.

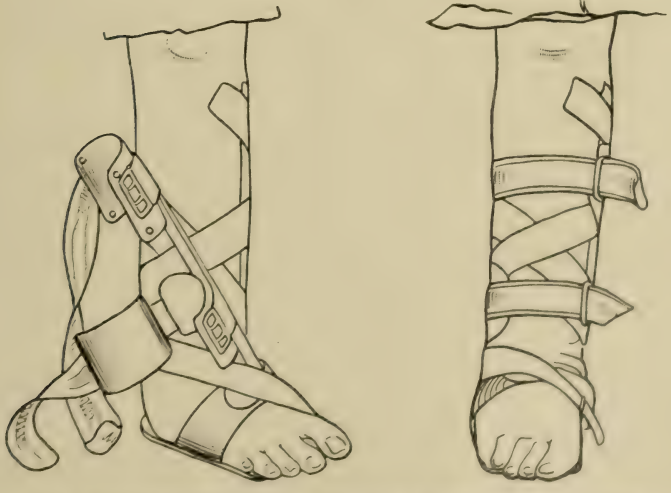

Taylor club-foot brace, showing the method of application and attachment.

right angle to the leg, or, better, in the early stage of treatment, in an attitude of dorsiflexion and valgus. Occasionally, after complete rectification of the deformity, the foot still turns in. In most instances this is due to an inward rotation of the tibia on the femur at the knee-joint, but in some cases it is caused by a spiral twist of the tibia itself. In order to correct this secondary deformity an extension of the upright of the brace is carried beneath the leg, provided with a joint at the knee, and is extended up the outer side of the thigh. At the hip it is attached by a free joint to a padded pelvic band of light steel (Fig. 470). The band holds the upright in the proper relation to the thigh; thus,

FIG. 462.

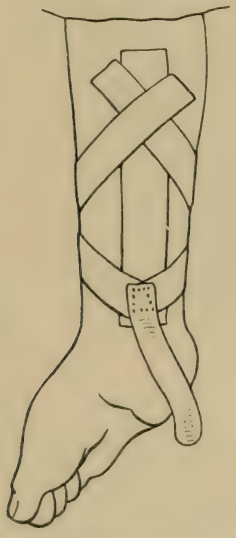

FIG. 463.

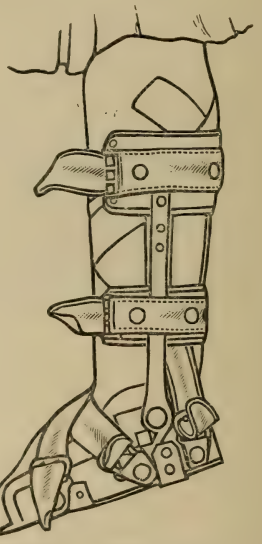

The Taylor club-foot brace, showing the adhesive plaster, by means of which the heel is held down, and the method of attachment. This brace may be used to correct deformity as well as to retain the foot in proper position, as is illustrated by these figures. As a retention apparatus the foot plate should be held at a right angle to the upright by the stop-joint shown in Fig. 459.

by twisting the part below the knee the foot can be rotated outward to the desired degree. In less marked cases the retention bands used for pigeon-toe may be employed (Fig. 426).

METHODICAL MANUAL CORRECTION. Several times during the day the brace should be removed in order that the foot may be thoroughly massaged and forcibly turned, first toward valgus —that is, outward at the mediotarsal joint—so that the inner border is made convex, and then to the extreme limit of dorsiflexion and abduction. If the leg is rotated inward it is forcibly

rotated outward on the femur. Even if the tibia is actually twisted on its long axis, the influence of the brace and forcible manipulation will usually correct the deformity. Active contraction of the weak muscles may be induced by tickling the sole of the foot or by the use of electricity, and, finally, the entire limb should be thoroughly massaged before the brace is reapplied.

When the deformity shows no tendency to recur the brace may be removed for a part of the day; later it is used only at night; and, finally, it may be discarded if the child walks normally. But it is best to continue the daily manipulation, more particularly the systematic stretching or overcorrection of the foot, for a long time. Thus one may assure one's self that there is no tendency toward deformity, of which the first symptom is always a slight limitation of dorsal flexion and of abduction.

In many instances the deformity may have been so thoroughly overcorrected by the plaster-of-Paris bandage or by the brace, and the after-treatment of massage and stretching may have been so efficiently applied by the nurse or parent, that the retention brace may be unnecessary. On the other hand, the inclination toward deformity may be so marked that a brace may be necessary to hold the foot in slight abduction and valgus for a year or longer. In other cases the use of a light brace to hold the foot in the overcorrected position during the night is alone required. These are points to be decided by the circumstances in each case. The period of observation and supervision is included in the final stage of the treatment.

Third Stage of Treatment. Supervision. During this period the attitudes of the limb and foot of the walking child must be carefully watched, and particularly the signs of wear on the sole of the shoe. If it shows greater wear on the outer side than is usual it is an indication that the weight does not fall directly on the centre of the foot, and that there is, therefore, a tendency toward deformity. This must be counteracted by making the sole thicker on the outer side or slightly wedge-shaped, so that the weight may be deflected toward the inner border.

This third period of treatment, or, rather, of oversight of the functional use of the foot, must be continued indefinitely. In fact, it is the quality of this final supervision that decides in most instances whether the ultimate outcome is to be what is called a satisfactory result or a perfect anatomical and functional cure.

The Treatment of Neglected Club-foot. The treatment of club-foot, under what may be called the proper conditions, as

outlined in the preceding pages, applies practically to all cases before the completion of the first year of life, and mechanical rectification may be successfully employed in cases far beyond this limit of age. As a rule, however, when the patient has walked for any length of time, the resistance of the tissues has increased to such an extent that more rapid and effective treatment is indicated. The investigations of Wolff have shown that the internal structure of the bones corresponds to their external contour, and that the structure and contour are adaptations to functional use. This internal structure is not, however, permanent, but is readily transformed to conform to changes in form or function. If, then, the external contour of the club-foot were suddenly reversed, and if the foot were used in this new attitude, a transformation of the internal structure of the bones and at the same time of their shape would begin at once. This would continue until both structure and shape had become adapted to habitual function. It is upon this natural power of transformation that one depends for the final and complete change of the distorted bones to the normal; and what is true of a resistant structure like bone is equally true of the other constituents of the deformed foot.

Age as Influencing Treatment. There is, then, this important difference between the indications for treatment in infancy and in childhood. In the first instance the foot has no essential function; in the second the weight of the body and habitual use tend to confirm and to increase the deformity. If walking is permitted during the process of rectification of the foot it must necessarily retard its progress. As a general principle of treatment, functional use should not be permitted, therefore, until the weight of the body may aid rather than retard the correction of deformity. The great numbers of complicated and cumbersome machines that are shown in the older text-books were designed for the ambulatory treatment of club-foot; and admitting that such apparatus may be efficacious in the hands of one skilled in its use, yet under ordinary conditions treatment by such means simply serves to fix rather than to correct the deformity. The most important function of the brace, aside from its use as a correcting appliance in early infancy, is to support the foot after deformity has been corrected and to guide it in its functional use until its normal strength has been regained. And while rectification of deformity, even in adolescence, by simple mechanical means alone is possible, yet only in exceptional cases would one

be justified in selecting a tedious and uncertain treatment which offers practically no advantage over more rapid methods.

The Rapid Correction of Deformity. The principles on which operative treatment should be conducted are the same that govern mechanical treatment. Thus, the deformed foot must be overcorrected, and it must be held in the overcorrected position until the immediate tendency toward deformity has been overcome. It must then be supported until the process of transformation of its internal structure is completed and until the balance of muscular power has been regained. No surgical operation, however

FIG. 464.

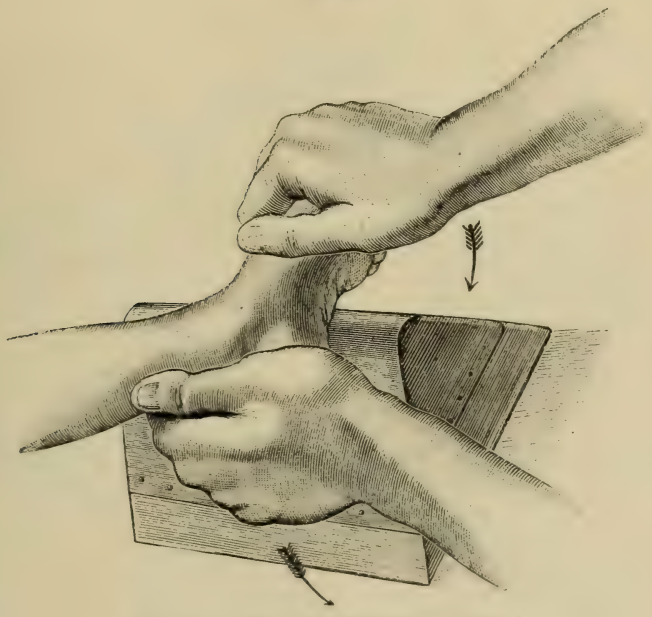

Reduction of the varus deformity. (Lorenz.)

radical, can be, in childhood at least, curative by itself alone. Operative procedures are undertaken simply for the purpose of accomplishing the primary overcorrection, and the operation by which this object can be attained with the least interference with the structure of the foot should be selected. Such an operation is what may be called forcible manual correction.

Forcible Manual Correction. The patient having been anæsthetized, one first attempts to correct the sharp inward twist at the mediotarsal joint. Supposing the left foot to be deformed, one grasps the heel with the right hand in such a manner that

the projection or muscular part of the palm lies on the outer aspect of the foot against the most prominent part of its outer border, which is at the junction of the os calcis and cuboid bones. This hand serves as a fulcrum over which the inverted foot may be bent. The forefoot is then grasped firmly by the left hand, and one begins a series of outward twists over the fulcrum of the opposing palm, gently at first, with alternate relaxation of pressure, but with gradually increasing force as the resistant tissues stretch under the tension.

FIG. 465.

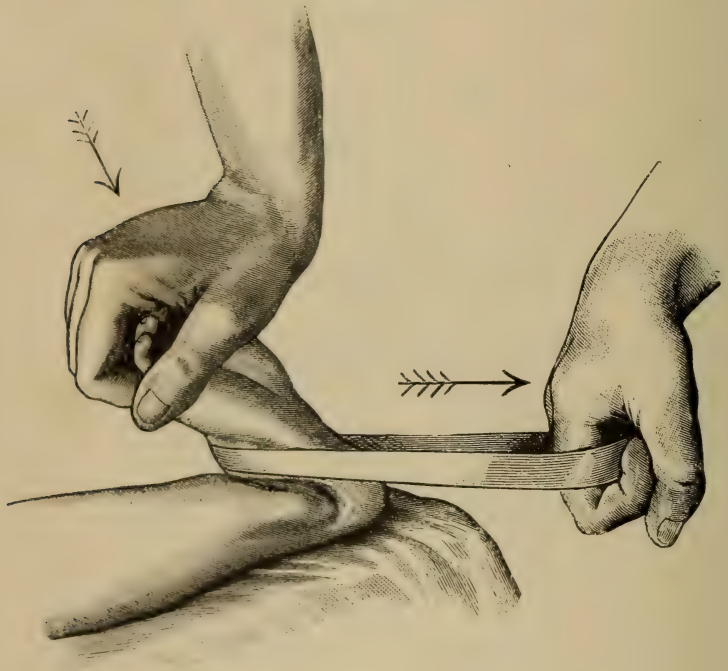

Flattening the sole. (Lorenz.)

If greater force is required, a triangular block of wood, well padded, may be used as the fulcrum (Fig. 464), one hand pressing on the heel and the other on the forefoot; but there is a great advantage in using nothing but the hands, because one feels sure that no injurious force is likely to be exerted. Under this steady manipulation the foot soon loses its rigidity and its elastic recoil toward deformity; it becomes so limp that with two fingers one cannot only hold the sole straight, but can push it or bend it

outward. Thus the first stage of the methodical correction has been accomplished.

One then turns his attention to the supination or inversion of the sole, which makes the outer border of the foot lower than the inner border. The leg is grasped firmly near the ankle with the left hand, and with the right the foot is forcibly twisted in a direction downward, outward, and upward, over and over again, with steadily increasing force as the tissues slowly yield, until it may be forced into a position of extreme abduction, so that the

FIG. 466.

Reduction of the equinus deformity. (Lorenz.)

sole may be made to look outward and downward—the reverse of the former attitude (Fig. 384).

One next stretches the contracted plantar fascia and reduces the cavus which is usually present by forcing the forefoot toward dorsiflexion, against the resistance of the contracted tendo Achillis, until the sole is made perfectly flat (Fig. 465). Finally, the fourth, and often the most difficult part of the rectification—that of forcing the displaced astragalus into its proper position between the malleoli—is attempted. To accomplish this the tendo Achillis is first divided subcutaneously, and, if necessary, the posterior

ligament of the ankle is also divided at the same time. The patient is then turned upon his face so that with the knee resting on the table the leg is held upright. This allows one to hook the fingers about the extremity of the os calcis, while the hand and arm, lying along the sole of the foot, may be used as a lever to force it toward dorsal flexion as the os calcis is drawn downward. In this manner forcible stretching is continued until the dorsum of the foot can be brought almost into apposition with the crest of the tibia. When the operation has been completed

FIG. 467.

Untreated club-foot, showing the secondary knock-knees. (See Fig. 468.)

the foot should be perfectly limp. It is usually somewhat congested from the pressure of the fingers, but it is warm and the circulation is unimpaired.

One may assume that in the change that has taken place from rigid deformity to a limp foot that can be moulded into the desired shape the component parts of the deformed foot must have been subjected to considerable violence; that ligaments and muscles must have been stretched and, it may be, ruptured; that new surfaces are now apposed to one another in the articulations, and that the bones have been forced into approximately

normal position. This method of treatment has a great advantage over the ordinary operative treatment in that the entire foot participates in the correction instead of a limited portion, as when, for example, bone is removed by cuneiform osteotomy. It has a second and almost equally important advantage in that the immediate use of the corrected and yielding foot is possible in the place of the necessary rest that must follow cutting operations. For these reasons forcible massage should be the operation of choice, and preliminary, at least, to more severe procedures

FIG. 468.



After forcible correction. Compare with Fig. 467.

FIG. 469.

The attitude of overcorrection, in which the feet are fixed after the operative treatment, the plaster bandage extending only to the knees.

in the treatment of resistant club-foot in childhood. The only disadvantage of the operation is the actual labor which it necessitates on the part of the surgeon, usually twenty minutes or more of rather exhausting work.

The foot must now be fixed by a plaster bandage in an overcorrected position. It is first evenly covered with a layer of cotton and a broad bandage of canton flannel, and while it is held by the assistant the plaster bandages are applied from the tips of the toes to the upper part of the thigh. It is important that the

toes should not project beyond the bandage because of the swelling that sometimes follows. It is important, also, that the foot should be held in the proper position while the bandage is hardening, and that it should not be manipulated to any extent after the bandage is applied, in order that no rigid wrinkle may press against the skin. The bandage is applied above the knee in order that the tibia may be rotated outward to its normal position and held there, and because more effective fixation may be assured and greater pressure exerted on the foot in walking. To utilize this pressure to better advantage the bandage should be made very thick beneath the sole, and a thin foot plate of wood may be incorporated in the plaster if due care is taken to prevent pressure on sensitive points. When the bandage is applied the position of the foot should be that of overcorrection of deformity, flexed beyond the right angle, twisted far outward, and the outer border should be elevated considerably beyond the level of the inner border (Fig. 468).

One would suppose, after using the force that has been necessarily applied, that much pain and swelling would follow. This is, however, not usually the case. Often, on the following day, the patients are able to stand upon the foot, and always within the first week if the bandage has been properly applied. The pain following this operation is far more often caused by pressure of an ill-fitting bandage than by the violence that has been used. Thus one should be careful to remove sections of the bandage if it appears to cause undue discomfort. These points are usually the front of the ankle, the back of the heel, and the inner border of the great toe.

The Importance of Functional Use. The immediate use of the foot is encouraged, in order that the weight of the body falling on its yielding structure may still further correct the deformity. Although only the heel and inner border bear weight directly, yet the pressure of the plaster sole on the parts that do not come in contact with the floor is usually sufficient to mould the foot into its proper shape. If greater pressure is thought to be necessary, wedges of wood or cork may be attached to the sole of the plaster bandage, so that all parts may bear weight equally. The bandage is covered by a stocking ; a slipper may be worn indoors and an ordinary overshoe for street wear.

The first bandage should be removed at the end of about four weeks, as it will have become loose. The foot will then be found to be extremely flexible, and by an enthusiast it might be consid-

ered cured; but knowledge of its previous condition should make it evident that a much longer time will be necessary to allow for its consolidation in the new position. At this time almost no evidence of the operation remains except, it may be, slight discoloration of the skin. The foot is again held as far as possible in the overcorrected position and another plaster bandage is applied, usually as far as the knee only. This is allowed to remain for from six weeks to six months, it being apparent, of course, that the longer the foot is fixed in the overcorrected position the less danger of subsequent relapse. The patient uses the foot constantly and is drilled in the proper method of walking, so that the muscles of the limbs may become accustomed to the new and normal attitudes.

In most instances the plaster bandage is replaced, at the end of about three months, by a brace, to be worn inside the shoe, usually of the simplest description (Fig. 484), consisting of an upright bar with a calf band, attached to a steel sole plate by a joint that will permit dorsal flexion but checks extension at a right angle. This is applied because the dorsal flexors, after years of disuse, only slowly recover sufficient power to resist the action of the opposing group and the force of gravity.

The second stage of the treatment is now begun. This may be divided into a period of active treatment and one of supervision. The first, or treatment stage, consists in massage of the entire leg and of the foot to stimulate the growth of the atrophied muscles, and methodical manipulation of the foot several times a day. The important point in this manipulation is to force the foot with the hand to the extreme of the range of motions possible immediately after the operation, viz., eversion, abduction, and dorsal flexion, in the same order as at the time of operation. At the same time the patient attempts voluntarily to carry out these motions by his own muscles, the power being supplied by the hand of the manipulator. Slowly the muscles gain in strength and ability, and when normal muscular power and balance have been regained the patient is practically cured. But for a long period supervision of the patient's attitude, of the manner of using the foot, of the wear of the sole of the shoe and the like must be exercised if one aims to restore its normal appearance and function.

One cannot exaggerate the importance of this after-treatment and of supervision, at least, on the part of the surgeon. The active treatment may often be left to the parents. But constant

oversight is necessary to make this after-treatment, which seems so commonplace and simple, effective, and to assure one's self that the range of motion regained by the operation does not gradually become more and more restricted, even though the contour of the foot appears to be normal.

Forcible manual correction may be employed with advantage from the second to the tenth year, although the limits may be extended in either direction in special cases. In this operation, as described, the tendo Achillis is the only structure divided. There is no particular objection to subcutaneous division of other tendons or ligaments in connection with forcible manual correction; but for such prolonged manipulation it is much better if the skin, which itself must be stretched, is unbroken and dry rather than moist from the bleeding from punctured wounds. For this reason it is well to correct the deformity without extensive tenotomy if possible.[1]

Fig. 470.

The Taylor club-foot brace, with pelvic band, to prevent rotation of the leg. The brace is shown before the covering and straps are applied.

Secondary Deformities. In cases such as have been described secondary distortions of the limb are often present. Knock-knee rarely requires other treatment than daily manual correction in connection with the massage of the foot and leg. Hyperextension at the knee will correct itself during the treatment of the foot, which, being fixed in an attitude of dorsal flexion, obliges the patient to bend the knee habitually in walking. Inward rotation of the leg upon the thigh is often present. This may be overcome

[1] Forcible manual correction appears to have been described first by Delore. Lorenz employs the method supplemented in the older cases by the use of his osteoclast, to the exclusion, practically, of all other treatment. (Heilung des Klumpfusses durch das modellirende Redressement, Wiener Klinik, November, 1895.) For this reason it is sometimes called the Lorenz treatment. The method that has been described has been employed by the author for many years.

by methodical manipulation and by the use of a brace attached to a pelvic band (Fig. 470).

In many instances, particularly in childhood and adolescence, the patient has so long walked with exaggerated outward rotation of the femur that after correction of the deformity no inward rotation of the foot appears, even though inward rotation of the tibia be present. In other cases the inward rotation of the foot is caused by a failure to completely replace the astragalus between the malleoli. Occasionally the tibia is actually twisted on its long axis, so that an osteotomy may be required in order to overcome the deformity.

Malleotomy. In confirmed club-foot, of the type under consideration, the chief obstacle to perfect correction is often the astragalus. This is displaced forward, downward, and inward, only the posterior portion of its articulating surface being contained between the malleoli. Thus the space between the two bones may have become insufficient for the anterior and wider part of the body of the astragalus. In such cases, even after division of the tendo Achillis and the posterior ligament of the ankle, dorsal flexion still remains restricted, and examination shows that the astragalus still projects as before, even though the foot has been forced into a position of apparent dorsiflexion and abduction. This apparent correction is the result of overcorrection at the mediotarsal joint, of outward rotation of the tibia upon the femur, and of backward displacement of the fibula.

In such instances the malleoli may be separated from one another by dividing the ligaments that hold them in apposition. A straight incision about two inches long is made directly over the anterior aspect of the articulation, the ligaments are divided, and by inserting a thin chisel the bones are pried apart, while the astragalus is replaced in the proper position. This is usually easy if the restraining tissues on the posterior part of the ankle have been divided. The wound is then closed and the foot held in the overcorrected position by a plaster bandage. Complete correction of the varus deformity should, of course, precede this operation.

It might seem on first consideration that if immediate correction of deformity can be accomplished so easily in the confirmed cases it should be employed even in infancy. There are, however, practical reasons against it: First, because the foot is so small that it cannot be easily manipulated; second, because even after it is corrected it must be supported until the child begins to walk; and, third, because the foot can be so readily straightened

without operation, which, even of so slight a character, is sometimes the cause of much anxiety to the parents. For these reasons, although immediate reduction of deformity is a thoroughly practical and safe operation, it is usually postponed until a later time.

Subcutaneous Tenotomy. The division of tendons and other tissues by the subcutaneous method has been mentioned incidentally, but as it has so long occupied an important and even at one time the most important place in the treatment of club-foot, the operation and its effects may be described somewhat in detail.

Tenotomy, as has been stated, is performed for the purpose of removing an obstacle to the correction and overcorrection of deformity. In the acquired or paralytic form of talipes one or more shortened tendons may be the chief obstacles to reposition; but in the congenital form, in which all the tissues have grown into deformity, the shortened tendons are by no means the only resistant parts, and tenotomy should be considered, therefore, merely as an incident in correction. In the ordinary treatment of infantile club-foot tenotomy may often be dispensed with, and in the great majority of cases division of the tendo Achillis is alone required.

When the tendon has been divided the deformity is immediately overcorrected; thus the two extremities are separated to the extent necessary to allow the improved position. At the end of three weeks or more, or at the time when the first plaster bandage is removed, the space will be filled with new material, and in another month the splice, which will be somewhat larger and thicker than the normal, should be strong enough for use. The slight thickening at the site of the operation may be felt for a year or more, but for all intents and purposes the new and lengthened tendon is perfectly normal, as is the function of the muscle of which it is a part.

The process of repair is somewhat as follows: Immediately after the operation the space between the divided ends of the tendon is filled or partially filled with blood; then leucocytes appear, which, with those in the blood clot, serve as pabulum for the plasma cells which migrate from between the fasciculi of the tendon and from the tendon sheath. The fibrin and red corpuscles of the clot are absorbed; the extremities of the divided tendon soften and become fused with the new material, which begins to take on the form and consistency of true tendon and to separate itself from the adherent sheath. This new tendon, differs from the normal structure in that the fibrous fasciculi

are more irregular and its substance is more like scar tissue, but practically it is perfectly normal in its appearance and function.[1]

Since the tendon sheath serves an important purpose in repair, it should be disturbed as little as possible. For this, as well as for other obvious reasons, subcutaneous tenotomy of the tendo Achillis, which is so prominent and so distinct from other important parts, is to be preferred; but if more extensive division of other tendons is required the open operation is often indicated.

Division of the Tendo Achillis. For this operation anæsthesia is usually required, preferably by means of nitrous oxide gas; and it is hardly necessary to state that surgical cleanliness, even in so slight a procedure, is essential.

The instrument should be small and very sharp, so that no force is required in the operation; the blade should be as long as the tendon is wide. The patient is turned upon the side or to the prone position, so that the foot may be held with the heel upward by the left hand. The position and size of the tendon is ascertained by careful palpation, and the knife is then inserted to its inner side, at about the level of the extremity of the internal malleolus. The flat surface of the blade is held parallel to the tendon, and it is passed beneath it until its point can be felt beneath the skin on the opposite side. The edge is then turned upward and the tendon, being made tense, is divided by a sawing motion of the knife. When the division is complete, as indicated by the separation of the divided ends, the knife is withdrawn, and the minute opening in the skin, from which there is usually slight bleeding, is covered with a pledget of aseptic cotton. The foot is forced into dorsal flexion and is securely fixed by a plaster bandage. In applying the dressing one should take care that no pressure is brought upon the seat of operation, as this might interfere with the effusion of plastic material. As soon as the discomfort attending the operation has subsided the patient is encouraged to stand and to walk. Functional use stimulates the circulation, and, far from retarding repair, it is in my experience an important agent in assuring firm and rapid union.

The Open Method. The tendon may be exposed by a long, vertical incision; it is then split for a distance of two or three inches, and the division is completed at the upper and lower ends. The two halves are then allowed to slide by one another until the necessary elongation has been obtained. These are then sutured to one another.

[1] R. Seggel. Beiträge zur klin. Chir., 1903, Band xxxvii. S. 342.

Theoretically, this operation, which assures union at a point of selection, is safer than the subcutaneous method, in which the ends of the tendon are separated from one another; practically, it is in this class of cases less satisfactory in its results than the subcutaneous method.

Division of the *plantar fascia* is not infrequently necessary, and should be performed subcutaneously. The tenotome is inserted beneath the skin at about the centre of the concavity to one or the other side of the central band of the fascia, which is divided by a sawing motion of the knife. The part is put upon the stretch, and other resisting bands to the outer and inner side are divided in the same manner; the cavus is then corrected by manual or instrumental force. The operation, like that upon the tendo Achillis, is practically free from danger.

Division of the *tibialis anticus* is not often necessary, as this tendon offers little resistance to the rectification of deformity of the ordinary type.

The tendon of the *tibialis posticus* may be divided together with that of the tibialis anticus near the points of attachment. If the operation is required it may be combined with simultaneous section of the *calcaneonavicular ligament*, with which are blended the anterior part of the deltoid and fibres of the anterior ligament of the ankle. According to Parker's directions, the foot should be strongly abducted to make the parts tense. The tenotome is entered directly in front of the anterior border of the internal malleolus, its cutting edge being turned forward between the skin and the ligament. It is then turned toward the ligament, and the tissues are divided to the bone. The blade is then made to enter the interval between the astragalus and the scaphoid, and is carried downward and forward to divide the inferior part of the ligament and at the same time the tendons of the tibialis anticus and posticus.

The posterior ligament of the ankle-joint may be divided or sufficiently weakened so that it may be ruptured after section of the tendo Achillis by passing the knife directly downward in the middle line upon the upper border of the astragalus.

The Correction of Confirmed Club-foot by the Method of Julius Wolff.

Wolff's treatment of club-foot, as described by Freiberg, a former assistant in his clinic, may be summarized as follows:[1]

[1] Medical News, October 29, 1892.

The patient is anæsthetized, and with the hands and by the use of a moderate amount of force the deformity is reduced as far as possible. The foot is held in the improved position by means of strips of adhesive plaster passing from the dorsal surface of the inner border of the foot under the sole and up to the outer aspect of the leg. The leg and foot are then covered with cotton from the tuberosity of the tibia to the tips of the toes, and a plaster bandage is applied. As the plaster is hardening the position of the foot is still further improved by pressing the heel inward and the forefoot outward and upward. Two fenestra are cut in the plaster at the points of greatest pressure—one over the external surface of the ankle and the other over the internal surface of the great toe. If tenotomy is considered necessary it is usually performed as a preliminary operation several days before forcible correction.

FIG. 471.

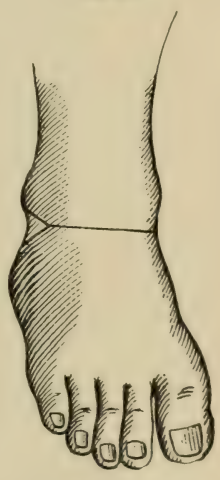

The points at which the bandage is divided and the wedge removed. (Freiberg.)

On the third or fourth day after the operation a wedge-shaped section is cut from the bandage on the outer side of the ankle-joint and a linear division is made about the ankle, so that the leg and the foot parts of the bandage are separated (Fig. 471). The leg being held firmly, the foot is forced outward and upward to the extent that the wedge-shaped opening on the plaster will allow, and the two sections are then united by a covering of plaster bandage. For the secondary correction anæsthesia is not required. At intervals of several days larger wedges are removed, and the manipulation is repeated until the patient stands with the foot in a satisfactory attitude; that is, in pronation, abduction, and dorsiflexion. If the deformity is extreme the bandage may be reapplied before the correction is completed with advantage. One should take care that the toes are not compressed, but lie on the same plane in normal relation to one another.

When rectification is complete the plaster bandage is covered with strips of pine shavings, held in place by a crinoline bandage, and painted with carpenter's glue. When this is hardened the whole is covered with a thin silicate bandage; over this the shoe is fitted and the patient is encouraged to walk. This form of dressing is used until the transformation of the deformed parts may

be supposed to be complete, the time varying with the case, from a few months to a year. The time required for the primary correction is from a week to a month. When the bandage is finally removed massage and exercises are to be employed.[1]

Wolff's treatment is an efficient means of correction, although somewhat tedious. It may be more conveniently employed in later childhood and adolescence than at an earlier age.

Forcible Correction of Deformity by Means of Osteoclasts and Wrenches.

In place of manual correction greater force may be employed by means of wrenches or osteoclasts to overcome the deformity. There is this important difference between the two procedures: force may be applied by the hands for as long a time as is necessary without fear of injury, while force applied by a machine must be momentary because of the pressure and strain on the parts where the leverage is exerted. Manual force continuously applied may be supposed to stretch the resistant parts, and although much less power is exerted it is really more effective than the sudden and momentary force of the wrench or osteoclast, because it may be continued until the deformity has been overcorrected, while complete correction by means of instruments may necessitate several operations.

FIG. 472.

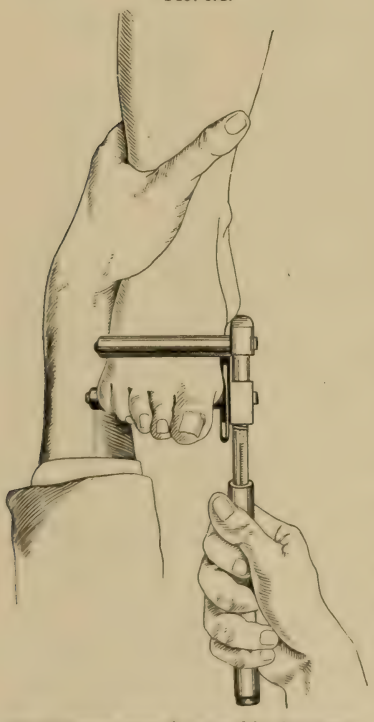

The Thomas wrench as used in the correction of club-foot.

The Thomas Method. Of instrumental correction that by means of the Thomas wrench is one of the simplest and most efficient. The wrenching may or may not be preceded by tenotomy, a point to be decided by the resistance of the parts. As

[1] Ueber die Ursachen, das Wesen und die Behandlung des Klumpfusses. Julius Wolff Berlin, 1905.

a rule, division of the tendo Achillis alone is necessary. The instrument is a simple heavy monkey-wrench, of which the jaws have been replaced by two strong pins slightly bulbous at the ends to keep the covers of rubber tubing from slipping off.

The wrench is applied to the inner side of the foot and screwed down so that it may "bite" and hold its place firmly, for if it slips it is likely to abrade or tear the skin; then with considerable force the foot is twisted outward and upward (Fig. 472).

FIG. 473.

Resistant club-foot in later childhood. (See Fig. 474.)

The "keynote" of the operation is to so wrench the foot that it loses its elasticity and shows no tendency to recoil toward deformity. The foot is then placed in the best possible position, and is retained there by the Thomas foot splint or by a plaster bandage. In certain instances one may complete the rectification at one operation, but this is not usually attempted, the procedure being repeated at intervals of a few days until the deformity has been overcorrected. In very resistant cases eight or ten applications of force may be necessary. When the deformity has been

rectified the foot is held in the overcorrected position for several weeks by the splint or by the plaster bandage.

As a walking appliance a simple upright of iron with a calf band is applied to the inner side of the leg, from a point just below the knee to the heel of the shoe into which it is inserted, as is the Thomas knock-knee brace (Fig. 343). By bending the upright the foot may be kept in slight valgus, and this position is still further assured by making the outer side of the sole of the shoe thicker than the inner, so that the weight falls upon the inner border of the foot. In many instances the walking brace may be dispensed with in the after-treatment, but a light brace is usually worn to hold the foot in the corrected position during the night, until the power of the abductors and dorsal flexors has been regained. Massage and manipulation are used in the after-treatment in the manner already described.

When properly applied the treatment is satisfactory and free from danger. Sloughing of the tissues caused by the pressure of the instrument or by the plaster bandages has been reported, but such accidents have not occurred in the extensive practice of Thomas and Jones.

Correction by Means of the Osteoclast. The late Mr. Grattan, of Cork, used the osteoclast that goes by his name (Fig. 346) to crush and to overcorrect resistant club-foot. The operation may include besides the correction of the deformity of the foot itself fracture of the leg above the malleolus, to turn the foot toward valgus, and a second fracture half-way up the leg, to overcome the inward rotation or twist of the tibia. Mr. Grattan's results have been very satisfactory. Other appliances constructed on somewhat similar principles may be employed. Of these the Lorenz osteoclast[1] and the Bradford[2] lever apparatus are the most effective.

The Open Incision Combined with Forcible Rectification of Deformity. Phelps' Operation. When extensive division of contracted parts is indicated the open incision is to be preferred because of the opportunity thus offered for the recognition and for intelligent selection of structures that require division in the final correction of the deformity.

Phelps' operation is essentially simply the division of resistant parts through an incision on the inner border of the foot, combined with sufficient force, manual or instrumental, to overcorrect

[1] Wiener Klinik, November, December, 1895. [2] Bradford and Lovett, 2d ed., p. 414.

the deformity It is the most conservative of the more radical procedures, and by it even the most severe type of deformity in the adult can be corrected; that is to say, the deformity may be overcome and a serviceable foot may be assured to the patient. Perfect functional cure is not possible when deformity has become habitual after many years of neglect.

The steps of the Phelps operation are as follows: After proper surgical preparation the Esmarch bandage is applied. The tendo Achillis, and usually the posterior ligaments of the ankle, are

FIG. 474.

The deformity (Fig. 473) corrected by Phelps' operation and by cuneiform osteotomy of the os calcis.

divided subcutaneously, and by manual or instrumental force one attempts to correct the plantar flexion. An incision is then made on the inner border of the foot, just below and in front of the internal malleolus, which is extended directly downward over the head of the astragalus to include the inner quarter of the sole. Through the incision all resistant parts are divided in order, as stated by Phelps.

1. The tibialis posticus, and the anticus if it offers resistance.
2. The abductor hallucis.
3. The plantar fascia.

4. The flexor brevis digitorum.
5. The long flexor of the toes.
6. The deltoid ligament in all its branches.

During the successive division of the tissues repeated attempts are made to correct the foot, and only those structures are divided that present themselves as tense and resistant tissues when the foot is forcibly abducted.

In the adult type of club-foot no particular effort is made to recognize the different structures, but all the tissues on the inner

FIG. 475.

Resistant club-foot in later childhood. (See Fig. 476.)

side of the foot, including bloodvessels and nerves, the deep ligaments, and occasionally the tendon of the peroneus longus muscle, are divided. Even then it is necessary to apply considerable force to correct the deformity. In certain instances the rectification of deformity necessitates osteotomy of the neck of the astragalus or the removal of a cuneiform section from the os calcis. The object of the Phelps operation is, by division of resistant tissues and by the use of force, to overcorrect the deformed foot at one sitting, and as much force and as extensive

division of tissues as are required to accomplish this object should be employed by the operator.

When the foot can be held in the desired position without resistance, the wound is covered with Lister protective, the foot and leg are thickly covered with gauze and cotton, a plaster bandage is applied, and the limb is elevated. The large gaping wound closes by granulation in from one to three months. The first bandage is usually changed at the end of a month, and the patient then begins to bear weight on the foot.

By this operation the foot, even in severe cases in adult life, may be made straight in appearance. It is evident, however, that in such cases the correction of the deformity of the bones is by no means always perfect, for the forefoot may be simply twisted outward and upward, while the astragalus and os calcis may remain in an approximation to their original deformity. After thorough overcorrection by the Phelps operation the danger of recurrence of deformity in the adult and adolescent type of club-foot is not great, and in many instances support other than that of the plaster bandage for several months after the operation may be unnecessary; but in childhood the ordinary precautions in after-treatment to prevent relapse will be necessary.

Operations on the Bones.

Osteotomy of the neck of the astragalus, as a supplementary part of the operation of forcible correction, has been mentioned. In certain instances, particularly in the adolescent or adult type of deformity, the displaced astragalus may offer such an obstacle to correction that its removal is indicated—an operation first performed by Mr. Lund, of Manchester.

Astragalectomy. The astragalus, which in club-foot is displaced forward, may be removed easily by means of an incision passing over its most prominent part, in a direction forward and downward from the tip of the external malleolus, between the tendons of the peroneus brevis and tertius. The soft parts are drawn aside, the ankle and astragalonavicular joint are opened, and the attachments to the scaphoid, and, as far as possible, those at the inner and outer border, are divided. The foot is then adducted so that the head of the bone may be seized with forceps and drawn upward, the interosseous ligament and the internal lateral ligament having been divided with curved scissors, and the bone is removed. If after removal of the astragalus the deformity

cannot be corrected, the anterior part of the os calcis or the external malleolus should be removed as well. A useful movable foot may be obtained by this operation, but it by no means assures the patient from recurrence of deformity. It is never indicated as a primary operation, in childhood at least. The varus should be thoroughly corrected as a preliminary procedure; then the resistance that the astragalus offers to dorsal flexion can be estimated (Fig. 476).

FIG. 476.

After forcible correction and astragalectomy. (See Fig. 475.)

FIG. 477.

Partially corrected club-foot, showing secondary knock-knee.

Cuneiform Osteotomy. The removal of cuneiform sections of bone from the outer border of the foot is sometimes indicated when the deformity is of long standing, but the operation should be secondary to other methods of correction. The aim should be to lengthen the contracted and shortened tissues on the inner border of the foot to the extent required for reposition, not to remove bone to accommodate these shortened tissues. If this has been shown to be impossible by ordinary means, then removal of bone may be indicated; but it is not often necessary in childhood or even in adolescence. If sufficient bone is

removed from the adult foot to permit complete correction of the deformity, relapse is not usual; but in childhood, as has been stated, no operation will take the place of after-treatment.

The treatment by cuneiform osteotomy as it is ordinarily carried out is sufficiently simple. In severe cases the astragalus is usually removed, and a wedge-shaped section of bone is taken from the os calcis, cuboid, and, if necessary, it may include the scaphoid bone also. The external malleolus may be removed if it interferes with reposition. Preliminary fasciotomies and tenotomies are usually performed, but those who favor this method of treatment rarely use force in reposition. If the deformity is less marked the astragalus is not removed, but a part of its body and neck is included in the cuneiform resection. The foot is retained in proper position until the wounds are closed; then plaster bandages are employed for several months. Braces are seldom used in the after-treatment.

Secondary Osteotomy. In certain cases of relapsed or ineffectively treated club-foot, even in childhood, deformity of the os calcis either interferes with correction of the foot or favors relapse. In such instances the removal of a cuneiform section of bone from the anterior extremity, as a supplementary part of overcorrection, may be of service.

Simple Mechanical Rectification of Deformity in Walking Children and in Later Years.

It has been stated that simple mechanical rectification of deformity was possible even in adolescence, but that the time required for such treatment, usually extending over several years, as a rule, excluded it from consideration.

The simplest mechanical treatment is that by which the foot is slowly forced from equinovarus into equinovalgus by a brace on the lever principle, which is at first shaped to the deformity, and is then gradually straightened as the resistance diminishes. When the midpoint has been passed between varus and valgus the weight of the body aids in the correction of the remaining varus and equinus. The modification of the Taylor brace used by Judson, an advocate of pure mechanics in the treatment of club-foot, will serve to illustrate the type of apparatus which, with slight change, may be employed to correct or to support the weakened or deformed foot.

The brace consists of an upright, a flat, tapering bar of mild

steel, a foot plate of steel from 18 to 16 gauge, and a strong calf band. The shape of the brace, the method of its attachment to the leg by straps of webbing, and its effect in gradually changing the attitude of the foot from varus to valgus are shown in the accompanying figures.

The upright is firmly riveted to the foot plate in the angle of deformity, so that the patient must walk upon his toes; as the equinus is decreased by the influence of the weight of the body this angle is lessened (Fig. 480).

Fig. 478. Fig. 479.

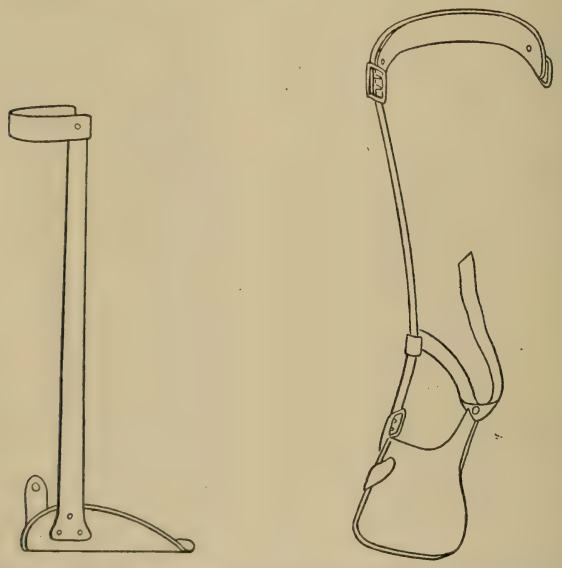

The Judson brace. Fig. 478 shows the construction of the brace; the foot plate, with the internal flange or "riser," the upright riveted to it, and the calf band. Fig. 479 shows the brace adjusted to fit the deformed foot.

The important points are that the brace shall be strong enough to hold its place under the strain of use and that the foot shall be firmly secured to it, whether one or many straps of webbing are required, as may be seen in the figures. The use of massage and manipulation is, of course, combined with the mechanical treatment.

By persistent attention to the details of treatment satisfactory results can be obtained by this method in the less resistant cases, even in adolescence.

Recapitulation of the Principles of Treatment of Congenital Talipes Equinovarus. The object of treatment is to over-

come and to overcorrect the deformity at as early a period of life as is possible, and as quickly as possible. The object of overcorrection is to overcome all the resistance of the tissues that may even in the slightest degree limit the normal range of motion in any direction. The foot must be fixed in the overcorrected position until the recoil of the tissues toward deformity is no longer present.

It must be supported in the proper relation to the leg, and at a right angle with it, until the muscular balance has been

FIG. 480. FIG. 481. FIG. 482.

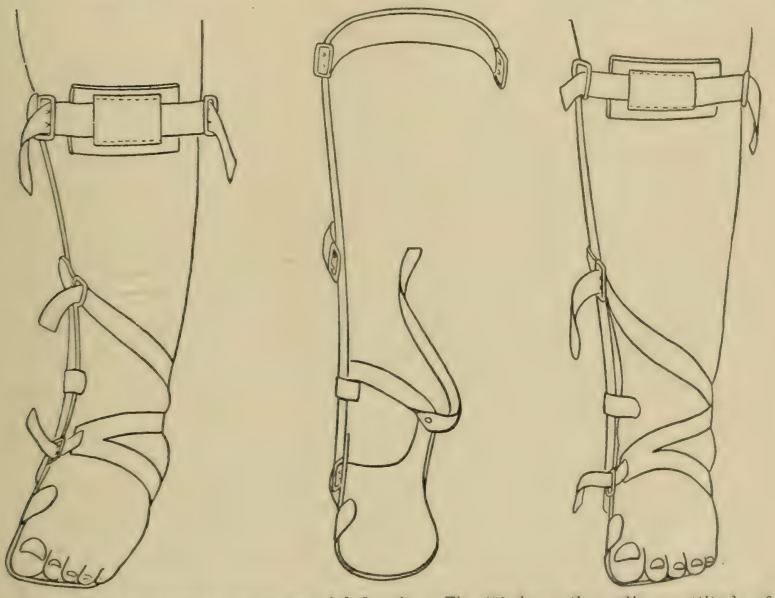

Showing the progressive reduction of deformity. Fig. 480 shows the ordinary attitude of the neglected club-foot in childhood with the adjustment of the brace, it being bent to accommodate the deformity. Fig. 481 shows additional details—an upright spur, useful in holding the heel and for the attachment of straps; the spur of sheet brass that may be bent over the great toe to hold it in position. Fig. 482 shows other details in the method of attachment, a strip of adhesive plaster, with two tails in the place of the band of webbing. This aids in fixing the heel. (See Figs. 483 and 484.)

re-established by stimulation of the weaker and by limitation of the activity of the stronger muscles, and until transformation of the internal structure has been completed.

If efficient mechanical treatment is applied at the proper time —that is to say, in earliest infancy—no operation other than division of the tendo Achillis will be required.

If the deformity is not corrected or is but partially corrected when the child begins to walk, some form of operation is, as a

rule, indicated; but division of the resistant tissues must always be combined with the employment of sufficient force to accomplish the desired result, viz., overcorrection of the deformity. Forcible manual correction, applied in the manner described, is the most efficient means of attaining this object. No instrument can equal the hand, and the force that can be applied by the hand is sufficient in all the ordinary cases in early childhood, and, in combination with subcutaneous division of the more resistant tendons and ligaments, even in later childhood and adolescence.

FIG. 483. FIG. 484.

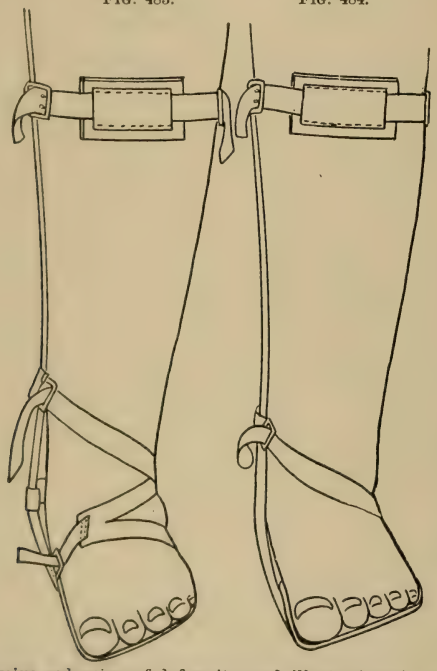

Showing the progressive reduction of deformity, and illustrating the process of changing the shape of the brace from time to time until it holds the foot in valgus. (See Fig. 480.)

Forcible correction by the Thomas wrench under the same conditions is an efficient treatment, but there is a manifest disadvantage in submitting a patient to a succession of operations, even of so slight a character, if immediate overcorrection can be attained by other means.

The Phelps operation, which combines thorough division of the resistant parts with the application of proper force to overcorrect the foot, is the operation of selection for the more resistant cases in adolescence, in adult life, and in extremely resistant cases in childhood.

Astragalectomy and cuneiform osteotomy are never indicated as primary operations, but one or the other may be necessary for the complete rectification of the deformity when other means have failed.

Complete cure of deformity, even in the later years of childhood, is possible by means of braces alone, but such treatment is very tedious. It requires not only the continuous supervision of the skilled surgeon, but the intelligent and persistent co-operation of the parents. The results are in no way superior to those attained by more rapid methods, while the disadvantages of long-continued use of braces are sufficiently obvious. To the popular faith in braces as a cure-all of deformity, and to the unintelligent use of braces, may be ascribed now, as in former times, the failures in treatment of this eminently curable deformity. This statement seems justified even when balanced by the equally fallacious belief, so prevalent among physicians, that a radical operation, if it does not absolutely assure a cure, is, at least, the essential part of the treatment.

Rectification of deformity, by whatever means, simply completes the first stage of treatment. Perfect cure can only be assured by attention to the small details of after-treatment, by checking the slightest impulse toward deformity, and by guiding the unbalanced foot toward perfect functional use.

Other Varieties of Congenital Talipes.

Forms of congenital distortion of the foot other than equinovarus are not uncommon; but, as a rule, these deformities are so slight and, as compared to equinovarus, so easily remedied that they are relatively of little importance. This distinction does not apply, however, to acquired talipes, which will be considered in the succeeding chapter.

Congenital Talipes Varus. Eighty-five cases of simple varus are recorded in the table of statistics in a total of 1660 congenital deformities of the foot.

This deformity often appears to be an incomplete form of equinovarus, but in some instances there is simply a slight inward twist of the foot without supination (Fig. 425); in fact, the forefoot is apparently drawn inward by the active movement of the great toe, which, in such cases, seems almost prehensile. (See Pigeon-toe.) In the more marked form the foot is adducted and supinated, and the tissues are very resistant.

The slight grades of deformity may be treated by simple manipulation, and if deformity remains after the first year the shoe will, as a rule, correct it. The more marked varieties must be treated like the varus deformity of ordinary club-foot, by braces or by plaster, until the varus has been transformed into valgus. The after-treatment is the same as that for ordinary club-foot.

Congenital Talipes Equinus. This is a rare congenital deformity, about half as common, according to the statistics, as varus (40 cases in 1660). The term equinus implies that dorsal flexion is limited, but that the foot is not deviated to one or the other side (toward valgus or varus). In congenital equinus the deformity is, as a rule, slight, and in many instances it may be overcome by gentle manual force applied frequently. In the more resistant type mechanical correction or tenotomy, followed by overcorrection and support, may be necessary.

Congenital Talipes Calcaneus. Congenital calcaneus is comparatively rare (28 cases in 1660). As a rule, the heel is prominent, the foot is habitually dorsiflexed, and the dorsum can be easily brought into contact with the crest of the tibia (Fig. 439). The exaggerated cavus that is usually present in acquired calcaneus is absent. Occasionally the deformity is accompanied by hyperextension of the knee ; and if, as in many instances, there is a history of breech presentation, it may be inferred that the attitude before birth was one of extreme flexion of the thighs upon the abdomen, the anterior surfaces of the extended legs being pressed closely to the ventral surface of the body, the feet being fixed in an attitude of dorsiflexion. As a rule, the deformity is slight, and the resistance of the tissues on the anterior aspect of the leg can be easily overcome by massage and manipulation. The foot should be gently forced toward plantar flexion several times in the day, and the weak muscles of the calf should be stimulated by massage.

Cure may be hastened by the use of some simple form of retention splint to hold the foot in plantar flexion until the posterior group of muscles has recovered its power. Tenotomy or other operative treatment is rarely required.

In rare instances the tibia may be bent slightly backward, thus increasing the deformity. In such cases the distortion of the bone may be overcome by manipulation and by apparatus.

Congenital Talipes Valgus. Congenital valgus (Fig. 440) is somewhat more common than the preceding varieties (123 in

1660). Not infrequently it is combined with a slight degree of calcaneus or equinus. The resistance of the contracted tissues is not great, and the deformity may be overcome, in most cases, by persistent manipulation. If the muscular power is sufficiently unbalanced to warrant it the foot should be fixed in the over-corrected position (varus) for a time.

Congenital valgus is one form of what is known as weak ankle, and it frequently passes unnoticed until the child begins to walk. If at that time, in spite of massage, the muscles appear weak or if the foot inclines outward when weight is borne, it is

FIG. 485.

Congenital calcaneovalgus.

well to make the sole of the shoe wedge-shaped, the thicker part (one-quarter of an inch) on the inner side. In more persistent cases a brace may be necessary, as described in the treatment of the acquired variety. (See Weak Foot.)

Talipes equinovalgus is less common (28 in 1660). This must be treated as the other varieties, by complete overcorrection of deformity, manual or otherwise, and by subsequent massage and support if necessary.

Calcaneovalgus (15 in 1660), **calcaneovarus** (7 in 1660), **equinocavus** (1 in 1660), **valgocavus** (1 in 1660), **cavus** (5 in 1660), are extremely rare, as indicated by the statistics. If

treated early by persistent massage supplemented by retention apparatus, these, as well as nearly all slighter grades of congenital deformity, may be corrected and cured even, before the child begins to walk.

Congenital Deformities of the Foot Associated with Defective Development.

Talipes Equinovalgus Associated with Congenital Absence of the Fibula. This is a rare deformity, but the most common of this class. The foot at birth is usually in an attitude of well-marked

FIG. 486.

Congenital equinovarus, with deformity of the great toes.

and resistant equinovalgus. The leg is somewhat shorter than its fellow, and the tibia is often bent sharply forward, sometimes to an acute angle, at a point somewhat below the centre, as if it had been broken *in utero*. At the most prominent point the skin may be adherent or it may present a dimpled appearance. In some instances the formation of the foot is perfect, but more often one or more of the outer toes, with the corresponding metatarsal bones, are absent (Fig. 487).

Statistics. Haudek collected from the literature 97 cases. Of these 46 were in males, 21 were in females, and in 30 the sex was not recorded. In 67 (69 per cent.) there was total absence of the fibula. In 30 the defect was partial; of the lower extremity of the fibula in 17, of the upper extremity in 9, and of the middle in 2 cases. In 27 cases both fibulæ were absent or defective; in 68 one only — the right in 31, the left in 25, and in the others the side was not recorded. In 61 cases toes were lacking, and in these cases it may be inferred that the corresponding metatarsal bones were absent also. The fourth and fifth toes were absent in 27 cases; the little toe alone was missing in 15. In many instances, as is usual in cases of defective development, deformity of other parts was present; for example, in 17 instances the patella was absent or undeveloped, and in 11 the upper extremities were defective.[1]

FIG. 487.

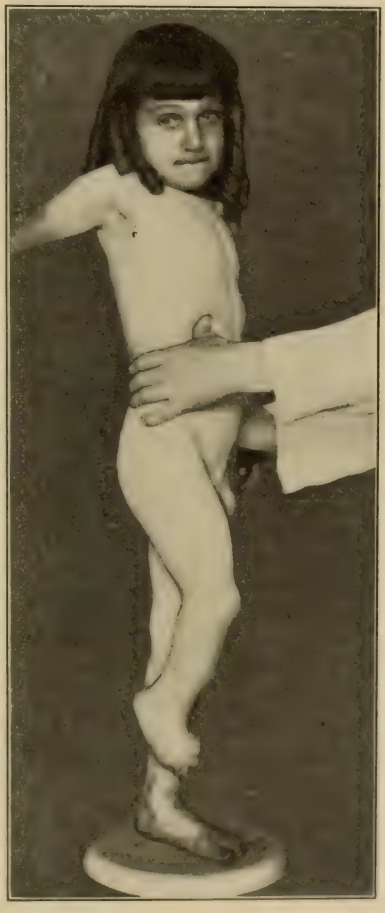

Defective formation of the lower limb, illustrating progress in shortening.

Etiology. The cause of deformity, associated with absence of bone, may be either an original defect in the germ or it may be due to interference with its development. In some instances amniotic adhesions may be one of the predisposing causes: the sharp bend in the tibia, so often present, may be due to the lessened resistance of the defective part.

[1] Cotten and Chute. Boston Medical and Surgical Journal, 1898, Nos. 8 and 9 (128 cases). Mazzitelli, Arch. Ortopedia, 1898, F. 5. Boinet, Revue d'Orthopédie, November, 1899. Vide also Emil Hain (113 cases), Archiv Orthop. Mechanicotherapie und Unfal Chir., Bd. i. H. 1, 1903.

Treatment. The indications for treatment are to correct the deformity of the foot in the usual manner. The bend in the tibia may be straightened by manipulation and splinting, or by osteotomy if necessary. When the patient begins to walk the foot must be supported. A light steel upright on the outer side of the leg, provided with a T-strap to hold the leg against it, will supply the place of the missing fibula. The growth of the tibia is retarded and a final shortening of three or more inches may be expected, but with care a useful limb may be assured.

Talipes Varus or Equinovarus Associated with Congenital Absence of the Tibia. Defective formation of the tibia is much less common than that of the fibula. Joachimsthal[1] records 31 cases. Of the 25 cases in which the sex was recorded 17 were males and 8 females. In 23 instances the defect was of one side; in 8 both tibiæ were defective. In most cases the femur is somewhat shortened and its lower extremity is imperfectly developed. In a third of the cases the patella was absent, and in many instances other malformations were present. In nearly all the cases there was flexion contraction at the knee and the fibula was dislocated backward. The foot is practically always in an attitude of varus. The toes may be normal, but in a number of instances the great toe was lacking. In possibly a third of the cases a portion of the tibia, usually the upper extremity, was present.[2]

The prognosis as regards a useful limb is extremely bad. The growth of both the thigh and the leg is much retarded, and it is almost impossible to balance the foot upon the fibula by any form of brace.

The ordinary treatment, after the correction of the deformity of the foot, has been to resect the extremities of the femur and the fibula to induce anchylosis. No final results have been reported, but it may be assumed that an artificial limb would provide a more useful support than the short and distorted extremity.

Congenital Deficiency and Hypertrophy. The leg bones may be perfectly formed, but one or more bones of the foot itself may be absent. In these cases, after the reduction of the deformity, a support to hold the defective foot in its proper relation to the leg must be used.

The foot may be divided into two parts, so that it resembles a lobster claw. Supernumerary toes, or deficiency of toes, or hyper-

[1] Zeits. f. Orth. Chir., vol. iii, p. 140.

[2] Lanois and Kuss report 40 cases. Revue d'Orthopédie, November, 1901.

trophy of one or more of the toes, with or without corresponding overgrowth of the foot or leg, are not extremely uncommon.

These deformities must be treated on ordinary surgical principles.

Constricting Bands.

Tightly constricting bands of scar-like tissue, which cause deep indentations in the flesh of the foot or leg, are sometimes seen. These are supposed to be caused by amniotic adhesions. "Spontaneous amputations" of toes or of the foot itself are due to the same cause (Fig. 443).

In ordinary cases the bands require no treatment, but if they interfere with the nutrition of the foot they may be removed.

Congenital Œdema of the Feet.

In rare instances, sometimes in combination with deformity, the tissues of the feet appear to be œdematous, although the circulation seems to be perfect. The condition is apparently due to obstruction of the lymphatic circulation.

It should be treated by massage and by compression.

Spinal Bifida and Talipes.

Talipes coexisting with spina bifida should be treated as are other forms of club-foot. If paralysis of the lower extremities be present, as is often the case, the corrected feet must be supported as in the ordinary forms of paralytic deformity.[1]

[1] Ueber missbildungen der Menschilichen Gliedmassen und ihre entstehungsweise, Klausner, 1900.

CHAPTER XXIII.

DEFORMITIES OF THE FOOT (Continued).

Acquired Talipes.

In the account of the congenital deformities of the foot it was stated that the form known as equinovarus was by far the most common, and that as compared with it the other deformities were of slight importance.

In the acquired varieties of talipes the equinovarus deformity is much less common, the proportion in the congenital form being 77 per cent. and in the acquired 32.5 per cent. of the total number. Acquired equinus comes next in frequency, 26 per cent. as compared with 2.4 per cent. of the congenital deformity; and every variety and combination of distortion finds its representative in acquired talipes, as may be seen in the tables. (See page 742.)

Etiology. The cause of acquired talipes is almost always paralysis. In the table of statistics it will be seen that in 82.8 per cent. the paralysis was of spinal origin (anterior poliomyelitis). In 11.3 per cent. it was cerebral, the talipes being a part of the deformity of hemiplegia or paraplegia. In a few cases the deformity was caused by local disease or by local paralysis, and the remainder, or 5.4 per cent., were of traumatic origin.

The distinction between the two varieties of talipes, congenital and acquired, has already been emphasized. In the congenital form the deformity is the essential disability, for when deformity has been rectified the most difficult part of the treatment has been accomplished and perfect cure may be expected. In the acquired form the straightening of the foot is but a preliminary part of the treatment, for cure is not to be expected except in that small proportion of cases in which the primary disease of the spinal cord has caused no permanent injury to its structure, or in which the deformity was the result of some slight or passing disability or of disease or injury. Congenital talipes cannot be anticipated or prevented. Acquired talipes is an effect of paralysis only when protective treatment has been neglected. It is a

result, therefore, that may be foreseen, and thus, by proper treatment, prevented.

Development of Deformity. The characteristics of anterior poliomyelitis are described elsewhere. (Chapter XVII.) In its effect upon the foot the usual sequence is somewhat as follows: At the onset the paralysis is usually widespread, affecting an entire limb, for example; then follows a period of partial recovery, after which the amount of damage that the spinal cord has sustained may be estimated. It is during the period of partial recovery, the six months or more following the attack, that deformity develops. If, for example, the anterior group of leg muscles is paralyzed, the foot habitually hangs downward, an attitude induced by the force of gravity and by the contraction of the unaffected posterior group. If it is allowed to persist the tissues accommodate themselves to the new position; the active muscles which are never extended to their normal limit become structurally shortened, while the weakened or paralyzed muscles are correspondingly overstretched. Even within a few weeks after the onset of the paralysis the evidences of progressive deformity are plain. The contracted tissues resist passive motion in the directions opposed to the habitual attitude, and the child shows evidence of pain if force is used to increase the limited range of motion. As has been stated already, acquired talipes is an unnecessary deformity. It may be prevented by supporting the paralyzed part in a right-angled relation to the limb, and by systematic passive movements throughout the entire range of normal motions.

Anterior poliomyelitis is most common during the second year of life, or when the child has already begun to walk. When the first or more general effect of the disease has passed away the child again uses the disabled limb as best it may; thus the distortion of the foot is increased and confirmed by the weight of the body and by functional use in the abnormal attitude.

The final deformity, in a particular case, can be predicted from a knowledge of the function of the muscles which have been disabled. For example, paralysis of the tibialis anticus, the most powerful dorsiflexor and adductor of the anterior group, must result in equinovalgus. If the peroneus brevis and tertius are affected varus will follow. Paralysis of the calf muscles will cause calcaneus. Paresis or paralysis of the entire anterior group will cause equinus. If all the muscles are paralyzed, what is called a dangle-foot is the result; the cold, atrophied member

dangles from the attenuated limb, with but little tendency to deformity unless it is capable of use, when it is usually forced into an attitude of equinovarus or valgus.

A slight degree of paralysis may cause so little immediate disability that it may be entirely overlooked, and yet it may be sufficient to induce disability or deformity even, in later years. This fact has been mentioned in the etiology of the contracted foot.

Differential Diagnosis between Congenital and Acquired Deformity. The history itself usually indicates the etiology, for deformity of the foot at birth is never overlooked by the mother. Acquired talipes is of slow development, and it is practically always preceded by disease, weakness, or injury.

In paralytic talipes (anterior poliomyelitis) there is evidence of paralysis in loss of function of certain muscles, as shown by electrical stimulation or by pricking the foot with a pin; later, in the atrophy of the muscles and often in the evident change in the nutrition and diminished growth of the limb.

Only in neglected and extreme cases of talipes in the adolescent or adult could there be difficulty in distinguishing between the acquired and the congenital deformity. In rare instances, it is true, paralysis may be present at birth, due to intra-uterine disease or to defect in the nervous apparatus. In such cases the cause of the paralysis is usually apparent (spina bifida, or spastic paralysis associated with defective cerebral development), and the treatment does not differ from that of the acquired form.

Acquired Talipes Equinus

In well-marked equinus the foot is plantar flexed to its full limit, and it is fixed in this attitude by the shortened structures on the posterior aspect of the leg, of which the tendo Achillis is the most important. The patient walks upon the heads of the metatarsal bones, the toes being dorsiflexed to accommodate the deformity. The arch of the foot is increased in depth and the tissues of the sole, particularly the plantar fascia, are contracted. The entire foot is broadened and shortened, the breadth being especially increased at the anterior metatarsal region (Fig. 438). Corresponding to the exaggerated depth of the arch, the dorsum projects, the cuneiform bones are prominent, and the head and body of the displaced astragalus may be felt beneath the skin on the anterior surface of the foot. In the slighter degrees of the deformity, when the patient still walks upon the sole of the foot,

the toes are usually dorsiflexed—an attitude due apparently to the overaction of the extensor longus digitorum and proprius hallucis, as aids in dorsiflexion (Fig. 488).

In rare instances, and only in those cases in which all the anterior muscles are paralyzed, the toes may be plantar flexed so that the patient walks upon their dorsal surface.

The cavus or increased depth of the arch is due primarily to the falling downward of the forefoot at the mediotarsal joint, and in many instances this dropping of the forefoot is in great degree responsible for the equinus; in fact, the os calcis is rarely plantar flexed to the degree commonly found in the ordinary congenital equinus.

FIG. 488.

Acquired talipes equinus, showing the limit of dorsal flexion.

The cases of slight equinus combined with cavus have been described already under the title of the contracted foot (page 699). The exaggerated arch is a secondary and a late result of the paralysis and of the equinus. In the slight degrees of deformity, particularly in the early stage of the paralysis, it may be absent.

Etiology. Equinus in the slighter degrees is the most common of the forms of talipes acquired in later life. Anterior poliomyelitis, although by far the most common cause, is by no means as important in the etiology of this as of other varieties of deformity. The nerve supply of the anterior muscles of the foot seems to be particularly susceptible, and toe-drop, from neuritis of various types, is not uncommon.

Equinus may be a result of disease of cerebral origin, or even, in rare instances, of pseudohypertrophic muscular paralysis or locomotor ataxia. It is sometimes induced by habitual posture, as after long confinement in bed for the treatment of fracture or during the treatment of hip disease by apparatus. Or the contraction may be an effect of voluntary posture, as when the patient habitually walks upon the toes because of a short leg. It is a very common sequel of neglected disease at the ankle-joint, and it may be a result of direct injury.

The changes in the internal structure of the foot are similar to those that follow other forms of deformity; the tissues on the long side are lengthened and attenuated, while those on the short side become contracted. The bones themselves are but little changed in gross appearance, but the articulating surfaces are in abnormal relation to one another; for example, only the posterior part of the astragalus may be contained within the malleoli in relation to the tibia, while only the lower part of its anterior surface articulates with the navicular. In all cases of equinus there is a strong tendency toward varus or valgus. This is especially noticeable in those of paralytic origin.

Symptoms. The effects of the deformity vary. If the limb is actually shorter than its fellow, so that the lengthening caused by the extension of the foot is no more than a sufficient compensation, and if the foot is firmly fixed in the deformed position, surprisingly little discomfort or disability may be experienced other than from corns or calluses beneath the metatarsal bones.

If the limb is not shorter the additional length caused by the equinus must be compensated by a tilting of the pelvis and lateral deviation of the spine. This often gives rise to symptoms of discomfort in the lumbar region. The gait in this class of cases is always awkward, giving the impression as of stepping over an obstacle.

If the foot is not fixed in the attitude of equinus—that is, if it hangs downward when it is lifted—the gait is very awkward, because of the insecurity and because of the exaggerated flexion at the knee necessary in order that the pendent foot may not drag upon the ground.

If the equinus is extreme the limb is usually flexed at the knee when in use; if the equinus is slight, so that the foot may be used in the plantigrade position, the strain resulting from the limitation of dorsal flexion is felt at the knee; and in childhood at least there is often a well-marked tendency to overextension

or recurvation, caused by the effort to place the heel upon the ground.

In the slight degrees of equinus discomfort about the calf is experienced; the limitation of dorsal flexion causes a rather shortened stride and awkward gait, while an unguarded step that throws a sudden strain upon the rigid heel cord is felt as a shock and strain through the leg and body. Very often the patient complains of pain about the metatarsal bones (anterior metatarsalgia), and if the equinus is accompanied by a slight degree of valgus, as is not uncommon, symptoms of the weak foot may be present.

The prognosis as to permanent cure depends, of course, upon the cause of the deformity. When it is simply the result of posture or of the ordinary form of neuritis and the like, permanent cure may be expected. In many of the cases that have followed anterior poliomyelitis recovery, complete or partial, of the original injury to the spinal centres, has occurred. Although voluntary control of the muscles has been regained, it cannot be exercised because the foot is held in the distorted position by the contracted tissues. In such instances practical cure may be predicted if, after the overcorrection of deformity, sufficient time is allowed for the overstretched and atrophied muscles to regain their proper length and volume.

Treatment. In the cases of fixed equinus combined with a shortened limb in which the patient suffers no discomfort it is well to allow the position to remain, a shoe being so built that the heel may support a part of the weight. In the more extreme cases in which the limb is short and the foot is atrophied an extension shoe, attached after the manner of an artificial leg, may be worn with comfort and with but little evidence of deformity.

In the ordinary cases, whether permanent cure is expected or not, the rule holds good that the heel should bear the weight of the body, and that the range of dorsal flexion should not be limited when the calf muscle retains its power. If the nervous apparatus has received permanent injury the foot must be supported after the deformity has been corrected; but even in this class the gait may be improved and the discomfort may be relieved by removing the restrictions to normal motion.

The slight degrees of equinus in young subjects may be overcome by simple manipulation or by retention in a splint or in a plaster bandage. If the foot is fixed by a plaster bandage at a right angle to the leg it will be found after a few weeks that the

range of dorsal flexion has been increased by the rest and by functional use. In older subjects manual stretching of the contracted tissues is of service; for example, the patient being seated extends the limb; the surgeon stands in front of him, one hand holds the leg firmly at the ankle, and the other grasps the foot, which is then dorsiflexed over and over again with as much force as is consistent with the comfort of the patient.

The Shaffer extension shoe is also a useful appliance for treatment of the milder degrees of equinus, and especially so because

FIG. 489.

A brace with a "limited" joint, allowing slight motion at the ankle.

FIG. 490.



A brace to prevent foot-drop. One upright is often sufficient.

it may be employed to reduce the accompanying cavus at the same time.

The weight of the body as a means of overcoming equinus when the foot is held in its proper relation to the leg by a brace or by a plaster bandage has been mentioned, but this tedious method has but little to recommend it in the cases of more resistant type. The elastic tension of straps and bands attached to a brace or to the foot itself by means of adhesive plaster is of some service in slight cases; but by far the most effective

method is the immediate reduction of the deformity by simple forcible manipulation under anæsthesia, or by tenotomy combined with forcible manipulation or wrenching.

Immediate Correction of Deformity. Attention has been called to the cavus as an important element in equinus, and whenever one attempts to correct the equinus deformity by force the exaggerated arch should be reduced to its normal depth, otherwise the foot will appear stunted and deformed.

One of the most effective procedures is forcible reduction by means of the Thomas wrench (Fig. 472). The resistant bands of the plantar fascia are first divided subcutaneously, the wrench is then fixed to the foot, and with sudden force exerted against the resistant tendo Achillis the foot may be straightened, the deep ligaments being ruptured or stretched to the proper degree. The resistance to normal dorsal flexion is then overcome by manual force, or, if this is ineffective, by subcutaneous division of the tendo Achillis, and the foot is fixed by a plaster-of-Paris bandage in an attitude of dorsiflexion.

As the patient is encouraged to walk upon the foot as soon as possible, the weight of the body forcing the relaxed tissues against the plaster sole, reinforced, if necessary, by a wooden foot plate, completes the flattening of the arch. In many of these cases the knee has been overextended by use in the deformed attitude, so that the habitual flexion necessary to bring the dorsiflexed foot upon the ground during the two months allowed for the complete union of the divided tendon is of benefit, as it serves to correct this secondary weakness and deformity.

The Tonic Effect of Immediate Correction. The importance of the tonic effect of immediate relief of the strain of the deformed position upon the weak anterior group of muscles, together with the complete relaxation of the overstretched tissues, during the long rest in the overcorrected position is not generally appreciated. Whenever the weakened muscles after paralysis show by tests, electrical or otherwise, that they have recovered their power in part, overcorrection of the deformity should be the treatment of selection. The application of electricity or other form of stimulation to muscles that are unable to exercise their function because of contraction of the opposing tissues is absolutely useless; nor is any other form of artificial stimulation equal to that of the functional use, which is made possible by the removal of the deformity and by the employment of proper support.

Equinus, more often than any other deformity, is the result of

slight or temporary disability of the anterior group of muscles, and not infrequently perfect cure seems to have been attained when the plaster bandage is finally removed, usually at the end of two months or more; but even in such cases the application of a simple support to hold the foot at a right angle with the leg for several months is of advantage. The after-treatment by massage, muscle-beating, electricity, and the like, combined with methodical passive movements to the limit of dorsal flexion to guard

FIG. 491.

An effective and inconspicuous support for paralytic toe-drop. An upright of light tempered steel, carefully adjusted to the inner side of the leg and ankle, provided with a light calf band. This is strengthened by a posterior support attached to the upright. The lower end of the brace is arranged as a caliper and is fitted to the metal disk, of which two views are shown. A depression is cut in the heel of the shoe for the disk, as is shown in the diagram. Two strong elastic tapes are sewed to the leather of the shoe. These are attached to the studs on the front of the calf band, and thus the toe-drop is prevented. (See Fig. 492.)

against recontraction of the calf muscle, should be continued for a long time or until the muscular balance has been regained.

Support is, of course, necessary, in cases of hopeless paralysis, to hold the foot at a right angle with the leg. The common form is a simple steel sole plate of sufficient size to support the sole, and the toes, also, if their muscles are paralyzed, attached to a light upright, provided with a calf band. The upright is usually applied on the inner side of the leg, where it is least

noticeable. At the ankle there is a "stop joint," which allows dorsiflexion but prevents the toe-drop. This, when properly fitted, can be placed inside the ordinary shoe, as the paralyzed foot is usually somewhat smaller than its fellow (Fig. 490). If the toes do not need support, the upright can be attached to the outside of the shoe and the foot plate may be dispensed with; or, the upright may be concealed by introducing it inside the shoe to a joint sunk in the heel, the toe-drop being prevented by straps passing from the front of the upper leather of the shoe to the calf band (Fig. 491).

FIG. 492.

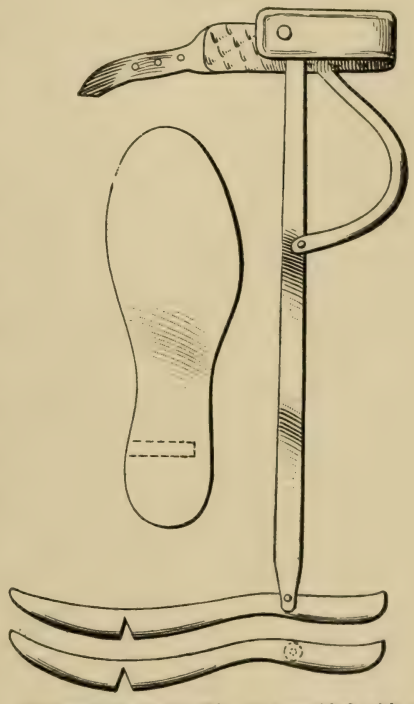

The same appliance (Fig. 491) provided with a foot plate of metal or of wood, as shown in the diagram. This modification is useful if the paralysis is complete or if the foot is much atrophied.

Arthrodesis. In this class of cases in which the anterior muscles are paralyzed the operation of arthrodesis for the purpose of fixing the foot at a right angle with the leg is of value. In most cases anchylosis must be secured at the mediotarsal as well as at the ankle-joint. Under the Esmarch bandage the two joints are opened by an incision in the centre of the foot, beginning about one inch above the ankle-joint and extending downward for about three inches. The cartilaginous surfaces of the astragalus and leg bones may be removed easily with a narrow-bladed knife or thin, sharp chisel, while the foot is held in plantar flexion. At the mediotarsal joint a thin, wedge-shaped section, base upward, including the astragalonavicular and calcaneocuboid joints, may be removed also in order to prevent the subsequent sinking of the forefoot.

If there is restriction of dorsal flexion the foot should be forced up to a right angle with the leg against the resistance of the tendo Achillis, thus determining the apposition of the denuded surfaces. In other instances silk sutures may be passed through the perios-

teum of the opposing bones. The wound is then closed with catgut and a plaster-of-Paris bandage is applied to hold the foot at a right angle with the leg. Operations of this character on the bones are sometimes followed by swelling. On this account the bandage should be applied tightly over a thick layer of elastic cotton and the foot should be elevated. As soon as the discomfort has subsided the patient should use the foot in walking. No support is equal in efficiency to the plaster bandage, and this should be worn for several months, when it may be replaced by a light supporting brace of the Judson type (Fig. 494).

Equinus due to posture or to disease, not involving paralysis, may be cured by simple correction of the deformity. That due to fracture, when the deformity is caused by displacement of the bones, may be treated by direct operation or by the removal of a cuneiform section from the anterior surface of the tibia above the ankle. (See Tendon Transplantation.)

Acquired Talipes Calcaneus.

Acquired talipes calcaneus is much less common than equinus, and it is practically always of paralytic origin (anterior poliomyelitis), although cases of calcaneus following injury or disease or distortion of the limb are occasionally seen.

There are several varieties or grades of the deformity. In the early stage, and especially if all the muscles of the posterior group have been paralyzed, the foot assumes an attitude of slight dorsiflexion, and the range of plantar flexion is gradually lessened by secondary contractions. This variety resembles closely the congenital form (simple calcaneus) (Fig. 439). In the ordinary and typical form of calcaneus, when fully developed, the patient walks, as the name implies, on an elongated heel. The arch of the foot is much increased in depth, and the forefoot is atrophied and useless (calcaneocavus) (Fig. 495).

Development of Deformity. The development of the deformity is somewhat as follows: When the tension of the calf muscle is removed the os calcis gradually assumes an attitude of extreme dorsiflexion. It stands on end, so that its posterior surface becomes inferior. The posterior projection of the heel is lost, and it lies in the plane of the atrophied calf. The change in the position of the os calcis increases the distance from the malleoli to the ground; thus calcaneus, though in less degree than equinus, makes the limb longer. The turning of the heel on end increases

the depth of the longitudinal arch and at the same time shortens the foot, thus cavus, in more marked degree than with equinus, accompanies calcaneus. The cavus is a later complication of nearly all cases of paralytic calcaneus. In many instances there is no permanent dorsiflexion or elevation of the forefoot, although in all cases the range of plantar flexion is limited. In this class the power in the remaining muscles of the posterior group is probably sufficient to counterbalance the action of the dorsiflexors. Cavus is thus a direct effect of the displacement of the os calcis. If the entire posterior group of muscles is paralyzed, while the anterior muscles are unaffected, the foot will be somewhat dorsiflexed and the cavus will be less marked. If the calf muscle only (gastrocnemius and soleus) is paralyzed, the remaining muscles of the posterior group will counterbalance the dorsiflexors and at the same time increase the cavus. In some instances the calf muscle alone is affected; in others one or more of the smaller muscles may be paralyzed also, in which case the foot is usually turned toward varus or valgus. The changes primarily caused by the paralysis and by unopposed muscular action become fixed by habitual use and by secondary adaptation of the tissues. The heel only is used in walking, and the area of callus which marks the weight-bearing surface becomes much enlarged, while the forefoot and toes, which have but little functional use, become atrophied—a mere appendage to the enlarged heel (Fig. 496).

Symptoms. The gait is awkward and inelastic; the patient, who is, as it were, "hamstrung," stamps along upon the insecure support of the heel in a manner which is easily recognizable by one familiar with the deformity. The changes in the internal structure of the foot, the inevitable adaptations to the deformity, do not call for special description. The disused bones atrophy together with the other tissues, and new articulating surfaces form to accommodate the necessities of functional use.

Treatment. The essence of successful treatment is prevention. When the diagnosis of paralysis of the calf muscle is made one may predict, unless recovery takes place, a deformity such as has been described. This deformity may be prevented by proper support, by massage, and methodical stretching of the tissues that have a tendency to contract. The form of brace used for walking and support should be provided with a sole plate, upright, and calf band, as already described in the treatment of paralytic equinus. If motion is allowed at the ankle it should be in plantar flexion only, the stop being the reverse of that used in equinus;

or, as this form of check entails much strain upon the brace, the joint may be omitted, as in that form used by Judson (Figs. 493 and 494). Thus the strain, removed from the weakened tissues, is borne by the anterior surface of the leg. Other forms of braces are sometimes employed, provided with elastic bands to supply the place of the calf muscle; but, as a rule, the improvement in gait hardly compensates for the trouble in adjustment or the conspicuousness of the appliance.

The most important part of the actual deformity of calcaneus is the cavus, in great degree due to the changed position of the os calcis; and in confirmed cases it is practically impossible to

FIG. 493. FIG. 494.

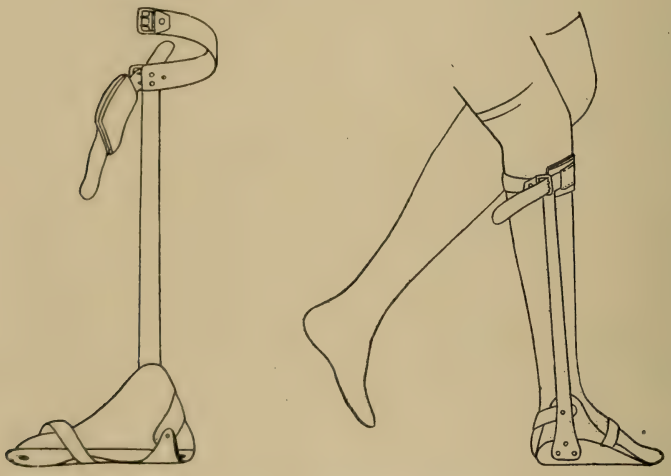

Judson's brace for calcaneous deformity.

reduce this except in part, because the loss of resistance of the tendo Achillis, takes away the point of fixation against which effective force can be exerted. If the deformity is not marked the foot may be drawn as far as possible toward equinus and fixed in a plaster bandage, the sole part being strengthened by the insertion of a thin board. Upon this the patient may walk, the heel being built up with cork wedges to make the sole level. When the contraction of the anterior tissues has been overcome the brace is applied and the usual treatment of manipulation and massage is continued.

The method of prolonged fixation in the attitude of equinus by means of the plaster bandage is often efficacious in childhood,

when the paralysis is not complete, and cures of apparently hopeless cases by this means have been reported.[1]

Operative Treatment. In more extreme cases immediate reduction of the deformity under anæsthesia may be attempted. The contracted tissues, more particularly the plantar fascia, may be divided subcutaneously or by open incision; then by forcible manipulation or wrenching the sole may be somewhat lengthened and the heel pushed upward and backward to permit of slight plantar flexion. In this attitude the foot should be fixed by

FIG. 495.

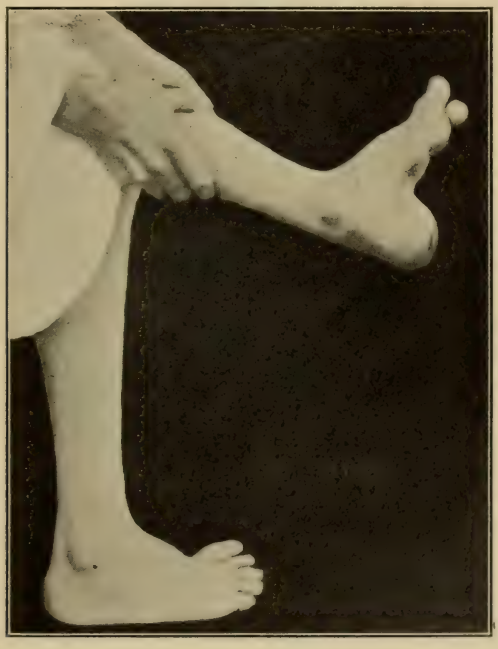

Paralytic calcaneus, showing secondary changes in contour.

means of a plaster bandage. In the reduction of the deformity one must not merely force the forefoot downward, as this would simply increase the cavus, but whatever correction is accomplished should be by means of elevation of the os calcis and elongation of the tissues of the sole of the foot. In cases of extreme deformity the contracted tissues in the anterior aspect of the ankle must be divided also.

In some instances the improved position of the os calcis may

[1] Gibney. Transactions of the American Orthopedic Association, 1900, vol. xiii.

be confirmed by shortening the tendo Achillis, as first performed by Willett, of London.[1]

Willett's Operation for Calcaneus. A Y-shaped incision about two inches in length is made through the tissues down to the tendon. At the lower or vertical part of the incision, which is continued down to the tuberosity of the os calcis, the tendon is dissected free from the surrounding parts. It is then divided in an oblique direction from within outward and downward, and the

FIG. 496.

Talipes calcaneus due to paralysis of the calf muscle (gastrocnemius and soleus), illustrating the typical deformity of moderate degree.

heel having been pushed upward as far as possible the divided ends are overlapped and sutured; the flap of skin is drawn downward at the same time, so that the Y-incision is converted into the shape of a V. According to Mr. Willett's original directions, deep sutures are passed through the skin flaps and through the tendon on either side, so that all the tissues are united. The foot is then fixed in a plaster bandage in an attitude of equinus. As soon as practicable the patient begins to use the foot, wearing a high heel to compensate for the elevation of the sole.

[1] St. Bartholomew's Hospital Reports, 1880, vol. xvi. p. 309.

The operation is of value in those cases in which some power remains in the calf muscle, which is thus made serviceable.

FIG. 497.

Talipes calcaneovalgus. In this form the adductors of the foot (tibialis anticus and posticus) as well as the calf muscle are paralyzed.

In cases of complete paralysis the position of the foot may be temporarily improved, but unless proper support is used afterward

FIG. 498.

Compare with Fig. 496.

FIG. 499.

Compare with Fig. 497.

the tissues will stretch under the strain of use; thus the treatment should always be supplemented by a brace of the character already described (Fig. 494).

Astragalectomy, Tendon Transplantation, and Backward Displacement of the Foot (the Author's Operation).[1] In cases of confirmed calcaneus or calcaneus combined with lateral deformity, varus or valgus, astragalectomy may be indicated. This operation permits the malleoli to be brought into direct contact with the os calcis, thus increasing the security of the foot and improving its appearance.

A long, curved, external incision is made, passing from just anterior to the tendo Achillis below the outer malleolus to the front of the joint. The peronei tendons are divided or drawn to one side. The joint is then opened and the foot is displaced inward.

This forces the astragalus out from between the malleoli and it is easily removed when its attachments to the neighboring

FIG. 500.

Figs. 498, 499, and 500 illustrate the effect of treatment by removal of the astragalus and backward displacement of the foot in cases of paralytic talipes calcaneovalgus.

bones have been divided. The articulating surfaces of the leg bones and of the os calcis and navicular are denuded of cartilage; and, finally, the peronei tendons, if the muscles are active, are attached to the os calcis, preferably by passing them through a hole bored just beneath the insertion of the tendo Achillis, for the purpose of lessening the tendency to deformity and increasing the subsequent stability of the foot. The entire foot is then displaced backward so that the denuded malleoli overlap the

[1] American Journal of the Medical Sciences, November, 1901.

anterior extremity of the os calcis. The object of this procedure is to throw the weight of the body toward the centre of the tarsus in order to lessen the leverage that tends to force the foot toward dorsal flexion. The wound is then closed without drainage, and the foot is fixed in plaster of Paris in moderate equinus.

As soon as possible the patient uses the foot in standing and walking. Ultimately apparatus may be dispensed with, but the Judson brace or the appliance shown in Fig. 501 may be used for a year or more with advantage. This operation has been performed in many instances by the author, for whom it is now

FIG. 501.

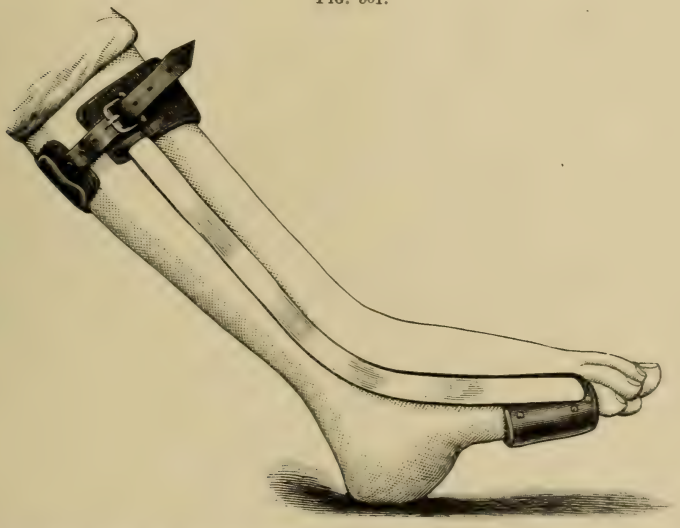

An effective brace for talipes calcaneus, consisting of two light lateral steel bars joined above by a padded band of steel, which crosses the upper third of the tibia, and below by a narrow sole plate. A leather heel support also adds somewhat to the efficiency of the apparatus. In most instances the heel should be somewhat elevated by a cork wedge placed within the shoe.

the treatment of choice in this type of deformity. It may be stated that absolute anchylosis does not follow the denudation of the bones, but this seems to be of service in lessening the direct strain upon the articulation. The tendon transplantation is rather for the purpose of removing an agent toward deformity if valgus is present and to lessen the tendency toward deformity than to replace the lost function of the calf muscle (Fig. 499). By this operation the usefulness of the foot is greatly increased and its appearance very much improved.

Acquired Calcaneovalgus and Calcaneovarus.

In many cases, the foot deformed as a result of paralysis of the calf muscle is in addition turned in a lateral direction, so that the weight of the body falls to the inner or outer side of its centre (Fig. 497).

Calcaneovalgus, in which the foot is turned outward and upward, so that the patient walks on the inner side of the heel or even on the inner ankle, is not uncommon. It is usually a result of more extensive paralysis than simple calcaneus. For example, all the muscles about the foot may be disabled except the peronei, or in cases of a milder type the tibialis anticus may be the only muscle of the front of the foot that is paralyzed.

Treatment. When the foot inclines toward calcaneovalgus it is difficult to hold it in proper position. The usual method is to apply the brace, used for ordinary calcaneus, with the upright on the outer side of the foot; the ankle and arch are then held against it by means of a leather strap. Another form of brace is provided with an upright on either side of the leg, the outer being slightly longer than the inner, so that the sole plate is tilted inward or, as it were, supinated; thus the weight is guided toward and balanced on the outer side of the foot. In many instances of this character other muscles of the limb are paralyzed, the deformity of the foot being but a part of more general distortion. In such cases the foot brace must be combined with apparatus for the support of the leg (Fig. 359).

Calcaneovarus is a much less serious affection, since the foot may be more easily supported. A brace, such as is used in the treatment of ordinary varus, without motion at the ankle or provided with a reverse stop, is ordinarily employed. Operative treatment is indicated for confirmed deformity of the valgus or varus type after the method last described.

Acquired Talipes Equinovarus.

Talipes equinovarus is, in the acquired as in the congenital form, the most common of the deformities of the foot (Fig. 505).

The tendency of simple equinus is usually toward varus, because in plantar flexion the foot is slightly adducted and because the outer side of the foot is shorter than the inner side, so that in

walking with the foot extended the tendency of the foot is to turn somewhat inward. Equinovarus is usually preceded by equinus, and the etiology of the one will serve for the other (page 796).

In certain cases the varus is more marked than the equinus, as, for example, when the abductors of the foot are paralyzed while the adductors retain their power; or in cases of direct injury, as in fracture at the ankle; or when the growth of the tibia has been arrested, as the result of injury or disease.

A detailed account of the appearance and effect of the deformity is unnecessary. In the early stage of the paralysis it may be reduced easily; the foot must then be supported by a brace, of which the Taylor club-foot apparatus is the type (Fig. 463). During the night the overcorrected attitude may be assured by a strap running from the upright to the sole plate.

If the deformity is fixed it should be reduced and overcorrected by forcible manipulation under anæsthesia. Division of resistant parts is less often necessary than in the congenital form, but it may be required in neglected cases. The overcorrected position should be retained until time has been allowed for the recontraction of the lengthened tissues; for, as has been mentioned in the treatment of equinus, overcorrection and rest is by far the most effective treatment that can be applied to a weak or paralyzed part. A support is then used of the character indicated.

Astragalectomy and cuneiform osteotomy are rarely indicated, but the latter operation is sometimes of service in checking the tendency toward recurrence of deformity, which is more persistent after overcorrection in the paralytic than in the congenital talipes.

Transplantation of half of the tendon of the tibialis anticus tendon to the periosteum or bone of the outer border of the foot, combined with arthrodesis of the astragalus scaphoid articulation in an attitude of slight abduction, is of service as a curative procedure. (See Tendon Transplantation.)

Acquired talipes equinovalgus is much less frequent than the preceding deformity. Simple equinovalgus is usually the result of primary paralysis of the tibialis anticus, the most powerful of the dorsal flexors; thus the foot is drawn somewhat outward when dorsiflexed, while the metatarsal bone of the great toe, having lost the proper support of the paralyzed muscle, falls downward and is drawn outward by the peroneus longus. In this type one's attention is often attracted by the peculiar appearance of the great toe, which is deformed somewhat like a hammer-toe

by the overaction of the extensor longus hallucis in its attempt to take the place of the tibialis anticus. The equinus is usually slight and is secondary to the valgus. Treatment may be begun by placing the foot in a plaster bandage in an attitude of varus and allowing the patient to walk upon it until the tendency toward deformity has been overcome. A support with the catch, as for toe-drop, is applied to the shoe, and the tendency toward valgus is checked by raising the inner border of the sole or by the use of a sole plate, as in the treatment of the simple weak foot (Fig. 413). In this class of cases tendon transplantation, particularly the implantation of the tendon of the extensor longus hallucis in the region of the navicular. Combined with arthrodesis of the astragalonavicular articulation in the attitude of adduction is particularly effective.

Acquired simple talipes valgus from combined paralysis of the tibialis anticus and posticus is rare. Talipes valgus, as when the foot is dislocated outward, in cases of complete paralysis of all its muscles, may be considered as a variety of dangle-foot.

Traumatic valgus and equinovalgus caused by fracture at the ankle (Pott's fracture) may be treated by osteotomy of the tibia above the ankle. By this means the proper relation of the leg to the foot may be restored in many instances. Equinovalgus of slight degree is not uncommon after tuberculosis or rheumatoid disease at the ankle or at the astragalonavicular joints. This is practically one variety of weak foot.

Talipes valgus, sometimes called spurious valgus, the simple weak or flat-foot, has been described elsewhere. (Chapter XX.)

Talipes caused by cerebral disease, whether of the paraplegic or the hemiplegic type, is in early childhood almost always of the form of equinovarus. In adolescence the deformity may be equinovalgus or even calcaneovalgus if there is extreme flexion at the knee. The hemiplegic form of talipes is much more rigid and unyielding than the paraplegic type. The treatment of spastic paralysis, of which the deformity is a part, is discussed elsewhere. (Chapter XVIII.) The deformity must be corrected by the ordinary methods. In many instances when the contractions are not marked mechanical treatment is unnecessary.

Hysterical equinovarus or other form of deformity is not especially rare. The diagnosis may be made from the other symptoms of hysteria, from the history of the onset and duration of the distortion, and from the appearance of the deformity, which is evidently merely an assumed posture. (See page 621.)

Tendon Transplantation for the Relief of Paralytic Talipes.

When one or more of the muscles are paralyzed the unbalanced action of those that remain tends to distort the foot. The object of the brace in such cases is to hold the foot so that the muscular traction, however applied, can move it only in the proper directions. The object of tendon or muscle transplantation is to utilize the muscular power that remains to the best advantage. Thus a muscle which only serves to distort the foot may be transplanted to a point where it may restrain deformity and improve functional ability.

Tendon transplantation was first performed by Nicoladoni in 1882[1] for the relief of paralytic calcaneus. The tendons of the peroneus longus and brevis were divided behind the external malleolus, and the proximal ends united to the distal extremity of the divided tendo Achillis.

The first operation on the front of the foot was performed by Parish,[2] of New York, for the relief of paralytic valgus, by sewing the tendon of the extensor proprius hallucis to that of the paralyzed tibialis anticus, without division of either tendon. In more recent years the field of the operation has been extended by Drobnik,[3] of Posen; Goldthwait,[4] of Boston, and many others, to include almost every possible combination of tendons and muscles.[5]

The functions of the muscles and their relative order of importance in the execution of each movement are indicated in the following table, modified somewhat from that of Codivilla:

	Dorsal flexion.	Plantar flexion.	Adduction.	Abduction.	Pronation.	Supination.
Tibialis anticus	1	...	...	...	...	1
Extensor proprius hallucis	3	...	...	...	...	6
" longus digitorum[6]	2	...	...	3	3	
Peroneus brevis	...	6	...	2	2	
" longus	...	3	...	1	1	
Gastrocnemius and soleus	...	1	2	...	...	2
Tibialis posticus	...	4	1	...	...	3
Flexor longus hallucis	...	2	3	...	...	4
" " digitorum	...	5	4	...	...	5

Time for Operation. The operation should not be undertaken until the degree of final and irremediable paralysis has been

[1] Archiv f. klin. Chir., 1882, iii., xxvii., S. 660.
[2] New York Medical Journal, October 8, 1892.
[3] Cent. f. Chir., July, 1894, N. 7.
[4] Transactions of the American Orthopedic Association, 1896, vol. viii.
[5] For a complete bibliography up to 1902, see Vulpius, Die Sehnenüberpflanzung, etc. Leipzig, 1902.
[6] Including peroneus tertius.

FIG. 502.

The muscles and tendons on the front of the leg. (Testut, from Gerrish's *Anatomy*.)

FIG. 503.

The muscles and tendons on the back of the leg. (Testut, from Gerrish's *Anatomy*.)

determined. This stationary stage may be reached in a comparatively short time, but in the ordinary cases in which, for want of protection, the part has become distorted, it is practically impossible to estimate the latent muscular power until the deformity has been corrected, and until the enfeebled muscles have been stimulated by functional use. In general, a period of two years at least should intervene between the onset of the paralysis and the operation.

The first essential for success by this means is a clear understanding of the mechanism of the disabled part and of the relative importance of its functions. As regards the foot, for example, plantar flexion is far more important than dorsal flexion, because the inability to plantar flex implies the loss of the principal lifting and propelling power of the body. Dorsal flexion is more important than adduction or abduction, because the drop-foot, so called, interferes seriously with locomotion. Adduction is more important than abduction, because the loss of power to turn the foot inward induces the attitude of valgus, which is more disabling and more difficult to remedy than the opposite deformity. To the importance of these movements the power of the muscles corresponds.[1]

FIG. 504.

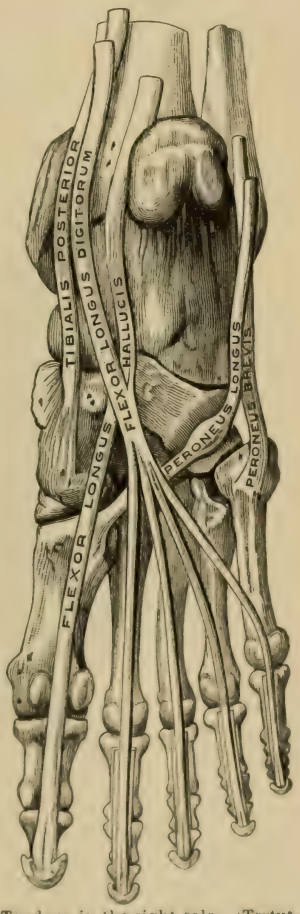

Tendons in the right sole. (Testut, from Gerrish's *Anatomy*.)

Selection of Muscles. In selecting muscles for transplantation one attempts usually to reduce the distorting power as well as to replace lost function. For example, if the tibialis anticus were paralyzed one would naturally replace it by its adjunct, the adjoining tendon of the extensor hallucis, and as the power of raising the toe is not essential it should be separated and transferred entire to its new position. This might complete the operation, or the principal abductor on the dorsal surface of the foot might

[1] See Tables on pages 659 and 660.

be divided and the proximal end attached to the periosteum or bone near the centre of the foot to further assure the success of the operation.

If, on the other hand, the dorsal abductors were reduced in strength so that the foot turned inward in dorsiflexion, the tibialis anticus tendon should be split, from its insertion to the muscular substance, and the outer half carried under the other tendons and fastened securely at or near the insertion of the peroneus tertius as well as to that tendon; thus, the power of supination would be weakened and that of pronation increased.

FIG. 505.

Paralytic equinovarus before operation. (See Fig. 506.)

If the calf muscle is paralyzed and if the foot is inclined toward valgus because of weakness of the adductor group, the two peronei tendon may be attached at the insertion of the tendo Achillis, not, of course, with the aim of replacing its lost function by two such feeble muscles, but because they might aid in preventing deformity and become of some functional service, even if slight.

Paralysis of the tibialis posticus muscle may be treated by dividing the peroneus brevis at or near its insertion, passing it

beneath the tendo Achillis and attaching it to the tendon of the former. It may be mentioned, also, that portions of the tendo Achillis have been used to strengthen either the posterior adductors and abductors. As has been stated, one must plan the operation according to the function that is lost and the power that remains. As a rule, the most successful operations are those in which a muscle of similar function to that of the paralyzed one is transplanted. It is apparent, also, that it will be of little use to transpose a muscle unless its origin is such that it can work to advantage at its new point of attachment.

FIG. 506.



Paralytic equinovarus cured by operation, showing power of dorsal flexion (one-half of the tendon of the tibialis anticus attached to the periosteum of the outer border of the foot). Operation July 19, 1898. The direct union of tendons to periosteum at the most advantageous point has been urged recently by Lange (*Ueber Periostale Sehnenverplanzung bei Lähgmung, Münch. med. Woch.*, 1900, No. 15).

For example, an anterior adductor may be changed to an abductor, and a posterior adductor or abductor can be similarly transferred, but a posterior abductor is unlikely to be efficient as a dorsal flexor; nor can one muscle act as an extensor and as a flexor at the same time, as would appear to be the belief of those who attach a portion of the tendo Achillis to the tibialis anticus tendon with the aim of restoring the power of dorsal flexion. The variety of combinations of this character that have been advocated is very large, but it is hardly necessary to describe them. As has been mentioned, one may always sacrifice a less

important to a more important function, and as a weak muscle can hardly carry out its original function and a more important one as well it is advisable in most instances to relieve it completely of the first in making the transfer.

The Operation. The technique of the operation is simple. All restriction to normal motion must be overcome by manual force and, if necessary, by tenotomy as a preliminary measure. The operation should be performed under an Esmarch bandage. The incision should be long enough, as a rule, to expose the

FIG. 507.

Talipes equinovalgus after treatment by tendon transplantation. The tendon of the peroneus tertius was attached to the overlapped and shortened tendon of the tibialis anticus. All the tendons on the front of the foot were then united, so that all might serve as dorsal flexors.

muscular substance of the muscles and the point at which the transplanted tendon is to be attached. By exposing the parts one is able to verify the previous diagnosis. A completely paralyzed muscle is atrophied and of a dull, reddish-yellow color, and its tendon is of a yellowish-white tinge. A partially paralyzed muscle is atrophied, its tendon is small, but it retains the silvery glisten of the normal structure. The tendon sheaths having been opened, the tendon is divided or split near its insertion, and the part to be transplanted is then placed in apposition to the tendon of the paralyzed muscle, whose surface has been freshened

with the knife. The two are then attached to one another by several sutures of fine silk, and the graft is covered by uniting the tendon sheath or fatty tissue over it with fine catgut. The skin incision is closed with a continuous catgut suture. It should be stated that the graft is applied under a certain tension, all the slack being drawn in, as it were, so that the foot is held if possible in the normal attitude. This is further assured in most instances by shortening the tendon of the paralyzed muscle. A plaster bandage is then applied in the overcorrected position, and in this attitude the foot should be used for many months.

Modifications of the Operation. Since its introduction the operation of tendon transplantation has been modified in several particulars. It has been demonstrated by experience that there is a strong tendency toward relapse to the original condition, either because of weakness of the transposed muscles or because of displacement of the new attachments. This indicates the necessity of long-continued fixation in the overcorrected attitude and of subsequent support by braces until one is certain of the final outcome.

It has been urged by Lange that the tendon of the living muscle should not be attached to that of the paralyzed one, but should be fixed directly to the periosteum at the point of greatest mechanical efficiency. If the tendon is not long enough for this purpose it should be lengthened by means of a silk cord incorporated in its substance, about which it is assumed new tendinous material will form during its absorption. Wolff has suggested implanting the end of the tendon beneath the cortex of the bone, and I have gone still further in the interest of security by boring a hole completely through the bone to which the attachment is to be made, passing the tendon through it and sewing it to itself and to the periosteum on the other side. Thus, in utilizing the extensor longus hallucis to replace the tibialis anticus the hole is made in the navicular. The tendon, having been divided about one inch from its insertion, is passed through and drawn tight enough to hold the inner border of the foot at a right angle to the leg. The tendon of the paralyzed tibialis anticus is then cut, overlapped, and sutured to aid in relieving the strain. If the tibialis anticus muscle, on the other hand, is to be used as an abductor it is split in the manner described, and as it is not long enough for bone implantation a cord of silk is quilted into it and passed through the cuboid, while the tendon itself is attached to that of the peroneus tertius and to the periosteum in the usual

manner. Silk may be depended upon to hold for about a year, although it is not completely absorbed for several years. For uniting adjacent tendons I prefer the continuous suture over a wide extent of surface.

Tendon Transplantation in Combination with Other Procedures. As the object of operative treatment is to prevent deformity and to increase the stability of the foot, tendon transplantation may be of greater service when combined with other operations. One of these has been mentioned in the treatment of talipes calcaneus. (See page 808.) For valgus deformity arthrodesis of the astragalonavicular articulation in the attitude of adduction, and for varus in the position of abduction, are useful adjuncts. The operation is very simple. The joint is opened by a lateral or superior incision and the cartilage is removed with a knife or sharp chisel. As a rule, when the foot is forced into the overcorrected position the cut surfaces are fixed in apposition.

The foot should be retained for several months in the overcorrected position in the plaster bandage, on which the patient walks about until the foot has become adapted to the new position. In many instances further support is unnecessary, but a brace should be used if there is a tendency toward deformity.

The prognosis depends upon the degree of permanent paralysis and its distribution. It is, of course, evident that tendon transplantation is essentially a palliative rather than a curative operation. In selected cases in which the attachment is directly to the bone, and especially when lateral motion is checked by arthrodesis, the results are very satisfactory. The improvement in functional ability is immediately shown in the improved circulation and size of the limb. In some cases of this class the transferred muscle is apparently undergoing an adaptive hypertrophy. It is needless to say that such results are favored by massage and by appropriate exercises. Even in those cases in which the result is far from satisfactory, some improvement is usually apparent.

The principles of tendon transplantation may be applied in other situations. For example, the sartorius or the tensor vaginæ femoris muscle may be attached to the tendon of a paralyzed quadriceps extensor muscle for the purpose of restoring in some degree the ability to extend the leg.

The flexor muscles may be transplanted to the extensor aspect of the thigh to overcome persistent contracture, the result of spastic paralysis. (See page 615.)

The operations for the relief of hemiplegic deformity of the hand have been mentioned. (See page 613.)

Tendon Splicing. Division and overlapping of the tendons of paralyzed muscles may be employed with advantage in certain instances. For example, in complete paralysis of all the dorsal flexors of the foot, each tendon may be shortened and attached to the anterior ligament; thus the toe-drop may be remedied or reduced to such an extent that the deformity may interfere but slightly with locomotion. As a rule, however, apparatus must be employed to prevent a recurrence of the deformity unless it be combined with arthrodesis.

Arthrodesis.

The removal of the cartilaginous surfaces of articulating bones and thus inducing anchylosis for the relief of paralytic deformities of the foot, was first performed by Albert, of Vienna, in 1878. As applied to the foot, it is of special service in those cases in which practically no muscular power remains, the so-called dangle-foot. It may be of service, also, in cases of less disability, as in equinus or calcaneus, when the patient is unable to provide himself with apparatus or desires to dispense with it.

The operation consists in opening the joint and removing the cartilage from the apposed surfaces of the bones, then sewing or nailing them to one another, or simply fixing the parts in a plaster bandage until union has taken place. If the case is one of simple calcaneus or equinus, without lateral deviation, the operation may be limited to the ankle-joint, which may be opened from the back or front side, as seems preferable. As has been stated, the usual incision is about two inches in length over the front of the ankle-joint. The foot is then plantar flexed and the cartilage is thoroughly removed from the articulating surfaces with a thin chisel or knife. The wound is then closed, and the denuded bones are forced into accurate apposition and fixed by a plaster bandage. As soon as possible the patient is encouraged to use the foot. As a rule, in cases of complete paralysis of the anterior group simple anchylosis at the ankle-joint is not sufficient to prevent the toe-drop, and it is well to destroy the mediotarsal joint also. A convenient method is to remove the cartilaginous surface of the astragalonavicular and calcaneocuboid articulations, together with a thin wedge of bone, base uppermost. In some instances the tendons of the paralyzed muscles are shortened to

aid in retaining the foot in the improved position. This, however, is of minor importance. The operation should be performed under the Esmarch bandage, and the limb should be elevated for a time to prevent the subsequent bleeding from the bones.

Arthrodesis and Tendon Transplantation. As has been mentioned, arthrodesis may be combined with tendon transplantation. For example, the astragalonavicular joint may be obliterated if the foot is inclined toward valgus, union being obtained in a position of adduction. Or, if the attitude is one of varus the foot must be held in abduction during the process of consolidation. In some instances the arthrodesis is obtained by removing a thin cuneiform segment from the inner or outer aspect of the foot, including the joint. In the treatment of varus deformity this may include the calcaneocuboid joint also.[1] The operation for the relief of calcaneus deformity has been described. (See page 808.)

The improvement in the gait, obtained by the rectification of deformity, and by fixation of the foot, after arthrodesis, is often very marked, and in many instances support may be discarded; but, in early childhood at least, the patients should, if possible, be kept under observation, in order that recurrence of deformity may be prevented.

Arthrodesis is also performed at the knee and at the elbow-joints and wrist-joints for the purpose of fixing the part in a useful attitude. The operation is, of course, limited to cases of hopeless paralysis, and it is more satisfactory to the older than the younger class of patients, because the liability to recurrence of deformity is less. Arthrodesis at the shoulder-joint is of service when the humeroscapular muscles are paralyzed, especially in those cases in which the muscles that move the scapula retain their power, since anchylosis adds to the effectiveness of the arm muscles. The joint may be opened by an incision along the anterior lower border of the deltoid. The cartilaginous surfaces are removed, and the humerus is then fixed in close contact with the glenoid surface of the scapula by a drill or by sutures until union is firm.

[1] Whitman. Journal of American Orthopedic Association, 1903, No. 1, vol. i.

INDEX.

ABDUCTION in extreme types of weak foot, 676
Abduction in hip disease, 301
Absence of clavicle, 233
  of ribs, 233
  of vertebræ, 230
Absent patella, 436
    treatment of, 436
Abscess in acute osteomyelitis of spine, 130
  complicating tuberculous disease of spine in different regions, 106
      treatment of, 108
  as complication in tuberculous disease of spine, 104
      statistics of, 104
  in different regions of spine, 106
      treatment of, 108
        aspiration in, 110
        injections in, 110
  pelvic, in tuberculous disease of lower region of spine, 44
  as secondary symptom in tuberculous disease of spine, 30
  in thoracic region in tuberculous disease of spine, 55
  in tuberculous disease of hip-joint, 371
      statistics of, 371
        Koenig's, 372
      treatment of, 374
        exploratory operations in, 376
    of knee-joint, 419
      statistics of, 419
      treatment of, 420
Achillobursitis, 713
  anterior, 713
  etiology of, 713
  pathology of, 714
  posterior, 715
  symptoms of, 713
  treatment of, 714
    operative, 715
Achillodynia. *See* Achillobursitis, 713
Achondroplasia. *See* Chondrodystrophia, 492
Acquired calcaneovalgus, 812
    treatment of, 812
  calcaneovarus, 812
    treatment of, 812
  cerebral paralysis, 606–611
Acquired luxation of the clavicle, 233
      treatment of, 233
  simple valgus, 814
  talipes, 794
    calcaneus, 804
      development of deformity in, 804
      symptoms of, 805
      treatment of, 805
        operative, 807
          Whitman's operation, 810
          Willett's operation, 808
    equinovalgus, 813
    equinovarus, 812
    equinus, 796
      etiology of, 797
      prognosis of, 799
      symptoms of, 798
      treatment of, 799
        arthrodesis in, 803
        immediate correction of deformity in, 801
          tonic effect of, 801
        Shaffer extension shoe in, 800
  torticollis, 631
    acute, 631
Acromegalia, 500
  diagnosis of, 500
Active congestion as means of treatment of joint affections, 261
Acute acquired torticollis, 631
  anterior poliomyelitis, 583
      causes of deformity in, 590
          functional use, 591
          gravity, 590
          habitual posture, 591
          muscular action, 590
          subluxation, 591
      deformities of neck in, 592
        secondary, in, 593
        of trunk in, 592
        of upper extremity in, 592
      diagnosis of, 586
        differential, 587
      effects of paralysis of different muscles upon function, 589
      etiology of, 584
      pathology of, 583
      prognosis of, 588
        electrical test in, 588
      retardation of growth in, 591
      statistics, age at onset of, 584

Acute anterior poliomyelitis, statistics of distribution of paralysis, 585
symptoms of, 585
treatment of, 595
mechanical, principles of, 595
operative, 601
arthrodesis in, 603
osteotomy in, 604
of paralysis of arm, 600
of anterior leg muscles, 596
of muscles of hip, 599
of posterior leg muscles, 596
of thigh muscles, 598
of paralytic scoliosis, 600
tendon transplantation in, 602
Acute arthritis of infancy, 270
etiology of, 270
prognosis of, 271
statistics of, 271
symptoms of, 271
treatment of, 271
Acute epiphysitis at hip-joint, 392
infectious arthritis of hip-joint, 392
osteomyelitis, 272
of spine, 130
symptoms of, 130
treatment of, 131
Acute tuberculous arthritis, 272
Adduction in hip disease, 302
Amputation in tuberculous disease of knee-joint, 423
Anchylosis, 286
etiology of, 286
pathology of, 286
prevention of, 286
treatment of, 286
forcible correction in, 288
passive motion in, 288
X-ray in, 289
Ankle-joint, tuberculous disease of, 440
Ankle, sprain of, 450
chronic, 453
treatment of, 453
symptoms of, 450
treatment of, 450
adhesive plaster in, 451
Ankle, tenosynovitis at, 454
treatment of, 455
Ankle, tuberculous disease of, 440
deformity of, 443
diagnosis of, 444
pathology of, 440
physical examination in, 443
prognosis of, 448
statistics of, 440
of age, 441
of results, 448
situation of disease, 441
Ankle, tuberculous disease of, statistics of, table of age at incipiency, 442
subastragaloid disease, 444
symptoms of, 442
treatment of, 446
operative, 447
reduction of deformity in, 446
Anterior achillobursitis, 713
bow-leg, 580
displacement of the tibia. *See* Congenital genu recurvatum, 434
metatarsalgia, 704
etiology of, 705
influence of shoe in causing pain in, 708
pathology of, 705
treatment of, 710
operative, 711
Anterior poliomyelitis, acute. *See* Acute anterior poliomyelitis, 583
Anterior shoulder brace in treatment of tuberculous disease of spine, 76
Anteroposterior deformities of spine, 224
kyphosis, 224
treatment of, 227
lordosis, 228
treatment of, 228
Arborescent synovial tuberculosis, 252
Arthrectomy in treatment of tuberculous disease of knee-joint, 420
results of, 421
statistics of, 421
Arthritis, acute, of infancy, 270
etiology of, 270
prognosis of, 271
statistics of, 271
symptoms of, 271
treatment of, 271
infectious, of hip-joint, 392
tuberculous, 272
complicating infectious diseases, 269
prognosis of, 270
spontaneous dislocation in, 270
treatment of, 269
Arthritis deformans, 274, 396
symptoms of, 397
treatment of, 397
gonorrhœal, 267
distribution, 267
statistics of, 267
of hip-joint, 394
symptoms of, 267
treatment of, 268
varieties of, 268
Arthritis of knee, infectious, 428
of spine, infectious, 135
treatment of, 135
puerperal, 269

Arthritis, rheumatoid, 279
etiology of, 282
treatment of, 282
subacute, of hip-joint, 393
Arthrodesis, description of operation, 823
for relief of paralytic deformities of foot, 823
and tendon splicing, 824
in treatment of acquired talipes equinus, 803
of acute anterior poliomyelitis, 603
of rigid weak foot, 697
Arthrotomy in treatment of congenital dislocation at hip, 527
Astragalectomy in treatment of talipes, 781
Astragaloscaphoid joint, tuberculous disease of, 449
Asymmetrical development, 234
Ataxia, hereditary, 619
Atrophy of bone, 241
progressive muscular, 616
in tuberculous disease of hip-joint, 307
Brackett's statistics of, 308

BACK knee. *See* Genu recurvatum, 432
Back, lower part of, pain in, 144
Bands, constricting, 793
Baseball finger. *See* Mallet finger, 484
Bier's treatment of tuberculous disease of joints, 259
of knee-joint, 418
Bilateral coxa vara, 541
tuberculous disease of hip-joint, 369
treatment of, 369
Billroth splint in treatment of tuberculous disease of knee-joint, 414
Bone, atrophy of, 241
Bow-leg, 553
anterior, 580
symptoms of, 580
treatment of, 582
etiology of, 554
predisposition to deformity, 555
outgrowth of deformity of, 557
statistics of, 553
relative frequency of, 553
table of, 554
treatment of, 558
Brace in treatment of weak foot, 685
construction of, 685
Bradford frame for horizontal fixation in treatment of Pott's disease, 68
modification of, 69
Bursa, enlargement of superficial pretibial, 430
Bursitis, chronic, at shoulder-joint, 469
gluteal, 395
iliopsoas, 395
treatment of, 396
prepatellar, of knee, 429
treatment of, 429
pretibial, 429
symptoms of, 429
treatment of, 430

CALCANEOBURSITIS, 716
treatment of, 716
Calcaneovalgus, 789
acquired, 812
treatment of, 812
Calcaneovarus, 789
acquired, 812
treatment of, 812
Caliper brace in treatment of tuberculous disease of knee-joint, 417
Calot's operation of forcible reduction of deformity of Pott's disease, 123
selection of cases for, 121
statistics of results of, 120
Caries sicca, 253
Cavus, 789
Cerebral paralysis of childhood, 606
acquired, 611
deformities of, 611
disability in, 611
loss of growth in, 611
congenital weakness in, 609
deformities of, 610
etiology of, 606
prognosis of, 615
statistics of distribution of, 606
symptoms of, 608
mental, 609
motor, 608
treatment of, 612
of hemiplegia, 612
of paraplegia, 614
varieties of, 606
acquired, 606
congenital, 606
Cervical opisthotonos, 646
Charcot's disease, 284
diagnosis of, 285
distribution of, 286
pathology of, 284
statistics of, 285
symptoms of, 285
treatment of, 285
Chest, deformities of, 230
minor, 232
flat, 230
treatment of, 230

Chest, funnel, 232
pigeon, 231
treatment of, 231
Chondrodystrophia, 492
etiology of, 492
pathology of, 492
prognosis of, 494
treatment of, 494
Chronic bursitis at shoulder-joint, 469
Clavicle, absence of, 233
acquired luxation of, 233
treatment of, 233
defect of, 233
Club-foot, hysterical, 621
non-deforming. *See* Contracted foot, 699
Club-hand, 479
etiology of, 479
statistics of, 479
treatment of, 481
varieties of, 479
Congenital cerebral paralysis, 606
contraction of fingers, 482
at knee, 439
deformities at elbow, 477
at wrist, 479
Congenital dislocation of hip, 502
anterior, symptoms of, 511
bilateral, symptoms of, 510
diagnosis of, 511
differential, 512
etiology of, 507
pathology of, 503
statistics of, 502
supracotyloid displacement in, 511
symptoms of, 508
general, 510
treatment of, 513
arthrotomy in, 527
description of, 527
in infancy, 526
Lorenz operation in, 514
description of, 515
prognosis of, 523
of older subjects, 526
open operation in, 530
description of, 531
statistics of, 532
osteotomy in, 529
palliative, 534
variation in, 527
unilateral, symptoms of, 508
Congenital dislocation of shoulder, 472
treatment of, 472
displacements of fingers, 483
of patella, 436
elevation of scapula, 228
lateral curvature of spine, 167
cases of, 167
subluxation of hip, 534
talipes, 738
Congenital calcaneus, 788
equinovalgus, 789
equinus, 788
varus, 787
torticollis, 626
Congestion, active, as means of treatment of joint affections, 261
passive, as means of treatment of joint affections, 259
Constricting bands, 793
Contour and flexibility of normal spine, 31
of spine, variations in, 223
Contracted foot, 699
etiology of, 699
symptoms of, 700
treatment of, 702
operative, 703
Contractions, general, at knee, 439
prognosis of, 439
treatment of, 439
Corsets in treatment of tuberculous disease of spine, 95
Coxa valga, 552
vara, 535
bilateral, 541
symptoms of, 541
diagnosis of, 543
etiology of, 537
mechanical predisposition to deformity, 537
other varieties of, 542
pathology of, 536
statistics of, 538
symptoms of, 539
mechanical effects, 539
physical effects, 540
traumatic, 548
in adult life, 551
treatment of, 550
treatment of, 545
operative, 546
cuneiform osteotomy in, 547
forcible abduction in, 546
linear osteotomy in, 546
Cretinism, 494
Cubitus valgus, 477
varus, 477
Cuneiform osteotomy in treatment of coxa vara, 547
of talipes, 782
Cysts of femur, 396
in popliteal region, 430

DEFECT of clavicle, 233
Depression of neck of femur. *See* Coxa vara, 535
Development, asymmetrical, 234
normal, table of, 235
Diagnosis of acromegalia, 500
of acute anterior poliomyelitis, 586
of Charcot's disease, 285

Diagnosis of congenital dislocation at hip-joint, 511
of coxa vara, 543
differential, of lumbar Pott's disease in infancy, 50
of tuberculous disease of hip-joint, 319
of disease of upper region in tuberculous disease of spine, 61
of joint disease, 256
of lateral curvature of spine, 175
posture in, 175
mobility in, 175
of malignant disease of spine, 130
of pseudohypertrophic muscular paralysis, 618
of sacro-iliac disease, 147
of syphilis of spine, 129
of torticollis, 635
of tuberculous disease of ankle-joint, 444
of knee-joint, 408
of spine, 46–64
Roentgen ray as means of, 65
of weak foot, 672
Diphtheritic paralysis with torticollis, 646
Diseases of nervous system, 583
statistics of, 583
Dislocation, spontaneous, in arthritis complicating infectious diseases, 270
of hip-joint, 393
Displacement of the peronei tendons, 727
treatment of, 727
of semilunar cartilage, 431
treatment of, 432
Distortions of fingers, 483
general rhachitic, 582
of limb in tuberculous disease of hip-joint, 301
Divisions of spine, 32
of tendo Achillis in treatment of talipes, 773
Döllinger's statistics of retardation of growth in tuberculous disease of hip, 311
of situation of tuberculous disease of spine, 24
Drop-finger. *See* Mallet finger, 484
Dry caries, 253
Dupuytren's contraction, 484
etiology of, 485
pathology of, 484
symptoms of, 485
treatment of, 485
Dystrophy, muscular, 617

ELBOW, congenital deformities at, 477
Elbow, tuberculous disease of, 460
-joint, tuberculous disease of, 460
Elbow-joint, tuberculous disease of, pathology of, 460
prognosis of, 462
statistics of, 460
age at incipiency, 461
symptoms of, 461
treatment of, 461
excision in, 464
statistics of final results, 464
operative, 464
reduction of deformity in, 462
Elongation of ligamentum patellæ, 438
etiology of, 438
symptoms of, 438
treatment of, 438
Enlargement of superficial pretibial bursa, 430
Epiphysitis, acute, at hip-joint, 392
symptoms of, 392
treatment of, 392
Equinovalgus, traumatic, 814
Erythromelalgia, 717
Excision of elbow in tuberculous disease of elbow-joint, 464
in tuberculous disease of knee-joint, 422
results of, 423
statistics of, 423
Exostoses of foot, 727
Extra-articular disease, 395
of knee, 419

FEET, congenital œdema of, 793
Femur, bending of neck of. *See* Coxa vara, 535
Femur, cysts of, 396
depression of neck of. *See* Coxa vara, 535
fracture of neck of, in adult life, 551
Finger, "baseball." *See* Mallet finger, 484
congenital contraction of, 482
treatment of, 482
displacements of, 483
distortions of, 483
drop. *See* Mallet finger, 484
jerking. *See* Trigger finger, 483
mallet, 484
snapping. *See* Trigger finger, 483
trigger, 483
webbed, 482
etiology of, 483
treatment of, 483
Flat chest, 230
treatment of, 230
foot. *See* Weak foot, 664
Fœtal rhachitis. *See* Chondrodystrophia, 492
Foot in activity, 650
arches of, 647

Foot considered as a mechanism, 660
contracted, 699
etiology of, 699
symptoms of, 700
treatment of, 702
operative, 703
Foot exostoses of, 727
flat. *See* Weak foot, 664
functions of muscles of, 658
general description of, 647
hollow. *See* Contracted foot, 699
improper postures of, 651
movements of, 651
as a passive support, 649
Foot, rigid, 690
treatment of, 690
forcible overcorrection in, 690
manipulation in, 693
varieties of, 695
treatment of, 696
operative, 697
plaster strapping in, 696
Thomas', 696
arthrodesis in, 697
splay. *See* Weak foot, 664
tables of relative strength of muscles of, 659
weak, 664
anatomy of, 664
in childhood, 678
symptoms of, 678
diagnosis of, 672
etiology of, 669
extreme types of, 676
persistent abduction in, 676
pes planus, 676
irregular forms of, 680
limitation of motion and muscular spasm in, 676
pathology of, 668
statistics of, 669
symptoms of, 670
treatment of, 682
attitudes in, 683
brace in, 685
construction of, 685
exercises in, 684
the shoe in, 682
support in, 684
varieties of, 675
Forcible manual correction of deformity of talipes, 763
overcorrection in treatment of rigid weak foot, 690
Fracture of metatarsal bones, 727
of neck of femur. *See* Traumatic coxa vara, 548
in adult life, 551
Fragilitas ossium, 495
Friedreich's disease, 619
Functional affections of joint, 622
pathogenesis of deformity, 235
Funnel chest, 232

GENU varum, 575
symptoms of, 576
Genu varum, treatment of, 578
by braces, 578
expectant, 578
operative, 579
Gluteal bursitis, 395
Gonorrhœal arthritis, 267
distribution, 267
statistics of, 267
of hip-joint, 394
symptoms of, 267
treatment of, 268
varieties of, 268
rheumatism. *See* Gonorrhœal arthritis, 267
Gout, rheumatic, 274
Grattan osteoclast in treatment of talipes, 778

HÆMARTHROSIS, 283
Hæmophilia, 283
Hæmophilia, treatment of, 283
Hallux flexus. *See* Hallux rigidus, 718
rigidus, 718
etiology of, 718
treatment of, 719
Hallux valgus, 722
etiology of, 722
pathology of, 722
symptoms of, 723
treatment of, 723
Holden toe-post in, 723
operative, 725
Hallux varus, 720
treatment of, 721
Hammer-toe, 725
symptoms of, 726
treatment of, 726
Heberden's nodosities in osteoarthritis, 278
Heel, painful, 716
Hemiplegia, treatment of, 612
Hereditary ataxia, 619
High hip in lateral curvature of the spine, 156
shoulder in lateral curvature of spine, 156
Hip, congenital subluxation of, 534
Hip disease. *See* Tuberculous disease of hip-joint, 291
hysterical, 620
-joint, acute infectious arthritis of, 392
epiphysitis at, 392
symptoms of, 392
treatment of, 392
congenital dislocation at, 502
anterior, symptoms of, 511
bilateral, symptoms of, 510
etiology of, 507
diagnosis of, 511
differential, 512

Hip-joint, congenital dislocation at, pathology of, 503
statistics of, 502
supracotyloid displacement in, 511
symptoms of, 508
general, 510
treatment of, 513
arthrotomy in, 527
description of, 527
in infancy, 526
Lorenz operation in, 514
description of, 515
prognosis of, 523
of older subjects, 526
open operation in, 530
description of, 531
statistics of, 532
osteotomy in, 529
palliative, 534
variations in, 527
unilateral, symptoms of, 508
gonorrhœal arthritis of, 394
malignant disease about, 396
osteo-arthritis of, 396
symptoms of, 397
treatment of, 397
snapping, 535
spontaneous dislocation of, 393
subacute arthritis of, 393
traumatism at, 391
treatment of, 391
Hip, tuberculous disease of, 291
abscess in, 371
significance of, 373
statistics of, 371
Koenig's, 372
treatment of, 374
exploratory operations in, 376
actual lengthening of limb in, 313
shortening of limb in, 309
in the adult, 371
atrophy in, 307
Brackett's statistics of, 308
bilateral, 369
treatment of, 369
changes of contour of hip in, 306
combined with disease of other parts, 370
correction of deformity by femoral osteotomy, 382
deformities of other parts caused by, 389
details of 1000 cases of, 324
diagnosis of, differential, 319
anterior poliomyelitis in, 319
coxa vara in, 321
disease of bursæ about joint in, 321
epiphysitis in, 320
extra-articular disease in, 320
Hip, tuberculous disease of, diagnosis of, differential hysterical joint in, 322
infectious arthritis in, 320
osteo-arthritis of hip in, 320
Pott's disease in, 321
rheumatism in, 320
sacro-iliac disease in, 321
scurvy in, 320
traumatic coxa vara in, 321
X-ray as means of, 322
distortion of limb in, 301
apparent lengthening, 301
shortening, 302
etiology of. *See* 243
examination in, method of, 313
physical, 314
excision of hip in, 377
Koenig's method, 377
statistics of, 379
table of functional results, 380
general symptoms of, 313
debility as, 313
fever as, 313
history of case of, 313
in infancy, 370
Koenig's statistics of, 304
local signs of, 318
measurements of, 315
method of estimating degree of distortion of the limb, 316
Lovett's table, 316
Kingsley's table, 318
of recording case of, 322
formula used, 323
mortality in, 384
statistics of, 384
causes of death, 385
"natural cure" in, 303
pathology of, 291
prognosis of, 384
as to function, 387
statistics of, 387
reduction of deformity in resistant cases of, 381
relative frequency of, 295
statistics of, 295
retardation of growth in, 311
Döllinger's statistics of, 311
Taylor's statistics of, 312
sinuses in, 375
treatment of, 375
statistics of age in, 295
of sex in, 295
side affected, 296
symptoms of, 296
limp as, 298
"night cry" as, 297
pain as, 297
stiffness as, 298
treatment of, 325

Hip tuberculous disease of, treatment of, application of spica bandage, 345
of traction splint in, 331
during stage of recovery, 363
immediate reduction of deformity in, 348
Judson's perineal crutch in, 365
Lorenz's spica in, 347
mechanical, 327
high shoe in, 331
perineal bands in, 331
splinting in, 327
traction in, 327
hip splint for, 327
straps for, 329
Taylor's method of, 329
by plaster bandage, 345
practical combination traction, stilting, and splinting, 356
reduction of deformity, lateral traction in, 353
by Marsh's appliance for, 351
by Thomas' method, 342
by traction brace, 333
by weights and pulleys, 350
relative efficiency of traction hip splint, 334
traction and splinting, 354
Taylor's median abduction brace in, 364
Thomas, 338
brace in, 339
modifications of, 343
Holden toe-post in treatment of hallux valgus, 723
Hollow foot. *See* Contracted foot, 699
Horizontal fixation in treatment of tuberculous disease of spine, 67
Bradford frame for, 68
modification of, 69
Lorenz apparatus for, 67
Phelps' bed for, 68
wire cuirasse for, 68
Housemaid's knee, 429
Hysterical club-foot, 621
deformities, 621
hip, 620
diagnosis of, 620
joint affections, 619
scoliosis, 621
treatment of, 621
spine, 143
symptoms of, 143
treatment of, 144

IDIOPATHIC osteopsathyrosis, 495
Iliopsoas bursitis, 395
treatment of, 396
Incurvation of neck of femur. *See* Coxa vara, 535
Infantile paralysis. *See* Acute anterior poliomyelitis, 583
scorbutus, 494
pathology of, 494
symptoms of, 494
treatment of, 495
talipes, 749
Infectious arthritis of knee, 428
of spine, 135
treatment of, 135
Injury of knee in childhood, 427
of spine, 131
of tibial tubercle, 430
Internal derangement of knee-joint, 430
Irregular forms of weak foot, 680

JERKING finger, 483
Joint affections, hysterical, 619
Joints, neurotic, 622
functional affections of, 622
syphilitic diseases of, 263
gonorrhœal arthritis, 267
distribution, 267
statistics of, 267
symptoms of, 267
treatment of, 268
varieties of, 268
puerperal arthritis, 269
treatment of, 265
Judson brace in treatment of talipes, 754
Julius Wolff's method of treatment of talipes, 774
Jury mast in treatment of tuberculous disease of spine, 86

KINGSLEY'S table for estimating degree of distortion in tuberculous disease of hip-joint, 318
Knee, back. *See* Genu recurvatum, 432
bursæ at, 430
congenital contraction at, 439
cysts at, 430
deformities of, 434
displacement of a similunar cartilage in, 431
injury as cause of, 431
treatment of, 432
Knee, general contractions at, 439
prognosis of, 439
treatment of, 439
enlargement of superficial pretibial bursa of, 430
housemaid's, 429

Knee, infectious arthritis of, 428
injury of, in childhood, 427
injury of tibial tubercle, 430
Knee-joint, loose bodies in, 431
internal derangement of, 430
non-tuberculous affections of 427
malformations of, 434
etiology of, 435
treatment of, 435
osteo-arthritis of, 428
treatment of, 428
prepatellar bursitis of, 429
treatment of, 429
Knee, pretibial bursitis of, 429
symptoms of, 429
treatment of, 430
snapping, 438
treatment of, 439
synovitis of, 427
chronic, 428
treatment of, 427
Knee, tuberculous disease of, 399
abscess in, 419
statistics of, 419
treatment of, 420
actual lengthening of limb in, 407
statistics of, 408
shortening of limb in, 407
statistics of, 407
arthrectomy in treatment of, 420
results of, 421
statistics of, 421
diagnosis of, 408
differential, 408
distortions of, primary, 404
secondary, 405
etiology of, 401
operations for relief of final deformity, 423
pathology of, 399
prognosis of, 423
statistics, course, and outcome of, 423
Gibney's, 423
of results, 424
statistics of, 401
age at incipiency, 402
symptoms of, 402
synovial tuberculosis in, 420
treatment of, 420
treatment of, 409
accessory, 417
Bier's treatment, 418
cautery as, 417
ichthyol ointment as, 417
X-ray as, 417
amputation in, 423
Billroth splint in, 413
caliper brace in, 417
during convalescence, 418
Knee, tuberculous disease of, treatment of, excision in, 422
results of, 423
statistics of, 423
forcible correction by reverse leverage, 412
mechanical, 414
operative intervention in, 419
plaster bandage in, 411
reduction of deformity in, 410
Thomas knee brace in, 414
traction in, 412
Knock-knee, 553
combined with bow-leg, 565
with general rhachitic distortions, 565
effects of deformity of, 564
etiology of, 554
predisposition to deformity in, 555
measurements of deformity in, 567
outgrowth of deformity of, 557
pathology of, 566
secondary deformities accompanying, 564
statistics of, 553
relative frequency of, 553
table of, 554
time of onset, 554
treatment of, 567
by braces, 570
duration of, 571
exercise in, 569
expectant, 567
Lorenz's, 575
manipulation in, 568
operative, 572
osteoclasis, 573
osteotomy in, 572
cuneiform, 573
plaster bandage in, 572
posture in, 569
Thomas brace in, 570
Wolff's, 574
unilateral, 565
Kyphosis of adolescents, 141

LAMINECTOMY in treatment of Pott's paraplegia, 118
Laminectomy in treatment of Pott's paraplegia, statistics of, 118
Landmarks of spine, 34
Late rickets, 492
Lateral curvature of spine, 149
changes in anteroposterior contour in, 155
compensatory deformity in, 165
congenital, 167
cases of, 167
diagnosis of, 175

Lateral curvature of spine, diagnosis of mobility in, 175
posture in, 175
due to occupation, 166
etiology of, 161
hereditary influence in, 169
high hip in, 156
shoulder in, 156
incidental, 166
lateral deviation in, 153
occupation as inducing deformity, 170
statistics of, 170
pathology of, 156
prevention of deformity in, 180
prognosis of, 177
records of, 177
rhachitic, 168
statistics of, 169
rotation in, 153
secondary to deformity elsewhere, 165
to disease within thoracic walls, 166
to paralysis, 166
statistics of age in, 163
of relative frequency of, 161
of sex in, 162
symptoms of, 174
treatment of, 181
duration of, 221
exercises in, 185–201
muscle building, 209
Teschner's, 187
forcible correction of deformity in, 217
general, 221
high shoe in, 221
posture in, 185
Volkmann seat in, 221
varieties of deformity in, 173
Ligamentum patellæ, elongation of, 438
etiology of, 438
symptoms of, 438
treatment of, 438
Linear osteotomy in treatment of coxa vara, 546
Loose bodies in knee-joint, 431
Lorenz apparatus for horizontal fixation in treatment of Pott's disease, 67
operation for congenital dislocation at hip, 514
spica bandage in treatment of tuberculous disease of hip-joint, 347
treatment of knock-knee, 575
Lovett's table for estimating degree of distortion in tuberculous disease of hip-joint, 316
Lumbar Pott's disease in infancy, peculiarities of, 49
diagnosis, differential, of, 50

MALFORMATIONS of knee, 434
etiology of, 435
Malformations of knee, treatment of, 435
Malignant disease about hip-joint, 396
of spine, 129
diagnosis of, 130
statistics of, 129
Malleotomy in treatment of talipes, 772
Mallet finger, 484
Marsh's appliance for reduction of deformity in tuberculous disease of hip-joint, 351
Metatarsal bones, fracture of, 727
Metatarsalgia, anterior, 704
etiology of, 705
influence of shoe in causing pain in, 708
pathology of, 705
treatment of, 710
operative, 711
Metzger-Goldthwait apparatus for correction of deformity of Pott's disease, 123
Mollities ossium. *See* Osteomalacia, 496
Morbus coxæ. *See* Tuberculous disease of hip-joint, 291
Morton's neuralgia. *See* Anterior metatarsalgia, 704
Muscles, pectoral, defective formation of, 233
Muscular dystrophy, 617
Myelopathic paralysis, 616
Myopathic paralysis, 617

"NATURAL cure" in tuberculous disease of hip-joint, 303
Nervous system, diseases of, 583
Neuralgia, plantar, 717
treatment of, 717
Neuritis, 619
Neurotic joints, 622
spine, 142
symptoms of, 143
treatment of, 143
Non-deforming club-foot. *See* Contracted foot, 699
Non-tuberculous affections of knee-joint, 427
deformities of knee-joint, 427

OBSTETRICAL paralysis, 473
treatment of, 474
Ocular torticollis, 646
Osteitis deformans, 141, 498
Osteo-arthritis, 274
etiology of, 277
Heberden's nodosities in, 278
of hip-joint, 396
symptoms of, 397

Osteo-arthritis of hip-joint, treatment of, 397
of knee, 428
treatment of, 428
pathology of, 275
symptoms of, 277
treatment of, 279
Osteoclasis in treatment of knock-knee, 573
Osteoclasts in treatment of talipes, 778
Osteomalacia, 496
in childhood, 497
local, 497
treatment of, 497
Osteomyelitis, acute, 272
of spine, acute, 130
symptoms of, 130
treatment of, 131
subacute, 273
Osteotomy, cuneiform, in treatment of knock-knee, 573
in treatment of congenital dislocation of hip, 529
of knock-knee, 572
Overlapping toes, 727

PAGET'S disease, 141
Painful great toe-joint, 719
Painful heel, 716
Paralysis, cerebral, of childhood, 606
acquired, deformities of, 611
disability in, 611
loss of growth in, 611
congenital weakness in, 609
deformities of, 610
etiology of, 606
prognosis of, 615
statistics of distribution of, 606
symptoms of, 608
mental, 609
motor, 608
treatment of, 612
of hemiplegia, 612
of paraplegia, 614
varieties of, 606
acquired, 606
congenital, 606
Paralysis complicating tuberculous disease of spine, 111
duration of, 114
frequency of, 112
liability to, in different regions, 113
prognosis of, 116
symptoms of, 114
time of onset of, 113
treatment of, 116
duration, 126
local, 119
operative, 117
laminectomy, 118
diphtheritic, with torticollis, 646
Paralysis, infantile. *See* Acute anterior poliomyelitis, 583
myelopathic, 616
myopathic, 617
obstetrical, 473
treatment of, 474
pseudohypertrophic muscular, 618
diagnosis of, 618
treatment of, 619
as secondary symptom in tuberculous disease of spine, 30
spastic spinal, 616
Paralytic talipes, tendon transplantation for relief of, 815
time for operation, 815
torticollis, 645
Paraplegia, treatment of, 614
Partial epiphyseal separation in adolescence, 551
Passive congestion as means of treatment of joint affections, 259
Patella, absent, 436
congenital displacement of, 436
rudimentary, 436
slipping, 436
etiology of, 436
symptoms of, 436
treatment of, 437
operative, 437
Pectoral muscles, defective formation of, 233
Pectus carinatum. *See* Pigeon chest, 231
excavatum. *See* Funnel chest, 232
Pelvic abscess, differential diagnosis of, 49
in tuberculous disease of lower region of spine, 44
Periarthritis of shoulder, 468
symptoms of, 468
treatment of, 469
Peronei tendons, displacement of, 727
treatment of, 728
Pes planus, 676
Phelps' bed for horizontal fixation in treatment of Pott's disease, 68
operation in treatment of talipes, 778
Pigeon chest, 231
treatment of, 231
toe, 721
Plantalgia, 717
Plantar neuralgia, 717
treatment of, 717
Plaster bandage in treatment of infantile talipes, 751
of knock-knee, 572
of tuberculous disease of knee-joint, 411
of hip-joint, 345
spica, Lorenz, in treatment of tuberculous disease of hip-joint, 347

Plaster corset in treatment of tuberculous disease of spine, 92
jacket in treatment of Pott's disease, 82
application of, in recumbency, 89
modifications of, 93
strapping in treatment of weak foot, 696
Poliomyelitis, acute anterior, 583
causes of deformity in, 590.
functional use, 591
gravity, 590
habitual posture, 591
muscular action, 590
subluxation, 591
deformities of neck, 592
secondary, 593
of trunk, 592
of upper extremity in, 592
diagnosis of, 586
differential, 587
effects of paralysis of different muscles upon function, 589
etiology of, 584
pathology of, 583
prognosis of, 588
electrical test in, 588
retardation of growth in, 594
statistics of age at onset of, 584
of distribution of paralysis, 585
symptoms of, 585
treatment of, 595
mechanical principles of, 595
operative, 601
arthrodesis in, 603
osteotomy in, 604
tendon transplantation in, 602
paralysis of anterior leg muscles, 596
of paralysis of the arm, 600
of paralysis of muscles of the hip, 599
of paralysis of posterior leg muscles, 596
of paralysis of thigh muscles, 598
of paralytic scoliosis, 600
Posterior achillobursitis, 715
Pott's disease, 17
characteristic angular deformity in, 17
complications of, 104
abscess, 104
in different regions, 106
statistics of, 104
treatment of, 108
aspiration in, 110
injection in, 110
paralysis, 111
Pott's disease, complications of, paralysis, duration of, 114
frequency of, 112
liability to, in different regions, 113
prognosis of, 116
symptoms of, 114
time of onset of, 113
treatment of, 116
local, 119
operative, 117
laminectomy, 118
description of, 17
diagnosis of, in general, 64
Roentgen ray in, 65
examination in, regional, 38
tests in, 37
history of patient having, 36
later effects of deformity of, 127
in lower region, 38
characteristic attitude in, 39
diagnosis of, 46
differential, 46
congenital dislocation of hip, 47
hip disease, 48
lumbago, 46
sacro-iliac disease, 46
sciatica, 46
strain of the back, 46
increased lordosis in, 39
lateral inclination of body in, 40
location of pain in, 40
pelvic abscess in, 44
psoas contraction in, 40
Pott's disease, pathology of, 18
prognosis of, 25
record of case of, 65
recurrence of, 127
relative frequency of, 22
statistics of, 22
secondary deformities of, 127
signs of, physical, 36
rational, 35
statistics of age at incipiency of, 22
Döllinger's, 24
of relative frequency of, in different vertebræ, 24
results of Calot's operation, 120
sex in, 23
situation of disease, 23
symptoms of, 26
awkwardness as, 28
deformity as, 28
diagnostic, 27
general, 31
pain as, 27
secondary, 30
abscess, 30
paralysis, 30
stiffness as, 28

Pott's disease, symptoms of, weakness as, 28
Pott's disease of thoracic region, 51
abscess in, 55
attitudes in, 52
diagnosis of, 55
differential, 56
kyphosis in, 54
muscular spasm in, 54
respiration in, 52
treatment of, 66
ambulatory supports in, 74
anterior shoulder brace in, 76
corsets, 95
jury mast, 86
plaster corset, 92
jacket, 82
application of, in recumbency, 89
modifications of, 93
Taylor brace, 74
head support, 81
Thomas' collar in 96,
Weigel's corset, 95
duration of, 126
forcible correction of deformity of, 119
Calot's operation, 119
selection of cases for, 121
gradual correction of deformity of, 123
Goldthwait's method, 123
Metzger-Goldthwait apparatus for, 123
horizontal fixation in, 67
Bradford frame for, 68
Lorenz apparatus for, 67
Phelps' bed for, 68
Wire cuirasse for, 68
modifications of, 69
indications for, by recumbency, 98
special, of different regions, 99
of lower region of spine, 100
dorsal region of spine, 101
mechanical, general principles of, 66
of middle cervical region of spine, 102
of middle region of spine, 102
of occipito-axoid region of spine, 103
of upper dorsal region of spine, 102
Pott's disease of upper region, 57
cervicodorsal junction, 60
diagnosis of, 61
lower cervical section, 59
occipito-axoid section, 58
symptoms of, 58
Pott's fracture, 814
Prepatellar bursitis of knee, 429
treatment of, 429
Pretibial bursitis, 429
symptoms of, 429
treatment of, 430
Progressive muscular atrophy, 616
varieties of, 616
myelopathic, 616
myopathic, 617
muscular dystrophy, 617
Pseudohypertrophic muscular paralysis, 618
Psychical torticollis, 646
Puerperal arthritis, 269

RECURRENT dislocation of shoulder, 476
Recurrent dislocation of shoulder, treatment of, 476
operative, 476
Retardation of growth in acute anterior poliomyelitis, 594
Retrocalcaneobursitis. *See* Achillobursitis, 713
Rhachitic distortions, general, 582
lateral curvature of spine, 168
statistics of, 169
spine, 133
natural cure of, 133
treatment of, 133
torticollis, 646
Rhachitis, 486
etiology of, 486
fœtal, 492
prognosis of, 490
symptoms of, 487
deformities as, 487
treatment of, 491
prevention of deformity in, 492
Rheumatic gout, 274
Rheumatism, gonorrhœal. *See* Gonorrhœal arthritis, 267
Rheumatoid arthritis, 279
etiology of, 282
treatment of, 282
Ribs, absence of, 233
Rice bodies in tuberculous joint disease, 253
Rickets. *See* Rhachitis, 486
late, 492
scurvy. *See* Infantile scorbutus 494
Rigid weak foot, 690
treatment of, 690
forcible overcorrection in, 690
manipulation in, 693
varieties of, 695
treatment of, 696
operative, 697
arthrodesis in, 697
plaster strapping in, 696
Thomas, 696

Roentgen ray as means of diagnosis in tuberculous disease of spine, 65
Rotary lateral curvature of spine, 149
Rudimentary patella, 436
treatment of, 436

SACRO-ILIAC articulation, injury of, 148
Sacro-iliac disease, 146
diagnosis of, 147
prognosis of, 147
symptoms of, 146
treatment of, 147
Scapula, congenital elevation of, 228
Sciatic scoliosis, 145
Sciatica, deformity secondary to, 145
Scoliosis. *See* Lateral curvature of spine, 149
hysterical, 621
treatment of, 621
Scorbutus, 284
infantile, 494
Scurvy, 284, 494
Secondary deformities accompanying knock-knee, 564
hypertrophic osteo-arthropathy, 499
Septic infection in tuberculous joint disease, 253
Shaffer extension shoe in treatment of acquired talipes equinus, 800
Shoes, 728
in treatment of weak foot, 682
Shoulder, congenital dislocation of, 472
treatment of, 472
Shoulder-joint, chronic bursitis at, 469
periarthritis of, 468
symptoms of, 468
treatment of, 469
recurrent dislocation of, 476
treatment of, 476
operative, 476
tuberculous disease of, 457
pathology of, 457
prognosis of, 460
statistics of, 457
age at incipiency of, 458
symptoms of, 458
treatment of, 459
operative, 460
Slipping patella, 436
Snapping finger, 483
hip, 535
knee, 438
Socks, 732
Spasmodic torticollis. *See* Torticollis, spasmodic, 640
Spastic spinal paralysis, 616
Spina bifida and talipes, 793
ventosa, 466
Spina ventosa, statistics of, 467
Spine, actinomycosis of, 131
acute osteomyelitis of, 130
symptoms of, 130
treatment of, 131
anteroposterior deformities of, 224
kyphosis, 224
treatment of, 227
lordosis, 228
treatment of, 228
contour and flexibility of normal, 31
divisions of, 32
hysterical, 143
symptoms of, 143
treatment of, 144
infectious arthritis of, 135
treatment of, 135
injury of, 131
landmarks of, 34
lateral curvature of, 149
cases of, 167
changes in anteroposterior contour in, 155
compensatory deformity in, 165
congenital, 167
diagnosis of, 175
posture in, 175
mobility in, 175
due to occupation, 166
etiology of, 161
hereditary influence in, 169
high hip in, 156
shoulder in, 156
incidental, 166
lateral deviation in, 153
occupation as inducing deformity, 170
statistics of, 170
pathology of, 156
prevention of deformity in, 180
prognosis of, 177
records of, 177
rhachitic, 168
statistics of, 169
rotation in, 153
secondary to deformity elsewhere, 165
to disease within thoracic walls, 166
to paralysis, 166
statistics of age in, 163
of relative frequency of, 161
of sex in, 162
symptoms of, 174
treatment of, 181
duration of, 221
exercises in, 185–201
Teschner's, 187
muscle building, 209
forcible correction deformity in, 217

Spine, lateral curvature of, treatment of, general, 221
high shoe in, 221
posture in, 185
Volkmann seat in, 221
varieties of deformity in, 173
Spine, malignant disease of, 129
diagnosis of, 130
statistics of, 129
neurotic, 142
symptoms of, 143
treatment of, 143
osteo-arthritis of. *See* Spondylitis deformans, 135
rhachitic, 133
natural cure of, 133
treatment of, 133
rheumatism of. *See* Spondylitis deformans, 135
syphilis of, 129
diagnosis of, 129
tabetic deformity of, 142
Spine, tuberculous disease of, 17
complications of, 104
abscess, 104
in different regions, 106
statistics of, 104
treatment of, 108
aspiration in, 110
injection in, 110
paralysis, 111
duration of, 114
frequency of, 112
liability to, in different regions, 113
local, 119
prognosis of, 116
symptoms of, 114
time of onset of, 113
treatment of, 116
operative, 117
laminectomy, 118
diagnosis of, 46
differential, 46
congenital dislocation of hip, 47
hip disease, 48
lumbago, 46
sacro-iliac disease, 46
sciatica, 46
in general, 64
Roentgen ray in, 65
examination in, regional, 38
tests in, 37
forcible correction of the deformity of, 119
Calot's operation, 119
selection of cases for, 121
gradual correction of deformity of, 123
Goldthwait's method, 123
Metzger-Goldthwait apparatus for, 123
Spine, tuberculous disease of, history of patient having, 36
later effects of deformity of, 127
in lower region, 38
characteristic attitude of, 38
increased lordosis in, 39
lateral inclination of body in, 40
location of pain in, 40
pelvic abscess in, 44
psoas contraction in, 40
pathology of, 18
prognosis of, 25
record of the case, 65
recurrence of, 127
relative frequency of, 22
statistics of, 22
secondary deformities of, 127
signs of, physical, 36
rational, 35
statistics of age at time of onset of, 23
results of Calot's operation, 120
sex, 23
situation of disease, 23
symptoms of, 26
awkwardness as, 28
deformity as, 28
diagnostic, 27
general, 31
pain as, 27
secondary, 30
abscess, 30
paralysis, 30
stiffness as, 28
weakness as, 28
thoracic region, 51
abscess in, 55
attitudes in, 52
diagnosis of, 55
differential, 56
kyphosis in, 54
muscular spasm in, 54
respiration in, 52
treatment, 66
ambulatory supports in, 74
anterior shoulder brace in, 76
corsets, 95
jury mast, 86
plaster corset, 92
plaster jacket, 82
modifications of, 93
Taylor brace, 74
head support, 81
Thomas' collar, 96
Weigel's corset, 95
duration of, 126
indications for, by recumbency, 98

Spine, tuberculous disease of, treatment of special indications for, of different regions, 99
mechanical, general principles of, 66
horizontal fixation in, 67
Bradford frame, 68
modifications of, 69
Lorenz apparatus for, 67
Phelps' bed, 68
wire cuirasse, 68
middle cervical region, 102
region, 102
occipito-axoid region, 103
upper dorsal region, 102
upper region, 57
cervicodorsal junction, 60
diagnosis of, 61
lower cervical section, 59
occipito-axoid section, 58
symptoms of, 58
Spine, typhoid, 134
treatment of, 134
variations in contour of, 223
Splay foot. *See* Weak foot, 664
Spondylitis deformans, 135
cases of, 138
pathology of, 136
symptoms of, 138
treatment of, 141
traumatic, 132
treatment of, 133
Spondylolisthesis, 145
Spondylose rhizomélique. *See* Spondylitis deformans, 135
Spontaneous dislocation of hip-joint, 393
Sprain of ankle, 450
chronic, 453
treatment of, 453
symptoms of, 450
treatment of, 450
adhesive plaster in, 451
of wrist, 470
chronic, 470
Sprengel's deformity, 228
cases of, 229
etiology of, 229
treatment of, 229
Statistics of abscess complicating tuberculous disease of the spine, 104
in different regions, 106
in tuberculous disease of hip-joint, 371
Koenig's, 372
knee-joint, 419
of actual lengthening in tuberculous disease of knee-joint, 408
shortening in tuberculous disease of knee-joint, 407
Statistics of acute arthritis of infancy, 271
age at incipiency of tuberculous disease of elbow-joint, 461
of knee-joint, 402
of shoulder-joint, 458
of wrist-joint, 465
in lateral curvature of spine, 163
at onset of acute anterior poliomyelitis, 584
of patients having tuberculous disease of ankle-joint, 441
of bones and joints, 247
of hip-joint, 295
at time of onset of tuberculous disease of spine, 23
of bow-leg, 553
relative frequency of, 553
table of, 554
Brackett's, of atrophy in tuberculous disease of hip-joint, 308
of causes of death in tuberculous disease of hip-joint, 385
of knee-joint, 425
of Charcot's disease, 285
of club-hand, 479
of congenital dislocation at hip-joint, 502
of coxa vara, 538
of deformity resulting from tuberculous disease of knee-joint, 425
of diseases of nervous system, 583
of distribution of disease in tuberculous disease of bones and joints, 246
of paralysis in acute anterior poliomyelitis, 585
in cerebral paralysis of childhood, 606
Döllinger's, of retardation of growth in tuberculous disease of hip-joint, 311
of situation of tuberculous disease of spine, 24
of excision of hip in tuberculous disease of hip-joint, 379
of final results of excision of elbow, 464
in tubercular disease of knee-joint, 424
of frequency of paralysis in Pott's disease, 112
functional results after tuberculous disease of hip-joint, 387
of knee-joint, 424
Gibney's, of course and outcome of tuberculous disease of knee-joint, 423
of gonorrhœal arthritis, 267
of knock-knee, 553
relative frequency of, 553

Statistics, knock-knee, table of, 554
of malignant disease of spine, 129
of mortality, Koenig's, in tuberculous disease of knee-joint, 424
in tuberculous disease of hip-joint, 384
occupation as inducing deformity in lateral curvature of spine, 170
of open operation for congenital dislocation of hip, 532
of relative frequency of different forms of talipes, 742
of lateral curvature of spine, 161
of tuberculous disease at different vertebræ, 24
of hip-joint, 295
of spine, 22
strength of muscles of foot, 659
of results of arthrectomy in tuberculous disease of knee-joint, 421
of Calot's operation, 120
of excision in tuberculous disease of knee-joint, 423
of laminectomy in treatment of Pott's paraplegia, 118
after-treatment of tuberculous disease of ankle-joint, 448
rhachitic lateral curvature of spine, 169
of sex in lateral curvature of spine, 162
of patients with tuberculous disease of hip-joint, 295
of spine, 23
of bones and joints, 247
of side affected in tuberculous disease of bones and joints, 246
of hip-joint, 296
of situation of disease in tuberculous disease of ankle-joint, 441
of spine, 23
of spina ventosa, 467
table of age at incipiency of tuberculous disease of ankle-joint, 442
of talipes, 741
equinovalgus with congenital absence of fibula, 790
Taylor's, of retardation of growth in tuberculous disease of hip-joint, 312
of tendon transplantation for relief of paralytic talipes, 815
of torticollis, 625
of tuberculous disease of ankle-joint, 440
elbow-joint, 460
individual bones, 449
of knee-joint, 401
of shoulder-joint, 457
of wrist-joint, 464
Statistics of weak foot, 669
Strain of tendo Achillis, 716
Subacute osteomyelitis, 273
Subastragaloid disease, 441
Subcutaneous tenotomy in treatment of talipes, 772
Subluxation of wrist, 478
etiology of, 478
treatment of, 479
Synovial tuberculosis at knee, 420
treatment of, 420
Synovitis of knee, 427
chronic, 428
treatment of, 428
treatment of, 427
Syphilis of spine, 129
diagnosis of, 129
Syphilitic diseases of joints, 263
gonorrhœal arthritis, 267
distribution of, 267
statistics of, 267
symptoms of, 267
treatment of, 268
varieties of, 268
puerperal arthritis, 269
treatment of, 265

TABETIC deformity of spine, 142
Table of functional results after excision of hip, 380
Table of weight, height, and circumference of chest in childhood, 235
Talipes, 733
acquired, 794
development of deformity in, 795
differential diagnosis from congenital, 796
etiology of, 794
arcuatus. *See* Contracted foot, 699
calcaneus, acquired, 804
development of deformity in, 804
symptoms of, 805
treatment of, 805
operative, 807
Whitman's operation, 808
Willett's operation, 808
congenital, 788
Talipes, congenital, anatomy of, 743
etiology of, 738
symptoms of, 748
treatment of, 748
cavus. *See* Contracted foot, 699
equinovalgus, 789
acquired, 813
with congenital absence of fibula, 790
etiology of, 791
statistics of, 791
treatment of, 792
equinovarus, acquired, 812
with congenital absence of tibia, 792

Talipes equinus, acquired, 796
etiology of, 797
prognosis of, 799
symptoms of, 798
treatment of, 799
arthrodesis in, 803
immediate correction of deformity in, 801
tonic effect of, 801
Shaffer extension shoe in, 800
Talipes, etiology of, 736
forcible manual correction of deformity of, 763
infantile, treatment of, Judson's brace in, 754
manual correction in, 760
mechanical, 750
plaster bandage in, 751
principles of, 749
rectification of deformity in, 750
retention brace in, 758
splints and braces in, 754
Taylor brace in, 758
tenotomy in, 756
plantaris. *See* Contracted foot, 699
rapid correction of deformity of, 763
secondary deformities of, 770
and spina bifida, 793
statistics of, 741
relative frequency of different forms of, 742
treatment of, division of the tendo Achillis in, 773
open method, 773
malleotomy in, 772
by method of Julius Wolff, 774
neglected, 761
operations on the bones in, 781
astragalectomy, 781
cuneiform osteotomy, 782
operations on bones in, secondary osteotomy, 783
by osteoclasts, 778
Grattan method, 778
Phelps' operation, 778
simple mechanical rectification of deformity in walking children, 783
subcutaneous tenotomy in, 772
by Thomas' method, 776
by wrenches, 776
valgus, simple, acquired, 814
varieties of, 734
varus, congenital, 787
with congenital absence of tibia, 792
Tarsus, tuberculous disease of, 449
treatment of, 449
Taylor brace in treatment of infantile talipes, 758
of tuberculous disease of spine, 74
Taylor brace in treatment of tuberculous disease of spine, application of, 77
measurements for, 76
Taylor head support in treatment of tuberculous disease of spine, 81
median abduction brace in treatment of tuberculous disease of hip-joint, 364
method of traction in tuberculous disease of hip-joint, 329
statistics of retardation of growth in tuberculous disease of hip, 312
Tendo Achillis, division of, in treatment of talipes, 773
strain of, 716
Tendon splicing, 823
and arthrodesis, 824
transplantation in combination with other procedures, 822
relief of paralytic talipes, 815
the operation, 820
modifications of, 821
selection of muscles for, 817
statistics of, 815
in treatment of acute anterior poliomyelitis, 602
Tenosynovitis, 454
acute, at wrist, 470
chronic, at wrist, 471
treatment of, 455
tuberculous, 455
Tenotomy in treatment of infantile talipes, 756
Teschner's exercises in treatment of lateral curvature of spine, 187
Thomas' brace in treatment of knock-knee, 570
of tuberculous disease of hip-joint, 339
modifications of, 343
collar in treatment of tuberculous disease of spine, 96
knee brace in treatment of tuberculous disease of knee-joint, 414
method of reduction of deformity in tuberculous disease of hip-joint, 342
of treatment of talipes, 776
treatment of tuberculous disease of hip-joint, 338
for weak foot, 696
Tibia, anterior displacement of. *See* Congenital genu recurvatum, 434
Toe-joint, painful great, 719
Toes, overlapping, 727
Torticollis, 625
acquired, 631
causes of, 633
varieties of, 631
acute, 631
etiology of, 632
symptoms of, 633

Torticollis, acquired, varieties of acute, treatment of, 640
congenital, 626
etiology of, 629
pathology of, 630
Torticollis, congenital, diagnosis of, 635
with diphtheritic paralysis, 646
irregular forms of, 645
cervical opisthotonos, 646
ocular, 646
paralytic, 645
pathology of, 641
psychical, 646
rhachitic, 646
spasmodic, 640
etiology of, 641
prognosis of, 642
treatment of, 642
description of operation for, 643
operative, 642
statistics of, 625
treatment of, 636
by manipulation, 636
by the open method, 637
overcorrection of deformity in, 638
by subcutaneous tenotomy, 637
Traction hip splint for tuberculous disease of hip-joint, 327
application of, 331
straps for tuberculous disease of hip-joint, 329
Traumatic coxa vara, 548
in adult life, 551
treatment of, 550
equinovalgus, 814
separation of the epiphysis of head of femur, 550
Traumatic spondylitis, 132
treatment of, 133
valgus, 814
Treatment of abscess complicating tuberculous disease of spine, 108
aspiration in, 110
injections in, 110
in tuberculous disease of hip-joint, 374
exploratory operation in, 376
of knee-joint, 420
of achillobursitis, 714
of acquired calcaneovalgus, 812
calcaneovarus, 812
luxation of clavicle, 233
talipes calcaneus, 805
equinus, 799
of acute acquired torticollis, 631
anterior poliomyelitis, 595
arthritis of infancy, 271
Treatment of acute epiphysitis at hip-joint, 392
osteomyelitis of spine, 131
of anchylosis, 286
forcible correction in, 288
passive motion in, 288
X-ray in, 289
of anterior bow-leg, 582
of anteroposterior deformities of spine, 227
of arthritis complicating infectious diseases, 269
deformans, 397
Bier's, of tuberculous disease of joints, 259
of bilateral hip disease, 369
of bow-leg, 558
of calcaneobursitis, 716
of cerebral paralysis of childhood, 612
of Charcot's disease, 285
of chondrodystrophia, 494
of chronic sprain of ankle, 453
synovitis of knee, 428
of club-hand, 481
of congenital dislocation at hip-joint, 513
of shoulder, 472
talipes, 748
of contracted fingers, 484
foot, 702
of coxa vara, 545
of displaced semilunar cartilage, 432
of displacement of peronei tendons, 727
of Dupuytren's contraction, 485
during stage of recovery of tuberculous disease of hip-joint, 363
of elongation of ligamentum patellæ, 438
of flat chest, 230
of general contractions at knee, 439
of genu varum, 578
of gonorrhœal arthritis, 268
of hæmophilia, 283
of hallux rigidus, 719
valgus, 723
varus, 721
of hammer-toe, 726
of hemiplegia, 612
of hysterical scoliosis, 621
spine, 144
of iliopsoas bursitis, 396
of infantile scorbutus, 495
talipes, 750
of infectious arthritis of spine, 135
of knock-knee, 567
of lateral curvature of spine, 181
duration of, 221
exercises in, 185–201

Treatment of lateral curvature of spine, exercises in, Teschner's, 187
for muscle building, 209
forcible correction of deformity in, 217
general, 221
high shoe in, 221
posture in, 185
Volkmann seat in, 221
malformations of knee, 435
mechanical, of tuberculous disease of hip-joint, 327
of spine, ambulatory supports in, 74
anterior shoulder brace, 76
application of, in recumbency, 89
jury mast, 86
plaster corset as, 92
plaster jacket as, 82
Taylor brace as, 74
head support, 81
Thomas' collar, 96
Weigel's corset as, 95
general principles of, 66
horizontal fixation in, 67
Bradford frame for, 68
Lorenz apparatus for, 67
Phelps' bed for, 68
wire cuirasse for, 68
of metatarsalgia, 710
of neglected talipes, 761
of neurotic spine, 143
of obstetrical paralysis, 474
operative, of tuberculous disease of ankle-joint, 447
of elbow-joint, 462
of shoulder-joint, 460
of osteo-arthritis, 279
of hip-joint, 397
of knee, 428
of osteomalacia, 497
of paralysis complicating tuberculous disease of spine, 116
operative, 117
laminectomy, 118
statistics, results, 118
of paraplegia, 614
of periarthritis of shoulder, 469
of pigeon chest, 231
of plantar neuralgia, 717
of prepatellar bursitis of knee, 429
of pretibial bursitis, 430
of pseudohypertrophic muscular paralysis, 619
of recurrent dislocation of shoulder, 476
of rhachitic spine, 133
of rhachitis, 491
of rheumatoid arthritis, 282
Treatment of rigid weak foot, 690
of rudimentary or absent patella, 436
of sacro-iliac disease, 147
of sinuses in tuberculous disease of hip-joint, 375
of slipping patella, 437
operative, 437
of snapping knee, 439
of spasmodic torticollis, 642
of spondylitis deformans, 141
of sprain of ankle, 450
of Sprengel's deformity, 229
of subluxation of wrist, 479
of synovial tuberculosis at knee, 420
of synovitis of knee, 427
of talipes equinovalgus with congenital absence of fibula, 792
of tenosynovitis, 455
of torticollis, 636
of traumatic coxa vara, 550
spondylitis, 133
of traumatisms at hip-joint, 391
of trigger finger, 484
of tuberculous disease of ankle-joint, 446
of elbow-joint, 461
of hip-joint, 325
of joints, 256
carbolic acid in, 258
by drugs, 257
by local application, 258
X-ray in, 258
of knee-joint, 409
of shoulder-joint, 459
of spine, 66
indications for, by recumbency, 98
special, at different regions, 99
lower region, 100
dorsal region, 101
middle region, 102
cervical region, 102
occipito-axoid region, 103
upper dorsal region, 102
of tarsus, 449
of wrist-joint, 465
of typhoid spine, 134
of varieties of rigid weak foot, 696
of weak foot, 682
of webbed fingers, 483
Trigger finger, 483
etiology of, 483
treatment of, 484
Tuberculosis of bones and joints, 243
distribution of disease in, 246
statistics of, 246
age, 247
sex, 247
side affected, 246
etiology of, 243
local predisposition to, 245

Tuberculosis of bones and joints, mode of infection in, 243
pathology of, 248
perforation of joint in, 250
latent, 243
synovial, at knee, 420
treatment of, 420
Tuberculous disease of ankle-joint, 440
deformity of, 443
diagnosis of, 444
pathology of, 440
physical examination in, 443
prognosis of, 448
statistics of, 440
age, 441
results, 448
situation of disease, 441
table of age at incipiency, 442
subastragaloid disease, 444
symptoms of, 442
treatment of, 446
operative, 447
reduction of deformity in, 446
of astragaloscaphoid joint, 449
Tuberculous disease of elbow-joint, 460
excision of elbow in treatment of, 464
statistics of final results, 464
pathology of, 460
prognosis of, 462
statistics of, 460
age at incipiency of, 461
symptoms of, 461
treatment of, 461
operative, 464
reduction of deformity in, 462
Tuberculous disease of hip-joint, 291
abscess in, 371
significance of, 373
statistics of, 371
Koenig's, 372
treatment of, 374
exploratory operations in, 376
actual lengthening of limb in, 313
shortening of limb in, 309
in adult, 371
atrophy in, 307
Brackett's statistics of, 308
bilateral, 369
treatment of, 369
changes in contour of hip in, 306
combined with disease of other parts, 370
correction of deformity by femoral osteotomy, 382
Tuberculous disease of hip-joint, deformities of other parts caused by, 389
details of 1000 cases of, 324
diagnosis of, differential, 319
anterior poliomyelitis in, 319
congenital dislocation of hip, 322
coxa vara in, 321
traumatic, in, 321
disease of bursæ about joint in, 321
epiphysitis in, 320
extra-articular disease in, 320
growing pains in, 319
hysterical joint in, 322
infectious arthritis in, 320
local injury in, 319
local irritation in, 319
osteo-arthritis of the hip in, 320
Pott's disease in, 321
rheumatism in, 320
sacro-iliac disease in, 321
scurvy in, 320
synovitis in, 319
X-ray as means of, 322
distortion of the limb in, 301
apparent lengthening, 301
shortening, 302
etiology of. *See* 243
examination in, method of, 313
physical, 314
excision of hip in, 377
Koenig's method of, 377
statistics of, 379
table of functional results, 380
general symptoms of, 313
debility, 313
fever, 313
history of case of, 313
in infancy, 370
Koenig's statistics of, 304
local signs of, 318
measurements of, 315
method of estimating degree of distortion of limb in, 316
Kingsley's table, 318
Lovett's table, 316
of recording case of, 322
formula used, 323
mortality in, statistics of, 384
causes of death, 385
natural cure in, 303
pathology of, 291
prognosis of, 384
as to function, 387
statistics of, 387
as to functional results, 387

Tuberculous disease of the hip-joint, reduction of deformity in resistant cases of, 381
relative frequency of, 295
statistics of, 295
retardation of growth in, 311
Döllinger's statistics of, 311
Taylor's statistics of, 312
sinuses in, 375
treatment of, 375
statistics of age in, 295
of sex in, 295
side affected, 296
symptoms of, 296
limp as, 298
night cry as, 297
pain as, 297
stiffness as, 298
treatment of, 325
application of plaster spica, 345
during stage of recovery, 363
immediate reduction of deformity in, 348
Judson's perineal crutch in, 365
Lorenz's spica in, 347
mechanical, 327
application of traction splint in, 331
high shoe in, 331
perineal bands in, 331
splinting in, 327
Taylor's method of traction in, 329
traction in, 327
hip splint for, 327
straps for, 329
by plaster bandage, 345
practical combination traction, splinting, stilting, 356
reduction of deformity by Thomas' method, 342
by traction brace in, 333
by weights and pulleys, 350
lateral traction in, 353
Marsh's appliance for, 351
relative efficiency of traction hip splint in, 334
and splinting, 354
Taylor's median abduction brace, 364
Thomas', 338
brace in, 339
modifications of, 343
Tuberculous disease of individual bones, 449
statistics of, 449
Tuberculous disease of bones and joints, 241
arborescent synovial, 252
caries sicca, 253
diagnosis of, 256
lipoma arborescens, 252
other forms of, 251
prognosis in, 254
repair in, 254
rice bodies, 253
septic infection in, 253
treatment of, 256
Tuberculous disease of knee-joint, 399
abscess in, 419
statistics of, 419
treatment of, 420
actual lengthening of limb in, 407
statistics of, 408
shortening of limb in, 407
statistics of, 407
diagnosis of, 408
differential, 408
Charcot's disease in, 409
hæmophilia in, 408
hysterical joint in, 409
infectious arthritis in, 409
injury in, 408
osteo-arthritis in, 409
rheumatism in, 409
rheumatoid arthritis in, 409
sarcoma in, 409
synovitis in, 408
distortions of, primary 404
secondary, 405
etiology of, 401
operations for relief of final deformity, 423
pathology of, 399
prognosis of, 423
statistics, course, and outcome of, 423
Gibney's, 423
of results, 424
statistics of, 401
age at incipiency, 402
symptoms of, 402
synovial tuberculosis, 420
treatment of, 420
treatment of, 409
accessory, 417
Bier's treatment of, 418
cautery as, 417
ichthyol ointment as, 417
X-ray as, 417
amputation, 423
arthrectomy in, 420
results of, 421
statistics of, 421
Billroth splint in, 413
during convalescence, 418
excision in, 422
results of, 423

Tuberculous disease of knee-joint, treatment of, excision in, statistics of, 423
forcible correction by reverse leverage, 412
mechanical, 414
caliper brace in, 417
Thomas knee brace in, 414
operative intervention in, 419
plaster bandage in, 411
reduction of deformity in, 410
traction in, 412
Tuberculous disease of shoulder-joint, 457
pathology of, 457
prognosis of, 460
statistics of, 457
age at incipiency of, 458
symptoms of, 458
treatment of, 459
operative, 460
Tuberculous disease of spine, 17
abscess in different regions, 106
treatment of, 108
aspiration in, 110
injections in, 110
complications of, 104
abscess, 104
statistics of, 104
paralysis, 111
duration of, 114
frequency of, 112
liability to in different regions, 113
prognosis of, 116
symptoms of, 114
time of onset of, 113
treatment of, 116
local, 119
operative, 117
laminectomy, 118
correction of deformity of, forcible, 119
Calot's operation, 119
selection of cases for, 121
gradual, 123
Goldthwait's method, 123
Metzger - Goldthwait apparatus for, 123
diagnosis of, differential, 46
congenital dislocation of hip in, 47
hip disease in, 48
lumbago in, 46
sacro-iliac disease in, 46
sciatica in, 46
strain of back in, 46
in general, 64
Roentgen ray in, 65
examination in, regional, 38
tests in, 37
Tuberculous disease of spine, history of patient having, 36
later effects of deformity of, 127
Tuberculous disease of spine in lower region, 38
characteristic attitude of, 38
increased lordosis in, 39
lateral inclination of body in, 40
location of pain in, 40
pelvic abscess in, 44
psoas contraction in, 40
pathology of, 18
physical signs of, 36
prognosis of, 25
rational signs of, 35
record of the case, 65
recurrence of, 127
relative frequency of, 22
statistics of, 22
secondary deformities of, 127
statistics of age at time of onset, 22
Döllinger's, 24
of relative frequency at different vertebræ, 24
of results of Calot's operation, 120
of sex, 23
of situation of disease, 23
symptoms of, 26
awkwardness as, 28
deformity as, 28
diagnostic, 27
general, 31
pain as, 27
secondary, 30
abscess, 30
paralysis, 30
stiffness as, 28
weakness as, 28
Tuberculous disease of spine, thoracic region, 51
abscess in, 55
attitudes in, 52
diagnosis of, 55
differential, 56
kyphosis in, 54
muscular spasm in, 54
respiration in, 52
treatment of, 66
duration of, 126
indications for, by recumbency, 98
special, of different regions, 99
of lower dorsal, 101
region, 100
mechanical, 67
ambulatory supports in, 74

Tuberculous disease of spine, treatment of, mechanical, ambulatory supports in, anterior shoulder brace, 76
corsets, 95
plaster, 92
Wiegel's, 95
jury mast, 86
plaster jacket, 82
application of, in recumbency, 89
modifications of, 93
Taylor brace, 74
head support, 81
Thomas collar, 96
general principles of, 66
horizontal fixation in, 67
Bradford frame, 68
modifications of, 69
Lorenz apparatus, 67
Phelps' bed, 68
wire cuirasse, 68
Tuberculous disease of spine of middle cervical region, 102
of middle region, 102
of occipito-axoid region, 103
of upper dorsal region, 102
of upper region, 57
cervicodorsal junction, 60
diagnosis of, 61
lower cervical section, 59
occipito-axoid section, 58
symptoms of, 58
Tuberculous disease of tarsus, treatment of, 449
Tuberculous disease of wrist-joint, 464
prognosis of, 466
statistics of, 464
age at incipiency, 465
symptoms of, 465
treatment of, 465
Tumor albus. *See* Tuberculous disease of knee-joint, 399
Typhoid spine, 134
treatment of, 134

UNILATERAL knock-knee, 565

VALGOCAVUS, 789
Valgus, simple acquired, 814
Valgus, traumatic, 814
Vertebræ, absence of, 230
Volkmann seat in treatment of lateral curvature of spine, 221

WEAK foot, 664
anatomy of, 664
Weak foot in childhood, 678
symptoms of, 678
Weak foot in childhood, diagnosis of, 672
etiology of, 669
extreme types of, 676
persistent abduction in, 676
pes planus, 676
irregular forms of, 680
limitation of motion and muscular spasm in, 676
pathology of, 668
rigid, 690
treatment of, 690
forcible overcorrection in, 690
manipulation in, 693
varieties of, 695
treatment of, 696
operative, 697
arthrodesis in, 697
plaster strapping in, 696
Thomas', 696
Weak foot, statistics of, 669
symptoms of, 670
treatment of, 682
attitudes in, 683
brace in, 685
construction of, 685
exercises in, 684
shoe in, 682
support in, 684
varieties of, 675
Webbed fingers, 482
etiology of, 483
treatment of, 483
White swelling. *See* Tuberculous disease of knee-joint, 399
Whitman's operation in treatment of acquired talipes calcaneus, 810
Willett's operation in treatment of acquired talipes calcaneus, 808
Wire cuirasse for horizontal fixation in treatment of Pott's disease, 68
Wolff's law, 235
treatment of knock-knee, 574
Wrist, acute tenosynovitis at, 470
chronic tenosynovitis at, 471
congenital deformities at, 479
-joint, tuberculous disease of, 464
sprain of, 470
chronic, 470
subluxation of, 478
etiology of, 478
treatment of, 479
tuberculous disease of, 464
prognosis of, 466
statistics of, 464
age at incipiency, 465
symptoms of, 465
treatment of, 465
Wryneck. *See* Torticollis, 625

X-RAY as accessory in treatment of tuberculous disease of knee-joint, 417

LIBRARY OF CONGRESS
0 021 068 960 6